Symptomatic Malformation of the Prepyloric Mucosa *

JAMES D. SPRINKLE, M.D., RICHARD T. MYERS, M.D.

From the Department of Surgery, Wake Forest College, Bowman Gray School of Medicine, Winston-Salem, North Carolina

THE PREPYLORUS is an area of extreme interest both from the standpoint of antral physiology and pathologic affections. For example, differentiation of benign peptic ulceration and primary malignant disease, both common prepyloric lesions, encompasses a vast medical and surgical literature, and despite advances, remains a perplexing problem as evident by such careful follow up studies as Larson, Cain, and Batholomew.[1] A 57-year-old white gentleman recently presented with intractable epigastric pain and symptoms of intermittent pyloric obstruction and was considered preoperatively and at operation to have peptic ulceration of the prepylorus. A very unusual but definite mucosal malformation was found which constitutes the basis of this report.

Case Report

Mr. E. F. S. was first admitted to the North Carolina Baptist Hospital in January 1961, for evaluation of progressive epigastric burning pain of two years' duration which was becoming refractory to antacids and food ingestion. The distress was associated with intermittent nausea and vomiting, radiated to the back, and was separate from low back pain associated with an apparent herniated nucleus pulposus for which he was operated upon February 1960, without benefit. There was no hematemesis or melena.

In the past he had seasonal asthmatic symptoms and progressive exertional dyspnea secondary to pulmonary emphysema and fibrosis. He had smoked one to one and one-half packs of cigarettes daily for 40 years.

On physical examination, he was edentulous, had increased A-P diameter of chest, expiratory wheezes, healed surgical scar of lumbosacral spine, minimal prostatic enlargement, and decreased ankle jerks bilaterally. Abdominal examination was normal.

Laboratory work-up was within normal limits except for Hgb. 12.5 Gm.%. Chest x-ray was interpreted as left ventricular enlargement and pulmonary fibrosis, cholecystogram normal, and upper gastro-intestinal x-rays as "deformity of the antrum of the stomach and duodenal bulb with ulceration in the region of the pylorus." A diverticulum of the third portion of duodenum was also reported. Osteoporosis, rotary scoliosis, and deforming spondylosis, were present on x-rays of the lumbosacral spine.

He was discharged in February 1961, to the care of his physician on bland diet, antacids, and antispasmodics. Adherence to the medical regimen was intermittent and by March he began to have moderately severe constant epigastric pain radiating to the back. He experienced episodes of nausea and vomiting one-half to one hour postprandially over four- to seven-day periods with intervening respites of several days and then daily in the one month prior to his second admission. Vomiting would partially alleviate the pain, but antacids and antispasmodics became completely ineffectual. He lost 20 pounds in the two months prior to his second admission, but never had hematemesis or melena.

Upper gastro-intestinal x-rays in the surgical out-patient department, June 20, 1961, were reported as showing "persistent deformity thought to be related to scarring in the distal portion of the antrum of the stomach with a persistent incisura along the greater curvature aspect. There is an inconstant small filling defect adjacent to the incisura which is not conclusive for an ulcer." Cinefluoroscopy was recommended and performed June 26, 1961, and reported as follows: "In the very distal portion of the antrum along the greater curvature there was a constant deformity and narrowing, and this area did not

* Submitted for publication September 19, 1961.

support peristalsis. The caliber of the distal antrum was decreased in a constant fashion. Along the greater curvature there was a constant large collection of barium which extended beyond the confines of the normal stomach." Conclusion:

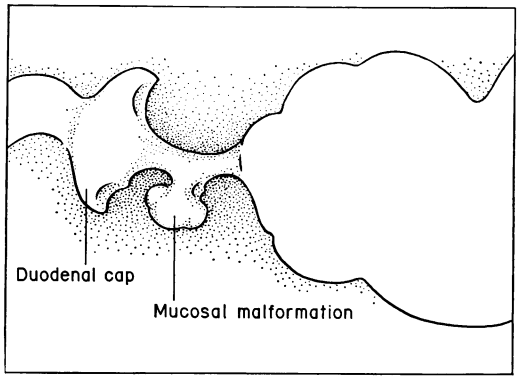

FIG. 1. Artist's conception of cinefluoroscopy. Routine photographic technics were indequate for reproduction.

FIG. 2. Mucosal aspect, gross specimen.

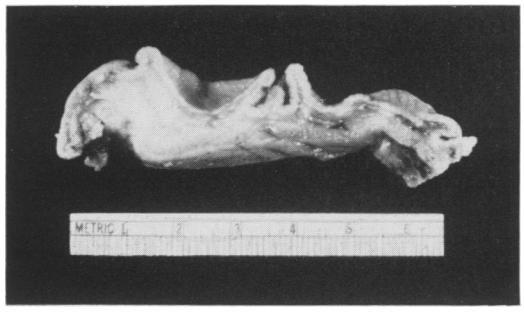

FIG. 3. Coronal aspect, gross specimen.

"There is an active ulcer along the greater curvature of the stomach in the very distal antrum in a juxtapyloric location with considerable narrowing of the antrum in this region." Figure 1 is an artist's conception of a typical segment of the cinefluoroscopy, the technic by which the lesion was best demonstrated.

On June 27, 1961, he was admitted to the surgical service, and minimal epigastric tenderness to deep palpation and evidence of weight loss were the only new physical findings. Except for blood urea nitrogen of 25 mg.%, albumin 3.1 Gm.%, and potassium 5.6 mEq./L., the laboratory workup was unchanged over the previous admission. A fasting gastric specimen, unstimulated, was negative for free acid. Vital capacity was 85 per cent normal.

Preoperative preparation included aerosols of penicillin and streptomycin in view of his chronic lung disease. At operation, omental adhesions and thickening of the prepyloric area were found. A definite crater-like defect was palpable along the greater curvature aspect of the prepylorus and this was thought to be gastric ulceration. There was no evidence of metastatic disease and, therefore, a two thirds subtotal gastric resection of the Billroth II type was performed. The postoperative course was uncomplicated and in the surgical out patient department several weeks later he was entirely asymptomatic.

Pathologic report was as follows: "*Macroscopic:* An apparent pyloric portion of stomach is 15 cm. along the lesser curvature and 18 cm. along the greater curvature. There is a previous defect within the wall 4.0 cm. in length on the anterior surface which is approximated by catgut suture. The external surface is wrinkled and glistening. There is approximately 2.5 cm. of proximal duodenum included. The mucosal folds are well preserved. In the immediate prepyloric area on the greater curvature there is a 3.0 × 2.5 cm. mucosal cup with redundant mucosa which falls toward the pyloric ring. The wall of this area on section is unremarkable.

Microscopic: In the prepyloric area the gastric mucosa is thrown up into exaggerated folds with a central cupped area which is lined by well preserved gastric mucosa. There is a slight increase of loose fibrous tissue within the submucosa in the areas of the elevated folds. The muscular layer and serosa are unremarkable.

Diagnosis: Gastric mucosal malformation with prepyloric cupping on the greater curvature."

The mucosal lesion is readily observed in Figures 2 and 3, respectively mucosal and coronal views of the gross specimen. A histologic section is seen in Figure 4, and represents the distal wall

and base of the mucosal and its location proximal to the pyloric ring.

Discussion

Symptoms of pyloric obstruction are common sequelae of peptic ulceration and carcinoma, and may be associated with other entities such as prepyloric diverticulum,[4, 7] pancreatic heterotopia,[3] and benign prolapse of the gastric mucosa.[2] According to Lichstein and Asher, gastroduodenal peristalsis under normal anatomic conditions can produce sliding of antral mucosa over its supporting layers and, despite a high incidence of associated disease (35 of 39 patients), they believe gastric mucosal prolapse is a specific clinical entity.[2] Todd reports a 7.8 per cent incidence of transpyloric prolapse of gastric mucosa on upper gastro-intestinal x-ray series and a 33 to 40 per cent incidence of associated pathologic lesions. Duodenal ulcer is most commonly associated, but gastroduodenitis, polyps, and gastric ulcer may be present.[6]

This mucosal malformation is most certainly congenital in origin and it appears that symptoms arose from transpyloric prolapse and intermittent entrapment of the redundant prepyloric mucosa. This lesion has not been observed in our previous experience and apparently not heretofore reported in American literature. Samuel describes a partial gastric diverticulum which is a mucosal projection into the gastric muscularis producing a filling defect radiographically because of surrounding mucosal edema.[5] However, this lesion differs from both gross anatomic and radiographic standpoints.

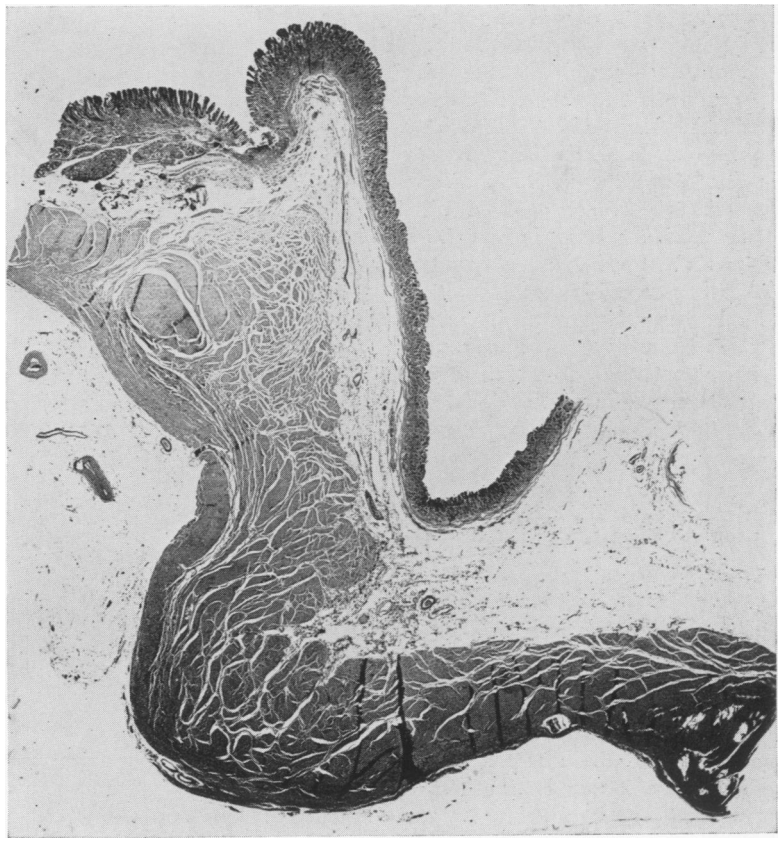

FIG. 4. Histologic section enlarged × 7.5, in which distal wall and base of mucosal cup and pyloric ring are demonstrated.

Summary

A very unusual benign prepyloric mucosal lesion is reported which presented clinically as intractable gastroduodenal ulceration with intermittent pyloric obstruction. Upper gastro-intestinal x-rays and cinefluoroscopic studies were interpreted as prepyloric ulceration. At operation the lesion was so grossly compatible with gastric ulceration, that a Billroth II subtotal gastrectomy was performed. No complications ensued and the patient experienced complete relief of symptoms.

Acknowledgments

The authors wish to acknowledge Drs. Ivan Holleman and Ray Cowan of the Department of Pathology for their disposition of the surgical specimen and Mr. George Lynch of the Department of Medical Arts for his reproduction of this cinefluoroscopy.

Bibliography

1. Larson, N. E., J. C. Cain and L. G. Batholomew: Prognosis of the Medically Treated Small Gastric Ulcer. I. Comparison of Follow-up Data in Two Series. New Engl. J. Med., **264**:119, 1961.
2. Lichstein, J. L. and L. M. Asher: Benign Prolapse of Gastric-Mucosa. J. A. M. A., **151**: 720, 1953.
3. Martinez, N. S. *et al.:* Heterotopic Pancreatic Tissue Involving the Stomach. Ann. Surg., **147**:1, 1958.
4. Montague, F. E. and J. C. Thoraughman: True Diverticulum of the Prepyloric Area of the Stomach. Am. J. Surg., **94**:669, 1957.
5. Samuel, E.: Gastric Diverticula. British J. Radiol., **28**:574, 1955.
6. Todd, M. C.: The Surgical Treatment of Prolapse of the Gastric-Mucosa. Amer. J. Gastroent., **33**:611, 1960.
7. Tracey, M. L. and B. P. Colcock: Gastric Diverticulum. Diagnosis and Indications for Surgical Excision. Gastroenterology, **18**:165, 1951.