ANNALS OF SURGERY
Vol. 230, No. 1, 24–30
© 1999 Lippincott Williams & Wilkins, Inc.

Hepatic Vascular Exclusion With Preservation of the Caval Flow for Liver Resections

Daniel Cherqui, MD, Benoît Malassagne, MD, Pierre-Ivan Colau, MD, Francesco Brunetti, MD, Nelly Rotman, MD, and Pierre-Louis Fagniez, MD

From the Department of Digestive Surgery, Hôpital Henri Mondor–Université Paris XII, Créteil, France

Objective
To report the technique and results of an alternative method of vascular clamping during liver resections.

Background
Most liver resections require vascular clamping to avoid excessive blood loss. Portal triad clamping is often sufficient, but it does not suppress backflow bleeding, which can be prevented only by hepatic vascular exclusion. The latter method adds clamping of the inferior vena cava, which results in hypotension, requiring invasive anesthetic management. There is growing evidence that intermittent clamping is better tolerated than continuous clamping, especially in the presence of underlying liver disease.

Methods
Hepatic vascular exclusion with preservation of the caval flow (HVEPC) involved conventional inflow clamping associated with outflow control by clamping the major hepatic veins, thus avoiding caval occlusion. HVEPC was used in 40 patients undergoing major or complex liver resection, including 16 with underlying liver disease. HVEPC was total (clamping of the porta hepatis and all major hepatic veins) in 20 cases and partial (clamping of the porta hepatis and the hepatic veins of the resected territory) in 20. Clamping was continuous in 22 cases and intermittent in 18. Resections included 12 hemihepatectomies, 12 extended hepatectomies, 3 central hepatectomies, and 13 uni- or bisegmentectomies.

Results
Hemodynamic tolerance of clamping was excellent in all cases, without the need for therapeutic adjustment. Median red cell transfusion requirements were 0 units, and 28 patients (70%) did not receive any transfusions during the hospital stay. There were no deaths, and the morbidity rate was 17.5%. Median hospital stay was 10 days.

Conclusion
HVEPC is a safe and effective procedure applicable to liver tumors without invasion to the inferior vena cava. It offers the advantages of conventional hepatic vascular exclusion without its hemodynamic drawbacks, and it can be applied intermittently or partially.

Control of bleeding remains a major key to successful hepatic resection.[1] Although some easy resections can be performed without any vascular clamping, most hepatectomies require some kind of vascular occlusion.[1–6] In most cases, inflow occlusion only is used by means of portal triad clamping (Pringle maneuver) or selective vascular occlusion (occlusion or division of the inflow to the resected lobe). However, inflow clamping does not prevent potential backflow bleeding from hepatic veins; the latter is prevented only by hepatic vascular exclusion (HVE), which involves both inflow and outflow hepatic vascular occlusion. Classic HVE includes portal triad clamping and clamping of the infra- and suprahepatic inferior vena cava (IVC).[7,8] Clamping of the IVC results in major hemodynamic disturbances requiring active intraoperative anesthetic management.[9] In addition, some patients do not tolerate HVE despite adequate management.[3] Another way to achieve HVE is to associate portal triad clamping with clamping of the major hepatic veins without clamping the IVC, as proposed by Elias et al.[10] This method, which we call HVE with preservation of the caval flow (HVEPC), avoids the hemodynamic consequences of HVE with caval clamping. In addition, HVEPC can be applied intermittently, and it can be total (clamping of the portal triad and all major hepatic veins) or partial (applied only to the tributaries of the resected lobe).

The aim of this study is to evaluate the results of total and partial HVEPC used in 40 patients, with special reference to

Correspondence: Daniel Cherqui, MD, Service de Chirurgie Générale et Digestive, Hôpital Henri Mondor, 94010 Créteil, France.
Accepted for publication February 26, 1999.

Table 1. INDICATIONS FOR 40 LIVER RESECTIONS UNDER HEPATIC VASCULAR EXCLUSION WITH PRESERVATION OF CAVAL FLOW

Indication	n
Hepatocellular carcinoma	13
With cirrhosis	9
Without cirrhosis	4
Cholangiocarcinoma	9
Intrahepatic	2
Klatskin tumor	5
Gallbladder cancer	2
Colorectal metastasis	8
Other metastasis	3
Benign lesion	7

technical issues, safety, and efficacy in terms of bleeding control.

PATIENTS AND METHODS

From June 1996 to June 1998, 86 hepatic resections were performed. Of these, 40 (46%) were performed with the use of HVEPC; these cases are the subject of this study. HVEPC was total in 20 cases and partial in 20. The resections included 27 major resections (three or more Couinaud's segments)[11] and 13 uni- or bisegmentectomies. The indications for liver resection are summarized in Table 1. Sixteen patients (40%) had underlying liver disease (cirrhosis in nine and obstructive jaundice in seven; the latter patients underwent surgery without preoperative biliary drainage). Indications for HVEPC were tumors with connections with the major hepatic veins, large tumors (≥10 cm), and anticipated bleeding during transection (cholestatic liver, elevated central venous pressure). During the same period, the clamping methods used in the other patients included HVE with clamping of the IVC in 4 cases (tumors with IVC invasion), portal triad clamping or selective inflow occlusion in 37 cases, and no clamping at all in 5 cases.

Surgical Technique

General Principles

A bilateral subcostal incision with upper midline extension was used in all cases. At the beginning of the operation, the liver was exposed and intraoperative ultrasonography was systematically performed. The method of vascular clamping was addressed in view of preoperative imaging, but the final decision was made after intraoperative assessment of the size and the location of the tumor and its connection to the hepatic veins and the IVC. HVEPC was used for large lesions (≥10 cm in diameter) or when the resection was considered to carry a risk of major hepatic vein injury. In case of suspected invasion of the IVC, HVE and IVC clamping was used; in one case, the tumor was separated from the IVC during an 8-minute IVC clamping secondarily converted to HVEPC.

Several types of clamping were used, according to the location of the lesion and the requirement for total or partial HVE. Total HVEPC (Fig. 1) involved clamping the porta hepatis, the left hepatic artery if present, the three major hepatic veins, and the right inferior hepatic vein if present. Left partial HVEPC (Fig. 2) excluded the left liver (segments II to IV) and part of the right anterior sector (segments V and VIII); it involved clamping the porta hepatis, the left hepatic artery if present, and the left and middle hepatic veins. Right posterior partial HVEPC (Fig. 3) excluded the right posterior sector (segments VI and VII) and involved clamping the porta hepatis or the right portal pedicle (portal and arterial branches to the right lobe) and the right hepatic vein, plus clamping or division of the right inferior hepatic vein if present. Right partial HVEPC, excluding the right lobe (segments V to VIII), was feasible only in cases where the left and middle hepatic veins had separate caval insertion; it involved clamping the porta hepatis and the right and the middle hepatic veins.

Control of Hepatic Veins

The falciform ligament was completely divided to expose the suprahepatic IVC and the confluence of the major hepatic veins. The right hepatic vein was controlled as previously described.[4,12] Briefly, after complete mobilization of the right lobe of the liver, the right and anterior aspect of the IVC was dissected by division of minor hepatic veins and division of the hepatocaval ligament, progressing cranially, until the right hepatic vein was exposed and encircled.

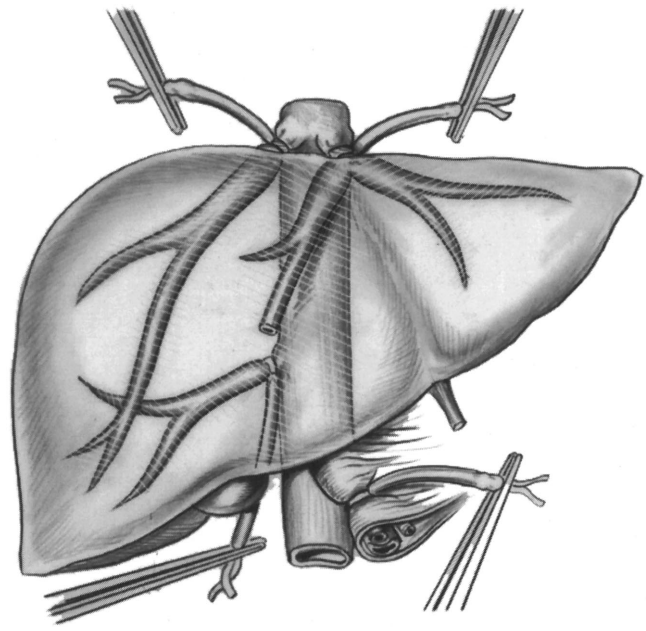

Figure 1. Total hepatic vascular exclusion with preservation of the caval flow. Inflow is occluded by portal triad clamping, and outflow is occluded by clamping the major hepatic veins, including the right inferior hepatic vein if present.

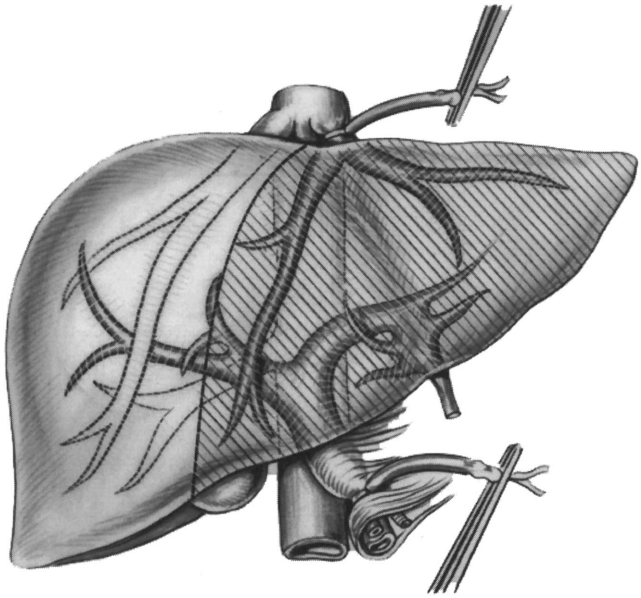

Figure 2. Left partial hepatic vascular exclusion with preservation of the caval flow. Inflow is occluded by portal triad clamping, and outflow is occluded by clamping the left and middle hepatic veins. Complete inflow occlusion is required to avoid middle hepatic vein congestion.

When a right inferior hepatic vein was present, it was either encircled or ligated and divided according to its size and the side of the resection. When the hepatectomy included the resection of segment I, the latter was completely separated from the IVC by division of all its venous branches until the liver was connected to the IVC by the three major hepatic veins only.

The control of the left and middle hepatic veins started by mobilization of the left hepatic lobe and division of the lesser omentum. The left upper aspect of the IVC was then exposed by division of the peritoneal reflection above the caudate lobe, and the ligamentum venosum was ligated and divided, exposing the junction of the left hepatic vein and the IVC. In most cases, the left and middle hepatic veins formed a common trunk and were encircled together, usually from right to left. In rare cases, the left and middle hepatic veins were looped separately.

Clamping Methods

For tumors without involvement of the hepatic hilum, the porta hepatis was clamped *en bloc* without prior dissection. For tumors involving the hepatic hilum, the porta hepatis was dissected. In all cases, when a left hepatic artery originating from the left gastric artery was present, it was either clamped or divided, according to the side of the resection. Vascular structures were encircled by umbilical tapes, and clamping was applied by a tourniquet. When the nontumorous liver was normal and a clamping time of $<$30 to 40 minutes was anticipated, continuous vascular occlusion was applied. In patients with underlying liver disease, or when a clamping time of $>$40 minutes was anticipated, intermittent occlusion was used, alternating 15-minute periods of clamping with 5-minute periods of clamp release.

Liver Transection

After cautery incision of the Glisson's capsule, liver transection was carried out using a Kelly forceps or an ultrasonic dissector. Hemostasis of vascular and biliary structures was achieved within the liver as they were encountered along the transection plane. Minor structures were treated with bipolar coagulation and the application of absorable clips or ties; larger structures were suture-ligated. In tumors without connections with the hepatic hilum, the main portal pedicles were ligated during liver transection, usually by application of a vascular stapler. In tumors with connections with the hepatic hilum, the main portal pedicles were divided extrahepatically before liver transection. In most cases, the main hepatic veins of the resected lobe were divided at the end of the transection; however, in some cases of right or extended hepatectomy, the right hepatic vein was ligated and divided before liver transection to facilitate exteriorization of the right lobe to be removed. Cholecystectomy was performed in all cases. Potential sites of biliary leakage were identified after resection by injection of methylene blue–dyed saline solution through the cystic duct, and completion cholangiography was performed in most cases to ensure the integrity of the remaining biliary tract. Fibrin glue was sprayed over the raw surface. Abdominal drainage was usually omitted.

Anesthesia Management

Efforts were made to avoid fluid overload and maintain low central venous pressure.[4,6] Packed red blood cells were

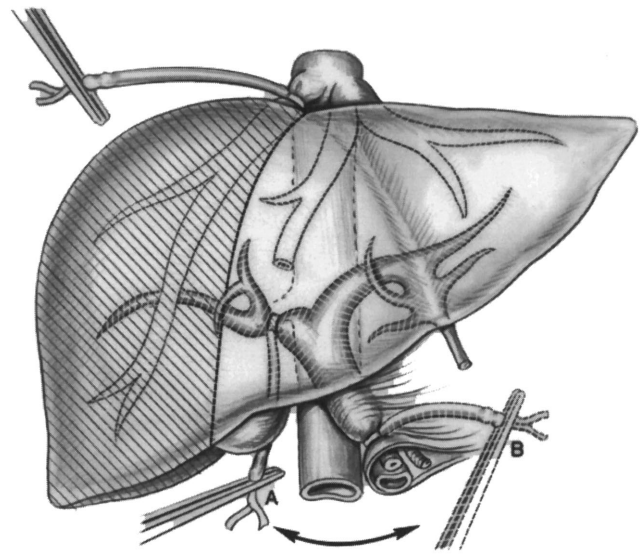

Figure 3. Right posterior partial hepatic vascular exclusion with preservation of the caval flow. Inflow is occluded by clamping the right portal pedicle (A) or the portal triad (B), and outflow is occluded by clamping the main right hepatic vein and the right inferior hepatic vein if present.

Table 2. TYPES OF LIVER RESECTIONS PERFORMED

Procedure	Total HVEPC (n = 20)	Left Partial HVEPC (n = 13)	Right Partial HVEPC (n = 4)	Alternate HVEPC* (n = 3)
Right hepatectomy	4			
Extended right hepatectomy	8			
To segment IV	5			
To segment I	3			
Left hepatectomy		8		
Extended left hepatectomy	2	2		
To segment VIII	1			
To segment I	1	2		
Left lobectomy (left lateral segmentectomy)		3		
Bisegmentectomy	2		2	
VII + VIII	1			
IV + V	1			
VI + VII			2	
Segmentectomy	4		2	
IV	2			
VII			2	
VIII	2			
Central hepatectomy (I,IV,V,VIII)				3

* Sequential left partial and right partial HVEPC.
HVEPC, hepatic vascular exclusion with preservation of caval flow.

the only blood product used. Red blood cells were transfused to maintain hematocrit ≥25% in patients younger than 60 years old and ≥30% in older patients and those with a risk of coronary disease. No autotransfusion was used.

Criteria Studied

The criteria studied were the type of clamping used, occurrence of surgical or hemodynamic difficulties or incidents, efficacy in obtaining a bloodless transection, transfusion requirements (both during and after surgery), mortality and morbidity rates, and hospital stay. Values are presented as mean ± SD (range) or median (range).

RESULTS

Types of Resections and Clamping Used

Total HVEPC was used in 20 cases where resections included segments in connection with the three major hepatic veins or the right and middle hepatic veins (Table 2). These included right and extended right hepatectomies and left hepatectomies extended to segments V and/or VIII. In two patients undergoing segmentectomy after previous hemihepatectomy, total HVEPC involved clamping the porta hepatis and the remaining hepatic vein(s). One of these patients had had previous right hepatectomy using HVEPC, and it was possible to control again the common trunk of the middle and left hepatic veins and reapply HVEPC. Left partial HVEPC was used in 13 cases where resections included segments in connection with the left and middle hepatic veins. These included formal left hepatectomies and left hepatectomies extended to segment I. In addition, we used left partial HVEPC in three left lobectomies (lateral segmentectomies), two in cirrhotic patients and one in a patient with congestive liver. Right posterior partial HVEPC was used in four cases of uni- or bisegmentectomy involving segment VI or VII. In three patients undergoing central hepatectomy (resection of segments IV, V, and VIII or I, IV, V, and VIII), alternate left and right posterior partial HVEPC was used. This operation involved two transection lines; the left one, between segments III and IV, was performed under clamping of the porta hepatis and the middle and left hepatic veins, and the right transection line, between the right anterior and posterior segments, was performed under clamping of the right portal pedicle and the right hepatic vein while the left lobe (segments II and III) was perfused.

Clamping was continuous in 22 cases, with a median duration of 27 minutes (range 10 to 45), and intermittent in 18 cases, with a median of three 15-minute courses of clamping (range 2 to 6). The median duration of surgery was 221 (range 150 to 360) minutes.

Surgical Results

Extrahepatic control of the major hepatic veins was possible each time it was attempted; there were no surgical incidents. Hemodynamic tolerance to HVEPC was excellent in all patients and identical to that of simple portal triad clamping; a slight increase in systemic arterial pressure was often observed during clamping.

HVEPC permitted a bloodless resection in all but one case of continuous clamping. In that one exception, some venous bleeding occurred; segment I had not been separated from the IVC, and venous connections between segment I and the clamped hepatic veins were suspected. Some degree of oozing from the part of the liver to be removed occurred in cases of intermittent clamping during the reperfusion phases, but it was easily controlled by compression. In addition, in cases where intermittent clamping was used, reperfusion allowed the liver to refill with blood, and minimal oozing could be seen at the beginning of the subsequent phase of transection.

Median red cell transfusion requirements (cumulative intra- and postoperative transfusions) were 0 (range 0 to 4) units. Of the 40 patients, 28 (70%) did not require any blood transfusion.

Mortality and Morbidity Rates

There were no postoperative deaths. One or more nonlethal complications occurred in seven patients (17.5%); complications included three subphrenic collections treated by percutaneous drainage, two episodes of ascites in cirrhotic patients, two cases of transient liver insufficiency after extensive resection, and one case of pneumonia. The postoperative course was uneventful in 33 patients (82.5%). Median hospital stay was 10 (range 7 to 28) days.

DISCUSSION

Intraoperative bleeding remains a major concern during liver resection, and the mortality and morbidity rates of these procedures clearly correlate with the amount of blood loss.[1,13,14] Taking advantage of the tolerance of the human liver to warm ischemia, interruption of blood flow to the liver by portal triad clamping or HVE is widely used, allowing many hepatic resections to be carried out without blood transfusions.[2–6,8,15–19] Portal triad clamping is sufficient in most cases to control bleeding during hepatectomy.[3] However, it does not prevent backflow bleeding from hepatic veins, which may become troublesome or even hazardous. This is particularly true in tumors that have connections to the major hepatic veins or are large. In these situations, HVE is recommended because it suppresses both inflow and backflow bleeding.[3,5,8,17–19] HVE, as initially described by Huguet et al, includes clamping the porta hepatis and the infra- and suprahepatic IVC.[7] HVE is the most effective method to achieve a bloodless hepatic transection.[8,15] However, caval clamping creates major central hypovolemia, which is the critical issue in HVE.[3] HVEPC permits both inflow and outflow occlusion while preserving the caval flow, thus avoiding hemodynamic disturbances. This technique was first formalized by Elias et al,[10] and few reports can be found in the literature.[20–22]

Our study demonstrates the feasibility, safety, and effectiveness of this clamping method. The advantages of HVEPC over conventional HVE are threefold: the preservation of hemodynamic stability, the possibility of intermittent application, and the possibility of partial exclusion. Our patients were very stable during surgery, particularly during the transection phase. It is well established that portal triad clamping alone is well tolerated and usually associated with a slight increase in systemic arterial pressure, as occurred in our patients.[20] The hemodynamic consequences of HVE with caval clamping have been well documented and include systemic arterial pressure and cardiac index reduction, which require fluid administration and occasionally the use of vasoactive drugs. Although hemodynamic tolerance to HVE can be achieved in most cases, these measures result in increased invasiveness. In addition, some patients with borderline cardiac function do not tolerate HVE because of persistent hypotension, despite adequate management.[3] This situation may require the use of venous bypass[23] or aortic clamping,[9] or may even make the resection impossible. Preservation of the caval flow with HVEPC avoids these consequences. The same observation has been made in orthotopic liver transplantation with preservation of the caval flow ("piggyback" procedure); this is an application of the same concept as HVEPC.[24,25]

A growing number of studies suggest that intermittent hepatic clamping is better tolerated than continuous clamping.[14,26–28] In a randomized trial, Belghiti et al[26] showed that hepatic ischemic injury, assessed by a postoperative rise in aminotransferase activity, was less severe with intermittent clamping than with continuous clamping for comparable or even longer cumulative clamping durations. This was particularly true in patients with underlying liver disease (*e.g.*, cirrhosis or steatosis) and probably also applies to patients with obstructive jaundice from cholangiocarcinoma. In addition, intermittent clamping may allow the surgeon time to perform a meticulous parenchymal transection and permits cumulative clamping times of >1 hour in complex resections; in contrast, single continuous clamping cannot usually exceed 1 hour. Finally, intermittent clamping allows splanchnic venous drainage during the reperfusion phases, which prevents excessive bowel swelling. Because HVE with caval clamping requires hemodynamic adjustment during vascular occlusion, intermittent interruption and release of the caval flow is impractical. In contrast, HVEPC, because it requires no hemodynamic adjustment, can be easily applied intermittently. We used continuous clamping in patients with normal livers and short anticipated clamping times. In other patients, including 16 patients with underlying liver disease, we used intermittent clamping. In such patients, intermittent HVEPC combines limited blood loss and limited ischemic injury, which are the main prognostic factors of outcome.

Partial vascular exclusion is an interesting possibility of the reported method. Whereas conventional selective inflow clamping is applied according to the anatomy of the portal pedicles,[4] partial HVEPC is based on hepatic venous anatomic territories. The left liver (segments II, III, and IV) is

drained by the middle and left hepatic veins, which commonly form a common trunk. Clamping this common trunk is sufficient to perform formal left hepatectomies, and clamping the right hepatic veins is unnecessary. This must be combined with complete portal triad clamping and not with selective left portal clamping to avoid congestion of the middle hepatic vein, which would remain fed by the right lobe. The right lobe of the liver (segments V to VIII) drains in the right and middle hepatic veins. Therefore, total HVEPC is usually required for right hepatectomies, except in the rare cases of separate implantation of the left and middle hepatic veins, where the left hepatic vein can be left unclamped. The right posterior sector (segments VI and VII) drains in the right hepatic vein and, when present, in the inferior right hepatic vein. In resections restricted to these segments, right posterior partial HVEPC can be applied by clamping the porta hepatis or the right portal pedicle and clamping the right hepatic vein(s). In central resections, which include two transection lines, one on the left liver and one on the right liver, alternate sequential partial HVEPC can be applied. When segment I must be removed, it must be completely freed from the IVC by division of all minor hepatic veins until the liver is completely pedicled on the three major hepatic veins. In a strict sense, total HVEPC should require systematic mobilization of segment I from the IVC to disconnect the liver completely from the systemic circulation and therefore achieve actual complete hepatic vascular exclusion. However, this is unnecessary when segment I is not part of the resection.

The efficacy of HVEPC for bleeding control was attested to by the 70% rate of nontransfused patients and the fact that no patient received more than four units of red blood cells. Blood loss was minimal during the transection phase, and most bleeding occurred during mobilization of the liver and after final reperfusion, especially in the presence of large tumors or an abnormal liver. As for conventional HVE, complete inflow occlusion of the clamped territory is essential to avoid liver congestion and bleeding; to this end, a left hepatic artery should always be sought in the lesser omentum and clamped accordingly. In all but one patient in whom continuous clamping was used, hepatic transection itself was bloodless. However, in that one case, some venous bleeding occurred during transection and was suspected to originate from the nondisconnected segment I. In patients who underwent intermittent clamping, we observed some degree of bleeding during liver transection. This occurred during the reperfusion phases, originating from the lobe to be resected, and at the beginning of each new transection phase because reperfusion allows the liver to refill with blood. However, this bleeding was mild and transient. This was also mentioned in the controlled study by Belghiti et al,[26] where bleeding was significantly greater during transection with intermittent clamping than with continuous clamping; however, this did not affect overall operative blood loss.

Indications for conventional HVE recommended by most authors include tumors with connections to the major hepatic veins or the IVC.[3,8,18,19,24] The indications for HVEPC should be the same, except for tumors with invasion of the IVC, which require caval clamping. Indeed, during the same period we used conventional HVE in four such patients, and in one case the tumor was dissected from the IVC under caval clamping secondarily converted to HVEPC once the IVC was cleared. We now make more liberal use of HVEPC for large tumors of the right lobe and in general for left hepatectomies because of the ease of partial left exclusion. This was extended to three left lobectomies (lateral segmentectomies) in the presence of cirrhosis in two cases and liver congestion in another. Indeed, a situation that increases bleeding from the hepatic veins during portal triad clamping alone is the inability to maintain low central venous pressure[29], and we had to use HVEPC for this reason. HVEPC was used in 13 so-called minor resections including uni- or bisegmentectomies. In fact, some of those segmentectomies may be difficult, such as those including segments VII and VIII. Partial or total HVEPC employed accordingly proved useful.

Potential drawbacks of HVEPC might include difficulties in the dissection and extrahepatic control of major hepatic veins, as well as possible injury to the hepatic vein or veins to be preserved with the remnant liver. This can be avoided by preliminary complete liver mobilization and exposure of the confluence of the hepatic veins and IVC above the liver and laterally. Encircling hepatic veins must not be done in a forceful manner. The use of tourniquets to clamp the hepatic veins seemed safer and less cumbersome than the use of regular vascular clamps, and no injuries occurred at the cavohepatic junction. This dissection might increase operative time, but it was not particularly long in our series and, unlike conventional HVE, retrocaval dissection and adrenal vein ligation are unnecessary.

There were no deaths in this series, and the morbidity rate was 17.5%. In addition, >80% of the patients had a smooth postoperative course, including 13 of 16 patients with underlying liver disease. These results reflect the safety and good tolerance of HVEPC.

In conclusion, our study shows that HVEPC is a safe and effective procedure applicable to liver tumors without invasion of the IVC. It has the advantages of conventional HVE without its hemodynamic drawbacks, and it can be applied intermittently or partially. We believe that this method represents a significant technical advance and that it should be part of the armamentarium of the liver surgeon.

References

1. Man K, Fan ST, Ng ION, et al. Prospective evaluation of Pringle maneuver in hepatectomy by a randomized study. Ann Surg 1997; 226:704–713.
2. Franco D, Smadja C, Meakins JL, et al. Improved early results of elective hepatic resection for liver tumors. Arch Surg 1989; 124:1033–1037.

3. Belghiti J, Noun R, Zante E, et al. Portal triad clamping or hepatic vascular exclusion for major liver resection. A controlled study. Ann Surg 1996; 224:155–161.
4. Malassagne B, Cherqui D, Alon R, et al. Safety of selective vascular clamping for major hepatectomies. J Am Coll Surg 1998; 187:482–486.
5. Gozzetti G, Mazziotti A, Grazi GL, et al. Liver resection without blood transfusion. Br J Surg 1995; 82:1105–1110.
6. Cunningham JD, Fong Y, Shriver C, et al. One hundred consecutive hepatic resections. Blood loss, transfusion, and operative technique. Arch Surg 1994; 129:1050–1056.
7. Huguet C, Nordlinger B, Galopin J, et al. Normothermic hepatic vascular exclusion for extensive hepatectomy. Surg Gynecol Obstet 1978; 147:689–693.
8. Bismuth H, Castaing D, Garden J. Major hepatic resection under total vascular exclusion. Ann Surg 1989; 210:13–19.
9. Delva E, Barberousse JP, Nordlinger B, et al. Hemodynamic and biochemical monitoring during major liver resection with use of hepatic vascular exclusion. Surgery 1984; 95:309–318.
10. Elias D, Lasser P, Dabaene B, et al. Intermittent vascular exclusion of the liver (without vena cava clamping) during major hepatectomy. Br J Surg 1995; 82:1535–1539.
11. Couinaud C. Le foie: etudes anatomiques et chirurgicales. Paris: Masson; 1957.
12. Makuuchi M, Yamamoto J, Takayama T, et al. Extrahepatic division of the right hepatic vein in hepatectomy. Hepatogastroenterology 1991; 38:176–179.
13. Nagorney DM, Van Heerden JA, Ilstrup DM, Adson MA. Primary hepatic malignancy: surgical management and determinants of survival. Surgery 1989; 106:740–749.
14. Makuuchi M, Takayama T, Gunven P, et al. Restrictive versus liberal blood transfusion policy for hepatectomies in cirrhotic patients. World J Surg 1989; 13:644–648.
15. Huguet C, Addario-Chieco P, Gavelli A, et al. Technique of hepatic vascular exclusion for extensive liver resection. Am J Surg 1992; 163:602–605.
16. Jamieson GG, Corbel L, Campion JP, Launois B. Major liver resection without a blood transfusion: is it a realistic objective? Surgery 1992; 112:32–36.
17. Cherqui D, Tantawi B, Alon R, et al. Intrahepatic cholangiocarcinoma. Results of aggressive surgical management. Arch Surg 1995; 130: 1073–1078.
18. Grazi GL, Mazziotti A, Jovine E, et al. Total vascular exclusion of the liver during hepatic surgery. Selective use, extensive use, or abuse? Arch Surg 1997; 132:1104–1109.
19. Berney T, Mentha G, Morel P. Total vascular exclusion of the liver for the resection of lesions with contact with the vena cava or the hepatic veins. Br J Surg 1998; 85:485–488.
20. Delva E, Camus Y, Paugam C, et al. Hemodynamic effects of portal triad clamping in humans. Anesth Analg 1987; 66:864–868.
21. Leow CK, Leung KL, Lau WY, Li AKC. Intermittent vascular exclusion of the liver (without vena cava clamping) during major hepatectomy. Br J Surg 1996; 83:712.
22. Yanaga K, Matsumata T, Hayashi H, et al. Isolated hepatic caudate lobectomy. Surgery 1994; 115:757–761.
23. Yamaoka Y, Ozawa K, Kumada K, et al. Total vascular exclusion for hepatic resection in cirrhotic patients. Application of venovenous bypass. Arch Surg 1992; 127:276–280.
24. Belghiti J, Panis Y, Sauvanet A, et al. A new technique of side to side caval anastomosis during orthotopic hepatic transplantation without inferior vena caval occlusion. Surg Gynecol Obstet 1992; 175:270–272.
25. Cherqui D, Lauzet JY, Rotman N, et al. Orthotopic liver transplantation with preservation of the caval and portal flows. Technique and results in 62 cases. Transplantation 1994; 58:793–796.
26. Belghiti J, Noun R, Malafosse R, et al. Continuous versus intermittent portal triad clamping for liver resection: a controlled study. Ann Surg 1999; 229:369–375.
27. Elias D, Desruennes E, Lasser P. Prolonged intermittent clamping of the portal triad during hepatectomy. Br J Surg 1991; 78:42–44.
28. Wu CC, Hwang CR, Liu TJ, P'eng FK. Effects and limitations of prolonged intermittent ischemia for hepatic resection of the cirrhotic liver. Br J Surg 1996; 83:121–124.
29. Jones RML, Moulton CE, Hardy KJ. Central venous pressure and its effects on blood loss during liver resection. Br J Surg 1998; 85:1058–1060.