GUMMA OF THE BREAST; ITS DIFFERENTIAL DIAGNOSIS FROM CARCINOMA*

By Frank E. Adair, M.D.
of New York, N. Y.

FROM MEMORIAL HOSPITAL; AND THE DEPARTMENT OF PATHOLOGY, CORNELL MEDICAL SCHOOL

In many instances the accurate diagnosis of breast conditions is most difficult. This is due chiefly to three causes:

I. The numerous manifestations of the normal breast; or the near normal breast; such as a thin breast, a fat breast, a pregnant breast, an involution breast following pregnancy, etc.

II. The varying phases of the normal breast due to the person's *age;* such as a breast of puberty or the atrophy and involution of the breast past the climacteric.

III. The multiple and widely varying forms taken by each of the well known diseases of the breast; such as carcinoma, fibro-adenoma, chronic mastitis, cysts, traumatic fat necrosis,[1] etc.

Other reasons for difficulty in breast diagnosis lie in the lack of help afforded by the anamnesis. The history of any given breast condition is less pathognomonic and less helpful for working out an exact differential pathological diagnosis, than the history which goes with a duodenal ulcer, or a gall-bladder disease. One must take the aid supplied by the available history; but he must chiefly rely upon our sense of careful scrutiny; and a sense of delicate touch.

In this paper the author will not attempt to differentiate gumma of the breast from the normal variations of the organ, nor from the changes due to the age of the patient; nor from the majority of the well known diseases of the breast. But since it is a common error to mistake gumma for carcinoma, our attempt will be to emphasize a number of points in diagnosis which will place gumma of the breast in a clean-cut category of disease so that more gummata will be recognized; fewer will be operated upon; and more patients will retain their breasts.

Virchow in 1861 said "concerning syphilitic tumors of the breast we know very little"; he states that he welcomed an opportunity to study one.

Lancereaux declared that "any one who had not observed the commencement of this affliction and did not know the antecedents of the patient, would be unable to distinguish this tumor from that known under the name of scirrhous of the lactiferous ducts."

Edward Martin[9] says "The diagnosis from cancer may be quite impossible except from a consideration of the associated symptoms and the result of the therapeutic treatment."

* Read before the Clinical Research Society of New York City, January 31, 1923.

Even those surgeons who see an extraordinarily large number of breast cases, have rarely seen a gumma of the breast. In fact the *rarity* of the condition is where the responsibility lies for its non-recognition; because it

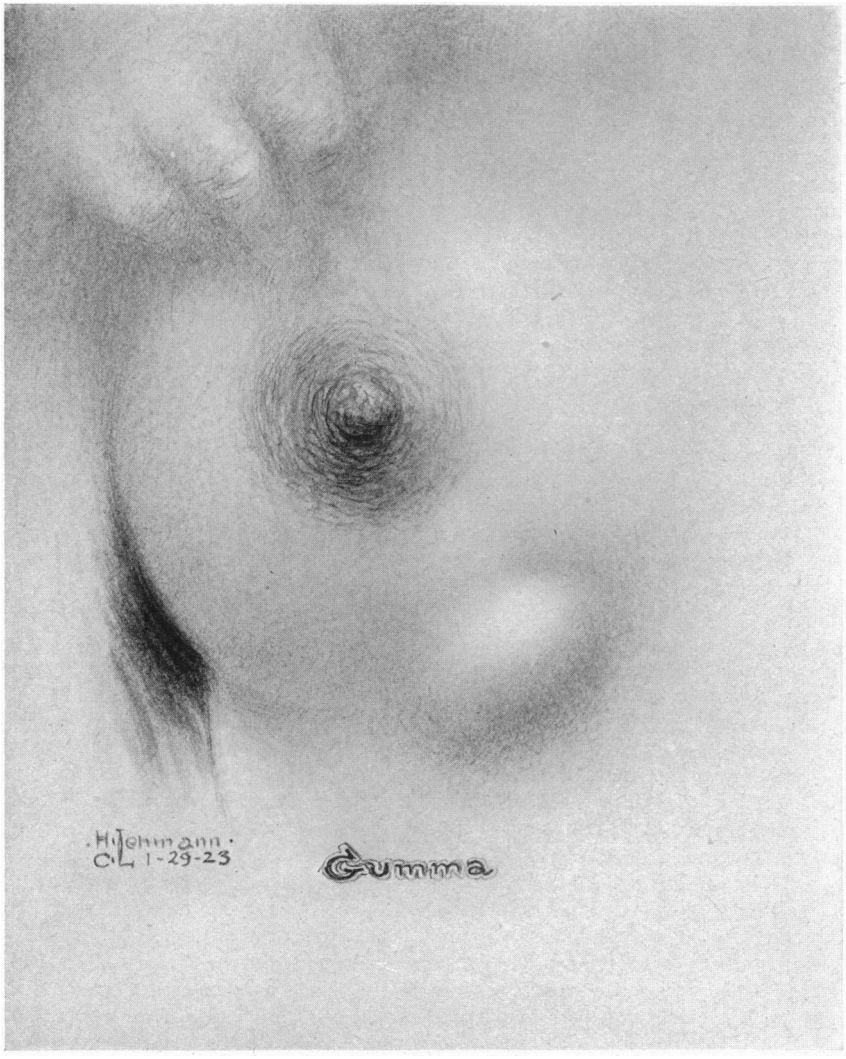

FIG. 1.—Gumma of breast.

has sufficient in the way of history, appearances and characteristic attributes, to definitely be diagnosed before coming to the operating table.

In the Breast Clinic of the Memorial Hospital conducted by Dr. B. J. Lee and the author, we see large numbers of breast cases with malignant and non-malignant conditions. But this is the only case of gumma which we have had during the period in which 1674 cases of carcinoma have been observed. It

is therefore obvious that gumma is a rare breast tumor. The following is the case report of a patient who came to Memorial Hospital August 14, 1922:

R. G., age thirty-five, female, married. Due to the fact that she spoke a Hungarian dialect only a poor history could be elicited. In brief it is as follows:

Family History.—Negative.

Personal History.—One year ago she had an operation at Mt. Sinai Hospital for "red spots" over the outer part of right shoulder. Otherwise, history is negative. At a later date through an interpreter the following supplementary history was obtained; but not until some time after her operation. It would have been an aid to diagnosis had we obtained it before our operation. The patient had one miscarriage during her first year of married life. Husband had had syphilis four years before his marriage. He had had no treatment. Otherwise the history is negative.

Mammary History.—About five months ago, the patient noticed a lump (Fig. 1) in the lower inner portion of the right breast, situated at the fold of breast with chest wall. This has increased considerably in size in past three weeks and has *recently* begun to give slight discomfort. No treatment has been given except application of salves locally. There is no history of trauma.

Physical Examination.—Patient is a middle-aged woman, with rather a pasty complexion.

Head.—Eyes react to light and accomodation.

Nose.—Negative except for a slight scar and redness of the skin of the nasal septum.

Mouth.—Teeth Poor. Marked pyorrhœa. No leucoplakia.

The outer aspect of right shoulder shows an irregular scar of a former operation. (Fig. 2.)

Chest.—Heart. Sounds are normal. Not dilated. *Lungs.*—There are occasional sibilant sonorous râles over lungs posteriorly, especially on right side. *Abdomen.*—Negative. *Lymph-nodes.*—There is slight enlargement of the entire system, but it is not marked.

Surgical Condition.—There is a tumor of the right breast situated at the fold of breast with chest wall. It appears about the size of a hen's egg bisected on its long axis; tumor is dome-shaped. It has a reddish-bronze color and is very hard in consistence; smooth over its surface; fairly sharply circumscribed; seems to be part of and attached to the skin; measures about 6 by 4.5 cm., and is elevated from the chest wall about 2.5 cm. at its peak. The tumor is movable on the chest wall and has no deep attachment. It is not tender to palpation. There is no nipple retraction; and no orange-peel skin appearance. Remainder of the breast is negative. Left breast is negative. The nodes in both axillæ are palpable but not sufficiently enlarged or hard to make a diagnosis of carcinomatous involvement certain. However, mental reservation was made on this point. There was one node in the left supraclavicular region which is hard and markedly enlarged.

The above physical examination was made by our admitting physicians who felt it was carcinoma of the breast; and they sent it to me for operation. The patient did not return for operation until ten days later. When she came the picture had changed in two respects; namely, there was a slight elevation of temperature of the tumor itself; and also a suggestion of fluctuation at the apex of the tumor. At the periphery it was very hard. In fact most of the tumor had the stony hardness of carcinoma. The skin had become deeper bronze color. My feeling was that this was some unusual form of infection. So instead of doing the radical breast amputation for carcinoma, an incision was made directly into the tumor. There exhuded about 30 c.c. of dirty looking, liquified necrotic tissue, which did not simulate pus. A section was removed for microscopic study, from the

thick indurated wall. The part of the tumor which was not necrotic was hard and appeared very cellular and œdematous; it simulated sarcoma tissue. The diagnosis was still uncertain so the cavity was packed. Further procedure was

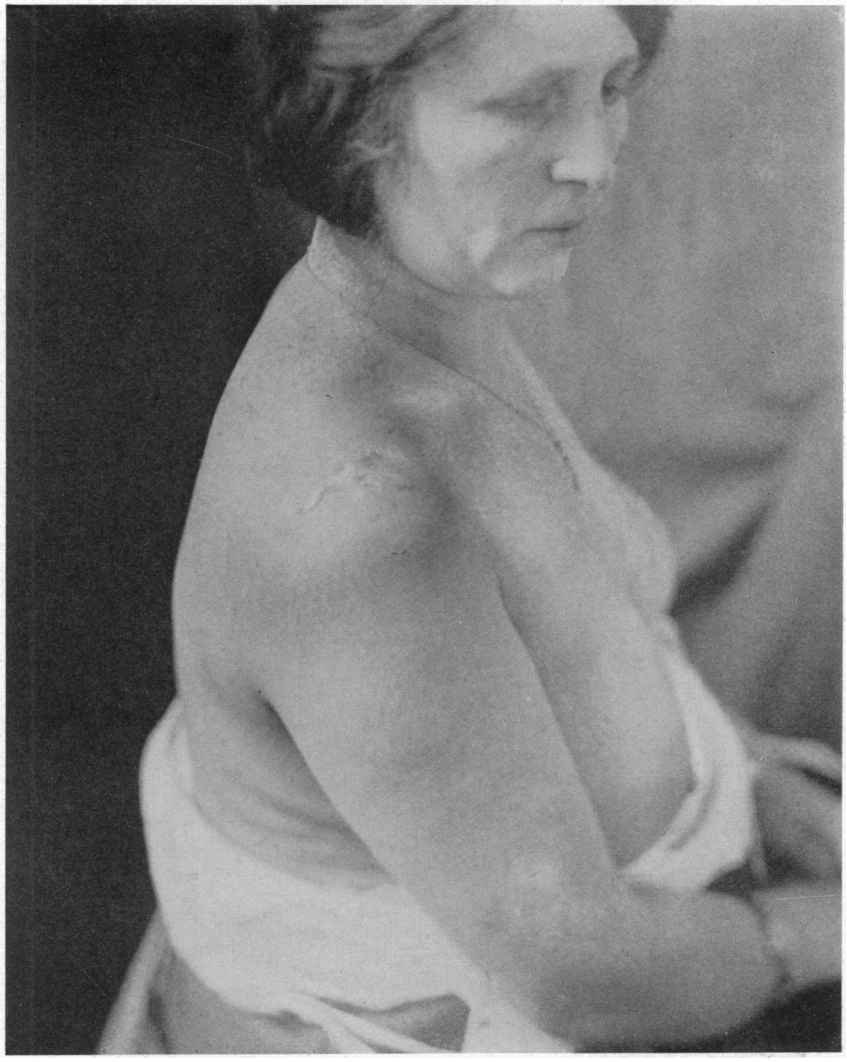

FIG. 2.—Showing scar of former operation on right shoulder.

to be guided by the microscopic report. Later the pathological report came that the tissue showed an infective process; with no evidence of neoplasm.

The subsequent course of this case was, that the wide open wound drained profusely for about a month. The bottom of the wound was covered with grayish, dirty, necrotic material. The sharp edges of the wound became red, thick, and clean-cut overhanging the excavated cavity. It was typical of a syphilitic ulcer. This condition persisted with not the slightest attempt at any reparative process. On two occasions, the slides were reviewed with a pathologist to ascertain his

impression as to whether or not it might be a tubercular process. It was at this juncture that we secured the interpreter who gave us the history of the syphilitic infection of the husband; and the miscarriage in the patient. Blood was taken for a Wassermann test; and it was reported four plus.

The slide was reviewed by Dr. James Ewing whose report follows: "The specimen consists of fat tissue very thickly infiltrated with lymphocytes and

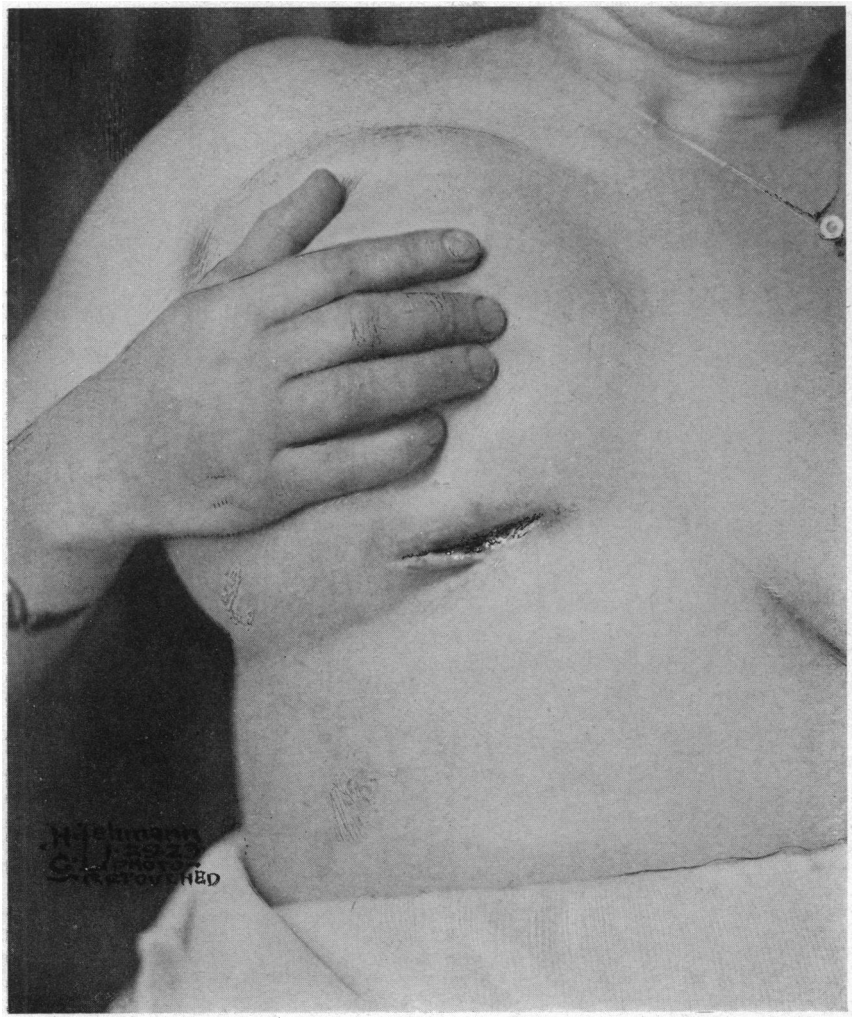

FIG. 3.—Showing wound of operation healing under the influence of salvarsan internally.

plasma cells. Some large arteries show lymphoid infiltration of the adventitia. There is no necrosis. Polymorphonuclear leucocytes are very abundant throughout. The lesion may be interpreted as a gumma."

I asked Dr. F. F. Mandlebaum, Pathologist to the Mt. Sinai Hospital, to review his sections of the tissue ("red spots") removed from the right shoulder, May 22, 1921, when the patient was operated in that institution. His report is: "Although the essential lesion is that of a purulent inflammation, there are some

vascular changes, which, in view of the further development in the case, may be interpreted as due to syphilis."

An X-ray plate was made of the ribs to see if this gumma might have some connection. Doctor Herendeen reported it "negative for bone involvement."

The patient was given seven doses of salvarsan which by January 15, 1923 entirely healed the gumma—four and one-half months after the patient was first seen.

Figure 3 shows the process when five doses of salvarsan had been given; a short time before the wound healed.

One will usually find some other evidence of a tertiary lesion associated with a breast gumma; in this case it is the nasal septum and the skin lesion (Fig. 2).

The natural history of gumma of the breast is more readily comprehended if divided into the following six periods:

First Period.—A lump appears which is painless, smoothly surfaced, very hard, shapely circumscribed, freely movable in the breast. There is no nipple retraction unless the tumor lies in close proximity to the nipple.

Second Period.—The tumor usually grows outward. It begins to involve the subcutaneous tissues. There may or may not be "orange-peel" appearance. The overlying skin becomes attached to the tumor.

Third Period.—The tumor in its growth pushes outward the overlying skin; and the skin becomes incorporated as a part of the tumor. The skin takes on a blush tint.

Fourth Period.—The tumor has increased in size; the skin has become purple or bronze due to the pressure and the stagnant blood supply. The centre of the tumor softens; and later becomes fluctuant. As it softens it becomes slightly tender. It now has a dome contour; and is shaped like a hen's egg bisected along the long axis.

Fifth Period.—Due to pressure necrosis, the skin becomes so thin and unhealthy that the gumma perforates and the necrotic material drains out.

Sixth Period.—After evacuation of the contents, a typical, crater-like, dirty, gray, sloughing, foul, deep syphilitic ulcer remains. This stage will remain until the patient receives anti-luetic treatment.

The great importance of this tumor lies in the fact that during the first three or four periods above described, it so simulates carcinoma of the breast, that it is most difficult to distinguish, and only with the most minute consideration will it be possible to do so before the tumor has reached the Fourth Period. After this stage the diagnosis is more simple.

The fact that a patient has had syphilis must not have too strong a bearing against the diagnosis of carcinoma; for we occasionally see a carcinoma in a luetic subject. Incidentally this group fare much worse than when carcinoma of the breast is not on luetic soil.

There are points which gumma and certain types of carcinoma have in common: namely, (1) stony hardness; (2) sharp circumscription; (3) painlessness; (4) skin involvement.

There are some characteristics of gumma usually not found with carcinoma. These are of diagnostic aid: (1) history of syphilitic infection;

miscarriage, etc.; (2) presence of other syphilitic manifestations; (3) bizarre involvement of the lymph-nodes; (4) tumor egg-shaped; (5) rarely orange-peel skin appearance; (6) gumma grows faster than carcinoma; (7) nipple never retracts unless lesion lies very near it; (8) fluctuation is the rule at one stage; (9) tenderness at this stage; (10) at later stage of ulceration the axillary nodes become markedly involved; (11) Wassermann test positive; (12) therapeutic test with salvarsan.

In carcinoma, the regional lymph-nodes do not become involved in any bizarre or irregular fashion; but they follow the definite rule that on the side of the lesion, the axillary and low-lying cervical " signal " nodes are involved first. Also in carcinoma, nipple retraction or a nipple slightly " stuck " is one of the *very early* signs; this point cannot be over emphasized.

In the following analysis of the 45 case reports previously recorded, one notes that the first report was 155 years ago, by Sauvages in 1768. It is interesting that it was a hundred years later before the disease became sufficiently recognized to merit a place in the text-books on breast diseases. Gromo's [34] thesis was an impetus because he was the first to collect the case reports. It seems strange that in searching the literature, one finds but 45 cases recorded. A study of these cases is unsatisfactory because of lack of information on which to base a diagnosis. One is struck with the confusion of gumma with carcinoma. Such terms as " pseudo-scirrhous " and others equally vague, are common. Pathologic fractures are recorded. Some " died from the disease." In New York one case was shown before a Dermatological Society [29] as a case of Paget's Disease; the same case later was presented as a gumma. The case of Patterson [30] in England is interesting. His case was confused with malignant disease. He made an ante-operative diagnosis of carcinoma; he performed a radical breast amputation before a surgical society. On gross section it appeared to be sarcoma. He brought out the point that grossly the fibrous tissue of this tumor so simulated sarcoma that he wondered how to avoid making a similar mistake in diagnosis.

Age Incidence.—There are 33 cases recording the age of the patient; eight cases reporting no age. There is one case in a congenital luetic child; two, in " old woman "; one in " middle age "; and one, in " young lady." According to decades:

1 to 10 years	– 1 congenital child.
10 to 20 years	– 2 cases.
20 to 30 years	– 6 cases.
30 to 40 years	–10 cases.
40 to 50 years	– 8 cases.
50 to 60 years	– 6 cases.
62 years	– 1 case.

Sex Incidence.—Of the 35 cases recording sex, it was 3 times present in men and 32 times in women.

Syphilitic History.—Of the 46 cases here recorded, 19 (41 per cent.) give definite syphilitic history. Lesions of lues other than gumma also were reported in 19 cases (41 per cent.). Unquestionably many such lesions were overlooked.

The diagnosis of gumma will chiefly depend on an exact detailed study of the *tumor itself.*

Size.—The most common size is that of a hen's egg. By this I presume most authors mean a hen's egg split on its long axis—in reality half an egg. The size is one of the most striking points. In going back to the original sources of these 45 cases reported from Italy, Netherlands, Germany, Scotland, France and America, it is interesting to note that the most descriptive term which came to the mind of these authors widely scattered in different countries, and separated by a space covering 155 years, was that of the "hen's egg."

The size was recorded in 29 cases; and in 11 cases it was the size of a "hen's egg"; 1 case, a "dove's egg"; 1 case, a "pigeon's egg"; 2 cases, a "small apple"; 2 cases, "an apple"; 1 case, "a lemon"; 1 case, a "hickory nut"; 2 cases, "a nut"; 1 case, a "thumb"; 1 case, a "button" 1 case the "head of an infant," the latter being the *only* case recorded in which the tumor grew to any great proportion. Five cases had the exact measurements given, and these, with one exception, corresponded to about the size of an egg. Therefore in diagnosis this size is one of our most important points.

Consistence.—One of the most impressive characteristics of gumma is "stony hardness." This consistent feature is responsible for it being mistaken for cancer. The hardness is maintained up to the period where necrosis begins in the centre, due to poor blood supply. In 17 cases such expressions as "densely hard," "hard," "the hardness of scirrhous," etc., were used.

It is an interesting fact that 7 of these 17 cases, *during the period of observation,* became soft or fluctuant; and 6 of the 17 cases were observed to go on to ulceration. This shows the later stages of the life history very clearly. There were thirteen cases which either ulcerated while under observation, or were ulcerated when the patient first came.

Surface.—In 21 cases the tumor was rounded. It is a smooth roundness from base to apex of tumor; and the peak is a rotund dome.

Color.—The color entirely depends on the stage of the disease:

(a) At first there is no discoloration of the over-lying skin.

(b) Later due to pressure by the tumor against the dermal vessels and capillaries, the skin takes on a faint blush; then a bluish-red; then purple; later bronze.

(c) At this juncture skin necrosis sets in, and it is a lead color.

(d) The dirty color of ulceration is the last stage.

Tumor Edge.—The base of the tumor as a rule has a definite, sharp edge. It is in no way comparable to an infiltrating carcinoma. In 8 cases where there is mention of the edge of tumor, seven had sharp, well defined edges. In only one case was it indistinct.

Pain.—One of the chief diagnostic points is painlessness at first. It is only in the later stages of tumor softening that pain is present. Thirteen of the tumors were painless; two of these 13 *while under observation* became painful. Five tumors were painful. The tumor is not tender to touch. It is tender only after fluctuation has appeared.

Movability.—The tumor is usually movable in breast tissue. In those cases where the point is discussed 8 cases were freely movable and only one had deep attachment.

Rate of Growth.—The tumor develops rapidly in comparison to most breast tumors; and goes on to quick ulceration. In Lapowski's case [29] the tumor grew in three months; in Bruc's case [26] the growth was " rapid "; in the author's case it took five months.

Skin Attachment.—Little aid is given on analysis of this point. Of 14 case reports mentioning this, 5 have no skin attachment, 6 have definite attachment, and 3 have tumor fusion with the skin. This point depends on the period of the disease. Early there is no attachment; late there is fusion.

Nipple Retraction.—In the eight reports mentioning this, 5 had definite retraction and 3 did not. But where so large a proportion of the 45 cases do not mention it, probably there was no retraction. Nipple retraction will occur only when the gumma lies in close proximity to the nipple.

Axillary Node Involvement.—In the 21 case reports mentioning this, 12 cases had no palpable involvement. Nine cases had definite enlarged nodes in the axilla of the side of the breast lesion. One states that the axillary mass of nodes is the size of an egg. Axillary node enlargement comes particularly at the time of ulceration; but is not to be expected before this stage. Delbert [35] states there are no axillary nodes; and gives this as an important differentiating point.

Supraclavicular Node Involvement.—Six cases had supraclavicular involvement; and six cases had the supraclavicular group combined with other lymphatic manifestations. There is great irregularity as to which supraclavicular nodes become involved.

Breast Involvement.—(a) One breast only was involved in 19 cases, in which this was mentioned. The probabilities are that the 18 cases in which this point was not mentioned had but one breast involved.

(b) Eight cases had gummata of both breasts.

(c) Seven cases had more than one gumma in the same breast.

(d) In one, the gumma lay between the breasts.

Wassermann Test.—In only three of the 46 cases was the test made. They were all positive. It is interesting to note in 1912 in the case of Yvert [31] which he had in the rural districts of France, that " a Wassermann was considered but not made because it cost too much for the test."

Microscopic Examination.—Aside from the case of the author, it has been made in only two previous cases. Had it been more frequently made we would have found more cancer cases in this series; and fewer gummata.

TABLE I.

Reported by year	Patient's age	Male	Female	Syphilitic history	Other signs	Tumor size	Tumor hardness	Soft or fluctuant	Tumor shape	Tumor color	Tumor edge	Tumor painful	Tumor painless	Tumor ulcerated	Movable in breast	Rate of growth	Skin attachment	Deep attachment	Nipple retracted	Orange peel skin	Axillary nodes	Supraclavicular nodes	General glandular enlargement	One breast	Both breasts	More than one tumor	Wassermann report	Microscopic report	Diagnosis	Surgical treatment	Antiluetic treatment	Remarks.
Sauvages [2], 1768	40		+			Head of infant																		+					Cancer	+		Removed because would not heal.
Sauvages [2], 1768	30		+	+	+	"Egg"	+		Rounded			+		O											+						+	Tumor disappeared under medication.
Bierchen [3], 1775	Record of case not obtained																															Author thought it "special type of cancer".
Richet [4], 1849	22		+	+	+	Chestnut grew to small apple	+	Became + fluctuant	Rounded	Became bronzed	Sharp	Later +	At first +	O			Fused		+					+		+			Scirrhus	+		Incision drained pus. Remained indurated.
Yvaren [5], 1854	48		+		Nasal +		+			Lead dirty				+										+	Between the breasts	+			"Pseudo scirrhus"			
Verneuil [6], 1855	?	+				6×3 cm.								Just + starting			Fused	+			O							+				
Ambrosoli [7], 1864	19		+	+	+					Not discolored		+		O							+				+						+	Cured.
Ambrosoli [7], 1864	24		+	+	+																			+							+	Cured.
Ichard [8], 1867	50		+	+	+	"Egg"	+	Became +	Rounded	Brown		+			+		+				Hard +			+							+	Cured.
Velpeau	48		+			"Egg"	+		Rounded						+		+												Cancer	Refused	+	Cured.
Hennig [10], 1870	55		+	+	+	6×7×3 mm.				Reddish brown				O											+							Case autopsied. Billroth doubted its authenticity.
Horteloup [11], 1872	47	+		+	+	Small apple, right Left, chestnut			Rounded	Not discolored						Slow	O								+							
Landreau [12], 1874	20		+	+	+					Normal					+						+	+	+	+							+	Cured.
Landreau [12], 1874	"Old woman"		+			"Large egg"			Rounded					+	+			O			O				+						+	Improved at first. Later died, generalized.
Landreau [12], 1874	45		+			3×1×0.5 cm. "Nut"	+						+	Later +	+						O			+						+		Breast amputated. Got spontaneous fracture of femur. Died.
Landreau [12], 1874	Case reported as gumma, died of cancer		+																													
Boeck [13], 1875	"Old woman"		+	+	+	"Dove's egg"		+	Rounded								O							+						+	+	Cured.
Boeck [13], 1875	Refers to case similar, but gives no details.																															
Segond [14], 1878	40		+	+	+	"Thumb"								+					+		Only one			+							+	
Cheever [15], 1879	?	+		+		"Egg"	+		Rounded	Reddish														+							+	Disappeared in three weeks.
Lang [16], 1880	39																														+	Cured. Parotid became enlarged.
Gay [17], 1883	19		+			"Hickory nut"	+					+							+						+	+			Non-malignant tumor	+	+	Wound broke down. Healed by antiluetic treatment.
Jully [18], 1888	Child congenital																															

TABLE I.—*Continued.*

Reported by year	Patient's age	Male	Female	Syphilitic history	Other signs	Tumor size	Tumor hardness	Soft or fluctuant	Tumor shape	Tumor color	Tumor edge	Tumor painful	Tumor painless	Tumor ulcerated	Movable in breast	Rate of growth	Skin attachment	Deep attachment	Nipple retracted	Orange peel skin	Axillary nodes	Supraclavicular nodes	General glandular enlargement	One breast	Both breasts	More than one tumor	Wassermann report	Microscopic report	Diagnosis	Surgical treatment	Antiluetic treatment	Remarks.
Neumann [19], 1889	27		+			"Apple"			Rounded				+	+							O	O	O	+								
Malfeso [20], 1890	Record of case not obtained																															
Ostermayer [21], 1893	26		+	+	+	"Egg"	+		Rounded	Bluish	Sharp			+	O		+				+	O			+	+						
Ostermayer [21], 1893	50		+		+		+			Very red	Sharp													+							+	Cured.
Emery [22], 1896	30		+	+	+	"Nut"			Rounded			+		Later +				O	+	+	O	O										
Legrain [23], 1897	50		+	O	O	"Button"				Bronze	Sharp		+	+			+				+ Size egg					+						
Kennedy [24], 1902	30		+	+	+	"Pigeon's egg"	+	Became + soft	Rounded	First red. Later blue red			+		+		O				O	O	O	+		+					+	Cured.
Heller [25], 1903	62		+		+	"Apple"	+	Became soft +	Rounded																	+		O	Scirrhus cancer	+	+	Due to bad heart condition, operation at first not done; antiluetic treatment. Later operation [because so large.
Heller [25], 1903	?																											+	Cancer			
Bruc [26], 1903	56		+	+			+			"Dark"				Later +		Rapid		O	O		O	Opposite +	Opposite axilla 1 node						Cancer			Patient refused operation.
Beer [27], 1905	35		+			6×7.5 cm.		+			Indistinct		+				O		O		+	+		+		O			Others—cancer, beer, syphilis		+	Cured in one month.
Bissel [28], 1907	32																															
Bissel [28], 1907	48		+	+		"Lemon"	+	Became +	Rounded		Sharp													+					Sent for cancer operation			Indurated growth.
Bissel [28], 1907	"Middle age"																															
Bissel [28], 1907	39			+												Slow																
Bissel [28], 1907	35					"Small egg"			Rounded				+						+			+										
Lapowski [29], 1908	56		+	+		7×7 cm. "Orange"	+	Became +	Rounded	Normal at first. Later red	Sharp		+	Not at first Later +			+				+	+	+		+				"Paget's disease" (cancer)		+	Shown first before society as a Paget's disease. Later treated by drugs.
Patterson [30], 1909	26		+				"Densly + Hard"						+			Three months	O	O			O			+					Cancer	+		On section looked like sarcoma. Radical operation. Two weeks later ulcerated and knew it was syphilis.
Yvert [31], 1912	46		+			"Egg"	+		Rounded	Later red			+	Became +							O	O	O				"Not done, cost too much"		Cancer			
Yvert [31], 1912	?					"Egg"			Rounded					+							O	O	O						Cancer			
Chevannez and Loubet [32], 1913	"Young lady"		+		+	"Egg"			Rounded	Later red			+		+		+				+			+			+				+	Cured
Thompson [33], 1920	33		+		+	10×4 cm. "Walnut"			Rounded				+								O			+			+				+	
Adair, 1923	35		+	+	+	6×4.5×2.5 cm. "Egg"	+	Became +	Rounded	Bluish red	Sharp	Later + slight	+	O	+	Five months	Fused	O	O	O	O	Opposite +	Slight +	+		O	+	Gumma +	1. Cancer 2. Infection	Simple incision +	+ Later	Sent for radical operation for cancer. Incised on diagnosis of infection. Wound would not heal. Antiluetic treatment, cured.

Preliminary Diagnosis.—One of the most striking points of the analysis is, that of the 15 cases in which diagnosis was made before operation, or before the diagnosis became self evident by the progress, 14 cases were definitely diagnosed as cancer; and only one case as a non-malignant condition.

Treatment.—(a) In 20 cases anti-luetic treatment was given; of these the records state 13 were cured.

(b) In eight cases surgical treatment was resorted to; some had a radical amputation of the breast and axillary contents. Some had less radical surgery performed. Some refused surgical aid.

One patient died and an autopsy was made. Billroth doubted the authenticity of this being a gumma. In another case, the patient got a spontaneous fracture and died. In these last two cases it requires little imagination to see the confusion between gumma and carcinoma in this series of reported cases. (See table of analysis of 46 cases.)

BIBLIOGRAPHY

[1] Lee and Adair: Traumatic Fat Necrosis of the Female Breast and Its Differentiation from Carcinoma. ANNALS OF SURGERY, August, 1920, p. 189. A Further Report on Traumatic Fat Necrosis of the Female Breast and its Differentiation from Carcinoma. ANNALS OF SURGERY, April, 1922, p. 521.

[2] Sauvages: Nostologia Methodica, 1768, T. iv, p. 344.

[3] Bierchen: Abhandlung von dem wahren Krebschaden. Göttingen, 1775.

[4] Richet: Maladies du sein—Valpeau 2e édition, 1849, p. 535.

[5] Yvarren: Métamorphoses de la syphilis, 1854, p. 435.

[6] Verneuil: Bulletin de la Société anatomique, 1855, 30e annéé, p. 97.

[7] Ambrosoli: Di una malatti della glande mammae. Gazetta Med. c. ital., Lombardi, 1864.

[8] Icard: Note sur un cas de tumeur syphilitique simulant un cancer du sein. Journal de méd. de Lyon, 1867, vol. vii, p. 23.

[9] Martin: Keen's Surgery, vol. i, p. 715.

[10] Hennig: Archiv für Gynakäologie, 1870, ii, Band, p. 71.

[11] Horteloup: Les tumeurs du sein chez l' homme. Thèse de d'agregation, 1872.

[12] Landreau: Thèse de Paris, 1874.

[13] Boeck: Erfahrungen über Syphilis. Stuttgart, 1875, p. 165.

[14] Paul Segond: Thèse de Gromo, 1878.

[15] Cheever: Boston Med. and Surg. Jour., vol. c, 1879, No. 12.

[16] Lang: Wr. med. Wochenschr., 1880.

[17] Gay: Syphilitic Mammary Disease. Report of a Case of Inherited Syphilis, etc. Med. Record, 1883, vol. xxiv, p. 91.

[18] Jully: Virchow. Hirsch, 1888.

[19] Neumann: Über die syphilitische Erkrankung der Brustdrüse. Allg. Wien med Zeitung, 1889, vol. xxxiv, p. 593.

[20] Malfeso: Un caso di mastite gummosa. Progresso med. Napoli, 1890, vol. iv, p. 375.

[21] Ostermayer: "Ein Fall von Gummöser Erkrankung der Weiblichen Brüstdrusse." Arch. f. Dermat. und Syph. Wien und Leipsiz, 1893, vol. xxv, p. 940.

[22] Emery: Gomme du sein. Bull. soc. franc de dermat. et syph. Paris, 1896, vol. vii, p. 36.

[23] Legrain: Mastite syphilitique gommeuse. Ann. de dermat et syph., Par., 1897, 3 S, vol. viii, p. 500.

[24] Kennedy: Case of Gumma of the Mamma. Tr. Med. Chir. Soc. Glasg., 1902, vol. iii, p. 71.

[25] Heller: Munchener med. Woch., 1903, vol. l, 738.

[26] Bruc: Mastite gommeuse du sein gauche. Montpel. Med., 1903, vol. xvi, p. 244.

[27] Beer: Medical News, N. Y., 1905, vol. lxxxvii, p. 825.

[28] Bissel: Syphilitic Tumors of Breast. Medical Record, N. Y., 1907, vol. lxxii, p. 14.

[29] Lapowski: Jour. Cut. Diseases, N. Y., 1908, vol. xxvi, p. 372.

[30] Patterson: Gumma of the Breast Simulating Malignant Disease. Proc. Royal Society of Med., London, 1909, vol. iii, p. 82.

[31] Yvert: Les tumeurs syphilitiques du sein. Poitu med., Poitiers, 1912, vol. xxvii, p. 179.

[32] Chevannez et Loubet: Gomme syphilitique du sein. Jour. de med. de Bordeaux, 1913, vol. xliii, p. 482.

[33] Thompson: Gumma of the Breast. J. A. M. A., 1920, vol. lxxiv, p. 791.

[34] Gromo: Syphilis Héréditaire et tertière. Thèse de Paris, 1878.

[35] Delbet: Duplay et Reclus. Traité de Chirurgie, vol. v, p. 857.