# Development of Aspirin Hydrolase in Fetal, Newborn and Adult Tissues

EDWARD J. EYRING, M.D., Ph.D.,* JAY L. GROSFELD, M.D.,**
PATRICIA A. CONNELLY

*From the Department of Orthopaedics, the Division of Pediatric Surgery, Department of Surgery, and the Department of Physiological Chemistry, Ohio State University College of Medicine, and the Children's Hospital, Columbus, Ohio*

ASPIRIN has been utilized for many years as a therapeutic agent because of its well known analgesic, antipyretic, and anti-inflammatory activity. In recent years unwanted side effects, particularly hemorrhage, has been the subject of considerable concern. Gastrointestinal bleeding, occurring in patients on salicylate therapy, has been considered due to inhibition of gastric mucous production.[14] Other data suggest that aspirin also has a direct effect on the coagulation mechanism by inhibiting platelet aggregation.[8,9,19,20]

Salicylates have been shown to induce congenital malformations in many animal species and be the cause of a high fetal death rate.[6,7,10,11] Skeletal anomalies and fetal hemorrhage located in the skin, liver, and stomach have been observed following salicylate treatment in late pregnancy.[6,7,13]

Since aspirin administration has shown its effect in both man and experimental animals in all stages of the life cycle, a study to help improve our understanding of drug tolerance of this commonly used medication would be useful. The purpose of this report is to study the development and activity of the detoxifying enzyme acetylsalicylic (aspirin) hydrolase in rabbit tissues from midfetal to adult life.

## Materials and Methods

Twenty-one white New Zealand rabbit does each weighing 8 pounds with dated pregnancy were housed in individual stainless steel cages. The pregnant does were maintained on standard rabbit chow and had an unlimited water supply. Based on a dated gestational period of 32 days, six does were lightly anesthetized with dilute intravenous barbiturate—three at 18 days and three at 25 days. Laparotomy was performed through a midline incision. In each instance, both uterine horns were mobilized and the uterine wall opened over each fetus. Fetal midline laparotomies were then done with intact placenta and umbilical vessels. Total hepatectomy, bilateral nephrectomy, gastrectomy, and resection of the entire small bowel were rapidly performed and the tissues placed into iced potassium chloride solution.

The remaining 15 does were allowed to come to term. Newborn rabbits were maintained in nests of fur, usually prepared by the doe and were allowed to nurse until the time of sacrifice. In the newborn and at 2, 5, 28 days, and six months of age three litters each were sacrificed and their tissues analyzed.

The organs or tissues excised were similar to those removed from the fetal rabbits and are listed in Table 1. In all cases where fetuses and rabbits up to 4 weeks old were studied, the figures represent pooled samples of an entire litter, ranging from 3 to 8 animals. For the 6-month-old rabbits, the figures indicate average activity in three to five samples of each tissue, each from a separate animal.

All steps in the enzyme preparation were carried out at 0–4°C. After removal from the animal, the tissues were placed immediately in 0.12 M KCl.

Submitted for publication 1972.

Supported by grants from Glenbrook Laboratories and the United Health Foundation.

* For Reprints: 973 East Broad Street, Columbus, Ohio 43205.

** Present Address: Division of Pediatric Surgery, Department of Surgery, New York University School of Medicine.

TABLE 1. *Levels of Hydrolysis Activity in the Various Litters Studied Measured in Micromoles ASA Hydrolyzed per Milligram of Protein per Minute* $\times 10^{-4}$

| | 2 wk. fetus | 3 wk. fetus | New-born | 2 day old | 5 day old | 4 week old | 6 month old |
|---|---|---|---|---|---|---|---|
| Liver | 3.7 | 3.5 | 18.9 | 22.2 | 26.9 | 139.0 | 88.6 |
| Kidney | 0.0 | 1.1 | 5.5 | 3.8 | 3.3 | 3.7 | 5.4 |
| Small Intestine | 0.0 | 1.8 | 1.8 | 44.4 | 76.0 | 136.0 | 50.0 |
| Stomach | 0.0 | 2.2 | 2.8 | 31.4 | 25.8 | 57.5 | 44.0 |

The tissues were homogenized either by hand in a teflon tipped tissue grinder or in the Virtis 45 homogenizer at low speed for approximately five minutes, depending on the amount of tissue and its fibrous content. In either case, the tissues were ground until a homogenous suspension was obtained. No differences were noted in assays made on tissues prepared by the two methods.

The entire greater curvature of the stomach and the first 5 inches of the small intestines were used in the samples for the younger rabbits. In the older and larger rabbits, the stomach and small intestines were scraped separately to remove the linings only.

The homogenates were strained through several layers of gauze and centrifuged at 9,000 rpm for 10 minutes. The microsomal supernatant obtained was used as the enzyme preparation. Total protein determinations were performed on this fraction using a micro Biuret technic described by Dawkins.[3]

The following substances were added to give the final concentration needed in a 5 ml. system: $KPO_4$ buffer; 0.01 M; pH 7.0; acetylsalicylic acid 30 $\mu$g/ml.; enzyme in 0.05, 1.0 mg./ml. concentration, depending on the activity. The reaction was started by the addition of the enzyme. A control with boiled enzyme was run with each experiment. Incubations were carried out in a 37°C shaker bath. 1.0 ml. aliquots were removed at various intervals of time and added to 50 ml. centrifuge tubes containing 0.5 mg. 5% $KHSO_4$. Five ml. of anhydrous ether were added immediately and tubes were tightly stoppered. The tubes were then shaken 100 times by hand and spun 5 minutes at 1500 rpm. Three ml. of the ether extract was pipetted into a second 50 ml. centrifuge tube containing 3.0 ml. of $KPO_4$ buffer, 0.01 M, pH 7.0. These were then shaken and spun again. The ether layer was discarded and $N_2$ bubbled through the aqueous layer for 30 seconds to remove the remaining ether.

The salicylic acid present was then determined on an Aminco-Bowman spectrophotoflurometer using excitation at 310 mu and emission at 410 mu against a standard of salicylic acid in concentration ranging from 0.1–2.0 $\mu$g/ml.

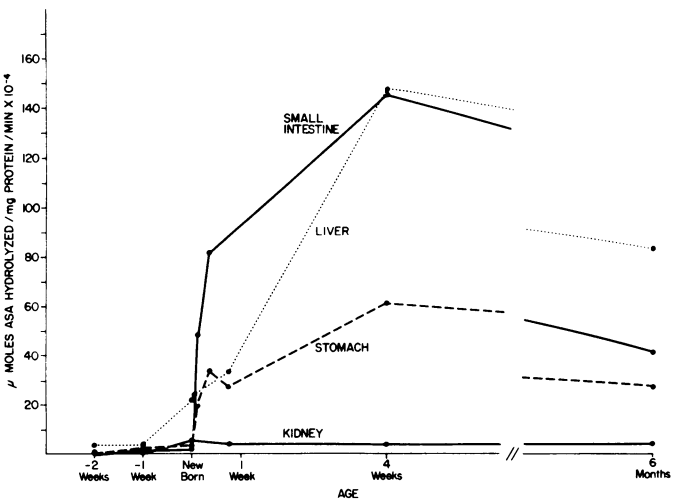


FIG. 1. This graph demonstrates the pattern of aspirin hydrolase activity observed in fetal, newborn, young, and 6-month-old rabbits. No activity is observed in the fetus. Starting at birth (liver) or shortly thereafter (GI-tract) a rapid rise in the rate of hydrolysis is observed with a gradual decline over 6 months. At 6 months of age, liver shows the greatest activity. Kidney activity remained very low throughout the duration of the procedure.

## Results

During the fetal period there was little, if any, hydrolase activity in any of the organs tested (Table 1).

At the time of birth, however, the liver showed a fivefold increase in hydrolysis rate while hydrolase activity of kidney, small intestine, and stomach remained low.

During the first week of life, the rate of liver hydrolysis continued to rise. The first significant stomach and small intestine activity appeared at 2 days and by 5 days had exceeded that of the liver. The kidney activity remained low.

By 4 weeks of age, all hydrolase activity had reached a maximum from which there was a gradual decline over the next 5 months to stable levels. At 6 months of age the greatest activity was observed in the liver.

## Discussion

Infants and children are more sensitive to salicylates than adults. However, very little is known about the susceptibility of the human fetus to this medication.[5] The mechanism of teratogenic action of acetylsalicylic acid has been considered due to a direct toxic effect on fetal cells and/or an uncoupling effect on oxidative phosphorylation.[10,11] Salicylates have been shown to have a significant influence on intermediary metabolism and exert inhibitory effects on at least three vital groups of cellular enzymes: oxidative phosphorylases, dehydrogenases, and transaminases.[17]

The development of enzyme activity in fetal and neonatal animals has numerous theories of explanation including substrate induction, birth stress, adrenal innervation, and inhibitors of gene action or enzyme action.[2,4,

[12,15] Moreover species and tissue differences are known to be reflected in differences in the rate of enzyme development.[2] While enzyme induction might occur in the fetal liver as thought by Weinberger *et al*,[18] experiments in our laboratory and by others suggest that acetylsalicylic acid (aspirin) hydrolase at birth follows the developmental pattern of other hydrolases such as glucose-6-phosphatase.[3] Its appearance therefore must be explained in terms of adrenocortical activity associated with birth stress and environmental change from intrauterine to extrauterine life.

Centrifugation studies in this report show that most aspirin hydrolase activity is present in the microsomal fraction of the tissues studied with very little activity found in the cytoplasmic supernatant.

Two patterns of activity were noted in rabbit tissues. The first exemplified by the liver, where enzyme activity was absent in the fetus, appreciable at birth, rising to a maximum and gradually falling to a stable level. The liver had the highest levels observed in older animals. Kidney activity was present at birth also, but did not rise further.

The second pattern of aspirin hydrolase activity was followed by the gastrointestinal tract where no activity was present until after birth. Activity rose rapidly for a few days, and then more slowly to a maximum and then dropped off by 6 months of age to a lower level than the liver.

While it may be difficult to assume that hydrolase activity in the human is similar to the rabbit because of significant variations between species, there is evidence to show that enzyme activity in the liver of premature infants is comparable with both rat and rabbit fetuses.[12]

Salicylate induced enzymatic inhibition of the synthesis of acid sulpho-mucopolysaccharide (an important factor in ground substance) has been suggested as a cause of skeletal malformations in fetuses of experimental animals.[13]

Eriksson demonstrated fetal hemorrhages located in the liver, skin, and stomach was a common finding following salicylate treatment in mice late in pregnancy.[6,7] These fetuses showed decreased prothrombin levels, diminished liver glycogen stores, and liver hemorrhage with hepatatic-cell necrosis. The present report suggests that these findings may be due to absence of activity of the detoxifying enzyme acetylsalicylic acid (aspirin) hydrolase in the fetal liver.

It has been suggested that fetal hemorrhage may also be due to anoxia associated with degenerative changes in the liver.[7] In addition, thrombocytopenia and/or a coagulation defect due to a depression of some coagulation factors has also been suggested as the underlying mechanism of induced hemorrhage.[8,9] Bleyer and Breckenridge described platelet dysfunctions and diminished factor XII activity in human newborn infants of mothers who had taken aspirin during the week prior to birth.[1]

Aspirin appears to inhibit the release of endogenous platelet ADP, and thus, prevents collagen induced platelet aggregation.[8,19,20] The "acetyl" structure of aspirin is of great importance since sodium salicylate does not inhibit platelet release of ADP and subsequent aggregation.

Gastric hemorrhage in patients receiving aspirin has been attributed to an increased gastric mucosal permeability for the hydrogen ion.[16] Menguy also described a decrease in the rate of secretion and change in carbohydrate composition of gastric mucus due to aspirin administration.[14] These findings suggested that gastric injury results from an impairment of mucosal defense mechanisms against the erosive action of acid gastric juices.

Absence of the detoxifying enzyme aspirin hydrolase may play a role in instances of fetal hemorrhage and skeletal malformations. However, high levels of the enzyme are present after birth and indicate that other factors, particularly aspirin inhibition of platelet ADP release and changes in gastric mucus play a significant role in older patients on aspirin therapy who exhibit bleeding problems. Exceptions to this may occur in premature infants and in older individuals with severe liver disease where a relative deficiency of enzyme activity may exist. Furthermore, these observations suggest a possible potential hazard in the administration of aspirin to gravid females late in pregnancy, in premature infants, and in patients with severe liver disease and/or known bleeding disorders where control of hemostasis may be a problem.

## Summary

This report describes the development of the detoxifying enzyme acetylsalicylic acid (aspirin) hydrolase in rabbit tissues from midfetal to adult life. The litters of 21 rabbit does with dated pregnancy were studied. Tissues were obtained from fetuses in the second and third week of gestation, newborn, 2, 5, 28 days, and 6-month-old rabbits. The hydrolysis rate of the microsomal fraction of liver, kidney, and the gastrointestinal tract were evaluated. Little hydrolase activity was observed in any of the fetal tissues. A five-fold increase in liver activity was noted at birth. Kidney activity remained low in all animals studied. Gastrointestinal activity appeared at 2 days. By 4 weeks of age liver and gastrointestinal hydrolase activity reached a maximum and gradually declined to stable levels. At 6 months the liver tissue had the greatest activity.

Absence of the detoxifying enzyme aspirin hydrolase may play a role in instances of fetal hemorrhage and skeletal malformations observed in fetuses of pregnant

animals treated with aspirin. However, high levels of enzyme present after birth indicate that other factors particularly aspirin inhibition of platelet ADP release, and changes in gastric mucus play a significant role in older patients on aspirin therapy who exhibit bleeding problems. These observations suggest a possible potential hazard in the administration of aspirin to gravid females late in pregnancy, in premature infants, and in patients with severe liver disease and/or known bleeding disorders, where control of hemostasis may be a problem.

## References


1. Bleyer, W. A. and Breckenridge, R. T.: Studies on the Detection of Adverse Drug Reactions in the Newborn. II. The Effects of Prenatal Aspirin on Newborn Hemostasis. J.A.M.A., **213**:2049, 1970.
2. Comline, R. S. and Silver, M.: Development of Activity in the Adrenal Medulla of the Fetus and Newborn Animal. Br. Med. Bull, **22**:17, 1966.
3. Dawkins, M. J. R.: Changes in Glucose-6-phosphatase Activity in Liver and Kidney at Birth, **191**:72, 1961.
4. Dawkins, M. J. R.: Biochemical Aspects of Developing Function in Newborn Mammalian Liver. Br. Med. Bull., **22**:27, 1966.
5. Done, A. K.: Developmental Pharmacology. Clin. Pharmacol. Ther., **5**:432, 1964.
6. Eriksson, M.: Salicylate-induced Fetal Hemorrhage in Two Mouse Strains. Acta. Pathol. Microbiol. Scand. **76**:164, 1969.
7. Eriksson, M.: Salicylate-induced Fetal Damage Late in Pregnancy. An Experimental Study in Mice. Acta. Paediatr. Scand., Suppl. 211, 1971.
8. Evans, G., Packham, M. A., Nishizawa, E. E., Mustard, J. F. and Murphy, E. A.: The Effect of Acetylsalicylic Acid on Platelet Function. J. Exp. Med., **128**:877, 1968.
9. Frick, P. G.: Hemorrhagic Diathesis with Increased Capillary Fragility Caused by Salicylate Therapy. Am. J. Med Sci., **231**:402, 1956.
10. Goldman, A. S. and Yakovac, W. C.: Salicylate Intoxication and Congenital Anomalies. Arch. Environ. Health, **8**:648, 1964.
11. Klein-Obbink, H. J. and Dalderop, L. M.: Effect of Acetylsalicylic Acid on Fetal Mice and Rats. Lancet, **2**:152, 1964.
12. Kretchmer, N.: Enzymatic Patterns During Development. An Approach to a Biochemical Definition of Immaturity. Pediatrics, **23**:606, 1959.
13. Larson, D. S. and Bostrom, H.: Teratogenic Action of Salicylates Related to the Inhibition of Mucopolysaccharide Synthesis. Acta. Paediatr. Scand. **54**:43, 1965.
14. Menguy, R. and Eiseman, B.: Extragastric Factors Associated with Peptic Ulcer. Curr. Probl. Surg., pp. 20, Aug., 1964. Year Book Publ., Chic., Ill., 1964.
15. Nemeth, A. M.: Mechanisms Controlling Changes in Trytophan Peroxidase Activity in Developing Mammalian Liver. J. Biol. Chem., **234**:2921, 1964.
16. Smith, B., Skillman, J. J., Edwards, B. G. and Silen, W.: Permeability of the Human Gastric Mucosa: Alterations by Acetylsalicylic Acid and Ethanol. N. Engl. J. Med., **285**:716, 1971.
17. Smith, M. J. H. and Smith. P. K.: The Salicylates. John Wiley and Sons, Inc., New York, 1966.
18. Weinberg, M. S., Goldhamer, R. E. and Carson, S.: Acute Oral Toxicity of Various Drugs in Newborn Rats after Treatment of the Dam During Gestation. Toxicol Appl. Pharmacol., **9**:234, 1966.
19: Weiss, H. J., Aledort, L. M. and Kochwa, S.: The Effect of Salicylates on the Hemostatic Properties of Platelets in Man. J. Clin. Invest., **47**:2169, 1968.
20. Zucker, M. B. and Peterson, J.: Inhibition of Adenosine Diphosphate Induced Secondary Aggregation and Other Platelet Functions by Acetylsalicylic Acid Ingestion. Proc. Soc. Exp. Biol. Med., **127**:547, 1968.