Periileostomy Fistulae in Crohn's Disease

ADRIAN J. GREENSTEIN, M.D., ADAM DICKER B.A., SAMUEL MEYERS, M.D.,* ARTHUR H. AUFSES, JR., M.D.

Fifteen of 214 patients with an ileostomy constructed during the course of Crohn's disease developed periileostomy fistulae. In each case this was the consequence of recurrent ileal disease. The incidence was higher in female patients as well as those with a prior history of either intraabdominal abscess or any type of fistula. Periileostomy fistulae are frequently multiple. In addition to the clinical features of recurrent disease, periileostomy fistulae cause additional symptoms that are particularly distressing. These result from the proximity of the fistula to the stoma and the difficulty of maintaining the seal of an appliance. All periileostomy fistulae require resection and reconstruction of the stoma. Superficial fistulae with relatively smooth skin around the stoma may be reconstructed using the original stoma site; but deep fistulae with severe peristomal excoriation, induration and inflammation require transposition to a different quadrant. This may, in suitable cases, be carried out by direct stoma-to-stoma transposition, without formal laparotomy. The quality of life following successful reconstruction of the stoma is excellent, even though some patients will develop additional recurrent disease. To date none of these patients have developed another periileostomy fistula.

From the Departments of Surgery and Medicine (Division of Gastroenterology), of the Mount Sinai School of Medicine of the City University of New York and The Mount Sinai Hospital, New York, New York*

THERE ARE NOW 1010 patients with Crohn's disease in the data bank of The Mount Sinai Medical Center of whom 149 (14.7%) developed an external fistula. Two hundred and fourteen patients within the entire group had an ileostomy constructed, and of them 15 (6.9%) developed a parastomal fistula.

Periileostomy fistulae produce especially distressing difficulties for the patient. These include problems with maintaining the seal of the ileostomy appliance, the usual problems of a draining fistula, and the problems of the underlying recurrent Crohn's disease. The clinical course, therapy, and long-term progress of these 15 patients are reported here.

Methods

A retrospective chart review of the computerized records of 1010 patients with Crohn's disease admitted to the Mount Sinai Hospital between January 1, 1960 and December 30, 1980 was carried out. The diagnosis of Crohn's disease, and the separation of Crohn's disease from ulcerative colitis had been determined by the criteria outlined in the authors' previous publication. The records of 15 patients with parastomal fistulae were then reviewed in detail.

Detailed information was obtained on the long-term course of the patients from the referring physician or surgeon, and verified by telephone contact by A.D. with each patient.

The presence of recurrent Crohn's disease in the surgically resected specimens was documented pathologically by criteria outlined in the authors' previous publication.[7] Recurrent disease in follow-up patients not operated upon was determined by clinical, radiologic, and endoscopic data. The patient's quality of life at the time of interview was evaluated subjectively, using two simple questions of overall satisfaction. "In general, how much trouble do you have because of illness? Do you feel the surgery helped in the way you thought it would?" Responses to the first question were graded on a scale of 0 to 2 (0 = None, 1 = some, 2 = a great deal). These measures of overall dysfunction correlate well with other more specific areas of psychosocial functioning.[11]

Results

Among the 1010 patients records reviewed, 455 patients had ileocolitis, 172 colitis, and 383 ileitis. Two hundred and fourteen of these patients had an ileostomy: 156 with ileocolitis and 58 with colitis. Fifty-eight per cent of this group were female. Within the entire group of 214 patients, 13 of the ileocolitis patients and two of the colitis patients developed a parastomal fistula. Thirteen of these were female (87%). The higher percentage of women in the fistula group was statistically significant ($X^2 = 4.8$, D:F = 1 $p < 0.03$).

The mean age of onset of inflammatory bowel disease in these 15 patients was 21 years (range 8–62) and the

* Department of Medicine.

Reprint requests: Adrian J. Greenstein, M.D., Mount Sinai Medical Center, Department of Surgery, One Gustave L. Levy Place, New York, New York 10029.

Submitted for publication: July 7, 1982.

0003-4932/83/0200/0179 $01.00 © J. B. Lippincott Company

FIG. 1. Multiple periileostomy fistulae in a 52-year-old female patient with recurrent Crohn's disease two years following total colectomy and ileostomy for Crohn's colitis.

mean age at the development of the fistula was 34 years (range 12–66). These patients had from one to seven operations prior to the development of the periileostomy fistula. Ten of the 25 patients had either an intra-abdominal abscess or intra-abdominal, perianal, or rectovaginal fistula as an indication for the prior surgery. At the most recent operation prior to the onset of fistula, all overt disease had been removed. The clinical symptoms reported at the time of presentation with the periileostomy fistula consisted of ileostomy diarrhea in 13, abdominal pain in ten, fever in two, weight loss in four, and overt bleeding in five. The fistulae were preceded by a well-defined parastomal abscess in eight patients. Four of these patients required incision and drainage lateral to the stoma. The remainder drained spontaneously, usually at the mucocutaneous junction. Symptoms reflected recurrent disease in each case with either partial obstruction or deep ulceration and hemorrhage. Thirteen of the 15 patients had multiple fistulae, the number of external openings ranging from one to eight (Fig. 1).

The depth of the site of origin, the length, and the location of the external orifice of the periileostomy fistula varied considerably. In six patients, the origin was within the peritoneal cavity, in two it was at the musculofascial level, and in six patients, it was either superficial or subcutaneous in origin. In one patient the exact level could not be determined. The length of the tract measured from 5 to 7 cm in those patients who had a fistulogram performed. The external opening of the fistulae varied from immediately adjacent to the stoma to more than five cm away.

Each patient with periileostomy fistula was treated medically initially, with dietary restriction and drugs such as prednisone, sulfasalazine, antimicrobials, or azathioprine. Such therapies proved to be of limited value, and, following failure of the medical therapy, surgery was ultimately required in all cases. All had pathologically documented recurrent Crohn's disease from 4 to 30 cm in length resected. There was a considerable variation in the operative procedures among these patients. In five patients, following spontaneous drainage of pus, the cutaneous swelling and induration was not severe, the skin relatively smooth, and the fistula origin relatively superficial. In these patients the bowel was resected and the original stoma opening used once again for the new ileostomy. In one patient resection was carried out through the original stoma, but in four the transabdominal approach utilizing the previous paramedian incision was necessary because of the length of bowel involved, intra-abdominal adhesions, and associated procedures such as resection of colon. In ten patients the stoma was transposed to the left lower quadrant of the abdomen. This was necessary as the original stoma site and peristomal area was inflamed, indurated, and irregular due to multiple poorly drained abscesses and fistulae. These areas of inflammation were felt to be a potential site of continued sepsis and thus unsuitable for application of an ileostomy appliance. In six of the earlier cases the transabdominal approach was used for transposition of the stoma. In four cases, a stoma-to-stoma transposition without formal laparotomy could be carried out (Fig. 2). In these latter cases mobilization of the diseased bowel was carried out via the original stoma. The bowel was transected and the proximal end closed either using a Parker–Kerr stitch or the G.I.A. stapler. The left lower quadrant trephine opening was then constructed and the bowel brought through the opening after meticulously taking down intra-abdominal adhesions between the two sites. The mesentery was then fixed to the deep fascial layer, and a typical Brooke ileostomy created with eversion of the mucosa and suture to the skin.

Three of the six patients who underwent transabdominal transposition of the stoma to the left lower quadrant developed wound infections that responded to the administration of antibiotics and opening of the wound. The four patients with stoma-to-stoma transposition and the five in whom the original stoma was reused had no early postoperative complication. All patients survived the operative procedure.

Follow-up was obtained on all 15 patients and ranged from one to 18 years with a mean of 5.5 years. Recurrence of ileal disease one to six years following resection and reconstruction of the stoma developed in five female patients. However, only one has been reoperated upon with further resection of 6 inches of diseased ileum; the others are controlled with medical measures. No patient developed recurrent periileostomy abscess or fistula. Only one patient had mechanical ileostomy dysfunction, and no case of intra-abdominal herniation to the left of the stoma was recorded.

All 15 patients felt the surgery helped in the way they expected, and suffered little overall dysfunction. The ten subjects with no further recurrence reported no impairment in their quality of life (grade 0). The five with recurrence noted only some overall dysfunction (grade 1).

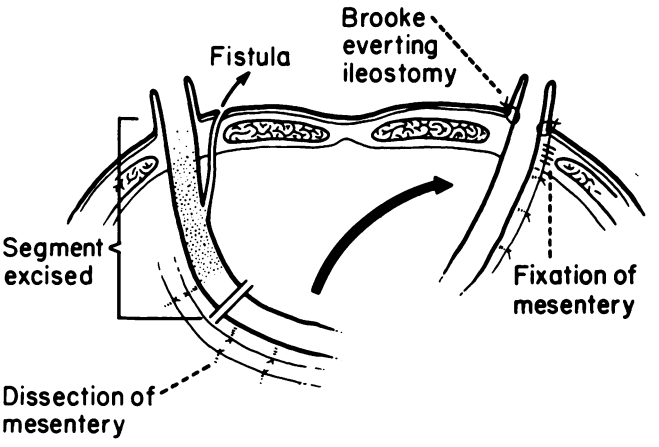

FIG. 2. Diagrammatic representation of stoma-to-stoma transposition of ileostomy from right to left lower quadrants of the abdomen. The original stoma site is enlarged by short fascial incisions on either side, the bowel freed up to a site proximal to the area of disease, and the mesentery freed up from the posterior abdominal wall. Following this, a separate left lower quadrant trephine opening is created; the bowel is transected with a GIA stapler and brought through the new opening; and the mesentery fixed with two to three sutures, avoiding undue tension.

Discussion

Although division of the terminal ileum and construction of an end ileostomy with total diversion of the fecal stream was first carried out in ten patients by John Brown in 1913,[3] it was not until the 1950s that Warren and McKittrick[12] carried out a large series of ileostomies and were able to fully evaluate the procedure and describe its complications. A high proportion of their patients, over 62%, developed ileostomy dysfunction. Brooke in 1952 introduced the eversion technique of suturing mucosa to skin with remarkable improvement in results and reduction in complication rate.[2]

Nevertheless, reoperation for various complications of ileostomy is still carried out, despite all improvements in surgical technique, and modern stomal appliances. Problems include prolapse, retraction, poor placement, necrosis, paraileostomy hernia, dermatitis, hemorrhage, stricture, and periileostomy fistulae.[5,8,12] Earlier reports[5,12] record fistulae comprising 24 to 40% of ileostomy complications; only a small percentage of the fistulae were due to recurrent Crohn's disease. Other reported causes of these ileostomy fistulae include operative injury, serositis, constriction of a tight fascial or cutaneous ring, ill fitting appliances, and self manipulation.[1] The authors' more recent report,[8] as well as the current data indicates all the periileostomy fistulae are due to disease recurrence. The higher incidence of fistulae not related to recurrence in the earlier series,[5,12] was undoubtedly the result of the end ileostomy without eversion of yesteryear. These problems are considerably reduced with precise and accurate surgical technique, as described by Brooke.[2] Since the time-dependent increase in the incidence of recurrent disease is now generally recognized,[4,9,10] the number of patients with periileostomy fistulae will undoubtedly increase in the future.

The number of patients with multiple fistula in this group, 13 of 15, is surprisingly high when compared with other abdominal fistulae. Goligher reported 95 fistulae among 81 patients with Crohn's[6] disease; a much lower incidence of multiplicity. The only other site in which multiple fistulae are exceedingly common is the perianal region. Thus, end stomas, whether ileostomy or anal, are associated with multiple fistulae, probably due to extension of the inflammation directly into the subcutaneous tissues alongside the bowel. A history of abdominal abscesses or fistulae prior to the construction of the ileostomy, as in ten of the 15 patients, appears to predict the patient who is quite likely to develop periileostomy fistulae. Females are also more likely to develop periileostomy fistulae. The preponderance of female patients with ileostomy fistula (87%) contrasts sharply with the total group of 214 patients with ileostomy ($p < 0.03$).

A surgical approach to the therapy of periileostomy fistulae was necessary in each case and was very successful. All patients survived, and only three each with transabdominal transposition of the stoma developed

wound infections. The more superficial or subcutaneous fistulas will drain relatively easily to the surface without severe local sepsis, thus allowing for reconstruction of the stoma at the same site. The deeper musculofascial or intra-abdominal fistulous tracts will produce subcutaneous or deep fascial abscesses that will either drain spontaneously or require incision and drainage of the abscess as a primary or concommitant procedure. In the latter type of disease, transposition of the stoma to the left quadrant is mandatory to allow for adequate drainage of the peristomal area, and healing of the wounds. In some patients complete resolution of the induration and inflammation has taken as long as six months.

Although Block and Giuliano[1] have found left-sided stomas to be notoriously troublesome because of inadequate length and inability to close the lateral space, the authors have had surprisingly little difficulty with these left-sided stomas. Only one patient has had intermittent dysfunction, and no case of herniation is recorded among these 15 patients, probably because the lateral gutter is relatively large with the mesentery originating anatomically from the right side of the abdomen.

It can, however, be technically difficult to obtain adequate bowel length to construct the left-sided ileostomy especially for the stoma-to-stoma transperitoneal transposition. In such cases, particularly with deep adhesions, deep fistulae, or long lengths of recurrent disease, the transperitoneal approach via formal laparotomy should be used. However, when the transposition can be carried out without reopening the main incision it is the authors' impression that the postoperative pain is reduced considerably and the postoperative recovery of both bowel function and general activity accelerated. Furthermore, wound infection in this series was only encountered when the laparotomy wound was reopened. Successful transperitoneal relocation of the stoma without formal laparotomy was previously described by Turnbull and Weakley in 1967.[14] In a subsequent publication, prestomal ileitis was the indication for this procedure in three of their cases.

Medical therapies proved to be of limited value, and all patients with periileostomy fistulae came to resection within one month to two years. Surgery was effective not only in control of the immediate problem but also provided a long-term satisfactory quality of life. Even those with later disease recurrence were satisfied with the surgical results and reported only some overall impairment in their physiosocial functioning. This gratifying success of surgical therapy is in accordance with the authors' previous data on the therapy of Crohn's disease.[11]

Acknowledgments

The authors wish to thank Jean DiCarlo for her excellent secretarial assistance in the preparation of this manuscript. Thanks also to Devaprasad Reuben, R.R.A., for assisting in gathering data, and the physicians at Mount Sinai for allowing us to use their private cases.

References

1. Block GE, Giuliano A. Complications of the surgical treatment of ulcerative colitis and Crohn's disease. In: Kirsner JB, Shorter RG, eds. Inflammatory Bowel Disease. 2nd ed. Philadelphia: Lea & Febiger, 1980; 577–604.
2. Brooke BN. The management of an ileostomy including its complications. Lancet 1951; 1:102–104.
3. Brown JY. Value of complete physiological rest of large bowel in treatment of certain ulcerations and obstructive lesions of this organ. Surg Gynecol Obstet 1913; 16:610–613.
4. Cooke WT, Mallas E, Prior P, Allan RN. Crohn's disease: course, treatment and long-term prognosis. Q J Med 1980; 195:363–384.
5. Goldblatt MS, Corman ML, Haggitt RC, et al. Ileostomy complications requiring revision: Lahey clinic experience, 1964–1973. Dis Colon Rectum 1977; 20:209–214.
6. Goligher JC. Other complications. abdominal fistulas. In: Surgery of the Anus and Rectum and Colon. 4th ed. London: Bailliere Tindall, 1980; 834.
7. Greenstein AJ, Geller SA, Dreiling DA, Aufses AH Jr. Crohn's disease of the colon IV. Clinical features of Crohn's (ileo) colitis. Am J Gastroenterol 1975; 64:191–199.
8. Greenstein AJ, Meyers S, Sher L, Heimann T, Aufses AH Jr. Surgery and its sequelae in Crohn's colitis and ileocolitis. Arch Surg 1981; 116:285–288.
9. Greenstein AJ, Sachar DB, Pasternack BS, Janowitz HD. Reoperation and recurrence in Crohn's colitis and ileocolitis. Crude and cumulative rates. New Engl J Med 1975; 293:685–690.
10. Lock MR, Farmer RG, Fazio et al. Recurrence and reoperation for Crohn's disease. The role of disease location in prognosis. N Engl J Med 1981; 304:1586–1588.
11. Meyers S, Walfish JS, Sachar DB, et al. Quality of life after surgery for Crohn's disease: a psychosocial study. Gastroenterology 1980; 78:1–6.
12. Roy PH, Sauer WG, Beahrs OH, Farrow GM. Experience with ileostomies. Evaluation of long-term rehabilitation in 497 patients. Am J Surg 1970; 119:77–86.
13. Warren R, McKittrick LS. Ileostomy for ulcerative colitis. Surg Gynecol Obstet 1951; 93:555–567.
14. Turnbull RB Jr, Weakley FL. Atlas of Intestinal Stomas. St. Louis: The CV Mosby Co, 1967.
15. Taylor RL, Rombeau JL, Turnbull RB Jr. Transperitoneal relocation of the ileal stoma without formal laparotomy. Surg Gynecol Obstet 1978; 146:953–958.