NIH Public Access
Author Manuscript
AJNR Am J Neuroradiol. Author manuscript; available in PMC 2006 January 25.

Published in final edited form as:
AJNR Am J Neuroradiol. 2003 January ; 24(1): 42–44.

Language processing during natural sleep in a 6-year-old boy as assessed by functional MRI

Marko Wilke[1,2], **Scott K. Holland**[1], and **William S. Ball Jr.**[1]

[1]*Imaging Research Center and* [2]*Department of Psychiatry, Cincinnati Children's*

Summary

Functional magnetic resonance imaging was performed on a 6-year-old child prior to neuro surgical intervention. A stories-listening task was used, revealing a left-lateralized language network. The task was repeated during the same session when the child had fallen asleep and surprisingly yielded strong activation in similar language areas. Our findings suggest that language processing does occur during natural sleep even in young children, potentially allowing for an assessment of language functions even in non-cooperative children.

Introduction

Although humans spend roughly a third of their life sleeping, surprisingly little is known about the brain's physiology during this state and indeed about the very purpose of sleep itself. While the long-held belief that the brain simply “shuts down” during sleep has been revised in recent years, it still remains unclear as to what exact purpose sleep serves and to what extent brain processes during sleep differ from those in the awake state. The recent application of functional imaging methods has renewed the research interest in this field [1].

Here, we report on a young boy who was seen for a functional MRI for presurgical planning. He fell asleep during the scan, allowing for the same task to be conducted awake and while he was asleep. The case shall be described in detail.

Case Report

This 6-year-old, right-handed boy was seen by a neurologist for complex-partial seizures. MR imaging was performed and demonstrated an enhancing left mesial temporal lobe lesion. As part of the presurgical evaluation, the child was scheduled for a functional MR-imaging study. This was aimed at evaluating language functions since an interference of language related areas with the neurosurgical approach was feared. IRB-approval and informed consent were obtained. Due to the age of the child, a passive listening task (stories vs. tones) was done. While the child was able to complete the functional task, motion of the hands and arms during the study impaired the quality of the scan. In order to allow the child to settle down, an anatomical scan was acquired. When the boy was approached in order to explain the next task, it was found that he had fallen asleep. It was decided to repeat the study, and he was still asleep when he was removed from the scanner bore several minutes later.

The scan was performed on a Bruker Bio spec 30/60 3 Tesla MRI scanner equipped with a head gradient insert (Bruker SK330). Functional images were acquired using a GE-T2*-

Corresponding author: Marko Wilke, Imaging Research Center, Cincinnati Children's Hospital Medical Center (ML 5031), 3333 Burnet Avenue, Cincinnati, OH 45229, Phone: (513) 636 – 0142, Fax: (513) 636 – 3754, e-mail: wilke@athena.chmcc.org.

NIH-PA Author Manuscript
NIH-PA Author Manuscript
NIH-PA Author Manuscript

NIH-PA Author Manuscript

NIH-PA Author Manuscript

NIH-PA Author Manuscript

weighted EPI-sequence (TR/TE = 3000/38 ms, 4 × 4 mm “in-plane”, slice thickness = 5 mm), yielding 24 slices over 110 time points during the alternating 30-s periods of control and activation for a total imaging time of 5 min, 30 s. A Tl-weighted, 3D whole-brain scan was also acquired (TR/TE = 15/4.3 ms, 1 × 1.5 × 2.25 mm). Postprocessing was done in CCHIPS and included the removal of Nyquist ghosts and geometrical distortions by use of a multi-echo reference scan [1] and motion correction using C-routines. Images were analyzed using a cross-correlation technique.

Discussion

We report on the case of a 6-year-old boy who underwent clinical functional MRI for presurgical planning due to a temporal-lobe lesion (Figure 1). After completing a “listening to stories-task”, the child fell asleep during the acquisition of the anatomical images. The task was then repeated and yielded strong activation in language areas, indicating language processing during natural sleep. The detected pattern of activation with a left-dominant network is slightly unusual, but in line with the high degree of variability in this age group (Figure 2).

Both scans reveal a remarkably similar pattern of neuronal activation, indicating that the receptive processing of heard speech does not seem to differ fundamentally between the awake and sleeping state in this child. Similar results were seen in a combined EEG/fMRI-study in adults, where, as in our subject, only the language component of a passive listening task activated language-related brain areas [3]. This case is also especially interesting since the child did the same (passive) task awake and during natural sleep, ruling out effects of sedative agents. Although fMRI has been conducted in young children under sedation [4], sedative agents have been shown to have a significant effect on the BOLD-response [5], limiting the conclusions to be drawn from such studies [6]. However, despite this advantage, comparability of the two studies conducted in this child is still hampered by the presence of involuntary motion in the first scan that was not present in the second scan.

Since this was a by chance-observation, no EEG-recordings were available to assess sleep stages. However, the child was documented to be asleep directly before and after the scan, and actually did not wake up until he was taken out of the scanner, several minutes after this study. Interestingly, when analyzing the pixel intensity timecourses of receptive and expressive language areas (traditionally known as Wernicke's and Broca's area [7]), they seem to differ significantly, with only the receptive language areas displaying a constant and robust correlation with the reference function (Figure 3). Activation in expressive areas shows a much more fluctuating course and only becomes robust in the second half of the 5-½ minute scan, while receptive brain areas show almost no fluctuation. This effect can be speculated to reflect different sleep stages, which is in line with a recent observation of a significant effect of the sleep stage on the magnitude of the BOLD-response [8]. In addition to a global influence, our data moreover suggests a differential affection of these areas by different sleep stages, which could be due to either anatomical or functional differences. However, continuous EEG-recordings would have been necessary to verify this effect.

We think our observation has two major implications: first, it demonstrates that language processing during sleep is not an exclusive function of the mature brain but can already be detected in young children, where language functions are still developing [9]. Our case also suggests differing effects of sleep stages on distinct brain areas. Second, by showing that language processing does occur during natural sleep, it indicates that this central higher brain function is amenable to functional imaging studies even in very young children. If natural sleep can be achieved, the confounding effects of sedative agents can thus be avoided.

NIH-PA Author Manuscript

NIH-PA Author Manuscript

NIH-PA Author Manuscript

Acknowledgements

We would like to thank John S. Myseros, MD, and Douglas F. Rose, MD, for referring their patient.

References

1. Stickgold R. Watching the sleeping brain watch us - sensory processing during sleep. . Trends Neurosci 2001;24:307–309. [PubMed: 11356489]
2. Schmithorst VJ, Dardzinski BJ, Holland SK. Simultaneous correction of ghost and geometric distortion artifacts in EPI using a multiecho reference scan. IEEE Trans Med Imaging 2001;20:535–539. [PubMed: 11437113]
3. Portas CM, Krakow K, Allen P, Josephs O, Armony JL, Frith CD. Auditory processing across the sleep-wake cycle: simultaneous EEG and fMRI monitoring in humans. Neuron 2000;28:991–999. [PubMed: 11163282]
4. Altman NR, Bernal B. Brain activation in sedated children: auditory and visual functional MR imaging. Radiology 2001;221:56–63. [PubMed: 11568321]
5. Martin E, Thiel T, Joeri P, et al. Effect of pentobarbital on visual processing in man. Hum Brain Mapp 2000;10:132–139. [PubMed: 10912592]
6. Miki A, Liu GT, Fletcher DW, Hunter JV, Haselgrove JC. Ocular dominance in anterior visual cortex in a child demonstrated by the use of fMRI. Pediatr Neurol 2001;24:232–234. [PubMed: 11301228]
7. Binder JR, Frost JA, Hammeke TA, Cox RW, Rao SM, Prieto T. Human brain language areas identified by functional magnetic resonance imaging. J Neurosci 1997;17:353–362. [PubMed: 8987760]
8. Czisch M, Wetter TC, Kaufmann C, Pollmacher T, Holsboer F, Auer DP. Altered Processing of Acoustic Stimuli during Sleep: Reduced Auditory Activation and Visual Deactivation Detected by a Combined fMRI/EEG Study. Neuroimage 2002;16:251–258. [PubMed: 11969332]
9. Holland SK, Plante E, Weber Byars A, Strawsburg RH, Schmithorst VJ, Ball WS Jr. Normal fMRI Brain Activation Patterns in Children Performing a Verb Generation Task. Neuroimage 2001;14:837–843. [PubMed: 11554802]

NIH-PA Author Manuscript

NIH-PA Author Manuscript

NIH-PA Author Manuscript

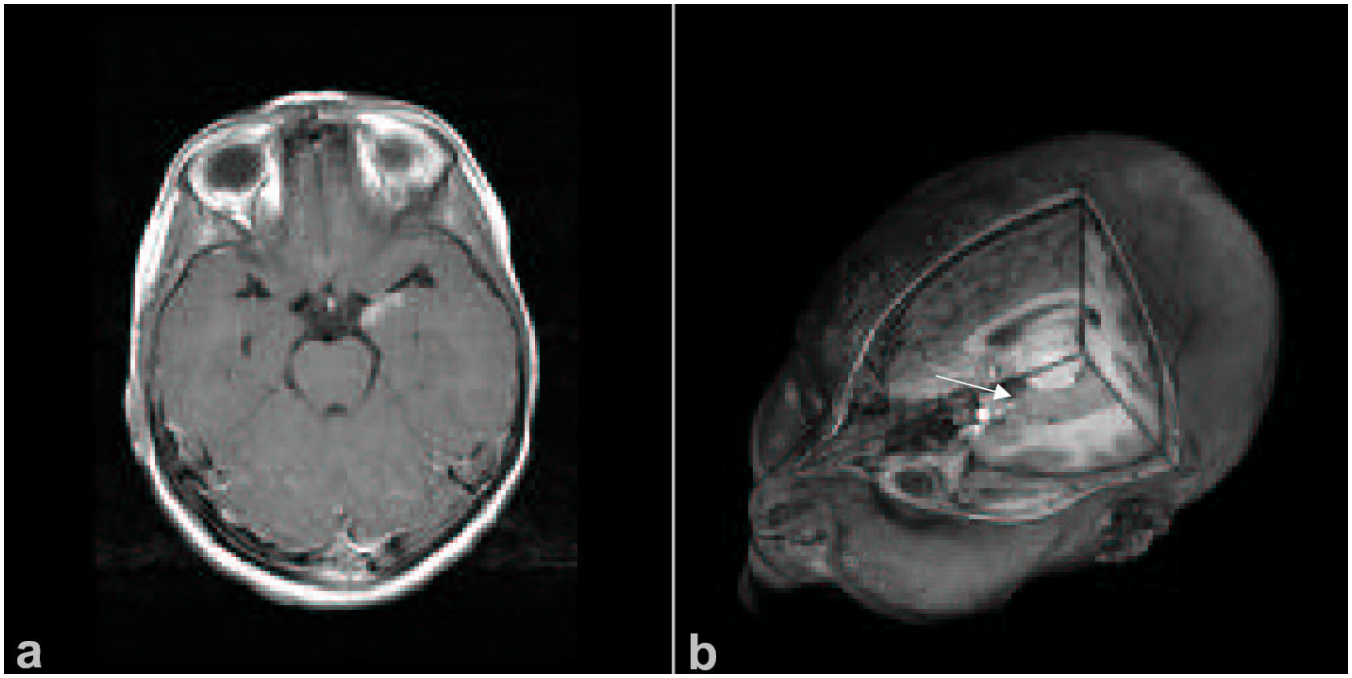

Figure 1.
a. post-contrast Tl-weighted imaging study, demonstrating the enhancing lesion in the left temporal lobe; b. SD-reconstruction of the Tl-weighted whole-brain dataset, demonstrating the location of the lesion (arrow).

NIH-PA Author Manuscript

NIH-PA Author Manuscript

NIH-PA Author Manuscript

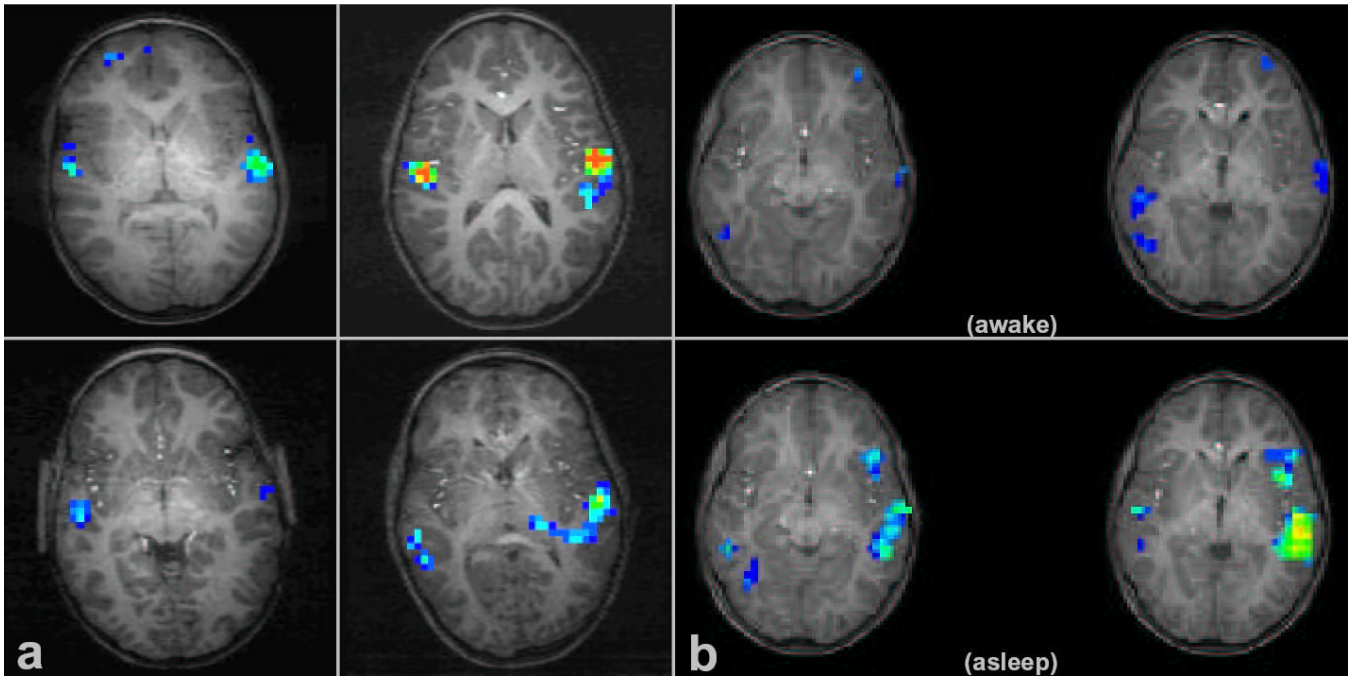

Figure 2.
a. reference data from four healthy 6-year-old boys while listening to stories (active) vs. listening to tones (control): note variability of activation patterns; b. imaging data from our patient performing the same task during the awake (top) and the sleeping study (bottom). Cross-correlation, r = 0.375, cluster size = 5.

NIH-PA Author Manuscript

NIH-PA Author Manuscript

NIH-PA Author Manuscript

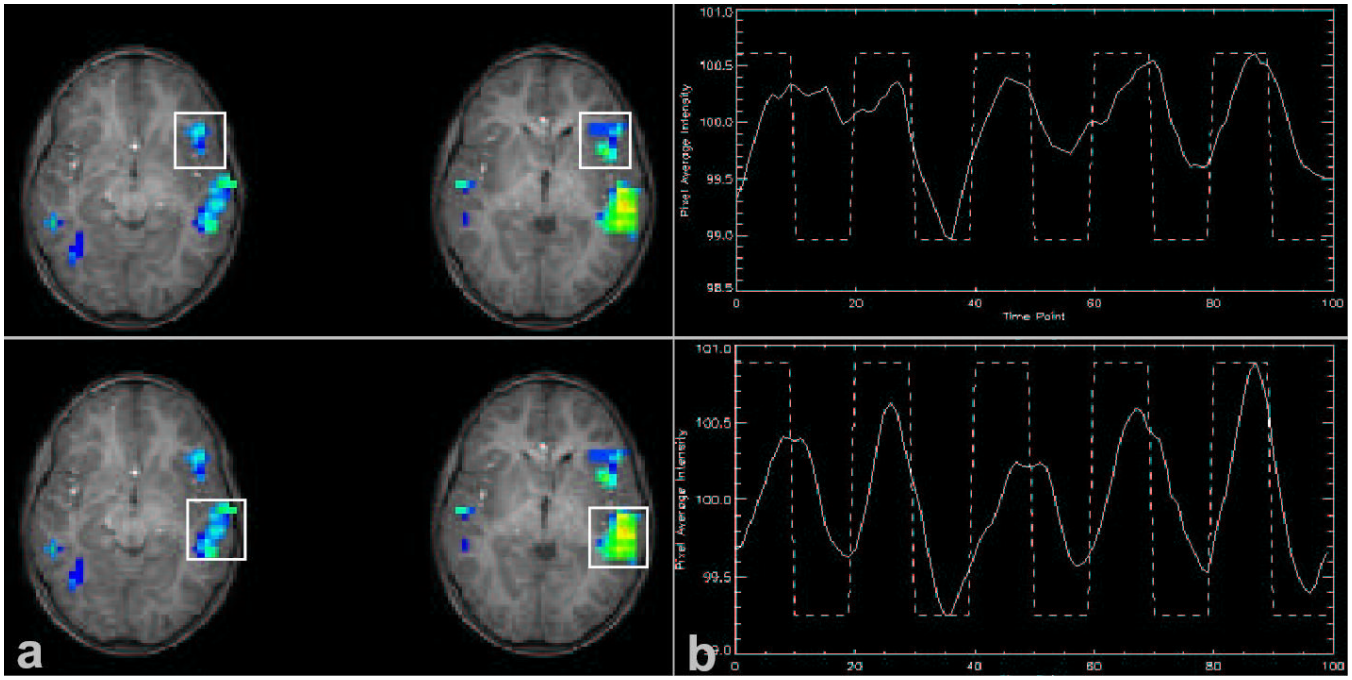

Figure 3.

a. activation pattern during the sleeping study: delineation of activation in expressive (top) and receptive language areas (bottom); b. pixel intensity timecourses in correlation to the reference function: note difference in response between expressive (top) and receptive areas (bottom) during the first 3 blocks.