ON THE TOPOGRAPHICAL ANATOMY OF ABDOMINAL VISCERA IN MAN, ESPECIALLY THE GASTRO-INTESTINAL CANAL.[1] PART I.

By CHRISTOPHER ADDISON, M.D., B.S. (Lond.), F.R.C.S., *Professor of Anatomy, University College, Sheffield.* (PLATES XLIII.–XLIV.)

AT the beginning of this paper I wish to acknowledge my great indebtedness to those who have so materially and so generously helped me,—particularly to Dr Claye Shaw and the Medical Officers of the London County Asylum, Banstead; and to Mr Waters, the Master, and the Medical Officers at the Fir Vale Union, Sheffield. At Banstead, the mortuary was placed at my disposal, and almost unlimited time and opportunity were afforded me. I cannot thank Dr Claye Shaw too much. To Drs Jones and Bond I also owe special thanks. The same facilities were afforded me at Fir Vale; and, in addition to Mr Waters, I must thank Drs Sorley and Waddy for their kind help. My thanks are also due to Drs Garrod and Calvert at St Bartholomew's for the work I was able to do there, and to Mr C. W. Smith, my Prosector, for drawing Figs. 3A and 3B, and for help with the Tables.

PURPOSE OF INQUIRY.

With the advance of medical and surgical science, especially with regard to the operations of surgery on the abdomen, the topography of the abdominal viscera becomes of increasing importance.

The method of determining the position of the underlying parts should be as simple as possible, it should be convenient of application, and, withal, having regard to the varying conditions of the abdominal organs, as accurate as can be. One seldom meets with an abdomen which can be called normal in all respects.

Very many accurate and extended measurements of various

[1] Read before the Royal Society, December 8, 1898. Communicated by Professor Alexander Macalister, F.R.S.

organs have been published at different times, but these, though exact in themselves, do not thereby enable us to form an adequate anticipation of the shape or position of particular organs, if they themselves, or adjoining organs, abdominal or thoracic, are enlarged or diminished in size, or altered in position, through any cause whatever. Notwithstanding that the enlargements and alterations in any one organ may in some cases be quite obvious on superficial examination, this does not carry with it the information as to what deviation from the usual position we may expect in the neighbouring parts. From the point of view of practice, abdominal organs must be considered collectively as well as singly. Moreover, the present methods of abdominal topography, in regard to surface-points, leave something to be desired. This is sufficiently evidenced by the diversity of the methods employed amongst anatomical authorities.

In undertaking this research, therefore, it seemed to promise the greatest utility if certain regular surface-points were taken which would be quite independent in themselves of such movable parts as the costal cartilages or the umbilicus, and which, whilst retaining, as far as may be useful, those parts as adjuncts, would be unvarying, and easily determined in any particular body. Having obtained these surface-points, the various abdominal viscera were measured, and their position in regard to the surface-points determined. Further, taking account of the varying mutual relations of the viscera, as far as the series allowed, indications were sought for of the alterations in position or shape which are to be expected under different conditions.

It was recognised that it was important that this should be done, whilst retaining the use of those terms of abdominal topography which have become established by usage, and with the least possible disturbance of their present significance.

Briefly, therefore, the purpose of this inquiry has been to carefully map out the abdominal viscera in relation to well-defined uniformly-proportioned surface lines, and to ascertain, as far as possible, the modes in which the abdominal viscera alter their position, or are displaced, when they themselves, or the viscera in their neighbourhood, are enlarged or diminished in size, or pressed upon by neighbouring parts.

PROF. ADDISON ON ABDOMINAL VISCERA IN MAN.

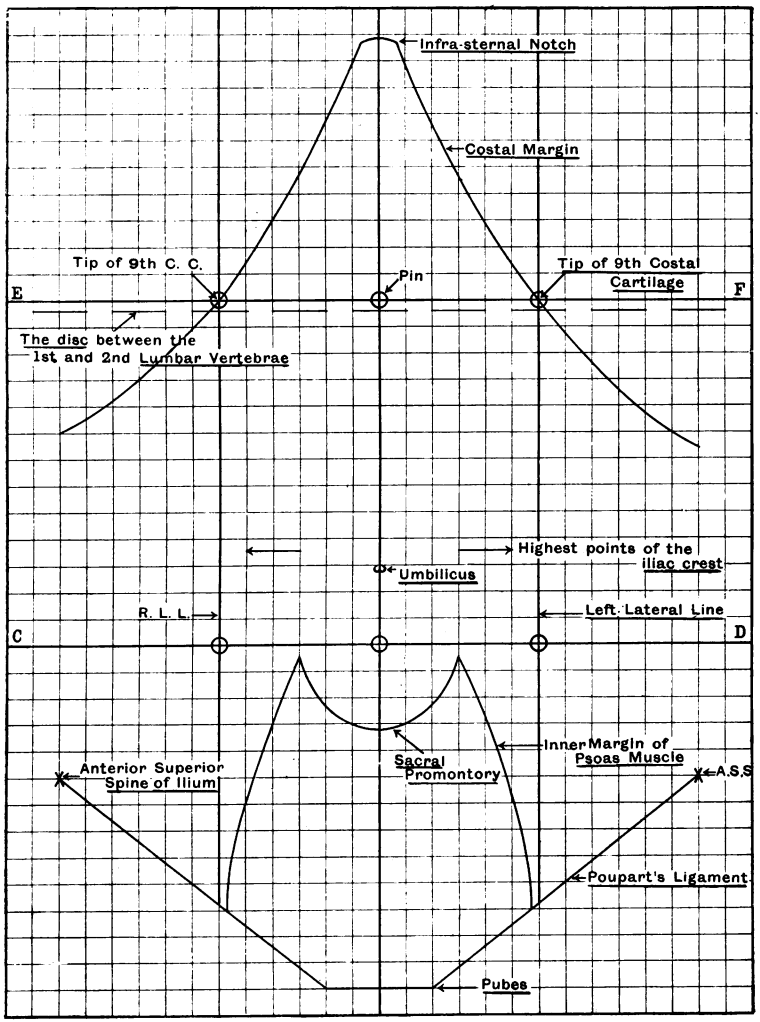

FIG. 1.—Diagram showing the average position of the landmarks whereby the abdominal regions are limited.

Delimitation of the Regions of the Abdomen.

In all cases the subject is laid flat on the back on a table, the legs extended and in a straight line with the trunk, the arms drawn evenly down by the side, and the head resting extended on the table.

The abdomen is divided *vertically* by three lines—a median line and two lateral lines.

The lateral lines are drawn vertically upwards, one on each side, through a point half way between the anterior superior iliac spine and the middle line, in a line drawn transversely across between the two anterior superior iliac spines.

The body is divided *transversely* by lines drawn across at points a quarter, a half, and three-quarters of the way along a line drawn from the upper border of the pubes to the supra-sternal notch. The uppermost transverse line we are not much concerned with. It passes across the thorax as a rule, 3·2 centimetres above the lower border of the body of the sternum. In Figure 1, and in the printed tables, it is spoken of as the line X.Y.

The *upper transverse abdominal line*, half way from the pubes to the supra-sternal notch, is spoken of as *the line E.F.* The *lower transverse abdominal line*, a quarter of the way from the pubes to the supra-sternal notch, is spoken of as *the line C.D.*

With regard to the vertical lines, the median line is most useful, both for the equal division of the abdomen and for the purposes of measurement, both vertically and transversely. The lateral lines correspond with those generally in use at present. The method used for determining them is more accurate than by taking the mid-point of Poupart's ligament, for this is a point not easy to determine exactly. Lines drawn obliquely upwards, such as those used by Macalister (1), from the spine of the pubes to the 8th costal cartilage, seem objectionable, because of the variations of the 8th costal cartilage, and because the lines divide the abdomen unequally.

With regard to the lines generally used to divide the abdomen transversely, they are open to the great objection that the distance between them varies very much. In the case of

the upper one, there is much difference between various writers as to the points between which it is drawn. If the line is drawn across between the tips of any particular costal cartilages—points which in large numbers of cases are very difficult, if not impossible, to determine—or between the lower border of the 10th costal cartilages, as Cunningham (2) advises, in many cases it does not pass horizontally. Moreover, the distance between the two transverse lines is often much less than the distances above or below them, to the sternum and pubes respectively; and the wide variations in the level of the upper transverse line are too considerable to make it a satisfactory line to use in any research on the topography of the viscera. In Cunningham's paper, he gives the average distance between the transverse lines as 2·7 inches, the average depth of the costal zone, above the upper line, as 6 inches; of the hypogastric zone, below the lower line, as 5 inches. Considering the very important structures in the costal zone, 6 inches is too great a length to allow without a surface line. A line is desirable in this region, at a somewhat higher level, if one can be found, which has a fairly constant significance.

Concerning the lower transverse line, without discussing the various positions in which it has been placed, it may be said the line C.D. practically corresponds with Cunningham's intertubercular line, drawn across between the two tubercles situated on the outer aspects of the iliac crests.

My purpose, however, in selecting the transverse lines I have described, was simply the obtaining of easily-found, equidistant points for the purpose of measurement; and I was not prepared for the regularity of position in regard to the vertebræ and other structures which, especially, the upper transverse line E.E. has been found to possess. It corresponds almost accurately to the disc between the 1st and 2nd lumbar vertebræ, and cuts the junction of the 8th and 9th costal cartilages at the tip of the 9th.

The lower line C.D. passes across on an average 5 cm. above the anterior superior iliac spine, and 3·5 cm. below the highest point of the iliac crest.

The consequence of this division of the abdomen, as will be seen on reference to fig. 1, is that there are right and left

epigastric, umbilical, and hypogastric regions, with right and left iliac and lumbar regions, and with the hypochondriac parts of the abdominal cavity, not, as a rule, extending from under cover of the costal cartilages. This limitation of the hypochondriac region, I think, will be seen not to possess any disadvantage, whereas the increase of the lumbar region is to be desired.

Method of Examination.[1]

The study of the relative anatomy of the abdominal viscera has been materially advanced of late years by methods of hardening the body by fluid injections, and, subsequently, dividing it into a series of sections, from which accurate models of the viscera in the hardened state have been built up. In various manners these hardening methods have been employed by His (3), Cunningham (4), Symington (5), Birmingham (6), Weinburg (7), Sernoff (8), and others.

For the obtaining of a series of accurate observations on the mutual as well as on the individual relations of the viscera, the hardening method gives perhaps the most reliable results; yet it is so very difficult of application to a large number of cases that it should be, if possible, supplemented by some other method, if such can be found to be trustworthy. The first two bodies of this series were hardened before examination by the injection on the 3rd, 4th, 5th, and 7th days after death of two quarts of 5 per cent. solution of formic aldehyde. It was cold weather during the whole time that the bodies lay on the table, and there was frost each night. The viscera and the muscles were quite firm, and retained exactly the impressions produced on them by surrounding parts. The abdomens of six other bodies, similarly hardened, have been used,—three for dissection, and three for the examination of special points and for the making of preparations.

In all cases the time after death when the examination was made was noted; and the condition of the nutrition of the body in such general terms as 'emaciated,' 'fair,' 'good' or 'fat,' and any special pathological or other condition, or obvious displacement

[1] In all cases where convenient, figures are used instead of written numbers.

or distension of organs was described. Furthermore, the state of the various viscera, whether soft or firm, was specifically stated.

The distance from the pubes to the supra-sternal notch is measured by drawing the tape tightly between these points. If the abdomen is convex, the half-way point is marked directly; if concave, the spot directly beneath the mid-point of the tape is taken; and at this point, after a small skin incision, a long steel pin is driven through the abdomen. This marks the level of the upper transverse abdominal line (E.F.).

In a similar way, beneath the quarter-way point the level of the lower transverse abdominal line (C.D.) is determined, and a second pin is driven through the abdomen at this point.

The position of the lateral lines, half way from the anterior superior iliac spines to the middle lines, is then determined, and four more pins are then driven through the abdomen, one in each lateral line in the planes of C.D. and E.F. If the abdomen between the anterior superior iliac spines is convex forwards beyond them, or is unequally distended, as in the case of a distended cæcum, the measurement between them is taken on a projection forwards, and is confirmed on opening the abdomen.

The distances vertically upwards from Poupart's ligament along the lateral lines, from the anterior superior iliac spines, and from the highest point of the iliac crests to the costal arch or ribs, are then measured, and the parts met with, as felt through the skin, are noted. On opening the abdomen, these points are confirmed or corrected, and a drawing of the costal arch is made. For the drawing, the distances of the tips of the different cartilages from the infra-sternal notch are measured along the costal margin, the transverse width of the arch in the plane of E.F., between the tips of the 10th costal cartilages, or other suitable points according to the arch, are also taken, and the differences in level, if any, of the points cut by the lateral lines as they impinge on the arch and the plane of E.F., and the difference in width, if any, at these levels.

The distances above or below the transverse line C.D. of the anterior superior iliac spines, the highest points of the iliac crests and the umbilicus, and the infra-sternal notch above E.F., and below the upper transverse line X.Y., are measured. The

greatest transverse diameter of the body in the planes C.D. and E.F., and the cartilages, intercostal spaces, and ribs, cut by prolonging the lines E.F. and X.Y. transversely, are noted. At the conclusion of the examination the relations are obtained of the upper median pin to the disc between the 1st and 2nd lumbar vertebræ, and of the lower pin to the aortic bifurcation, to the disc between the 4th and 5th lumbar vertebræ, and to the pelvic brim in the middle line,—the pelvic brim in the middle line being variously the upper border of the 1st sacral vertebra, the disc between the 5th lumbar and the 1st sacral, or the lower border of the 5th lumbar vertebra, according to the tilt of the spine. Finally, the brim of the pelvis, as measured between the inner margins of the psoas muscles, is fully drawn in its relation to C.D. and Poupart's ligament.

In this way a complete map of the superficial and deep points in their relations to the lines of division is obtained, so that the measurement of the viscera projected on to the surface in relation to the lines I have adopted can, if these be not found convenient, be transferred to any other system of surface divisions whatever.

The steel pins used to transfix the abdomen are 14 inches in length, with a long sharpened point and an expanded head, and as thin as is consistent with absolute rigidity. They were driven in with the utmost care at the exact distances from one another, and at right angles to the table. They were made so long in order that, as they project for some inches from the front abdominal wall, the slightest obliquity might be obvious. For it is clear that even a small degree of obliquity in the case of a thick abdomen would lead to the point of the pin entering the back wall a centimetre or more higher or lower, as the case might be. I can only say that the pins were always driven in with the utmost care; and I think the degrees of error are so small that, in the whole series, they will fairly correct one another.

The median and lower lateral pins fasten themselves in the vertebræ and iliac bones respectively.

The upper lateral pins, which passed free of, at the margin of, or through the costal cartilages, as the case may be, were driven through into the table in the cases in which it was wood. For

the rest, in those cases in which they did not fasten themselves, by transfixing the costal cartilages, after the stomach and liver had been removed, it was sometimes necessary to fix the tops of the pins; but as the pins were in no cases removed, and the measurements of the viscera on the posterior abdominal wall were taken immediately from the pin at the point of its transfixion of them, the accuracy of the measurements was not interfered with.

Printed tables were used for recording the surface measurements, and large sheets, ruled after the manner of the surface lines, were employed for making the rough diagrams of the viscera, and for recording in centimetres at various points along the diagrams the distances of the parts from the pins. The measurements in the abdomen were taken with a stiff steel measure, graduated in centimetres.

The abdomen was opened by a median incision, and transverse incisions in the planes of C.D. and E.F. to clear the pins. The lower transverse incisions were sometimes prolonged even further outward than the pins. A drawing was made of the costal arch when it was cleared. The great omentum was measured and its free border represented by a line, and the distances above, below, to the right or left of the different pins marked in figures. The omentum was then cut away, and as far as possible the cæcum, the transverse colon, the lower border of the stomach, and the lower border of the liver were measured and drawn, and the general course (but not representing accurate measurements or figures) of the superficial convolutions of the small intestines was indicated by a line. The lower border of the liver was then, if necessary, cut away or lifted up to permit of measurement of the pylorus, the lesser curvature, and the cardiac orifice of the stomach. The upper border of the liver, to the left, and in the middle and lateral lines, was taken by passing the rod along its anterior surface to its upper border. Although in general easy, the measurements of the upper border of the liver and of the summit of the stomach were sometimes attended with considerable difficulty, as the organs were tightly jammed up beneath the ribs. In such cases, either the anterior abdominal wall was transfixed higher up until the proper level had been obtained, or some of the ribs and cartilages in front were cut away and lifted up as much as was necessary. The right border

of the liver, the gall-bladder, the hepatic flexure of the colon, the highest point of the splenic flexure of the colon, and the greater curvature of the stomach at the left were then measured in the order they presented, and the splenic flexure of the colon or the descending colon, as the case might be, down to the plane of E.F.; overlying parts being lifted up or cut away as was necessary. At this stage the small intestines were cut away piecemeal and the length of the mesentery measured, and diagrams and measurements made of the ileo-cæcal region, of the ascending, descending, and sigmoid colons, of the commencement of the rectum, and of the brim of the pelvis. The stomach and liver were then cut away. The previous measurements, if any, of the duodenum were completed and confirmed, the pancreas, kidneys, spleen, supra-renal bodies, the vena cava, and the parts of the back abdominal were measured and filled in.

The foregoing order of examination was necessarily subject to variations in different abdomens. No part was disturbed before measurement, and any obstructing part was cut away piecemeal to expose it. Often, of course, it was very laborious and difficult, but the greatest care was taken; and I am convinced that, except where otherwise so stated in the tables, the measurements are substantially accurate.

The line of the attachment of the mesentery and of the peritoneum along the ascending and descending colons, and of the lower layer of the transverse meso-colon, was marked and measured, and any peritoneal bands or pouches drawn. The time occupied in making the post-mortem was, as a rule, four hours. Two or three of the large ruled sheets were used for marking in the viscera and recording the distances at various points from the pins; also sundry accessory sheets were used for diagrams of special parts, such as the ileo-cæcal region.

Subsequently, the diagrams were worked out on the life-size scale on sheets ruled in centimetre squares (see figs. 3A and 3B). At the risk of some complexity, for the sake of having in one place a representation of the mutual relations of the viscera, I outlined all the organs of each case on one sheet in various colours. The individual organs from the whole series are presented collectively on the scale of one-ninth in the figures embodied in this paper.

In all cases, except where specially drawn or stated, on the ground both of convenience and utility, the forward projection of the viscera is the only one represented. It is difficult, if not impossible, in a considerable proportion of persons, to satisfactorily map out the various bony points on the back.

This paper is written on the basis of the complete measurement in the manner described of 40 subjects—full details of each case being presented in the Tables in the Appendix.

The cases are consecutive, and not selected at all, being taken only according to time and opportunity.

Case 8, however, is an exception. It is really the twenty-first. The case originally numbered 8 had been done hurriedly, and after the first twenty were completed it was decided to omit it altogether from the series, as it was found that many measurements and notes had been omitted. The next coming case, No. 21, was therefore substituted for it. In addition to these 40 cases, various other illustrative preparations were made.

The main subject of inquiry has been the topography of the gastro-intestinal canal, but it was quite impossible adequately to consider it without including the other abdominal viscera, except the pelvic.

Although 40 cases are presented in this paper and averages are drawn from them, it is fully recognised that, in the case of many of the averages, much more extended observations are necessary.

TABLE I.

PROF. ADDISON ON ABDOMINAL VISCERA IN MAN.

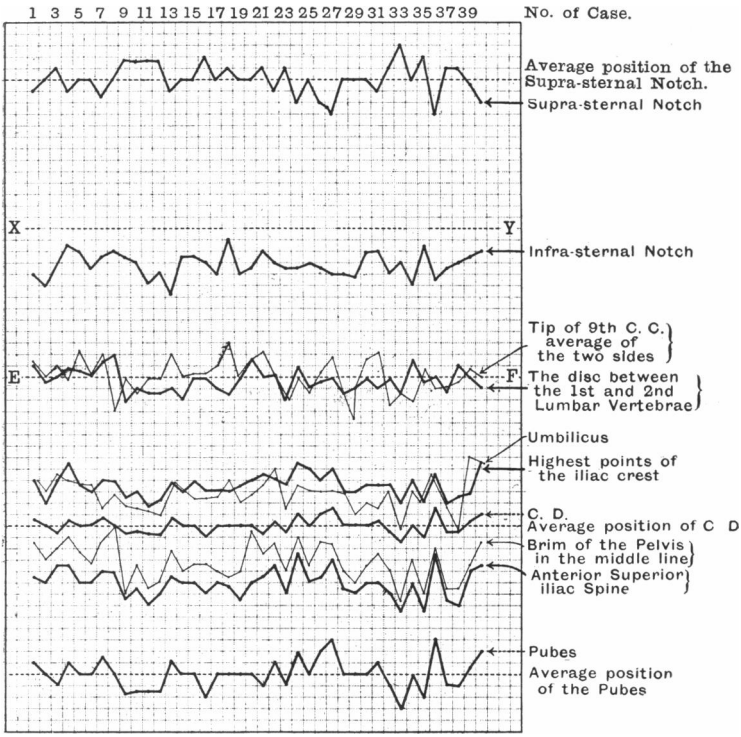

FIG. 2.—The curves show the variations in position of different superficial and deep points in regard to the upper (X, Y), middle (E, F), and lower (C, D) transverse lines. Scale—Each square represents 1 square centimetre.

Table I.

Table of Averages of Surface Measurements.

Age		45·6 years.
Height	5 ft. 3¾ inches,	about 160 cm.
Distance from the pubes to the suprasternal notch,		52·0 cm.
,, between the transverse lines		13·0 ,,
,, of the infra-sternal notch above E.F.,		9·8 ,,
,, of the infra-sternal notch below X.Y.,		3·2 ,,
,, of the sacral promontory below C.D.,		3·2 ,,
,, of the anterior superior iliac spine below C.D.,		5·0 ,,
,, of the umbilicus above C.D.,		2·7 ,,
,, of the iliac crest (highest point) above C.D.,		3·5 ,,
,, of the aortic bifurcation above C.D.,		2·0 ,,
,, alone the lateral line to the costal arch	—right,	24·8 ,,
,, ,, ,, ,, ,, ,,	left,	24·8 ,,
,, from the ant. sup. iliac spine to the ,,	right,	13·0 ,,
,, ,, ,, ,, ,, ,,	left,	12·5 ,,
,, from the iliac crest (highest point) ,,	right,	4·8 ,,
,, ,, ,, ,, ,, ,,	left,	4·7 ,,
,, between the ant. sup. iliac spines,		23·8 ,,
[1] ,, of the lateral lines from the middle line,		5·95 ,,
Width of the body in the plane of C.D.,		29·0 ,,
,, ,, ,, ,, E.F.,		26·5 ,,
,, across the costal arch, ,,		12·1 ,,
Part of the costal arch cut by E.F.—right		Junction of 8 and 9 costal
,, ,, ,, ,, —left		cartilages at the tip of 9th.

The level of the point on the costal arch cut by the lateral line as to E.F.; right—corresponds with E.F.; left—·125 cm. below E.F.

The relation of E.F. to the disc between the 1st and 2nd lumbar vertebræ, ·33 cm. above.

[1] *Note.*—These measurements, representing a quarter of the preceding, are shown on figs. 3A and 3B as 6 cm., which is sufficiently accurate for practical purposes.

Compare fig. 1 facing page 567.

Surface Points and Measurements.

Height.—There were 12 females and 28 males examined. Only two subjects were under twenty years of age—these being a female, æt. 16, 4 feet 10 inches in height; and a male, æt. 13, 4 feet 6½ inches in height. The average age was 45½ years. The average height 5 feet 3¾ inches, or about 160 centimetres.

The average distance from the pubes to the supra-sternal notch was nearly a third of the height, namely, 52 cm. This distance varied very little: 14 cases were 52 cm. exactly, 5 were

from 50 to 52 cm., 5 from 48 to 50 cm., 7 were 54 cm., and 6 from 54 to 56 cm. One case, a male of 5 feet 5 inches in height, was 58 cm., and two cases were only 46 cm.; being respectively, a male 4 feet 6½ inches in height, and a female 4 feet 7 inches in height.

The average length of the abdominal part of the trunk was 35·8 cm., leaving the manubrium and body of the sternum a total average length of 16·2 cm., or 9·8 per cent. of the total height of the individual. Wright (9) gives the average for males as 9·65 per cent., and for females 9·22 per cent.

The average distance between the transverse lines was 13 cm., or a little over 5 inches. The average distance of the infra-sternal notch[1] above E.F. was 9·8 cm., nearly 4 inches, thus leaving a not too large interval between the body of the sternum and the upper transverse abdominal line. The maximum in this distance was 11·5 cm., and occurred only in 2 cases, and there were only 2 cases in which the distance was less than 8 cm.:—these cases being 7·25 cm. and 7·75 cm. respectively. In such a diversity of subjects, with so different characters of the chest and abdomen, this variation is small.

The line E.F.—Since the mid-point of the distance from the pubes to the supra-sternal notch is taken quite regardless of the condition of the body, whether fat or thin, with the abdomen or chest distended or not, the regularity of the position found to be occupied by the line E.F. renders it a most useful line for surface marking. The variations are fully shown on the curves in fig. 2. In regard to the vertebral column:—The average position it occupied was in the body of the 1st lumbar vertebra ·33 cm. above the disc between the 1st and 2nd lumbar vertebræ. The variations from this disc were very small: in 12 cases the pin pierced the disc; in 15 cases it was 1 cm. or less from the disc; in 9 others the pin was more than 1 cm. but less than 2 cm. from the disc; thus giving 36 cases, or 90 per cent., in which the pin was less than 2 cm. from the

[1] By the infra-sternal notch is meant the notch at the lower border of the sternum between the two 7th costal cartilages, as it can be felt and located on the surface. By the anterior superior iliac spine is meant that spot where the crest of the ilium, as felt through the skin, ceases, and where Poupart's ligament begins. The xiphoid cartilage is in all cases neglected.

disc. Of the remaining cases, the greatest variation was 2·5 cm. above. In three cases it was 2 cm.; in 2 cases above, and in 1 case below the disc.

As regards the costal arch, the line E.F. in the average position passed across exactly at the tip of the 9th costal cartilage on the right side, and a very little above it on the left (see Table I. in the Appendix). Although this was the average level of the tip of the 9th costal cartilage, yet it will be seen on reference to Table I. and to fig. 2, that this point had a wider excursion in relation to E.F. than the first lumbar intervertebral disc[1] had.

In 10 cases the level of the tip of the 9th cartilage was 2 cm. or more removed from E.F.; the greatest distance away being 3 cm. in 2 cases, one above and one below E.F. In 10 cases this point was 2 cm. or more removed from the disc, in 5 of them being from 3 cm. up to 5 cm. away. Although in the remainder of the cases the tip of the 9th costal cartilage closely followed the level of the disc, yet the extent of its variations would make it of somewhat less value than E.F. And, besides, it must be remembered that the 9th costal cartilage often tapers gradually to its extremity, and that even in quite thin persons it is not always possible to locate it.

The line C.D.—Concerning the lower transverse line C.D., its average distance was a little over 5 inches from the upper border of the pubes (13 cm.). In this region of the abdomen, as the bony points are more stable, the necessity for a transverse line, as apart from them, is not pressing. However, the line C.D. occupies a very constant position in relation to the anterior superior iliac spines. Its average distance was exactly 5 cm. vertically above them. As regards the variations:—In 2 cases the iliac spines were nearer than 4 cm. to C.D., namely, 3 cm. and 3·5 cm. In 3 cases the distance was increased beyond 6 cm., being 6·5 cm. In 26 cases, or 65·7 per cent., the line was within ·5 cm. of its average level as regards the iliac spines.

The relation of C.D. to the highest part of the iliac crest was also subject to little variation. It was, on an average, on a plane 3·5 cm. lower than the highest part of the crest. Taking a centimetre each way from the average: there were 4 cases

[1] In future, for convenience, this will be termed the disc.

in which the distance was 4·5 cm. or more, up to 5 cm. below, and five in which it was 2·5 cm. or less, down to 2 cm., the maximum variation thus being 3 cm. In the remaining 31 cases (77·5 per cent.) the variation was less than a centimetre each way from the average. By combining these two statements of the relations of C.D., it will be seen that the average difference in level between the highest part of the iliac crest and the anterior superior iliac spine, as the subjects lay on the table, was 8·5 cm., or nearly 3½ inches.

For the purposes of utility, the relation of the line C.D. in regard to the vertebral column, in the figures and in most of the tables, is referred to the brim of the pelvis in the middle line behind. Its relations, however, to the disc between the 4th and 5th lumbar vertebræ will be fully set forth in the individual case tables.

The part of the vertebral column which, looked at from the front, would be selected as the spot where the spine definitely bends backwards into the pelvis, is, variously, the lower border of the 5th lumbar vertebra, the disc between this bone and the sacrum, or the projecting upper border of the first sacral vertebra.

Wheresoever this point might be, the figures here considered refer to that point, as observed at the end of the examination, from the front. Therefore, as the tilt of the spine varied, C.D. would be expected to vary in level from this point more than from the disc between the 4th and 5th lumbar vertebræ. For the present, however, the average distance of C.D. above this point, which provisionally may be called the sacral promontory, was 3·2 cm. In 23 cases, or 57·5 per cent., the variation was not more than 1 cm. higher or lower than the average. In 9 cases the distance was 2 cm. or less, in 1 case the levels corresponded. Of the remaining 8 cases; in 6 the promontory was from 4·25 to 5 cm. below C.D., and in 2 cases more than 5 cm. up to 5·5 cm. below.

Umbilicus.—As regards the position of the umbilicus, the tables, as well as a large number of the figures, show that, however convenient the umbilicus may appear to be as a surface point, it is not sufficiently stationary in its position for purposes of precise measurement. Summarising here, however, only its

variations as regards C.D. and the iliac crest: Its average position was 2·7 cm. above C.D.; in 12 of the cases it was 3·5, up to 5·5 cm. higher; and in 7 cases it was 1·5 cm. or a less distance from C.D., in one instance being on the same level. The maximum of its variations in level, therefore, was 5·5 cm., as regards C.D.

There were 10 cases in which the umbilicus was 2 cm. or more, up to 3 cm., removed from the level of the highest part of the iliac crests, the maximum of the variation from above downwards being 6 cm. Of the remaining 30 cases, however, there were only 6 in which the difference in level between the umbilicus and the highest part of the iliac crest was as much as 1·5 cm.

Costal Arch.—The width across the costal arch in the plane of E.F. varied too much for the figures to be of any value. The average was 12·5 cm., the extremes being 6 and 18 cm. There were 8 cases with a width of 15 cm. or more, and 7 cases with a width of 9·5 cm. or less. In fact, the tables and figures show quite well that to describe any deep parts as being so much internal to, or so much beneath the costal margin is of very little utility. This, however, applies with less force to the very highest or lowest parts of the costal arch.

The total tranverse diameter of the body in the plane E.F. was 26·5 cm.

The average distance across the body in the plane C.D. was 29 cm., and between the two anterior superior iliac spines was 23·8 cm. The difference between these two measurements indicates that in rising in level 5 cm., up to C.D. from the iliac spines, the crests of the ilia have widened out 1 inch on each side. There were 8 cases in which the distance between the two anterior superior iliac spines was 22 cm. or under; of which 2 were females. The smallest measurement was 19 cm.—in a man 5 ft. 4½ in. in height, 52 cm. from the pubes to the supra-sternal notch. There were 7 cases, all males, in which the distance was 26 cm. or more; the maximum distance, 28 cm., existing in 3 cases, the individuals being respectively 5 ft. 2½ in., 5 ft. 10½ in., and 5 ft. 5 in. in height, and 55, 55, and 58 cm. from the pubes to the supra-sternal notch.

The distance of the lateral line from the middle line follows

from the preceding, and needs no comment, save to point out its average was nearly 6 cm.

The distance vertically upwards from the anterior superior iliac spines to the nearest point of the costal arch varied considerably, on the right side from 9 to 18 cm., and on the left from 8·5 to 17 cm. The average on the right side was 13 cm., on the left 12·5 cm. There were 17 cases in which the distance on the right side exceeded that on the left, and 5 cases in which it was less, there being 18 cases in which the measurements were equal on the two sides. There were 23 cases on each side in which the variation was not more than 1 cm. from the average, upwards or downwards. The 10th costal cartilage was almost invariably the part struck. There were 16 cases, or 40 per cent., in which the 10th costal cartilage did not articulate with the 9th, and in most of these cases the 12th rib was noticed to be small and difficult to feel.

Iliac Crests.—The average distance from the highest part of the iliac crest vertically upwards to the nearest rib was 4·8 cm., and 4·7 cm. on the right and left sides respectively. The part met with was usually some part of the 11th rib. In 33 cases the distances on the two sides were practically equal. In 5 cases that on the right exceeded that on the left, and in 2 cases (one in which is marked doubtful) it was less. The minimum distance on the right side was 3 cm., and the maximum 8 cm.; on the left the minimum was 3 cm., and the maximum 7 cm.

Lateral Lines.—The measurement along the lateral line from Poupart's ligament to the costal arch being taken along the surface of the abdomen, does not always represent the perpendicular between these points. It is of no particular consequence in this place. The average on each side was 24·75 cm. The point on the costal arch cut by this line is, however, of much interest. In 9 cases on the right side and in 10 cases on the left it was identical with that struck by E.F., passing transversely. In 14 cases on each side the lateral line met the costal arch below the level of E.F.; there being in these cases, as well as in those in which the lines met at the costal margin, no hypochondriac region beyond the costal arch. The sum of the distances below E.F. in these 14 cases was on each side 28·5 cm. This, however, does not mean

that, in the individual cases, the distances were the same on each side; in fact, they were not often so; it merely happens that the sums of the differences below the level of E.F. are equal on the two sides. (See Table I., Appendix.)—The greatest distance below E.F. on the right side was 3·5 c.m., and on the left 4·5 c.m.

In 17 cases on the right side and in 16 cases on the left the lateral line struck the costal arch above the level of E.F., the sum of the distances above on the right side being 28·75 cm., and on the left 22·25 cm. The maximum distance above E.F. on the right was 4·5 cm., and on the left 3·5 cm. In all these cases there would be a hypochondriac region, free of the ribs, of varying extent. (See the Figures of the different viscera on the reduced scale.)

The aggregate distances above and below the level of E.F. on the right side, 28·75 and 28·5 cm., practically balance, leaving the level of the point on the costal arch on the right side, struck by the lateral line, identical, in the average, with that cut by E.F., passing transversely.

This point is the tip of the 9th costal cartilage.

On the left side, the aggregate above the level of E.F., 22·25 cm., is less than that, 28·5 cm., below, giving the point struck by the left lateral line as on the 9th costal cartilage ·125 cm. below the level of E.F., which difference for practical purposes is of no account.

Hence, E.F. drawn transversely and the lateral lines drawn vertically, in the average, cut the costal arch on each side in identical points,—these points being on either side the tip of the 9th costal cartilage.

[TABLE II.

THE STOMACH.

TABLE II.

Section I.—Showing the average position of the various parts of the stomach.

M.L. signifies the middle line.

Distance of the centre of the *cardiac orifice below* the infra-sternal notch,	2·1 cm.
" " " above E.F., .	7·7 "
" " " to the left of M.L.,	1·0 "
The lesser curvature.	
[1] The extreme left, or the *left point* of the lesser curvature from M.L.,	3·8 "
" " " " above E.F.,	4·5 "
The lesser curvature in the middle line above E.F., .	1·9 "
The upper border of the pylorus above E.F., . . .	·76 "
" " " from M.L., . . .	2·0 "
The greater curvature.	
The summit of the stomach above E.F., . .	9·6 "
" " below the infr-st. notch,	·13 "
" " from M.L., . .	5·1 "
[1] " extreme *left point* from M.L., . . .	10·7 "
" " above E.F., ...	3·5 "
[2] " in the left lateral line below E.F., . .	1·2 "
[2] " as it passes beneath the costal arch below E.F.,	·5 "
" in the M.L. below E.F., ...	2·5 "
[1] The *right extremity* of the stomach from M.L., . .	2·8 "
" " " below E.F., . .	1·75 "

1. *The average position of the Stomach as regards the surface.*

Definitions.—In the table of averages, the central point of the cardiac orifice is taken for convenience, but the upper and lower borders, the position and obliquity, are fully recorded, and are shown in fig. 4 and in the Appendix. The cardiac orifice in all cases after the first was taken as that part where the œsophagus becomes free of the diaphragm and passes to the stomach. This, in all cases, is not the actual orifice, as the œsophagus

[1] These points are defined more precisely in the text.

[2] Although the average position of the lateral line corresponds to E.F. at the costal arch, these two averages do not necessarily correspond. See fig. 4 and, in the next number of the *Journal*, Table II. (Appendix).

PROFESSOR ADDISON ON ABDOMINAL VISCERA IN MAN.

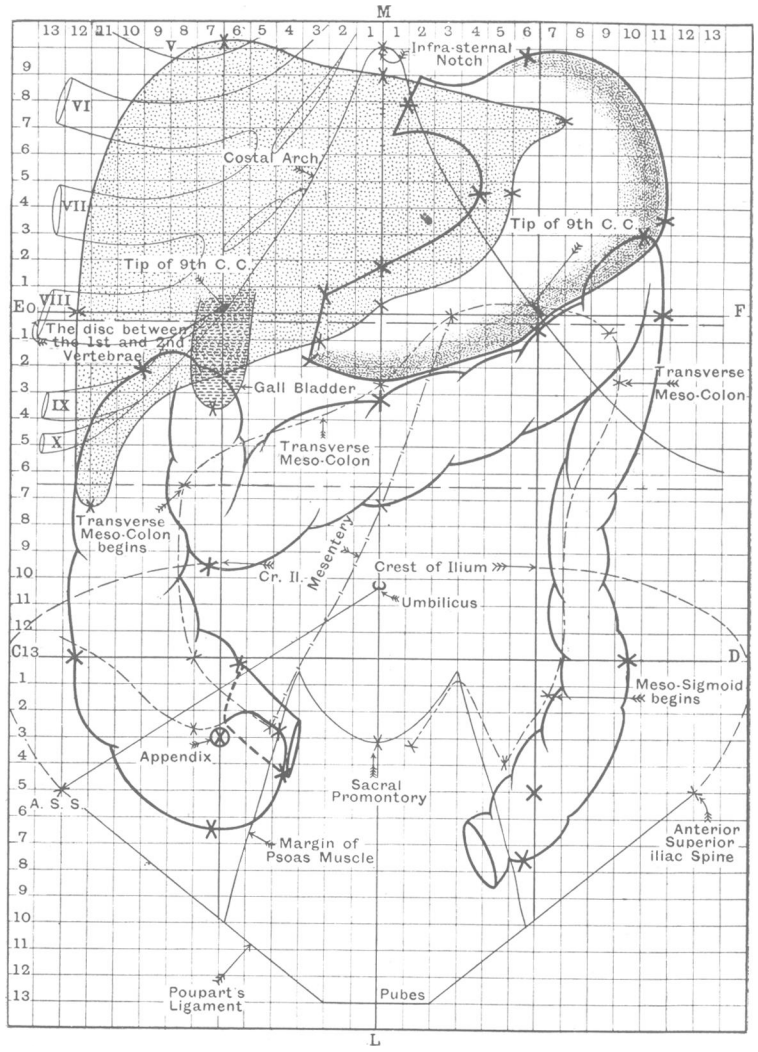

FIG. 3A.—Outline figures showing the average position of the Abdominal Viscera on a centimetre scale; reduced to ·36 natural size. The lines of the peritoneal attachments are also shown. The crosses (+ +) indicate the position of the various "points" referred to in the text. The lettering is the same as in fig. 1. (From a drawing by C. W. SMITH.)

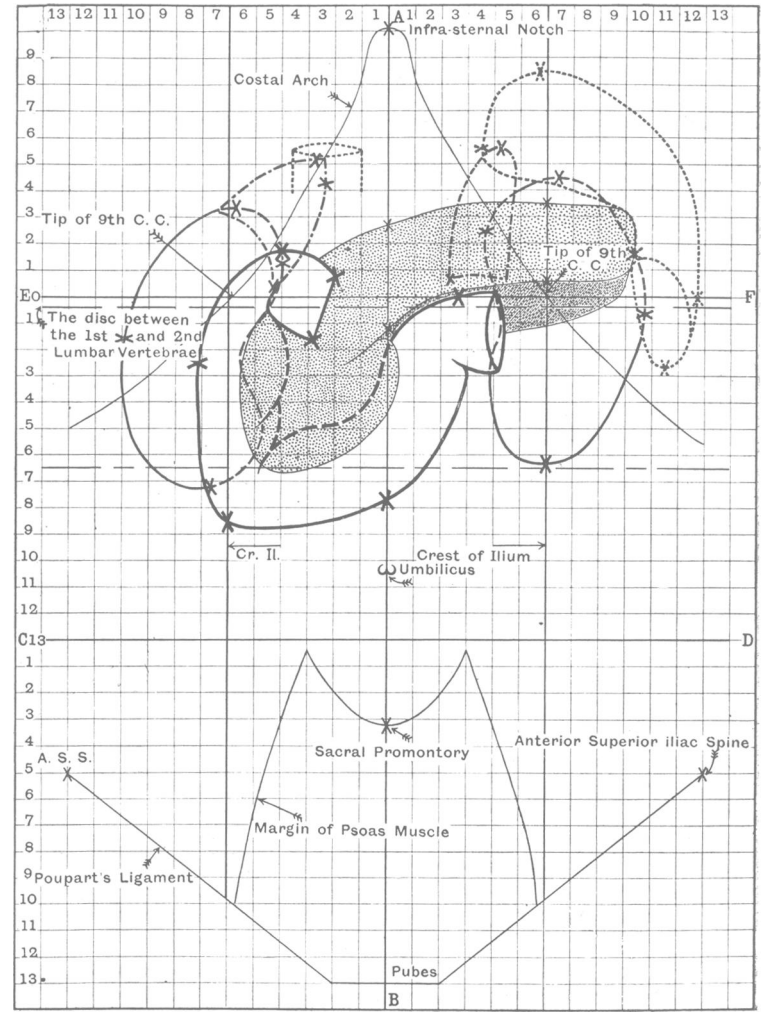

FIG. 3B.—Outlines of the deeper Abdominal Viscera constructed on the same plan as those shown in fig. 3A. (From a drawing by C. W. SMITH.)

Footnote to Figure 3A.—The arrow showing the tip of the 9th right costal cartilage should have been drawn pointing to the intersection of E. F. and the right lateral line.

The lower border of the stomach and the upper border of the transverse colon in the left lateral line should have been each represented ·5 cm. lower down.

frequently passes downwards and to the left for a short distance in the abdomen before opening into the stomach. The extreme of the lesser curvature to the left is always recorded, and the point at its extreme distance from the middle line, which is nearest to the plane of E.F., is spoken of as the *left point* of the lesser curvature. It was necessary to decide upon some such point, as in some cases the lesser curvature passes perpendicularly downwards for some centimetres at its maximum distance from the middle line.

In those cases in which the pylorus was to the left of the middle line, the figures relating to the lesser curvature in the middle line refer to the upper border of the first part of the duodenum. The summit of the stomach was taken as the highest part of the greater curvature when *in situ*. If the stomach be removed from the body and distended, that part which was the highest when in the body is sometimes found to be, now, below the highest part of the freed organ—the actual summit being previously directed backwards. The part along the highest part of the stomach, *in situ*, which was nearest to the middle line is the one referred to in the Table.

The point along the line of the maximum extent to the left of the stomach, which is nearest to E.F., is spoken of as the *left point* of the greater curvature. The part spoken of as the *right extremity* of the stomach was nearly always the lower border of the pylorus, but in those cases in which the stomach bulged to the right beyond the pylorus, it is taken as the most extreme point to the right which is the nearest to E.F.

Average Position of the Stomach.

The lesser curvature.—The average width of the cardiac orifice was a little over 2 cm. Its central point was situated 2·1 cm. below the infra-sternal notch, and 7·7 cm. above E.F.; 1 cm. from the middle line.

Traced from the cardiac orifice, the *lesser curvature* passed downwards and to the left until it reached its 'left point' a little over half way between the infra-sternal notch and E.F., at a distance of 3·8 cm. from the middle line. This 'point' was 4·5 cm.

above E.F., and 5·3 cm. below the infra-sternal notch. From this left point the lesser curvature turned inwards and downwards to the middle line, which it reached at a point 1·9 cm. above E.F., or 7·9 below the infra-sternal notch. From this point the lesser curvature passed for 2 cm. to the right of the middle line, inclining a little downwards to the pylorus. The average level of the upper border of the pylorus above E.F. was ·76 cm.

In connection with the fall in level of the lesser curvature from the middle line to the pylorus, it should be pointed out that if the 4 cases in which the stomach was displaced very low down in the middle line be excluded, in the remaining 36 cases—90 per cent. of the entire series—the fall of the lesser curvature from the middle line to the pylorus was very small indeed, being only ·15 cm.; the level of the upper border of the pylorus in this 90 per cent. of cases being exactly 1·75 cm. above E.F.

The greater curvature.—Passing along the greater curvature from the cardiac orifice, the stomach reached its maximum height in the upper part of the 5th intercostal space at a distance of 5·1 cm. from the middle line, and ·13 cm. below the infra-sternal notch, and 9·66 cm. above E.F. Continuing to the left, the greater curvature maintained nearly this level for a further 3 cm., extending to about 8 cm. from the middle line. It then turned downwards in the concavity of the diaphragm, extending still more to the left as far as its 'left point,' which was situated at a distance of 10·7 cm. from the middle line, 3·5 above E.F., whence it turned inwards as the lower border of the stomach. It emerged from beneath the costal arch, at the 9th costal cartilage, a very little below the plane of E.F. (·5 cm.), and continued inwards, with a slight convexity downwards, to the middle line, which it reached at a point 2·5 cm. below E.F. The average width of the stomach, therefore, over the middle line was 4·4 cm., *and the line E.F. passed about midway between its upper and lower borders*, being, as a matter of fact, ·3 cm. above the middle.

From the middle line the greater curvature passed to the right for 2·8 cm., with an inclination upwards; its right extremity being situated 1·75 cm. below E.F. The pylorus had a vertical

depth of 2·5 cm., its upper border being situated 2 cm. and its lower border 2·8 cm. from the middle line; the line of the orifice thus passed obliquely downwards and to the right, *and the line E.F. passed almost midway across it*,—as a matter of fact, a little nearer its upper than its lower border.

The remarkable regularity of the line E.F., as a guide to the pylorus, the stomach in the middle line, and, with less accuracy, the greater curvature in the left lateral line, seems to give it a very considerable value as a surface-line. These points are seen at a glance on reference to fig. 4, in which all the stomachs are displayed on the one-ninth scale, arranged along vertical and horizontal lines representing the middle line and E.F. respectively. It will be seen that in at least 29, or 72·5 per cent., of the 40 cases, E.F. as a guide line to the pylorus would have been absolutely reliable.

From the foregoing figures it may be pointed out:—

That the average transverse width of the stomach, as seen from the front, at the level of the 'left point' of the lesser curvature, was 7 cm.; that the vertical depth at the point where the greater curvature passes from the costal margin, a little below the level of E.F., was 10 cm.; that the distance on the vertical plane from the centre of the cardiac orifice to the centre of the pylorus was 8·2 cm.; that the distance between the lower border of the cardiac orifice and the upper border of the pylorus in the vertical plane was 5·9 cm.; and that the distance on a transverse plane between the centres of the two openings was 3·5 cm. The accordance, or otherwise, of any of these averages with the surface markings generally adopted will be referred to in discussing the variations in the position of the stomach.

To summarise the foregoing statement in general terms of inches:—

The central point of the cardiac orifice is situated rather less than an inch below the infra-sternal notch, about half an inch from the middle line. From the cardiac orifice the lesser curvature passes downwards and to the left, until it reaches a point rather more than half way from the infra-sternal notch to E.F., at a distance of 1½ inches from the middle line. Here it bends inwards and downwards, and reaches the middle line about ¾ of an inch above E.F., beyond which it continues to the

right for nearly an inch, to end as the upper border of the pylorus.

The greater curvature, from the cardiac orifice, passes outwards and upwards until the stomach attains its maximum height in the 5th interspace in the left lateral line, about the level of the infra-sternal notch. The greater curvature continues for rather more than an inch further outwards in this level, where it bends downwards, gradually attaining a maximum distance of nearly $4\frac{1}{2}$ inches from the middle line. At this maximum distance from the middle line, under cover of the ribs, it reaches a point $1\frac{1}{2}$ inches above the level of E.F., where it bends inwards, forming the lower border of the stomach which passes from beneath the costal arch about the level of E.F., a little behind the tip of the 9th costal cartilage. From this place the greater curvature continues inwards with a slight convexity downwards, reaching the middle line 1 inch below E.F., from which it passes to the right, with a slight inclination upwards for a little over an inch, to the lower border of the pylorus.

The pylorus is situated 1 inch to the right of the middle line, and is bisected by the line E.F.; its upper border is 3 inches below the infra-sternal notch.

The line E.F., beside bisecting the pylorus, practically bisects the portion of the stomach overlying the middle line, and represents the lower border of the stomach, where it meets the left costal arch.

The distance on a vertical plane between the centres of the cardiac and pyloric orifices is about 3 inches, and on a transverse plane nearly $1\frac{1}{2}$ inches.

DESCRIPTION OF PLATES XLIII. AND XLIV.,

REFERRED TO, ERRONEOUSLY, ON pp. 582 AND 585 AS FIG. 4.

Figures showing the stomachs from the whole series of cases, arranged on a scale of one-fifth—the divisions representing centimetres—about the middle line (M.L.) and the upper transverse abdominal line (E.F.). The costal arch and the position of the left lateral line are also represented.

To follow page 586.]

APPENDIX.

TABLE I.

All measurements in centimetres except the height, which is in feet and inches.
The sign = indicates corresponding points or levels.

Notes.	Number of Case.	1	2	3	4	5	6	7	8	9	10	11	12	13	14	15	16	17	18	19	20	21	22	23	24	25	26	27	28	29	30	31	32	33	34	35	36	37	38	39	40	Average.
	Age,	52	55	59	60	71	47	36	55	59	66	30	50	52	40	61	45	31	39	24	39	35 ?	55	29 ?	40 ?	29	16	13	42	63 ?	38 ?	35	65 ?	64	35	35	43	55	65	35	64	45·6 Years.
	Sex,	M	M.	M.	F.	F.	M.	M.	F.	M.	M.	M.	M.	M.	M.	M.	M.	M.	F.	M.	F.	M.	F.	M.	F.	M.	F.	M.	M.	M.	M.	F.	M.	M.	M.	F.	M.	F.	F.	M.	F.	
	Height,	5 ft. 4 in.	5 ft. 6½ ins.	5 ft. 5 ins.	5 ft. 2 ins.	5 ft. 1 ins.	5 ft. 6 ins.	5 ft. 4 ins.	5 ft. 6 ins.	5 ft. 3½ ins.	5 ft. 2½ ins.	5 ft. 10½ ins.	5 ft. 7 ins.	5 ft. 6½ ins.	5 ft. 4½ ins.	5 ft. 6½ ins.	5 ft. 11 ins.	5 ft. 4½ ins.	5 ft. 1½ ins.	5 ft. 9 ins.	5 ft. 1 in.	5 ft. 9 ins.	5 ft. 1 in.	5 ft. 8 ins.	4 ft. 10 ins.	5 ft. 4½ ins.	4 ft. 10 ins.?	4 ft. 6½ ins.	5 ft. 1½ ins.	5 ft. 2 ins.	5 ft. 4½ ins.	4 ft. 6 ins.	5 ft. 7 ins.	5 ft. 5 ins.	5 ft. 5 ins.	5 ft. 7 ins.	4 ft. 7 ins.	5 ft. 5½ ins.	5 ft. 7 ins.	5 ft. 1 in.	4 ft. 10 ins.	5 ft. 3½ in., 160 cm. about.
	Distance from the upper border of the pubes to the supra-sternal notch,	50	52	54	50	52	52	49	52	55·5	55	55	55	49·5	52	52	56	52	52	52	52	54	50	54	48	52	48	46	52	52	52	50	54	58	52	56	46	54	54	51	48	52 cm.
(1)	,, between the transverse abdominal lines C.D. and E.F.,	12·5	13	13·5	12·5	13	13	12·25	13	13·75	13·75	13·75	13·75	12·25	13	13	14	13	13	13	13	13·5	12·5	13·5	12	13	12	11·5	13	13	13	12·5	13·5	14·5	13	14	11·5	13·5	13·5	12·75	12	13 ,,
	,, of the infra-sternal notch below the transverse thoracic line X.Y.,	3·5	5·25	3	1	2	3·5	2	2	3·5	3·5	5·5	4·5	5	2·5	2·5	4	3·75	1	4	3·5	2·5	2·5	4	2·5	3	2·5	2·5	4	4·5	2	1·5	4·5	4·5	5	2·5	3·25	4	3·5	2·5	1	3·2 ,,
	,, ,, ,, ,, above E.F.,	9	7·75	10·5	11·5	11	9·5	10·25	11	10·25	10	8·25	9·25	7·25	10·5	10·5	10	9·25	12	9	9·5	11	10	9·5	9·5	12	9·5	9	9	8·5	11	11	9	10	8	11·5	8·25	9·5	10	10·25	11	9·8 ,,
	,, ,, sacral promontory . below C.D.,	2	3	1·5	1·5	2·5	3·5	2	=	5·25	3	4·75	4	3	4	3·5	2·5	4	4·5	4	·5	2	2	3·5	1·75	3·5	2·5	3	4	5	3·5	3	3·5	5·5	3	5	3·5	5	5	4	2·5	3·2 ,,
	,, ,, anterior superior iliac spine ,, C.D.,	5	5	3	4	5	5	4·5	4	5·5	4·8	6	5	5·25	5	5	5	5	5·5	6·5	5	4	4	5·5	3·5	5	5·5	4·5	5·5	6	5	5·5	5·5	6	5	6·5	4	6	6·5	4·5	4·5	5 ,,
	,, ,, umbilicus . . . above C.D.,	3·5	3	5	3·5	3·5	3·5	1	2·75	2·25	2	2	1·5	3	3	2·5	3·5	2·5	4	2	2·5	4	4·5	2	2·25	3	2	1·5	3	1	2	1	3·5	1	3	3	3	2	=	5·5	4·5	2·7 ,,
	,, ,, aortic bifurcation . ,, C.D.,	=	=	1	5	3	3	2	1	1	2	·5	2·5	=	=	1	=	4	4	1	4·5	4·75	3	3	5·5	3	3·5	1·5	1·5	=	3	2·5	3·5	2·5	2	2	2·5	=	=	=	2·5	2 ,,
	,, highest part of the iliac crest ,, C.D.,	3·5	2	4·5	5	3·5	3·5	3·5	4	3	3·5	2·5	3	3	3	4	4	3	3	3·5	4	5	3·5	4	4·5	5	3	3·5	3	3	3·5	3	4	3·5	4	3	3·25	2·5	3	2·5	4·5	3·5 ,,
(2)	,, along the lateral line to the *costal arch*—right,	22·5	23	24·5	20·5	22	25	24	21·5	30	30	28	27	26	25·5	23·5	26	23·5	23·5	23·5	25	21	25·5	27	19·5	25	23	23·5	24	27	24·5	28	25·5	30	25	27	20	26	28·5	23·5	25	24·8 ,,
	,, ,, ,, ,, ,, left,								22	29			25·5				27			24		19·5								23		26	26·5				22		29	26·5		21·8 ,,
	,, from the ant. sup. iliac spine to the *costal arch*—right,	10·5	12·5	11·5	14	14	11	13	11·5	18	11·5	13	9	10	14·5	11·5	13	12	15	14	13	14	13	14	11	14	14	13	14	11·5	12·5	14	13	18	11	14	11	12·25	15	13·5	14	13 ,,
	,, ,, ,, ,, ,, ,, left,	9	11·8	12	13				13	15			8·5		13			11	13	13		13				13				10·5	13	13	12	17			11·5		14	14	13	12·5 ,,
	,, ,, highest part of the iliac crest to the *costal arch*—right,	3	5·8	5·5	5	5	4	3·5	4	8	5·5	5	4·5	4·5	4·5	5	5·5	4	7	4	6·5	4·75	3·5	5	6	6·5	4·5	4·5	3·75	5	2·5	6·5	5	6·5	4	5·5	4·5	5	5	4·5	4	4·8 ,,
	,, ,, ,, ,, ,, ,, left,		5	7·1	4					5																						5	3·5				5·5					4·7 ,,
	,, between the anterior superior iliac spines,	27	23	21	24	25	23·5	20	20	25	28	28	24	23	24	24	27	23	23	25	24	25	24	24	24	24	23	21	22	26	19	22	25	28	23	26	23	22	25	25	23	23·8 ,,
(3)	,, of the *lateral lines* from the *middle line*,	6·75	5·75	5·25	6	6·25	5·8	5	5	6·25	7	7	6	5·75	6	6	6·75	5·75	5·75	6·25	6	6·25	6	6	6	6	5·75	5·25	5·5	6·5	4·75	5·5	6·25	7	5·75	6·5	5·75	5·5	6·25	6·25	5·75	6	,, see note 3.
	Width of the body . in the plane of C.D.,	30·5	27·5	27·5	25·5	29	26 ?	24 ?	28	30	32	34	30·5	27·5	27	29	31	29	28	28	33	29·5	29	31	29	28	29	27	28·5	34	26	32	30·5	34	28	29	24	26	34	28	27·5	29 ,,
	,, ,, ,, E.F.,	28	26·5	26	22·5	26	26 ?	24	21	30	34	32		28	29	26	30		24	26	24	25	25	29	22	26·5	27		27·5	30	25	28	29	31	26	27	21	28	33	24	25	26·5 ,,
	,, across the costal arch ,, E.F.,	14	10	12	10	18	11·75	12	8	16	13	14	14	14	14	10	11	11·5	8	8	10·5	6	13·5	12	7	14	10	16·5	12	11	9·5	15·5	13	17	11	15	9	11	15·5	10·5	16	12·1 ,,
(4)	The costal cartilage cut by E.F.—right,	9th (−1)	8th & 9th	9th (−1·5)	8th (+·5)	9th (−3·5)	8th & 9th	9th (−2·5)	8th (+3·5) / 8th (+2)	8th & 9th	8th (+2)	8th & 9th	8th & 9th	9th (−3) / 9th (−2·5)	8th & 9th	9th (−1) / 8th & 9th	8th & 9th	9th (−2) / 8th & 9th	9th (−3) / 9th (−4)	8th & 9th	8th (+3) / 8th (+3·5)	9th (−2·5)	8th & 9th	8th (+3)	8th & 9th	8th (+1·5) / 8th (+2·5)	9th (−1)	9th (−2)	8th (+2)	8th (+3) / 8th (+3·75)	9th (−1·5)	9th (−3)	8th (+3)	8th (+2)	8th (+3) / 8th (+2·5)	8th & 9th	9th (−1·5) / 8th (+1·5)	8th (+1)	8th (+2) / 8th & 9th	8th (+1)	9th (−1)	8th & 9th	Junct. of 8th and 9th (Tip of 9th c.c.).
	,, ,, ,, E.F.—left,	=																																								
	The point where the lateral line cuts the costal arch above (*a*) —right,	·75.*a*.	2.*b*.	2.*a*.	2·5.*b*.	1·75.*a*.	=	=	2·5.*b*.	3.*a*.	1.*b*.	=	1.*a*.	1·5.*a*.	1.*a*.	1·5.*b*.	2·5.*b*.	=	1·5.*b*.	2·5.*b*.	1.*b*.	3·5.*b*.	1.*a*.	=	3·5.*b*.	1.*a*.	1.*b*.	1·5.*a*.	·5.*a*.	·5.*a*.	=	4·5.*a*.	=	1·5.*a*.	1.*b*.	1.*a*.	=	=	1.*a*.	2.*b*.	3·5.*a*.	=
	or below (*b*) the plane of E.F., —left,	=							1 5.*b*.	2.*a*.	1.*b*.		1.*a*.	1·5.*a*.	1.*a*.	1·5.*b*.	1.*b*.	=	1·5.*b*.	2.*b*.	1.*b*.	4·5.*b*.	·5.*a*.	=	3·5.*b*.	1.*a*.	1.*b*.	1·5.*a*.	·5.*a*.	3·5.*b*.	=	2·5.*a*.	1.*a*.	1·5.*a*.	=	1.*a*.	2.*b*.	=	1.*a*.	=	2·5.*a*.	·125 cm. below.
	The plane E.F. above (*a*) or below (*b*) the disc between 1st and 2nd vertebræ,	1.*b*.	·5.*a*.	=	·75.*b*.	·5.*b*.	=	1·25.*b*.	2.*b*.	2·5.*a*.	1.*a*.	1·5.*a*.	1·5.*a*.	1.*a*.	2.*a*.	=	=	1.*a*.	1·5.*a*.	=	1·5.*b*.	=	=	2.*a*.	1.*b*.	1.*a*.	·5.*a*.	=	1·5.*a*.	1.*a*.	=	1.*a*.	=	1·5.*a*.	1·5.*b*.	·5.*a*.	=	1·25.*a*.	1.*b*.	=	1.*a*.	·33 ,, above.
(5)	Commencement of examination. Hours after death,	Hardened	Hardened	12	30	16	30	20	38	3rd day	3rd day	44	28	40	36	6	3rd day	18	40	20	16	56	40	16	3rd day	12	14 ?	16	3rd day	60	24	16	14	30	18	24	36	3rd day	50	14	36	
(6)	Condition of nutrition,	F	G	E	E	Fat	F	E	E	G	Fat	G	G	E	F	E	G	F	F	E	G	E	Fat	G	E	G	G	E	F	Fat. D	E	Fat. D	F	Fat	F	F	E	F D	Fat	E D	E	
(7)	Place of examination,	A	A	B	C	C	C	C	C	A	A	E	D	D	D	D	D	D	D	D	D	C	C	B	C	B	B	B	C	C	C	B	C	B	C	C	D	D	D	D	D	

Notes.—(1) The distance from the pubes to the supra-sternal notch is divided into four equal parts by three transverse lines—C.D., a quarter-way; E.F., half-way; X.Y., three-quarters of the way. C.D. is wholly abdominal; E.F. is partly abdominal, partly thoracic; X.Y. is wholly thoracic.
(2) The distance directly upwards from Poupart's ligament along the surface of the abdomen.
(3) Midway between the anterior superior iliac spine and the middle line. The average, given as 6 cm., instead of the precise average 5·9 cm., is adopted for convenience' sake.
(4) The costal cartilage cut by E.F. is indicated thus:—If the 8th cartilage were cut 1 cm. in front of the tip of the 9th, it would be written 8th (+1); if the 9th cartilage 1 cm. behind its tip, 9th (−1); if at the tip of the ninth, 8th and 9th.
(5) The first two subjects were hardened by the injection a 5′/₁ solution of formic aldehyde as described in the text. In some cases the exact number of hours after death could not be ascertained, in these cases the day after death is stated only.
(6) F = fair, G = good, E = emaciated, D = abdomen distended.
(7) A, the Medical School, Sheffield. B, St Bartholomew's Hospital. C, the London County Asylum, Banstead. D, the Fir-Vale Workhouse, Sheffield. E, the Royal Infirmary, Sheffield.

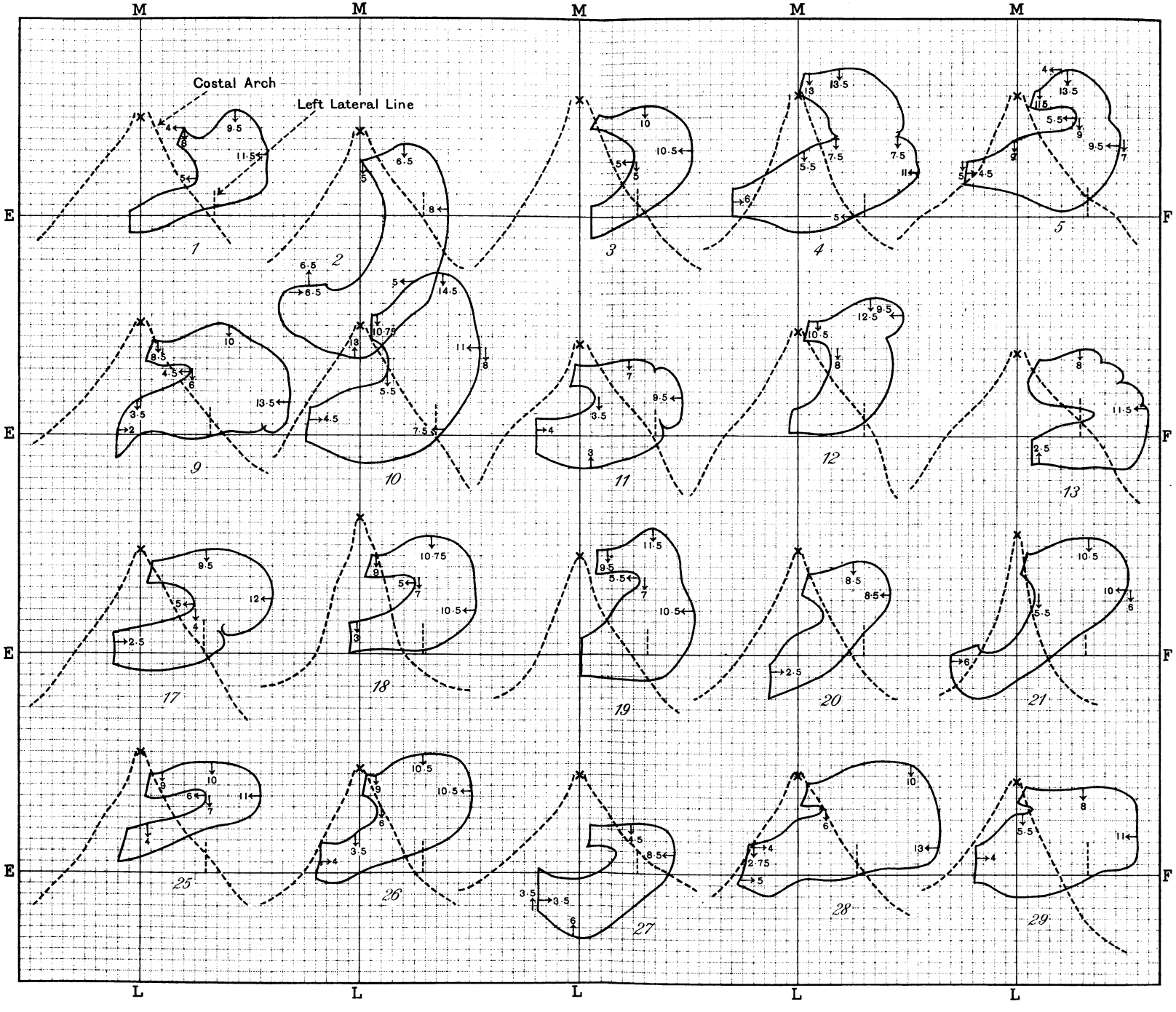

Edwin Wilson. Cambridge.

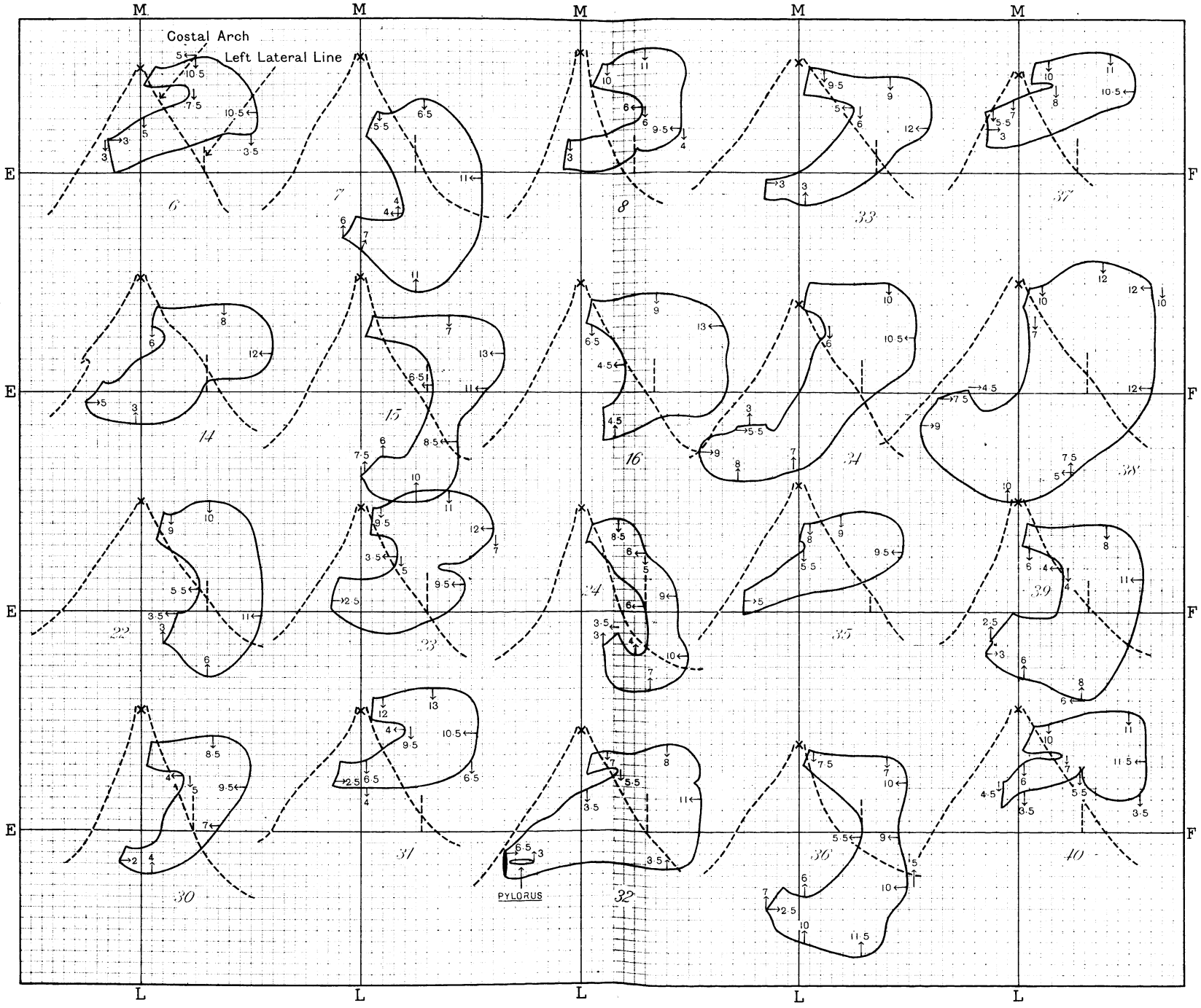

Edwin Wilson Cambridge