CONJUNCTIVAL FLAPS FOR CORNEAL DISEASE: THEIR USEFULNESS AND COMPLICATIONS

BY *Trygve Gundersen*, M.D., AND (BY INVITATION) *Harrison R. Pearlson*, M.D.

ELEVEN YEARS AGO, the senior author described a method of covering the cornea with conjunctiva, which gave a reasonable assurance that the covering might be permanent.[1] At that time, 31 operations were reported. It was found especially useful for patients with chronic or severe herpetic keratitis, neuroparalytic keratopathy, uncontrolled relapsing erosions, marginal ulcers, advanced bullous keratopathy, filamentary keratitis, and painful blind eyes.

Two years later, the senior author described two types of operations for combining lamellar keratectomy with conjunctival flaps, when bullous keratopathy was the major problem.[2] The first, called an "inlay flap," consisted of removing a segment of the cornea adjacent to the limbus and replacing this defect with conjunctiva and Tenon's capsule brought in from the adjacent limbus, and sewing them in place with fine silk sutures. The second type of operation, called "peripheral lamellar keratectomy with permanent conjunctival flap," was also described for use in more severe cases of bullous keratopathy.

From 1958 through 1968, we have performed 146 additional operations on 133 patients. The present report summarizes our experiences with a total of 177 operations of this type. As in the two previous reports, the operations were performed for disease that had resisted all conventional forms of treatment, including idoxuridine, cortisone, chemical and thermal cauterization, and sometimes irradiation.

TECHNIQUES

The techniques of these types of operations have been described in detail in the two earlier publications.[1,2] There have been no significant modifications of technique since the 1960 publication.

AGE DISTRIBUTION

Table 1 illustrates the age distribution in our present series of 133 patients. The youngest group includes several patients with retrolental fibroplasia with secondary corneal edema or band-shaped keratopathy. Lamellar keratectomy combined with total conjunctival flap permitted the wearing of a prosthesis by these children. Others in this group had neuroparalytic keratopathy, either congenital or resulting from intracranial neoplasms. Patients ranging in age from 20 to 50 years were operated on primarily for herpes simplex of the cornea or for

TABLE I

AGE DISTRIBUTION (133 PATIENTS)

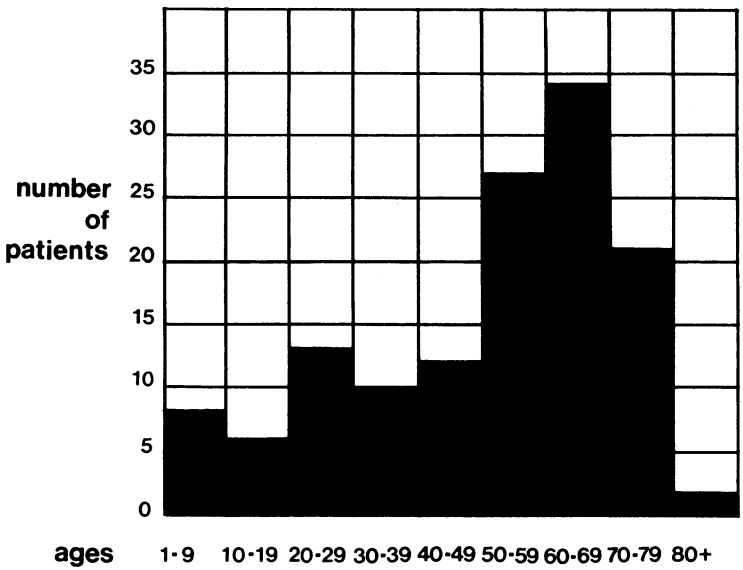

trauma. Those in the age group above 50 years comprised the largest group. These patients were operated on primarily for bullous keratopathy and frequently their corneal disease followed surgery for cataract or glaucoma.

INDICATIONS FOR SURGERY

Table 2 shows the most frequent indications for applying conjunctival flaps with or without keratectomy in the total series to December

TABLE 2. MOST FREQUENT INDICATIONS FOR SURGICAL INTERVENTION

Diagnosis	Number of patients
Herpes simplex	60
Bullous keratopathy	44
Trauma	11
Neuroparalytic keratopathy	9
Traumatic relapsing keratopathy	6
Others	47
TOTAL	177

TABLE 3. PREOPERATIVE DIAGNOSES IN PRESENT SERIES OF 133 PATIENTS

Diagnosis	Number of patients
Herpes simplex (11 with hypopyon)	39
Keratitis, unclassified	7
Bullous keratopathy	40
Idiopathic	8
Secondary to endothelial dystrophy	7
Secondary to aphakia	25
Neuroparalytic keratopathy, not herpetic	8
Traumatic relapsing keratopathy	5
Trauma	11
Lacerations	5
Chemical burns	5
Birth injury	1
Exposure keratopathy	3
Keratitis sicca	4
Retrolental fibroplasia with hydrops or glaucoma	2
Buphthalmos	2
Glaucoma, absolute	4
Herpes zoster	2
Tuberculosis with lipoid dystrophy	1
Coats disease with band-shaped keratopathy	1
Corneal leucoma with band-shaped keratopathy	1
Keratomalacia perforans	1
Filamentary keratitis	1
Exophthalmos with hypopyon ulcer	1

1968. Table 3 gives a complete analysis of the preoperative diagnosis in the present series of 133 patients. The severity of the corneal disease for which these operations were performed is apparent when one considers that of 39 patients with herpetic keratitis, 11 had a hypopyon, and 3 had a descemetocele. The preoperative visual acuity was less than 6/60 in most patients, when a total flap was applied. This operation was often an alternative to enucleation.

DISCUSSION

HERPES SIMPLEX

Sixty operations were done for herpes simplex of the cornea in the combined series. Conjunctival flaps combined with chemical or thermal cauterization appear to be an effective method of treating severe corneal ulcers caused by herpes simplex when there is loss of substance, loss of sensation, or hypopyon. The best results have been obtained in cases of stromal herpes with ulceration, or when the corneal disease has reached the neuroparalytic phase. No matter what the cause of neuroparalytic keratopathy might have been, conjunctivoplasties have protected the cornea during the most critical period and often allowed the cornea to re-establish its integrity.

This operation has been performed in only advanced stages of herpetic keratitis. The authors have found conjunctival flaps to be safe and effective, even in the presence of corneal descemetocele or impending perforation.

In the entire series of operations carried out for herpes simplex, only three eyes were lost because of subsequent perforations under the conjunctival flap. Most eyes that initially appeared to be hopeless at the time of surgery, healed and usually required no further surgery. The vision usually improved. In a few eyes, the cornea healed sufficiently so that a subsequent autograft or homograft could be performed successfully.

It is of interest that epithelial herpes has never been observed under a thin conjunctival covering even though dendritic figures have occurred in the adjacent uncovered cornea.

BULLOUS KERATOPATHY

Forty-four operations were performed for bullous keratopathy. Peripheral lamellar keratectomy, when combined with a total conjunctival flap, is useful when the bullous keratopathy is diffuse. It relieves pain, partially dehydrates the cornea, and does not preclude subsequent penetrating keratoplasty should it become necessary. These flaps may be left in place or the conjunctiva covering the central cornea (that which was not keratectomized) may be removed at a later date. The relief of pain has been universal when the cornea is permanently covered with a smooth conjunctival surface. Removing the superficial cornea with its sensory nerves and replacing it with less sensitive conjunctiva is undoubtedly the explanation.

The dehydrating effect of a conjunctival flap on the cornea has

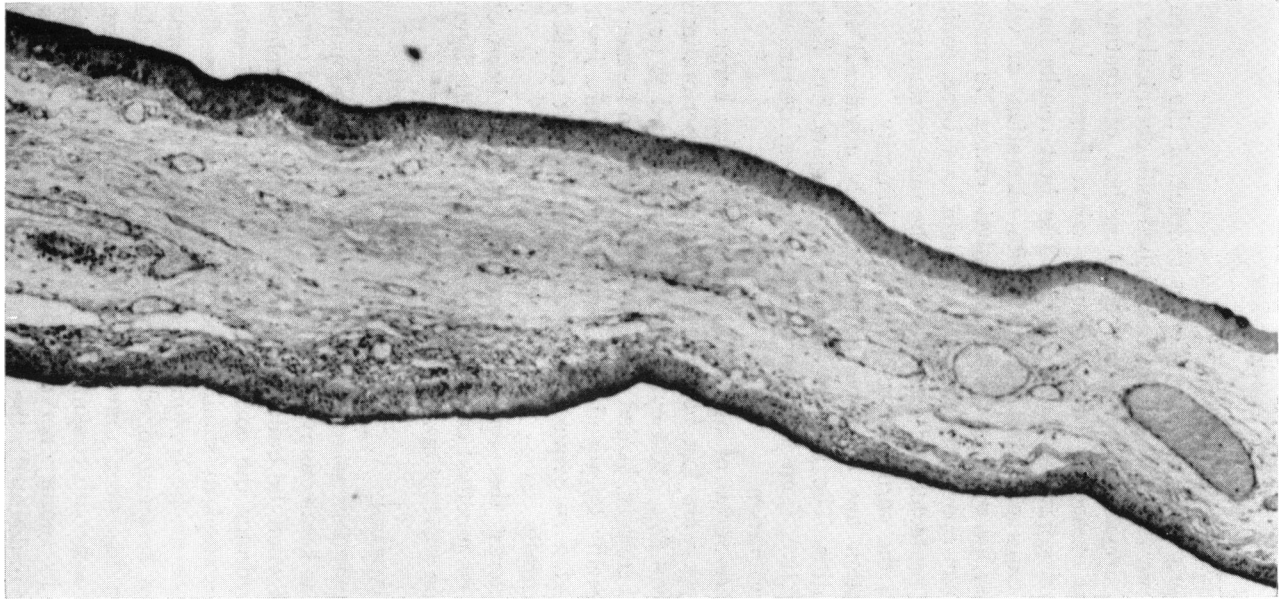

FIGURE 1
Conjunctival flap removed after seven months. Epithelium covering both surfaces. (× 4)

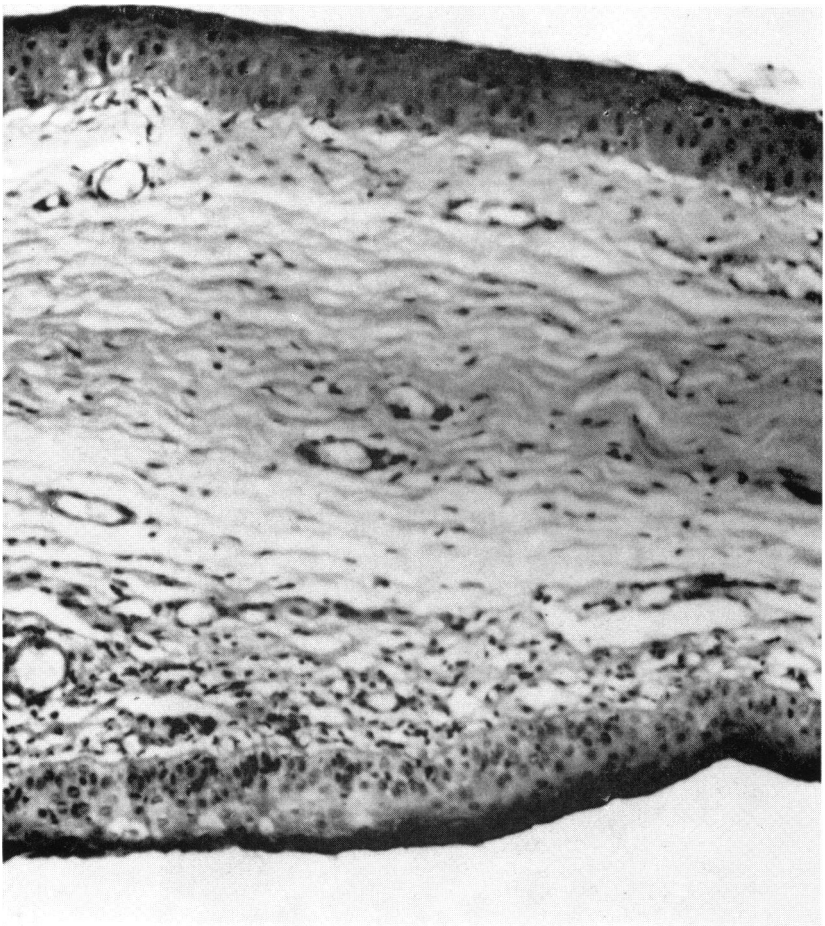

FIGURE 2
Conjunctival flap removed after seven months. Epithelium covering both surfaces. (×10)

also been well demonstrated. While the flap is in place, fluid apparently filters through the partially keratectomized and therefore more permeable peripheral cornea. This fluid is absorbed by the rich blood supply that now comes in contact with the peripheral cornea, and clearing of the edematous cornea occurs. After healing, removal of the conjunctiva over the central cornea, which has not been keratectomized, restores the preoperative visual acuity in all cases. Total conjunctival covering without a lamellar keratectomy is not advised,

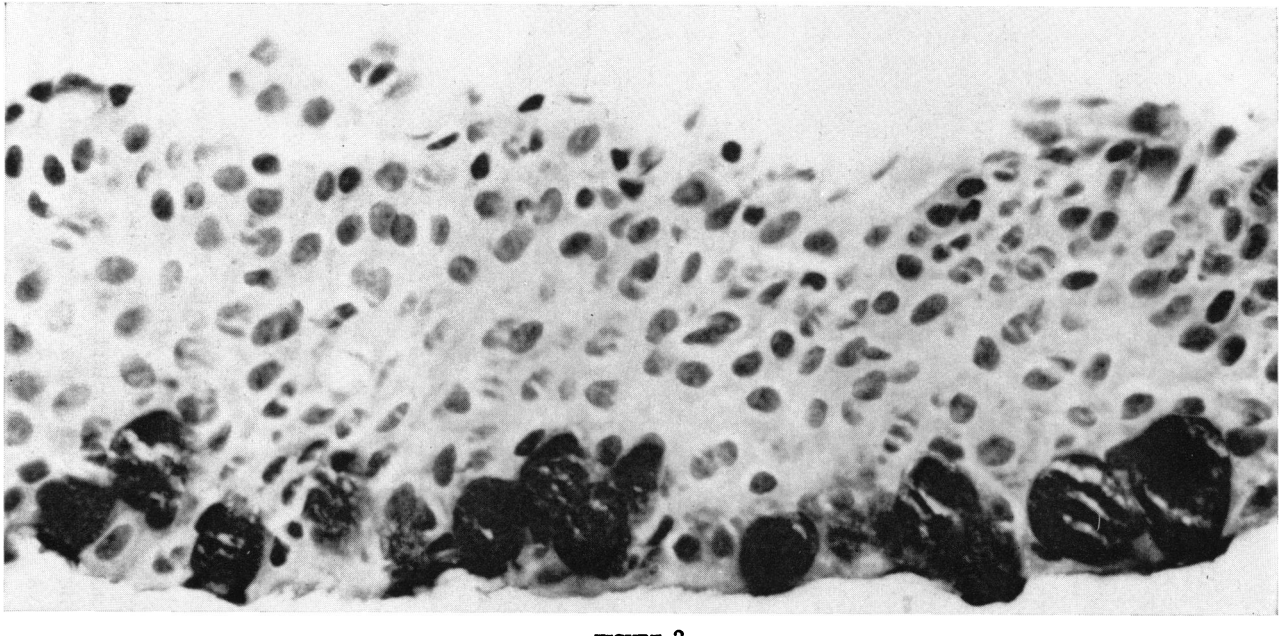

FIGURE 3
Goblet cells in conjunctival flap. (× 40)

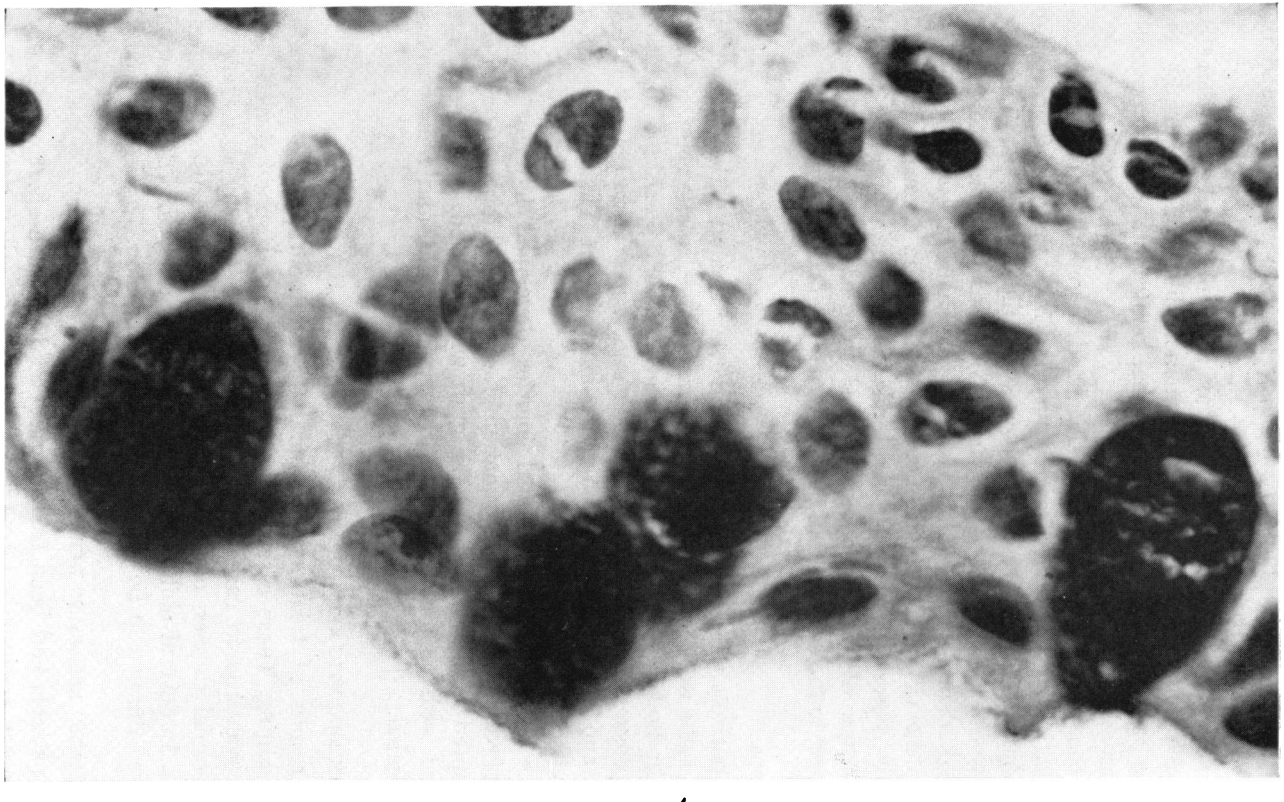

FIGURE 4
Goblet cells in conjunctival flap. (× 100)

since accumulation of fluid can occur between the cornea and the overlying conjunctiva.

A fall in intraocular pressure has been observed after lamellar keratectomy with an inlay flap. Permanent filtration was established in one patient when a wide transcorneal keratotomy was subsequently performed.

If the bullous keratopathy is localized to one-third of the cornea or less, a partial lamellar keratectomy and inlay flap is the procedure of choice. This can arrest the progress of bullous keratopathy advancing from the limbus regardless of its cause. In aphakic eyes with corneal edema, the operation has been particularly successful. In these cases, the visual results are more gratifying. The corneal edema will usually regress, and even if it extends beyond the margin of the flap at the time of surgery, unmistakable clearing has occurred in the area adjacent to the conjunctival inlay.

TRAUMA

Five patients with penetrating wounds were treated with conjunctival flaps, some with and others without keratectomy. In one child, retained foreign bodies in the peripheral stroma caused persistent irritation and progressive vascularization. After one year of symptoms, keratectomy and an inlay flap arrested the inflammation. This child's vision is now normal.

Five patients with chemical injuries developed indolent corneal ulcers with persistent inflammation. Lamellar keratoplasty had been attempted in one patient but the graft was extruded. All five patients treated with conjunctival flaps are asymptomatic, and their corneas are healed.

NEUROPARALYTIC KERATOPATHY

The results of treating neuroparalytic keratopathy were especially encouraging. Those cases due to herpes simplex responded well. The same was true in cases of neuroparalytic keratopathy secondary to intracranial tumors, congenital anomalies, or other causes of hypesthesia. In several children under the age of ten years, the operation allowed the eye to be retained with useful vision.

TRAUMATIC RELAPSING KERATOPATHY

Five patients had been treated unsuccessfully with chemical cautery. While the conjunctival covering was in place, all patients remained

asymptomatic. However, two patients required keratoplasties following removal of the flaps. One patient had a recurrence. The three remaining patients who had inlay flaps recovered and have been free from symptoms.

EXPOSURE KERATOPATHY

Inlay flaps have been especially successful for patients with exposure keratopathy and other diseases where there was localized loss of corneal substance. Ulceration occurring under these conditions are recalcitrant to medical therapy. Relief of symptoms and healing of the ulcer has been prompt in the three patients who have been operated on.

KERATITIS SICCA

Advanced keratitis sicca is frequently unrecognized when the eye is inflamed and has an indolent ulcer. Three total flaps with keratectomies were done for this condition and all patients were relieved of symptoms. One patient had a large ulceration inferiorly, which healed following an inlay flap and transplantation of the canaliculi.

Conjunctival flaps are a useful alternative to enucleation for painful blind eyes, when enucleation is refused.

COMPLICATIONS

In the present series the following complications were encountered and are summarized in Table 4.

TABLE 4. COMPLICATIONS IN PRESENT SERIES OF 133 PATIENTS

Complications	Number of patients
Total enucleations	6
Perforations *after* flap, secondary glaucoma	2
Perforations *before* flap, secondary glaucoma	1
Endophthalmitis with hypopyon	1
Endophthalmitis following flap and autograft	1
Retrolental fibroplasia, corneal hydrops cosmetic reasons	1
Corneal perforations followed by healing	2
Fluid accumulations under flap	11
Requiring paracentesis	5
Retractions of flap	10
Limbal cysts	5
Fenestrations in flap	4

CORNEAL PERFORATIONS

Even though the corneas eventually healed, four perforated under the conjunctival flap. Two patients developed secondary glaucoma preceding the perforation. These eyes were ultimately enucleated. The third patient with a severe necrotizing herpetic keratitis was treated by thermal cauterization and a conjunctival flap. The eye became white and quiet, but for unknown reasons and without apparent secondary glaucoma, the cornea perforated under the flap four months later. Further surgical intervention including lamellar keratoplasty, cyclodialysis, and cataract extraction permitted this eye to be retained with normal light projection. The fourth patient with a descemetocele experienced a corneal perforation ten days after operation. The flap bulged forward still adherent around the limbus, but a small incision in the flap near the lower limbus allowed the conjunctiva to adhere to the edge of the perforation and uneventful healing followed.

In addition, four eyes were enucleated for other reasons. The first had a severe herpetic keratitis with hypopyon, which had perforated at least seven days preoperatively. The perforation did not heal. Lens and iris prolapsed into the perforation, secondary glaucoma followed, and the eye was ultimately eviscerated. The second, with necrotizing herpetic keratitis, resisted all supportive treatment. The cornea failed to heal following cauterization of the ulcer and application of a total conjunctival flap. A lamellar graft was no more successful and the eye was finally enucleated.

The third was the eye of a patient with endocrine exophthalmos and lagophthalmos. She presented with a large ulcer and hypopyon. The eye did not heal and was ultimately enucleated. The fourth, the eye of a child with retrolental fibroplasia, suddenly developed an enormous corneal hydrops. Lamellar keratectomy was done and a total flap applied, but the cosmetic result was so poor that enucleation was preferred.

FLUID ACCUMULATION BETWEEN THE CORNEA AND OVERLYING CONJUNCTIVA

As mentioned before, four corneas perforated under the conjunctival flap. These perforations were sudden and painful. The fluid was obviously aqueous. A second type of fluid accumulation occurred after a conjunctival flap had been applied for bullous keratopathy without lamellar keratectomy. This accumulation occurred over a period of several weeks or months. After aspiration of the fluid, it

slowly reaccumulated. This was thought to be transcorneal exudation from the anterior chamber. A third type of fluid accumulation has been observed in three patients. The flap had been in position for a longer period, eight months in one instance. The cornea appeared to be healed. The bulging was not as pronounced, usually three to four millimeters over the cornea. On removing the flap, a thicker mucoid fluid was discovered between the cornea and the flap. The pathological sections of the flap showed an abundance of goblet cells in its epithelium and it was presumed that the bulging was due to mucoid secretion and cellular desquamation by the conjunctiva.

All conjunctival flaps that were removed after healing occurred were examined by Doctor Taylor R. Smith, chief pathologist at the Massachusetts Eye and Ear Infirmary. He found that in every instance the conjunctiva covering relatively normal cornea formed epithelium on its under surface, namely that surface that was in contact with the cornea. This space between the cornea and the flap might be considered a synovial space. Only when there was loss of corneal substance through ulceration, cauterization, or surgery did the conjunctiva grow firmly onto the cornea. These facts are illustrated in figures one through four.

RETRACTION OF CONJUNCTIVAL FLAPS

Retraction of the flap occurred in ten eyes, resulting usually from inadequate mobilization of the conjunctiva. It should be pointed out that the operation is more difficult in the aged than in the young, since the conjunctiva is thinner and less elastic in the older individual. In one patient with third-, fourth-, fifth-, sixth-, and seventh-nerve paralysis, complete retraction occurred. Trophic changes were probably responsible.

FORMATION OF CYSTS

Limbal cysts have developed after five operations. They have been single or multiple and have varied in size from three millimeters in diameter to a size that encompassed one-third of the corneal circumference. They have epithelial linings and probably result from tags of conjunctiva left on the corneal limbus at the time of surgery.

FENESTRATIONS IN CONJUNCTIVAL FLAPS

A fenestration in the flap at the time of the operation cannot be repaired successfully. A small hole invariably enlarges and may defeat the purpose of the operation. When a hole is made inadvertently

especially near one side, it has been possible, by increased mobilization of the bridge, to slide the flap toward the side of the perforation and cover the entire cornea with intact conjunctiva. Four such incidents have occurred.

CONCLUSIONS

1. Conjunctival flaps combined with chemical or thermal cauterization appear to be the most effective method of treating severe corneal ulcers caused by herpes simplex, especially where there is loss of substance, loss of sensation, and hypopyon.

2. Peripheral lamellar keratectomy combined with a total conjunctival flap is useful for diffuse bullous keratopathy. It relieves pain, partially dehydrates the central cornea and does not preclude a subsequent penetrating keratoplasty should it become necessary.

3. Regional lamellar keratectomy with an inlay flap of conjunctiva can arrest the progress of bullous keratopathy advancing from the limbus, regardless of its cause.

4. A total conjunctival flap is a safe and effective operation for corneal descemetocele or threatened perforation when due to herpes simplex or other conditions.

5. Total conjunctival covering of the cornea for bullous keratopathy is not advisable without lamellar keratectomy, since accumulation of fluid can occur between the cornea and the overlying conjunctiva.

6. Epithelial cysts will occur around the corneal limbus unless great care is exercised in performing the peritomy.

7. A fall in ocular pressure has been observed after partial lamellar keratectomy. When an inlay flap is used in conjunction with a partial lamellar keratectomy, a wide transcorneal keratotomy can be done under the inlaid conjunctiva. This operation has established permanent drainage in one patient, and this operation for obstinate examples of glaucoma should be studied further.

SUMMARY

This report is a brief review of personal experiences in the use of conjunctival flaps for corneal disease. The senior author began this work while he was a member of the Howe Laboratory of Ophthalmology from 1931 to 1942, and he has continued his interest in the subject since that time. It encompasses a period of thirty-seven years. The work was originally stimulated by the late F. H. Verhoeff.

Conjunctival flaps have been used for generations. They bring to mind such names as Van Lint, Hussaine, and others. Not until the late nineteen-thirties however, was a technique discovered by which conjunctiva could be applied to the cornea as a covering, which would either be permanent or remain in position as long as desired. This series of 177 consecutive operations has been done on private patients, most of whom were referred to us by colleagues in New England. It has been possible to follow these patients both clinically and photographically for periods up to 25 years. More than 35,000 patients have been seen in our offices during this period, and this number gives an idea of the incidence of these particular corneal problems.

It is our firm conviction that the application of a conjunctival flap has an important place in ophthalmic surgery. Its usefulness has been of greatest value in chronic herpetic keratitis when other treatments have failed. Loss of substance, loss of sensation, threatened perforations or hypopyon are particular indications for conjunctivoplasties, especially when combined with chemical or thermal cauterizations. The eyes that were lost were most often those that had perforated prior to, during, or immediately after the operations. It is therefore our firm belief that conjunctival flaps should be applied earlier, before such catastrophies occur.

In bullous keratopathy, lamellar keratectomies – both peripheral with total flap and regional with inlay flap – have been of great value. When bullous keratopathy is diffuse, chronic, and painful, the operation relieves pain and preserves considerable vision. When bullous keratopathy is localized to the corneal periphery, an inlay flap with lamellar keratectomy always retards, and often stops the advancement of corneal edema.

As has been indicated, conjunctival flaps have also been of considerable value in other conditions including neuroparalytic keratopathy from all causes, marginal ulcerations, severe endocrine exophthalmos, filamentary keratopathy, keratitis sicca, and other obstinate corneal diseases. It is an excellent alternative when enucleation is refused.

There is evidence that the intraocular pressure falls after lamellar keratectomy, and, if an inlay flap has been performed, the site of the inlay offers an excellent place for a transcorneal keratotomy. This has produced permanent external filtration.

Fluid accumulations under the flap appear to arise from three sources; namely, perforations of the cornea, transcorneal seepage, or

mucous from goblet cells in the conjunctiva. Pathological studies of removed tissues have confirmed these observations.

Complications have been well documented but most of them can be avoided by meticulous attention to surgical techniques.

The advantages derived from conjunctival flaps seem to far outweigh these disadvantages.

Recent studies on the use of cyanoacrylate adhesives for sealing corneal perforations especially from injuries, show great promise but have not yet stood the test of time. Until their usefulness has been proved, conjunctival flaps still will occupy an important place in the surgical treatment of corneal diseases.

REFERENCES

1. Gundersen, T., Conjunctival flaps in the treatment of corneal disease with reference to a new technique of application. A.M.A. Arch. Ophth., 60: 880–8, 1958.
2. Gundersen, T., Surgical treatment of bullous keratopathy, A.M.A. Arch., Ophth., 64: 260–7, 1960.

DISCUSSION

Dr. John W. McTigue. The usefulness of the flap in severe corneal disease is beyond question and frequently is the only way to save an eye, particularly in advanced herpes simplex keratitis, exposure keratitis, keratitis sicca, absolute glaucoma, and keratomalacia perforans.

It is most important to follow the Gundersen technique carefully and prepare the flaps meticulously. Failure usually results from poor operative technique.

Alternate methods for dealing with some of these same problems are constantly before us. We have had some success with the microcautery of Bowman's membrane, described by DeVoe and others, for advanced bullous keratopathy. It is a simple procedure which can give relief of symptoms comparable to that achieved with the Gundersen flap. Therapeutic lamellar keratoplasty, full thickness corneal implants on a deep lamellar bed, and even penetrating keratoplasties are frequently attempted, at least as initial procedures in many of these cases. The hope is that the same therapeutic results can be obtained as with the flap, at the same time avoiding vascularization and providing significant visual improvement.

In a case of an aphakic eye with an indolent central corneal ulcer which formed a descemetocele, a penetrating graft was done with some success. Occasionally, and I stress this word, keratoplasties are successful depending, of course, on the severity of the condition. At least an attempt can be made with a keratoplasty in some of these cases and, when they fail, the flap can be used as a second procedure.

Currently, we are hearing a great deal about the use of epikeratoprostheses in many of the conditions Dr. Gundersen discussed, and it is certainly a simple procedure. The epithelium is scraped off – it is apparently very important to remove all of the epithelium in these cases – and the prosthesis is glued on with one of the cyanoacrylate monomers.

In a case of a moderately severe corneal edema with vision of finger counting, a prosthesis was applied. Vision of 20/50 resulted after the application of the lens. In a case of keratoconus in which surgery was refused and in which a contact lens or scleral lens could not be fitted, the epikeratoprosthesis was glued on and resulted in 20/80 vision.

In case of traumatic unilateral aphakia in which again a contact lens could not be fitted due to the scarring on the one side, the lens was glued on and 20/20 vision resulted in this eye. However, this procedure does have very definite and possibly severe complications, which are now beginning to appear in this patient.

In a patient we followed with a complete third-nerve paralysis and ptosis, the ptosis was overcorrected, resulting in an exposure keratitis. The lens was glued on and for about two weeks after the vision stayed at about 20/30. Then, an epithelial ingrowth became apparent underneath the lens. When ingrowth became complete, we asked the referring physician, who had put the lens on in the first place, what to do; he advised that we take this off and put another one on.

We found the lens very difficult to remove. The adhesion between the lens and Bowman's membrane is so tight that it required a lamellar keratectomy to remove the lens. We had hoped that we would find a relatively clear stroma under the lens and epithelium, as had been described in the first place, but we found fairly deep stromal scarring still present. A second lens was glued on, and the patient has remained about the same since then.

Our only personal experience with these lenses has been in experimental animals. In rhesus monkeys particularly these lenses do show some deep stromal vascularization, although this has not been reported in human subjects. There are obviously, then, many disadvantages to any alternate technique. Whether or not they are attempted depends upon how extensive a procedure you want to recommend, and of course, the patient's ability to undergo such procedures. Particularly new experimental procedures using foreign materials should be regarded with some caution.

The Gundersen flap is relatively easy on the patient, uses autogenous material and is obviously successful in a large number of cases.

Dr. Harrison R. Pearlson. One of the objections that is brought up in regard to conjunctival flaps is the potential for perforation under the flap, in the immediate postoperative period. This has not been a particular problem in our series of cases. We have had four perforations under the flap, two of which have led to enucleation; two have gone on to heal.

We feel that in the two patients who developed secondary glaucoma, the

secondary glaucoma probably caused the perforation, as these occurred quite late after the conjunctival flap had been applied.

The third patient with perforation had a very severe necrotizing herpetic keratitis and was treated by thermal cauterization and flap. The eye apparently became white and quiet, but for unknown reasons, and apparently without glaucoma, the eye perforated under the flap four months later. Further surgery, including lamellar keratoplasty, cyclodialysis, and cataract extraction permitted this eye to be retained with normal light projection. The fourth patient had a descemetocele, and experienced a corneal perforation 10 days after operation. This is the earliest that we have seen a perforation following a flap operation. This is the same eye that was shown before, where the bulge was taken care of by paracentesis of the aqueous. This eye also healed.

In addition, there were four eyes that were enucleated for other reasons. One eye had perforated seven days before flap surgery, and the perforation did not heal at all. The lens and iris prolapsed into the perforation, and secondary glaucoma followed. The eye was ultimately eviscerated. The second was in a child who had endophthalmitis following an attempt at flap surgery. Lamellar keratoplasty and autograft were attempted unsuccessfully.

The third patient had thyrotropic exophthalmus and lagophthalmus and presented with a very large ulcer and hypopyon. The eye did not heal in spite of a flap and antibiotics, and it was ultimately eviscerated.

The fourth patient had retrolental fibroplasia. An enormous corneal hydrops developed, a lamellar keratectomy was done, and the total flap was applied, but the cosmetic result was so poor that the patient preferred enucleation.

As Dr. Gundersen mentioned, there are three ways that fluid can accumulate underneath the conjunctival flap. The cornea perforated four times under the flap, as I just mentioned, and these perforations, obviously, were sudden and painful. The fluid in this particular case is obviously aqueous.

A second type of fluid accumulation occurred after conjunctival flap had been applied for bullous keratopathy without doing a lamellar keratectomy along with it. This accumulation is more gradual. If this fluid is aspirated, it will slowly reform. It is thought to be a transcorneal exudation from the anterior chamber.

A third type of fluid accumulation has been observed in three patients, and the flap in these particular cases has generally been in position for a much longer period, even up to eight months. This occurred in a white and quiet eye, and the cornea appeared to be healed. The bulging was not as pronounced as was that we saw with Mr. L., and usually it is only 3 or 4 mm over the cornea. On removing the flap in this particular instance, we found a much thicker mucoid material, which was shown to contain both mucoid secretion and cellular desquamation and is obviously from goblet cells that line the inner surface of the flap.

We have also had 10 patients who have had retraction of the flap. This is usually due to inadequate mobilization of the conjunctiva at the time of surgery. It should be pointed out that, again, this is a more difficult operation in the aged than in the young since the conjunctiva is much thinner and less elastic in older patients.

In one particular case where there was a third-, fourth-, fifth-, sixth-, and seventh-nerve paralysis, complete retraction occurred and we feel that this was probably due to tropic changes.

Limbal cysts are also a complication of this technique. We have had five such cystic lesions. They have varied in size from 3 mm to almost a third of the corneal circumference. They all have epithelial linings and probably result from tags of conjunctiva left, as Dr. Gundersen mentioned, right at the limbus at the time of surgery.

Finally, we have had four flaps that have developed fenestrations in them. We feel that probably a small hole was made on one side or the other of the flap. If a small hole is made in the central portion of the flap, it invariably enlarges and may defeat the whole purpose of the operation. But when a hole is made inadvertently, especially to one side or another, it is possible to increasingly mobilize the bridge and slide the flap toward the side of the perforation and cover the entire cornea with intact conjunctiva.

We feel, in general, that conjunctival flaps have an important place in ophthalmic surgery. Their usefulness has been of greatest value in chronic herpetic keratitis when other treatments have failed; where there has been loss of substance, loss of sensation. Threatened perforation or hypopyon are particular indications for conjunctivoplasty, especially when combined with chemical or thermal cautery.

The eyes that were lost, we feel, were most often those that had perforated either prior to operation or after operation, and it is, therefore, our firm belief that conjunctival flaps should be applied earlier, before such catastrophes occur or are imminent.