Case Reports

Phenylpropanolamine and Cerebral Hemorrhage

JAMES R. McDOWELL, MD
HECTOR J. LeBLANC, MD
Olympia, Washington

PHENYLPROPANOLAMINE HYDROCHLORIDE is a sympathomimetic drug, differing from amphetamine by only a hydroxyl group on the β-carbon atom.[1] It is a component of many decongestant and anorectic medications available without prescription.[2] Controversy regarding the safety of these substances centers about reports of adverse reactions, which include hypertension,[3-6] central nervous system stimulation,[1,7] renal failure[8] and cerebral hemorrhage.[9,10] Increasing concern over the significant side effects and abuse potential of phenylpropanolamine has prompted this report of three cases of cerebral hemorrhage in otherwise healthy women in whom no other cause could be found.

(McDowell JR, LeBlanc HJ: Phenylpropanolamine and cerebral hemorrhage. West J Med 1985 May; 142:688-691)

From the Department of Neurology and Neurosurgery, St Peter Hospital, Olympia, Washington.

Submitted April 11, 1984.

Reprint requests to Hector J. LeBlanc, MD, 3525 Ensign Road, Unit N, Olympia, WA 98506.

Reports of Cases

Case 1

The patient, an 18-year-old woman, ingested eight "diet pills," each containing 50 mg of phenylpropanolamine and 200 mg of caffeine. Approximately two hours later she was seen in an emergency room with a blood pressure of 140/90 mm of mercury and a pulse of 52 per minute. Neurologic examination showed no abnormalities. She was given atropine sulfate and a gastric lavage. After discharge she had generalized convulsions and was brought back to the emergency room for admission. She was lethargic but awake and oriented without focal neurologic signs or symptoms. Her past history included normal results on a diagnostic evaluation for headache and obesity at age 12.

There was an abrupt deterioration of her mental state 24 hours after admission. Examination showed total loss of all brain-stem reflexes. Her spinal fluid was grossly bloody. Carotid angiography showed nonfilling of intracranial vessels and the electroencephalogram was isoelectric. Her condition did not improve and, after an appropriate interval, the patient was pronounced dead and respiratory support was withdrawn.

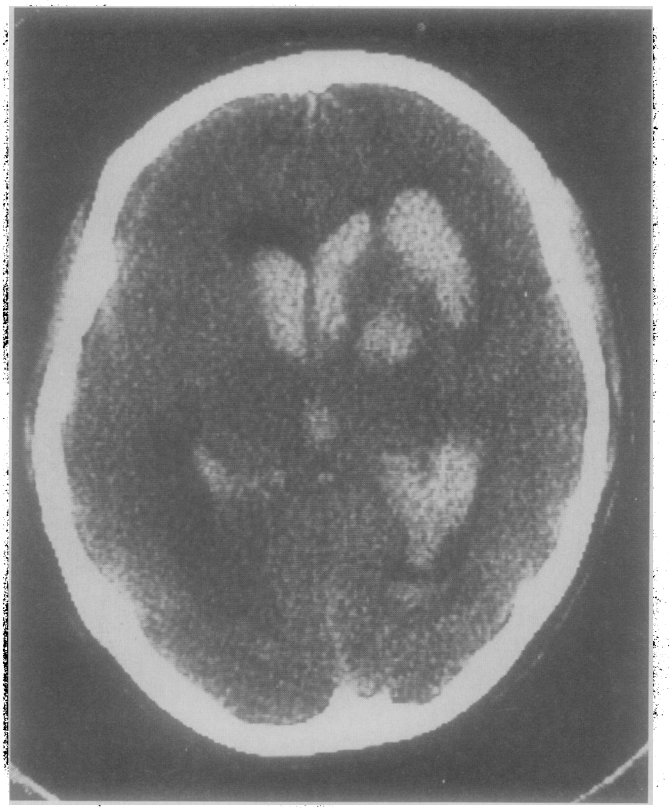

Figure 1.—Case 2. Computed tomographic scan showing intracerebral and intraventricular hemorrhage.

Figure 2.—Case 3. Computed tomographic scan done the day of admission showing deep left intracerebral hemorrhage.

Postmortem examination showed a right intracerebral hematoma with rupture into the lateral ventricle and subarachnoid space. There was diffuse brain swelling with tonsillar and transtentorial herniation. Detailed neuropathologic examination failed to identify a source of bleeding and microscopic examination showed no abnormalities of the cerebral arteries.

Case 2

A 45-year-old woman took a combination of aspirin and antacid for an upset stomach. Several hours later a headache and neck discomfort developed. She went to sleep and could not be aroused by her family two hours later. Paramedics were summoned who found her to be agitated but on arrival at the emergency department she was comatose with slowly reacting midposition pupils. She was breathing spontaneously with a blood pressure of 150 mm of mercury systolic. Her condition deteriorated rapidly over the next hour to apnea, anisocoria, then pupillary dilatation and unreactivity. She was hyperreflexic and decerebrate on the left side and soon lost all brainstem reflexes with ensuing apnea and flaccidity. A computed tomographic (CT) scan showed intracerebral and intraventricular hemorrhage (Figure 1). An electroencephalogram showed no activity of cerebral origin and, after an appropriate interval with no clinical change, the patient was pronounced dead.

The patient's previous health had been excellent. There was no history of smoking or hypertension. She had been taking phenelzine sulfate (Nardil), 15 mg three times a day, for chronic depression. The morning of her ictus she had taken for the first time two anorectic tablets, each containing 50 mg of phenylpropanolamine.

Postmortem examination showed a large right putaminal hemorrhage with extension into the globus pallidus and anterior horn of the right lateral ventricle. There was tonsillar and transtentorial herniation. Detailed neuropathologic examination failed to show a bleeding source and the cerebral arteries appeared normal on microscopic examination.

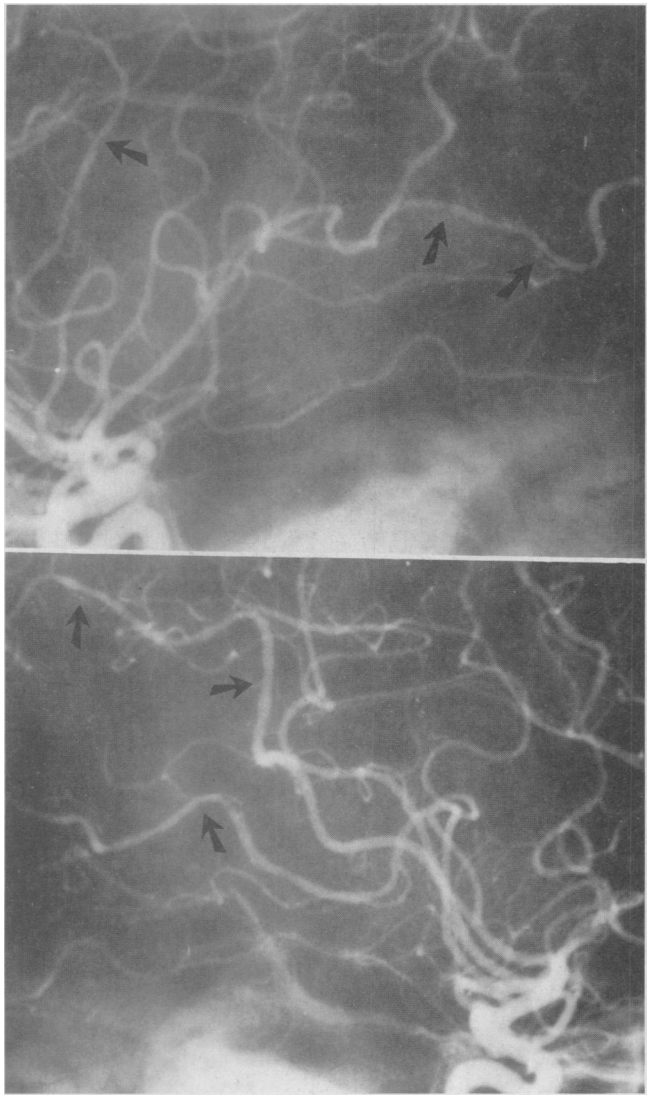

Figure 3.—Case 3. Carotid angiograms done shortly after admission showing segmental spasm **(arrows)** of distal branches of the middle cerebral artery. **Top,** Right carotid angiogram. **Bottom,** Left carotid angiogram.

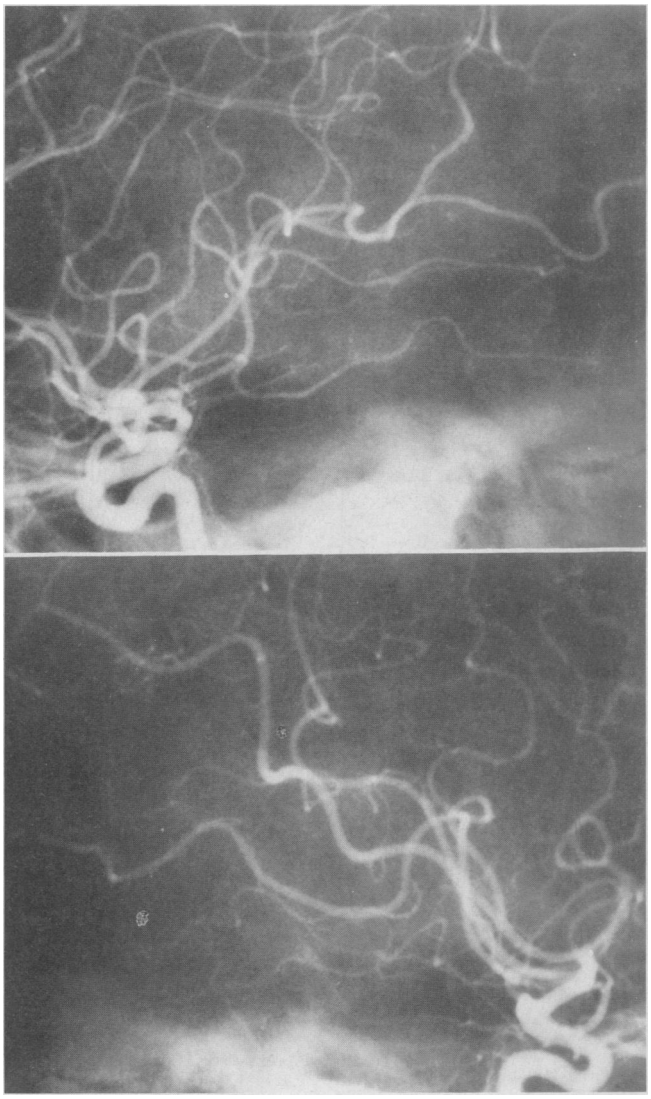

Figure 4.—Case 3. Carotid angiograms done a month later with no further evidence of spasm. **Top,** Right carotid angiogram. **Bottom,** Left carotid angiogram.

Case 3

The patient, a 23-year-old woman, had a severe headache while driving home from work. Subsequently, her behavior became erratic and she was brought to the hospital where she was found to have right hemiparesis. She was otherwise in good health with no history of hypertension or drug abuse. A CT scan showed a deep left intracerebral hemorrhage (Figure 2). A retrograde femoral three-vessel cerebral angiogram showed no bleeding source, but there were areas of beading and irregularity of the diameters of several cerebral vessels (Figure 3).

Earlier that day she had taken two tablets of a proprietary "cold remedy," each containing acetaminophen, chlorpheniramine and 25 mg of phenylpropanolamine. Continued diagnostic evaluation included search for blood dyscrasia, collagen vascular disease, clotting disorder and evidence of latent or paroxysmal hypertension, but no abnormalities were found. The patient's course was one of pronounced improvement with only minimal hemiparesis and dysphasia detectable two weeks after onset. Repeat angiography one month later was normal (Figure 4), showing no bleeding source and interval clearing of the previously seen segmental narrowing.

Discussion

These three patients all had spontaneous intracerebral hemorrhages, two of which resulted in a fatal outcome. All three occurred in relatively healthy young women without an antecedent history of neurologic illness or hypertension. In the two fatal cases, a detailed postmortem examination of the brain failed to show a bleeding source such as aneurysm or arteriovenous malformation. The cerebral vessels were normal on microscopic examination. In one nonfatal case, angiography similarly failed to show a bleeding source but did show an irregularity of multiple cerebral vessels; this radiographic finding cleared completely with clinical recovery.

The temporal association of phenylpropanolamine ingestion and spontaneous intracerebral hemorrhage in these cases suggests a causal relationship. All three patients had taken drugs containing phenylpropanolamine the day of their hem-

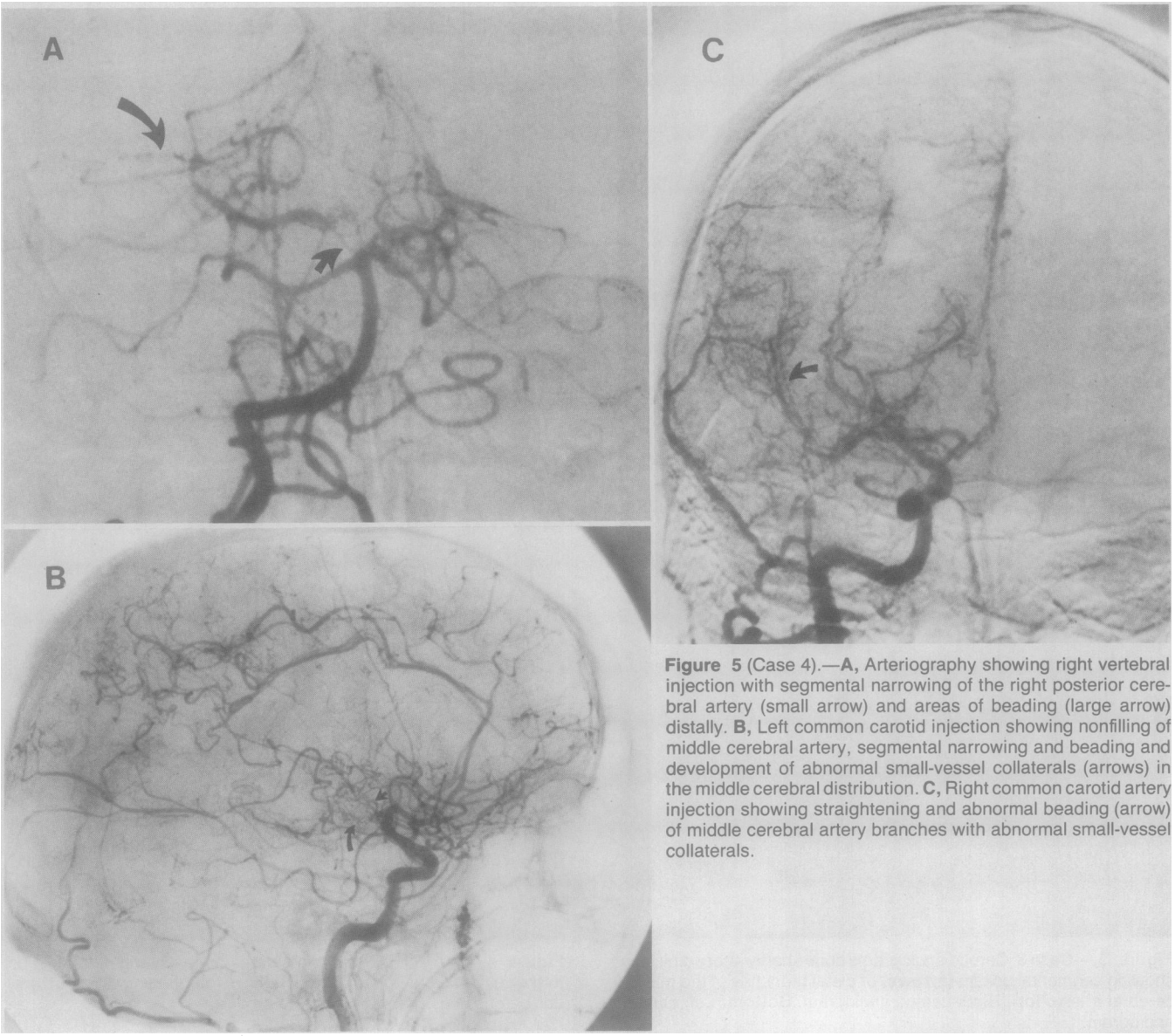

Figure 5 (Case 4).—**A,** Arteriography showing right vertebral injection with segmental narrowing of the right posterior cerebral artery (small arrow) and areas of beading (large arrow) distally. **B,** Left common carotid injection showing nonfilling of middle cerebral artery, segmental narrowing and beading and development of abnormal small-vessel collaterals (arrows) in the middle cerebral distribution. **C,** Right common carotid artery injection showing straightening and abnormal beading (arrow) of middle cerebral artery branches with abnormal small-vessel collaterals.

orrhage in amounts ranging from 50 to 400 mg. There were no signs of chronic hypertension found at autopsy of the two fatal cases, nor was there a history of hypertension in any of the three cases. No hypertension was noted on follow-up of case 3. Potentiation of the hypertensive sympathomimetic effect of phenylpropanolamine by a monoamine-oxidase inhibitor was a possible factor in case 2. Drug interactions between phenylpropanolamine and monoamine-oxidase inhibitors,[3] thioridazine hydrochloride[11] and indomethacin,[6] have been previously reported.

Hypertensive responses to phenylpropanolamine have been shown experimentally,[1] and hypertension has been part of the constellation of adverse reactions to phenylpropanolamine in clinical situations. Other prominent features have been headaches, seizures and changes in mental state.[7] Cerebral hemorrhage in association with phenylpropanolamine has been reported previously in only three cases.[9,10]

The angiographic picture in case 3 is similar to that previously described in association with amphetamine abuse and pseudoephedrine overdose,[12-14] both substances being chemically and pharmacologically similar to phenylpropanolamine. The reversal of these radiographic changes combined with the normal findings on pathologic examination of cerebral arteries in cases 1 and 2 suggests that the arterial change responsible for symptoms may be dynamic rather than anatomic, namely, spasm rather than arteriopathy.

Addendum

Since this paper was written, we have seen an additional very similar case.

Case 4

A 59-year-old woman had the abrupt onset of headache and nausea while eating lunch. Right hemiplegia rapidly developed and she became unresponsive. On examination, the patient was moderately overweight, had a blood pressure of 130/80 mm of mercury and frequent premature ventricular beats. She was mute but withdrew from painful stimulation. Brain-stem reflexes were intact and fundi were normal. A CT scan showed hemorrhage originating in the thalmus adjacent to the third ventricle with rupture into the ventricular system. Three-vessel arteriography showed multiple abnormalities in the intracranial vessels with segmental stenoses, beading and nonfilling of several branches (Figure 5). These changes were present in several areas, some quite distant from the site of hemorrhage. The patient's condition gradually improved and she was discharged to an extended care facility after three weeks in hospital. By that time, she could sit in a chair and was awake but mute, with a dense right hemianopia and right hemiplegia.

Ten years before admission to hospital, the patient had a right ventriculoperitoneal shunt because of the development of abnormal speech, gait and mentation. Before her acute illness, she was ambulatory and independent in the activities of daily living. She was a heavy smoker and was taking a "diet pill" daily containing 75 mg of phenylpropanolamine. Past medical history was otherwise unremarkable. She was found to have had an old diaphragmatic myocardial infarct and some chronic obstructive pulmonary disease.

REFERENCES

1. Dietz AJ Jr: Amphetamine-like reactions to phenylpropanolamine. JAMA 1981 Feb 13; 245:601-602
2. Blum A: Phenylpropanolamine:An over-the-counter amphetamine?(Editorial). JAMA 1981 Apr 3; 245:1346-1347
3. Cuthbert MF, Greenberg AM, Morley SW: Cough and cold remedies: A potential danger to patients on monamine oxidase inhibitors. Br Med J 1969 Feb 15; 1:404-406
4. Frewin DB, Leonello PP, Frewin ME: Hypertension after ingestion of trimolets. Med J Aust 1978 Nov; 2:497-498
5. Horowitz JD, Lang WJ, Howes LG, et al: Hypertensive responses induced by phenylpropanolamine in anorectic and decongestant preparations. Lancet 1980 Jan 12; 1:60-61
6. Lee KY, Bielin LJ, Vandongen R: Severe hypertension after ingestion of an appetite suppressant (phenylpropanolamine)with indomethacin. Lancet 1979 May 26; 1:1110-1111
7. Mueller SM: Neurologic complications of phenylpropanolamine use. Neurology (NY) 1983 May; 33:650-652
8. Bennett WM: Hazards of the appetite suppressant phenylpropanolamine (Letter). Lancet 1979 Jul; 2:42-43
9. Bernstein E, Disdant BM: Phenylpropanolamine:A potentially hazardous drug. Ann Emerg Med 1982 Jun; 11:311-315
10. King J: Hypertension and cerebral haemorrhage after trimolets ingestion (Letter). Med J Aust 1979 Sep; 2:258
11. Chouinard G, Ghadirian AM, Jones BD: Death attributed to ventricular arrhythmia induced by thioridazine in combination with a single Contac C capsule. Can Med Assoc J 1978 Oct; 119:729-730
12. Citron BP, Halpern M, McCarron M, et al: Necrotizing angiitis associated with drug abuse. N Engl J Med 1970 Nov; 283:1003-1011
13. Margolis MT, Newton TH: Methamphetamine ('speed') arteritis. Neuroradiology 1971 Aug; 2:179-182
14. Kessler JT, Jortner BS, Adapon BD: Cerebral vasculitis in a drug abuser. J Clin Psychiatry 1978 Jun; 39:559-564

Septic Arthritis and Osteomyelitis of the Symphysis Pubis (Osteitis Pubis) From Intravenous Drug Use

GREGORY J. MAGARIAN, MD
JAMES B. REULER, MD
Portland

IN FOUR recently published series of infectious arthritis, synovial joints have typically been involved, usually in cases of prior joint damage from arthritis or trauma, joint replacement by prostheses, bacteremia from extraarticular infections with secondary hematogenous seeding of distant sites, prior use of immunosuppressive drugs or the presence of other debilitating conditions such as alcoholism, diabetes mellitus or malignant tumors.[1-4] Microbial organisms responsible for nongonococcal pyogenic arthritis in adults in these studies have most commonly been *Staphylococcus aureus* and other Gram-positive organisms and, much less commonly, Gram-negative or anaerobic organisms.[1-4] *Pseudomonas aeruginosa* was the responsible agent in only 12 of 218 patients reported in these combined series [1-4] and in only 1 of 12 cases of Gram-negative arthritis reported by Goldenberg and co-workers.[5]

Though these studies were from large metropolitan

(Magarian GJ, Reuler JB: Septic arthritis and osteomyelitis of the symphysis pubis (osteitis pubis) from intravenous drug use. West J Med 1985 May; 142:691-694)

From the Department of Medicine, Division of General Internal Medicine, The Oregon Health Sciences University, and Ambulatory Care and Medical Services, Veterans Administration Medical Center, Portland.

This study was supported in part by US Department of Health, Education and Welfare grant No. 1-029-PE10051-02.

Submitted April 17, 1984.

Reprint requests to Gregory J. Magarian, MD, Ambulatory Care Service (11C-P), VA Medical Center, 3710 SW US Veterans Hospital Road, Portland, OR 97207.