Am. J. Hum. Genet. 77:653–660, 2005

Report

Loss of Desmoplakin Tail Causes Lethal Acantholytic Epidermolysis Bullosa*

Marcel F. Jonkman,[1] Anna M. G. Pasmooij,[1] Suzanne G. M. A. Pasmans,[5] Maarten P. van den Berg,[2] Henk J. ter Horst,[3] Albertus Timmer,[4] and Hendri H. Pas[1]

Departments of [1]Dermatology, [2]Cardiology, [3]Pediatrics, and [4]Pathology, University Medical Centre Groningen, University of Groningen, Groningen, the Netherlands; and the [5]Department of Dermatology, University Medical Centre Utrecht, University of Utrecht, Utrecht, the Netherlands

The cytoplasmic plaque protein desmoplakin (DP), which is located in desmosomes, plays a major role in epithelial and muscle cell adhesion by linking the transmembrane cadherins to the cytoplasmic intermediate filament network. Mutations of DP may cause striate palmoplantar keratoderma, arrhythmogenic right ventricular dysplasia, skin fragility/woolly hair syndrome, Naxos-like disease, and Carvajal syndrome. DP must be indispensable, because DP-/- mice are early abortive. Here, we report a patient with severe fragility of skin and mucous membranes caused by genetic truncation of the DP tail. The new phenotype is lethal in the neonatal period because of immense transcutaneous fluid loss. The phenotype also comprised universal alopecia, neonatal teeth, and nail loss. Histology showed suprabasal clefting and acantholysis throughout the spinous layer, mimicking pemphigus. Electron microscopy revealed disconnection of keratin intermediate filaments from desmosomes. Immunofluorescence staining of DP showed a distinct punctate intercellular pattern in the patient's skin. Protein analysis revealed expression of truncated DP polypeptides. Mutational analysis of the patient demonstrated compound heterozygosity for two DP mutations, 6079C→T (R1934X) and 6370delTT, respectively. Aberrant mRNA transcripts that predict premature termination of translation with loss of the three intermediate filament-binding subdomains in the DP tail were detected by RT-PCR. The new dramatic phenotype, which we named "lethal acantholytic epidermolysis bullosa," underscores the paramount role of DP in epidermal integrity.

Desmoplakin (DP) is a cytoplasmic plaque protein that is located in desmosomes, which are abundant in tissues subjected to mechanical stress, like muscle and epidermis. The role of DP is to link the transmembrane cadherins via plakoglobin to the cytoplasmic intermediate filament network (Kowalczyk et al. 1997; Smith and Fuchs 1998). DP comprises an N-terminal, desmosome-associated plakin domain binding to plakoglobin and plakophilin (Smith and Fuchs 1998), a central coiled-coil rod domain responsible for dimerization, and a C-terminal domain consisting of three homologous plakin repeat subdomains, named "A," "B," and "C," that interact with the intermediate filaments (Choi et al. 2002). Alternative splicing generates two isoforms (DP I and DP II) that differ in their rod domain lengths, with relative molecular weights of 332 kDa and 259 kDa, respectively (Green et al. 1988).

Mutations in desmoplakin can cause cardiocutaneous syndromes (for review, see Cheong et al. 2005). Haplotype insufficiency of DP may cause striate palmoplantar keratoderma (PPK [MIM 125647]) (Armstrong et al. 1999; Whittock et al. 1999), whereas dominant missense mutations in the N-terminal domain may cause arrhythmogenic right ventricular dysplasia (ARVD [MIM 607450]) (Rampazzo et al. 2002). A nonsense mutation in the N-terminal domain combined with a recessive missense mutation causes skin fragility/woolly hair syndrome with striate PPK [MIM 607655] (Whittock et al. 2002), whereas a homozygous recessive missense mutation in the B-subdomain causes ARVD, woolly hair, and acral skin blistering (Naxos-like dis-

Received May 31, 2005; accepted for publication July 26, 2005; electronically published August 17, 2005.

Address for correspondence and reprints: Prof. M. F. Jonkman, Department of Dermatology, University Medical Centre Groningen, P.O. Box 30.001, 9700 RB Groningen, the Netherlands. E-mail: m.f.jonkman@med.umcg.nl

* Part of this study was presented at the 12th Scientific Meeting "The Keratinocyte: Inter- and Extracellular Events" of the Fondation René Touraine for Research in Dermatology, in Paris, November 5, 2004 (Jonkman 2004).

© 2005 by The American Society of Human Genetics. All rights reserved.
0002-9297/2005/7704-0014$15.00

ease) (Alcalai et al. 2003), and a homozygous truncatious mutation in the C-terminus causes left ventricular cardiomyopathy, woolly hair, and PPK (Carvajal syndrome [MIM 605676]) (Norgett et al. 2000). DP must be indispensable, because DP-/- mice are early abortive (Gallicano et al. 1998).

Here, we report on the identification of a patient who was compound heterozygous for DP mutations that truncated the protein with an almost complete loss of the intermediate filament-binding domains. The tailless DP caused a new human phenotype, which we name "lethal acantholytic epidermolysis bullosa."

The subject in the present study was a male term newborn referred to the Centre for Blistering Diseases in Groningen, Netherlands, on the 2nd day postpartum because of rapidly progressive generalized epidermolysis. The epidermolysis started during delivery. The area of epidermolysis progressed from 30% to 70% within the 1st day. The patient was the first child of nonconsanguineous parents. Skin fragility, palmoplantar keratoderma, hair abnormalities, and sudden cardiac death were not known in the parents' families. The mother's pregnancy was uneventful. The parents had neither woolly hair nor palmoplantar keratoderma. Screening of the parents for cardiomyopathy by electrocardiography, echocardiography, and magnetic resonance imaging was negative. Appropriate informed consent for publication was obtained from the parents.

At first admittance, we saw a distressed, nondysmorphic child with skin erosions covering 70% of the body surface area (fig. 1*A*). The skin loosened extremely easily by Nikolsky's sign. Large sheets of skin were detached, leaving superficial, not bleeding, dull, intense red wound surfaces (fig. 1*B*). We did not see intact blisters or vesicles. Signs of re-epithelialization were observed, but the new epithelium rapidly detached again. A horseshoe-shaped, re-epithelialized erosion extended from cheek to cheek (fig. 1*C*). The skin on the hands and feet had detached in glove and sock pattern (fig. 1*E* and 1*F*). The skin on the forehead and frontal scalp remained attached (fig. 1*A* and 1*B*). There was no hypergranulation tissue. At the elbows, wrists, knees, and ankles, cutis aplasia with a shimmering vascular pattern was observed.

Further examination revealed a complete absence of scalp hairs, eyebrows, cilia, and vellus hairs (universal alopecia), although we discerned follicular openings on the skin of the scalp (fig. 1*C*). All 20 nails had recently shed; the impressions of the nail plates in the nail beds were still visible (fig. 1*E* and 1*F*). The child had three triangular neonatal teeth in the mandibula (fig. 1*D*). The oral cavity and conjunctivae were erosive. The glans penis was affected, and a pseudophimosis had occurred. The fingers of one hand had minimal pseudosyndactyly due to juxtaposed erosions. The distal phalanges of the hand were tapered. Toes were long and spread wide, with a sandal gap and globular distal phalanges.

The child was hospitalized in the neonatal intensive care unit.The skin erosions rapidly extended to 90% by the 5th day. X-ray of the abdomen and ultrasound examination revealed no signs of pyloric atresia or other passage restrictions of the digestive tract. No other abnormalities were observed. There were neither clinical signs nor cultures indicative of infection. The child was

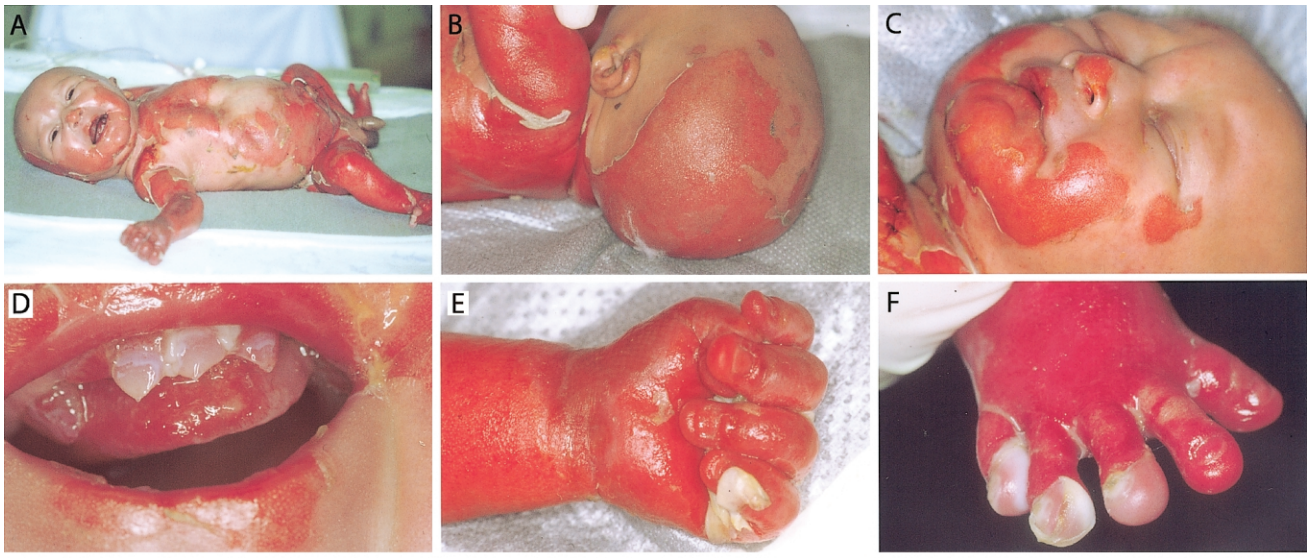

Figure 1 Clinical presentation of day 1. *A*, *B*, Generalized skin erosions covering 70% of the body surface area. *B*, *C*, Universal alopecia. *D*, neonatal teeth. *E* and *F*, Eroded skin of the hands and feet, respectively, with complete nail loss.

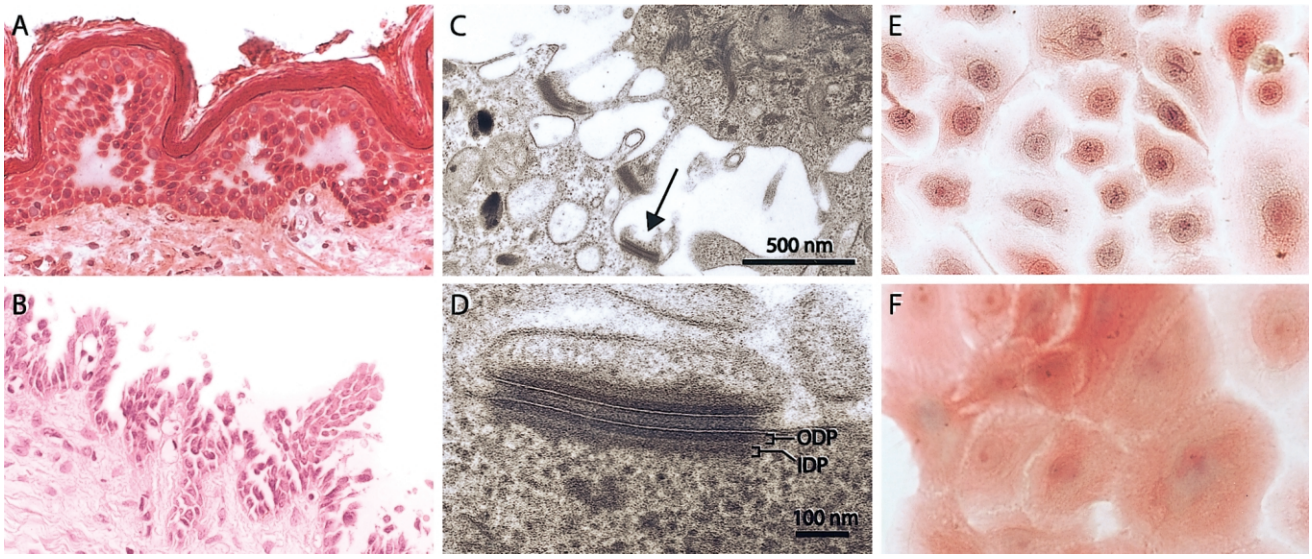

Figure 2 *A,* Histopathology of skin showing suprabasal clefting and acantholysis throughout the spinous layer, leaving a row of basal keratinocytes ("tombstones") on the (*B*) blister floor (objective 40 times). *C,* Electron microscopy revealed that the desmosomal connection remained intact while the plasma membrane was stretched to its limits until intracellular cleavage occurred behind the desmosomal plaque, which was torn from the cell body (*arrow*). *D,* Desmosome, lacking bound intermediate filaments, contained an inner (IDP) and outer (ODP) dense plaque of normal thickness. *E* and *F,* Cultures of patient's keratinocytes show loosened cell-to-cell contacts (spongiosis representing early acantholysis) compared with the close apposition between control human keratinocytes.

fed by gastronasal tube. Pain was treated by morphine and fentanyl, and the infant was sedated by means of midazolam. Micurition started slowly and a suprapubic catheter was inserted. The child lost profuse amounts of fluid from the extensive skin erosions. The erosions were covered by an absorbing, non-adhesive wound covering, Mepitel, with Aquacell on top fixated by tube bandage and Elastomull Haft. A fluid intake of 450–500 ml/kg/day (N = up to 150 ml/kg/day) and infusion of albumen (3 g/kg/day) were necessary to compensate for immense transcutaneous fluid losses, estimated at 350 ml/kg/day, and to establish urine output of at least 0.5 ml/kg/hr (N = 1–6 ml/kg/hr). Within days, the face and body had swollen, and ascites developed. Pulmonary tube ventilation was necessary. Skin cultures contained no microorganisms. In a final attempt to stop the persistent oozing from the wounds, fibrin glue (Tissuecoll) was sprayed over the body surface. The polymerized glue did not attach to the oozing wound surface. Ten days postpartum, the child died.

Permission for autopsy was obtained. Examination showed an edematous male neonate with bilateral pleural effusion and ascites. Body measurements were appropriate for a corrected gestational age of 41 wk. The epidermis demonstrated very extensive (>90%) suprabasal acantholytic separation with desquamation. At the site of the nail bed, a focal residue of matrix was encountered. The suprabasal epithelium of the mouth, epiglottis, and larynx had been lost. Structural anomalies of internal organs were not found. The microscopic anatomy of epithelia was abnormal. Predominantly in the lung, gastrointestinal tract, and bladder, epithelial integrity revealed loss of cell-to-cell adhesion and detachment of epithelial cells from the basement membrane. The significance of these observations is uncertain, as loss of epithelial integrity may be due to postmortem autolysis. The heart was dilated possibly because of overfilling. On microscopy, focal subepicardial coagulative necrosis was noticed, but there were no signs of cardiomyopathy. The cause of death was multiorgan failure precipitated by secondary heart failure, probably induced by tremendous amounts of intravenous fluid supplementation that were needed to compensate for excessive transcutaneous water loss. The skin blistering that was fatal early in life may have precluded later development of palmoplantar keratoderma and cardiomyopathy.

Histopathology of the skin showed suprabasal clefting (fig. 2*A*), leaving basal cells attached to the blister floor like a row of tombstones (fig. 2*B*). The spinous layer showed spongiosis (widening of the intercellular space) and acantholysis, looking like a "dilapidated brick wall" (fig. 2*A*), which extended into hair follicles and eccrine ducts. The histopathology mimicked that of pemphigus vulgaris.

Electron microscopic examination of the skin revealed perinuclear retraction of intermediate filaments that had disconnected from the inner dense plaque of desmosomes (fig. 2*C* and 2*D*) in all layers of the epider-

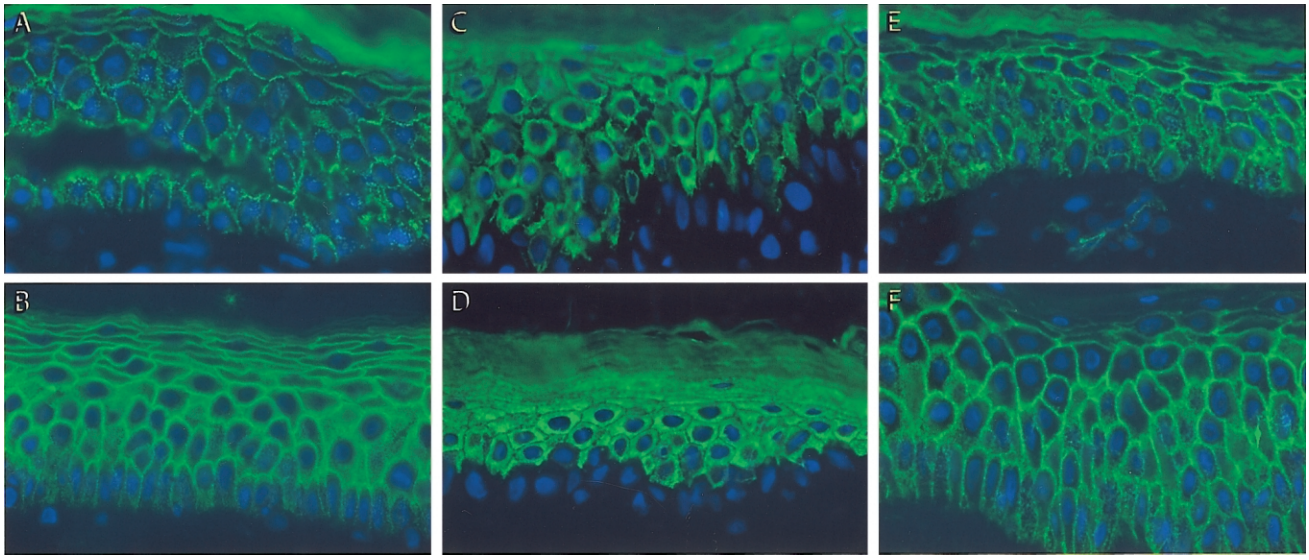

Figure 3 Immunofluorescence with monoclonal antibodies of patient's skin (*A*, *C*, and *E*) and age-matched human control skin (*B*, *D*, and *F*). Desmoplakin I/II in the patient shows a more punctate intercellular staining (*A*) than in human control skin (*B*). Note the suprabasal clefting in the patient (*A*). The suprabasal keratin 10 is retracted around nuclei in the patient (*C*) as compared with a control subject (*D*). The adherens junction component β-catenin (9G2) has a similar fine granular intercellular staining pattern in patient skin (*E*) and control skin (*F*).

mis. The desmosomes, lacking the cytoskeleton reinforcement, sheared out of the cell membrane (fig. 2*C*). Desmosomes appeared normal in number and were normal in diameter: mean 355 $\pm$ 100 nm (control 366.2 $\pm$ 6.9 nm) (McMillan et al. 2003). The thickness of the desmosome substructures, with normal values according to North et al. (1999), were as follows (fig. 2*D*): inner dense plaque 24 nm (N = 15–20 nm), electron-lucent zone 3 nm (N = 10 nm), outer dense plaque 19 nm (N = 15–20), total plaque thickness 46 nm (N = up to 50 nm), and interplasma membrane distance 30 nm (N = 30 nm). Hemidesmosomes were structurally normal.

In vitro serum free cultures of the patient's keratinocytes exhibited few and meager sites of intercellular contact (fig. 2*E*).

Routine immunofluorescence examination of the patient's skin revealed no immunodepositions, and routine antimapping revealed normal staining of pan-keratin, laminin 5, and type VII collagen and suprabasal blister formation. Indirect immunofluorescence for circulating pemphigus antibodies was negative. ELISA for circulating anti-desmoglein 1 and 3 antibodies was negative.

Immunofluorescence examination of the patient's skin—performed after the child had died, using a large panel of antibodies against β-catenin; γ-catenin/plakoglobin; type VII collagen; type XVII collagen; desmocollins 1, 2a/b, 3; desmogleins 1, 2, 3, 4; desmoplakin I/II; desmoyokin/ahnak; integrins α2, β1; keratins 1, 10, 2e, 5, 14; laminin 5; M3 muscarinic acetylcholine receptor; nicotinic alpha3 acetylcholine receptor; plakophilins 1, 2a/b, 3, 4/p0071; plectin/HD1; and tetraspanin/CD151—all demonstrated unreduced staining, except for the intercellular staining of desmosomal proteins that was more punctated (desmoplakin, plakoglobin, plakophilins, desmogleins, and desmocollins) (fig. 3*A*). The interference of intermediate filament binding was witnessed by perinuclear retraction of keratin filaments (fig. 3*C*). The desmosomal defects did not affect the level or the pattern of expression of the adherens junction component β-catenin (fig. 3*E*).

The strategy for finding the candidate gene by immunofluorescence analysis using monoclonal antibodies for desmosome components with expected loss-of-function mutation was not that helpful. Although this strategy might work in most hemidesmosome disorders, it distracted from our search for the cause of this desmosomal disorder. The clue that led us to DP was the observation by electron microscopy that the keratin intermediate filaments were disconnected from the inner dense plaque, similar to that in DP knockout mice and in skin fragility/woolly hair syndrome (Vasioukhin et al. 2001; Whittock et al. 2002).

Mutation screening of the patient's genomic DNA, isolated from peripheral blood, was performed by direct sequencing of the 24 exons of the desmoplakin gene (*DSP*), with primers and conditions described elsewhere (Whittock et al. 1999). Each *DSP* exon was PCR amplified and purified (QIAquick PCR purification kit, Qiagen), and 100 ng of the purified PCR products was sequenced using DyeTerminator chemistry (Amersham

Biosciences) on a MegaBACE 1000 sequencer (Amersham Biosciences). Two heterozygous mutations in exon 24 were identified in the proband, a nonsense mutation (C6079T; R1934X) at position 6079 (GenBank accession number M77830), and a deletion of two nucleotides, 6370delTT. This latter mutation causes a frameshift and results in a novel sequence beginning at amino acid 2031 and leading to a premature termination codon at position 2058. Both parents were heterozygous carriers, the father of the C6079T mutation and the mother of the 6370delTT deletion (fig. 4).

RT-PCR performed on cultured keratinocytes and followed by direct sequencing showed that both nonsense allele transcripts were detectable in the proband. Therefore, the mutations did not result in desmoplakin haploinsufficiency by nonsense-mediated mRNA decay, which is consistent with the presence of immunoreactive desmoplakin in the skin. Instead, two mRNA transcripts were present, both coding for DP proteins with a truncated C-terminal tail, one truncated at the end of the rod domain (1–1933) and missing all three intermediate filament-binding subdomains, and the other truncated shortly after the start of subdomain A (1–2031+28 missense) and still containing the first 71 residues of this domain (1960–2208).

Immunoblot of extracts of the patient's cultured keratinocytes with monoclonal antibody DP2.17, specific for the 332-kDa isoform desmoplakin I, revealed the absence of the DP I protein band in the keratinocytes of the patient. Instead, two aberrant DP I molecules with a higher mobility were detected, which is in line with the prediction of smaller proteins made on the basis of the mRNA transcripts (fig. 5, lane 2). Extracts of the parents' cultured keratinocytes demonstrated, as expected, wild-type DP I in conjunction with a truncated DP I polypeptide with higher mobility (fig. 5, lanes 3 and 4).

The severe fragility of the skin and mucous membranes was fatal for the child. The skin fragility was accompanied by universal alopecia, nail loss, and neonatal teeth. At the histological level, the disorder is characterized by acantholysis. The exact split level, however, was intracellular between the inner dense plaque of the desmosome and the cytoskeleton. To the best of our knowledge, the presented phenotype with lethal acantholytic epidermolysis bullosa has not been reported before.

The term "acantholytic epidermolysis bullosa" has been used to denote mild acral blistering in a single family (Hoffman et al. 1995). This autosomal dominant bullous disorder, however, was less severe than the presented case and comprised mild, late-onset blistering confined to hands and feet, with histological features that remind us of our case: suprabasal clefting with acantholysis. The molecular pathology of that pedigree has not been determined, nor have there been any other clinical reports of such a disease phenotype.

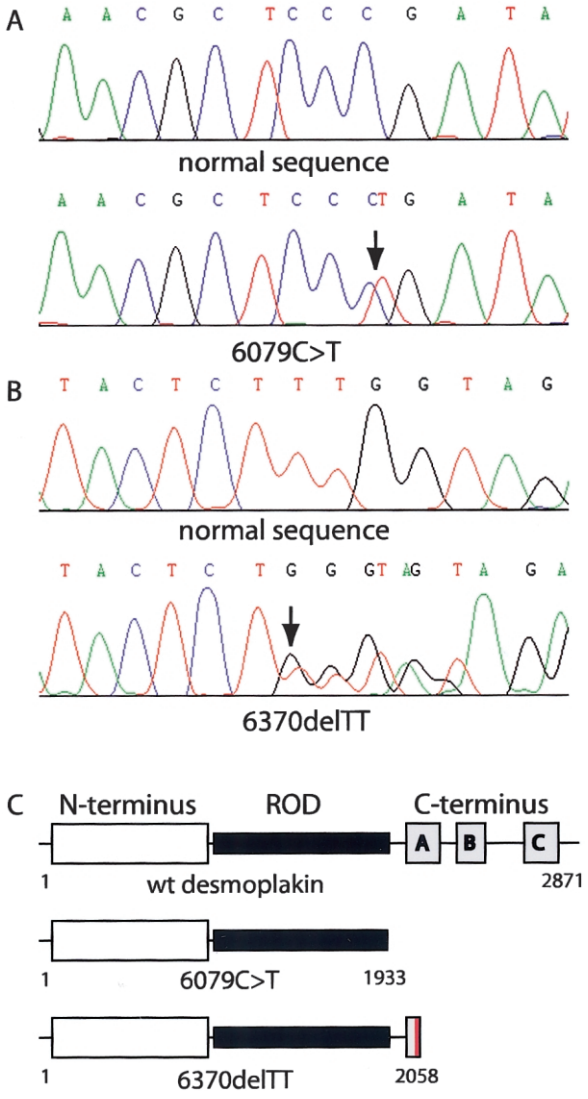

Figure 4 Mutations in exon 24 of the *DSP* gene in the patient and his parents. *A*, Automated sequence analysis of the patient's and his father's DNA revealed a heterozygous C→T transition at nucleotide position 6079 of the cDNA (*lower panel*). The mutation was not present in the mother and a control (*upper panel*). *B*, A heterozygous frame-shift mutation, 6370delTT, was disclosed by nucleotide sequencing in the patient's and his mother's DNA (*lower panel*). This deletion was not present in the father and a control (*upper panel*). *C*, The DP protein comprises an N-terminus, a central rod-domain and a C-terminus implicated in the binding with the intermediate filaments by the subdomains A, B, and C. The paternal allele results in a DP protein of 1933 amino acids lacking all three subdomains. The maternal allele leads to a truncated protein of 2,058 amino acids, from which the last 28 amino acids are aberrant from the wild-type protein sequence (*red*).

The phenotype had some similarity with skin fragility/ectodermal dysplasia syndrome (MIM 604536), a rare

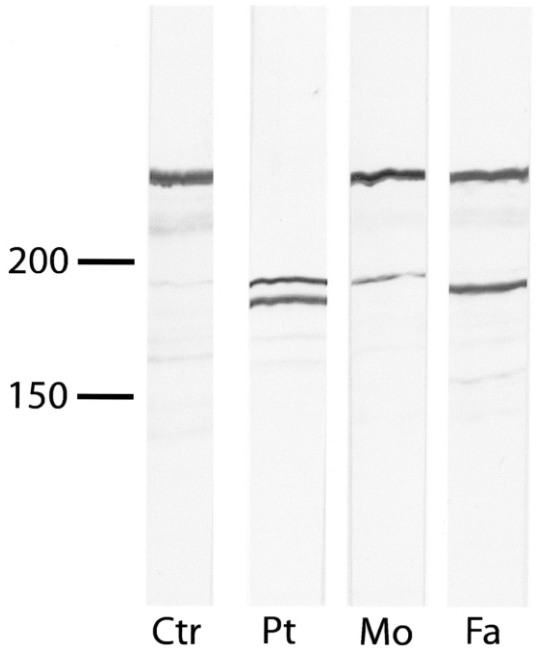

Figure 5 Immunoblot staining for desmoplakin I demonstrating two different truncated DP I forms in the patient's cells. Extracts of keratinocytes cultured from the patient (Pt), the mother (Mo), the father (Fa), and a normal human control (Ctr) were separated on 5% SDS-PAGE slab gels, electroblotted, and stained with DP I-specific monoclonal 2.17. *Left,* molecular markers 150 and 200 kDa. The mRNA-computed molecular weights for the truncated forms are 228 kDa and 243 kDa, versus 332 kDa for the wild-type protein. Note that all proteins run slightly faster than deduced from the nucleotide sequences in line with earlier observations (Green et al. 1990).

autosomal recessive disease that is due to mutations in the gene encoding the critical desmosomal plaque protein plakophilin 1 and that manifests with skin fragility, fissuring palmoplantar keratoderma, abnormal hair growth, nail dystrophy, and, in some cases, defective sweating (McGrath et al. 1997). The characteristic histopathology of acantholysis increasing in an upward direction in the epidermis was not present in our case, where the acantholysis was increasing in a downward direction.

The histopathology with acantholysis was reminiscent of that observed in Hailey-Hailey disease (benign familial pemphigus [MIM 169600]), although here the adnexa were spared, in contrast to our case. We considered the possibility that our patient was suffering from a theoretical recessive congenital variant of benign familial pemphigus Hailey-Hailey disease with complete loss of the *ATP2C1* polypeptide, but this appeared not to be the case, as witnessed by normal SPCA1 staining of cultured keratinocytes (P. Arvan).

At first impression, the clinical phenotype was also reminiscent of neonatal pemphigus, which also displays suprabasal acantholysis with basal cells standing apart like tombstones. The mother, however, was not affected by pemphigus, and no antibody reactivity against keratinocytes could be detected in the patient's skin and serum.

The autoimmune analogue of this genetic desmoplakin disorder, mucosal dominant pemphigus vulgaris with anti-desmoplakin autoantibodies, has clinicopathological similarities: all mucous membranes were involved, cutaneous blisters were flaccid and ruptured easily, and histology showed suprabasilar acantholytic bullae without dyskeratosis (Mimouni et al. 2004). Anti-desmoplakin pemphigus patients do not display cardiomyopathy or palmoplantar keratoderma.

Loss of the desmoplakin tail did not disturb the formation of epidermal sheets in vivo, but the epidermal stability was insufficient to resist mechanical stress during delivery. The hair, nails, and orolaryngopharyngeal mucous membranes were also instable. The distribution of desmoplakin includes all tissues with desmosomes, such as muscle, heart, kidney, bladder, intestines, lungs, and blood vessels (Kowalczyk et al. 1999). The lack of gross pathology in the internal organs of this patient suggests that mechanical stress in the neonatal period is more critical for skin epithelia.

Truncatious DP mutations causing Carvajal syndrome (Carvajal-Huerta 1998; Norgett et al. 2000) and lethal acantholytic epidermolysis bullosa (this study) are recessive, as witnessed by healthy parental carriers. This said, it is important to note that individuals who are heterozygous carriers of desmoplakin nonsense mutations do not display striate palmoplantar keratoderma due to tentative desmoplakin haploinsufficiency (Whittock et al. 2002). In contrast, we show that the parents who carried a *DSP* mutation that leads to premature termination of translation do not exhibit complete nonsense-mediated RNA decay, but do express the truncated desmoplakin polypeptide in addition to the normal protein from the wild-type allele.

Nonsense-mediated RNA decay is a surveillance system that detects and degrades RNA transcripts containing nonsense mutations if the termination codons are located more than 50–55 nucleotides upstream of the 3′-most exon-exon junction (Nagy and Maquat 1998). Our mutations described and the 7901delG found by Norgett et al. (2000) are all located in the last exon downstream of the 3′-most exon-exon junction, and, therefore, the mRNA transcripts will not be recognized by this mechanism, regardless of the functionality of the eventually formed protein. The ablation of the C-terminal tail of desmoplakin in this case led to a stably expressed protein, which is recruited in desmosomes, although more punctate staining was observed.

Our results confirm previous experimental work that deletion of the DP tail results in a protein that is capable

of associating with desmosomes but cannot interact with intermediate filament networks (Stappenbeck et al. 1993). The globular B and C subdomains of the DP tail exhibit a conserved basic groove that may serve as a recognition site for the rod domain of vimentin (Choi et al. 2002). Specifically, sequences between the highly homologous B and C subdomains and within the COOH extremity of DP contain recognition sites crucial for IF binding and confer specificity for various IF proteins, such as keratins in simple and complex epithelia, and vimentin and desmin (Meng et al. 1997; Fontao et al. 2003). In this context, it is important to compare our case with truncations after amino acids 1933 and 2058 with the cases of Carvajal syndrome, where the truncation occurred after amino acid 2540 (Norgett et al. 2000). In our case, the DP deletion resulted in additional loss of the A and B subdomains, which, considering the retraction of intermediate filaments in basal and suprabasal epidermal cell layers, are apparently important for binding to keratins 5/14 and 1/10.

This human phenotype with large erosions and disruption of large sheets of skin without blistering, and the lack of keratin connections with the desmosomes, is very similar to the conditional DP-null mice reported by Vasioukhin et al. (2001). The ultrastructural difference of the desmosome between the DPΔrod-Δtail mouse and our DPΔtail patient is the rescue of the inner dense plaque in the latter. The inner dense plaque thus appears to represent the DP rod excluding the tail (Yin and Green 2004). Even more striking is the similarity of intercellular gaps between cultured keratinocytes of conditional DP-null mice after rescue by a transgene encoding a DPΔtail (Vasioukhin et al. 2001) and those in the present case. Borders of DPΔtail keratinocytes were incapable of zipping to seamless epithelial sheets. Vasioukhin and coworkers hypothesized that desmosomes act as molecular clamps that hold the adherens junctions in place for the second phase of epithelial sheet formation in vitro. Like Vasioukhin et al. (2001), we found no reduction of adherens junction components, such as β-catenin (fig. 3*E*). The conclusions of Vasioukhin et al. (2001) that desmoplakin is essential for epidermal sheet formation and that the DP tail strengthens proper connections to intermediate filaments leading to reinforcement of the membrane, such that adherens junctions and desmosomes are maintained upon mechanical stress, are all supported and refined by this study.

In conclusion, we described a new genetic phenotype, which we name "lethal acantholytic epidermolysis bullosa," comprising fatal skin fragility, alopecia, nail loss, and neonatal teeth and caused by compound heterozygosity for a recessive nonsense and frameshift *DSP* mutation resulting in deletion of the intermediate filament-binding domains in the DP tail.

Acknowledgments

We thank Prof. David R. Garrod, University of Manchester School of Biological Sciences, Manchester, United Kingdom, for the suggestion that desmoplakin is the prime candidate gene for the reported case. We thank the following colleagues for kindly providing us monoclonal antibodies against desmosomal components: Dr. P. Arvan, New York (ATP2C1), Dr. A. Christiano, New York (desmoglein 4), Dr. T. Hashimoto (desmoyokin), and Dr. M. Hatzfeld, Bonn, Germany (plakophilin 4/p0071). We thank Guus Kloosterhuis, Gonnie Meijer, Miranda Nijenhuis, Janny Zuiderveen, and Siep Noorman for excellent technical assistance.

Web Resources

Accession numbers and URLs for data presented herein are as follows:

GenBank, http://www.ncbi.nlm.nih.gov/Genbank/ (for *DSP* [accession number M77830]

Online Mendelian Inheritance in Man (OMIM), http://www.ncbi.nlm.nih.gov/Omim/ (for desmoplakin-related syndromes)

References

Alcalai R, Metzger S, Rosenheck S, Meiner V, Chajek-Shaul T (2003) A recessive mutation in desmoplakin causes arrhythmogenic right ventricular dysplasia, skin disorder, and woolly hair. J Am Coll Cardiol 42:319–327

Armstrong DK, McKenna KE, Purkis PE, Green KJ, Eady RA, Leigh IM, Hughes AE (1999) Haploinsufficiency of desmoplakin causes a striate subtype of palmoplantar keratoderma. Hum Mol Genet 8:143–148

Carvajal-Huerta L (1998) Epidermolytic palmoplantar keratoderma with woolly hair and dilated cardiomyopathy. J Am Acad Dermatol 39:418–421

Cheong JE, Wessagowit V, McGrath JA (2005) Molecular abnormalities of the desmosomal protein desmoplakin in human disease. Clin Exp Dermatol 30:261–266

Choi HJ, Park-Snyder S, Pascoe LT, Green KJ, Weis WI (2002) Structures of two intermediate filament-binding fragments of desmoplakin reveal a unique repeat motif structure. Nat Struct Biol 9:612–620

Fontao L, Favre B, Riou S, Geerts D, Jaunin F, Saurat JH, Green KJ, Sonnenberg A, Borradori L (2003) Interaction of the bullous pemphigoid antigen 1 (BP230) and desmoplakin with intermediate filaments is mediated by distinct sequences within their COOH terminus. Mol Biol Cell 14:1978–1992

Gallicano GI, Kouklis P, Bauer C, Yin M, Vasioukhin V, Degenstein L, Fuchs E (1998) Desmoplakin is required early in development for assembly of desmosomes and cytoskeletal linkage. J Cell Biol 143:2009–2022

Green KJ, Goldman RD, Chisholm RL (1988) Isolation of cDNAs encoding desmosomal plaque proteins: evidence that bovine desmoplakins I and II are derived from two mRNAs and a single gene. Proc Natl Acad Sci USA 85:2613–2617

Green KJ, Parry DA, Steinert PM, Virata ML, Wagner RM, Angst BD, Nilles LA (1990) Structure of the human des-

moplakins. Implications for function in the desmosomal plaque. J Biol Chem 265:2603–2612 (erratum 265:11406-11407)

Hoffman MD, Fleming MG, Pearson RW (1995) Acantholytic epidermolysis bullosa. Arch Dermatol 131:586–589

Jonkman MF (2004) Dysfunction of keratinocyte adhesion. Exp Dermatol 13:654–655

Kowalczyk AP, Bornslaeger EA, Borgwardt JE, Palka HL, Dhaliwal AS, Corcoran CM, Denning MF, Green KJ (1997) The amino-terminal domain of desmoplakin binds to plakoglobin and clusters desmosomal cadherin-plakoglobin complexes. J Cell Biol 139:773–784

Kowalczyk AP, Bornslaeger EA, Norvell SM, Palka HL, Green KJ (1999) Desmosomes: intercellular adhesive junctions specialized for attachment of intermediate filaments. Int Rev Cytol 185:237–302

McGrath JA, McMillan JR, Shemanko CS, Runswick SK, Leigh IM, Lane EB, Garrod DR, Eady RA (1997) Mutations in the plakophilin 1 gene results in ectodermal dysplasia/skin fragility syndrome. Nat Genet 17:240–244

McMillan JR, Haftek M, Akiyama M, South AP, Derrot H, McGrath JA, Eady RA, Shimizu H (2003) Alterations in desmosome size and number coincide with the loss of keratinocyte cohesion in skin with homozygous and heterozygous defects in the desmosomal protein plakophilin 1. J Invest Dermatol 121:96–103

Meng JJ, Bornslaeger EA, Green KJ, Steinert PM, Ip W (1997) Two-hybrid analysis reveals fundamental differences in direct interactions between desmoplakin and cell type-specific intermediate filaments. J Biol Chem 272:21495–21503

Mimouni D, Foedinger D, Kouba DJ, Orlow SJ, Rappersberger K, Sciubba JJ, Nikolskaia OV, Cohen BA, Anhalt GJ, Nousari CH (2004) Mucosal dominant pemphigus vulgaris with anti-desmoplakin autoantibodies. J Am Acad Dermatol 51: 62–67

Nagy E, Maquat LE (1998) A rule for termination-codon position within intron-containing genes: when nonsense affects RNA abundance. Trends Biochem Sci 23:198–199

Norgett EE, Hatsell SJ, Carvajal-Huerta L, Cabezas JC, Common J, Purkis PE, Whittock N, Leigh IM, Stevens HP, Kelsell DP (2000) Recessive mutation in desmoplakin disrupts desmoplakin-intermediate filament interactions and causes dilated cardiomyopathy, woolly hair and keratoderma. Hum Mol Genet 9:2761–2766

North AJ, Bardsley WG, Hyam J, Bornslaeger EA, Cordingley HC, Trinnaman B, Hatzfeld M, Green KJ, Magee AI, Garrod DR (1999) Molecular map of the desmosomal plaque. J Cell Sci 112:4325–4336

Rampazzo A, Nava A, Malacrida S, Beffagna G, Bauce B, Rossi V, Zimbello R, Simionati B, Basso C, Thiene G, Towbin JA, Danieli GA (2002) Mutation in human desmoplakin domain binding to plakoglobin causes a dominant form of arrhythmogenic right ventricular cardiomyopathy. Am J Hum Genet 71:1200–1206

Smith EA, Fuchs E (1998) Defining the interactions between intermediate filaments and desmosomes. J Cell Biol 141: 1229–1241

Stappenbeck TS, Bornslaeger EA, Corcoran CM, Luu HH, Virata ML, Green KJ (1993) Functional analysis of desmoplakin domains: specification of the interaction with keratin versus vimentin intermediate filament networks. J Cell Biol 123:691–705

Vasioukhin V, Bowers E, Bauer C, Degenstein L, Fuchs E (2001) Desmoplakin is essential in epidermal sheet formation. Nat Cell Biol 3:1076–1085

Whittock NV, Ashton GH, Dopping-Hepenstal PJ, Gratian MJ, Keane FM, Eady RA, McGrath JA (1999) Striate palmoplantar keratoderma resulting from desmoplakin haploinsufficiency. J Invest Dermatol 113:940–946

Whittock NV, Wan H, Morley SM, Garzon MC, Kristal L, Hyde P, McLean WH, Pulkkinen L, Uitto J, Christiano AM, Eady RA, McGrath JA (2002) Compound heterozygosity for non-sense and mis-sense mutations in desmoplakin underlies skin fragility/woolly hair syndrome. J Invest Dermatol 118:232–238

Yin T, Green KJ (2004) Regulation of desmosome assembly and adhesion. Semin Cell Dev Biol 15:665–677