CASE REPORTS

Refer to: Ylvisaker JT, McDonald GB: Sexually acquired amebic colitis and liver abscess. West J Med 132:153-157, Feb 1980

Sexually Acquired Amebic Colitis and Liver Abscess

J. THOMAS YLVISAKER, MD
GEORGE B. McDONALD, MD
Seattle

AMEBIASIS has long been recognized as a possible consequence of travel to areas where the parasite is endemic.[1] Various forms of the disease also have been seen in people with no travel history outside the United States—particularly in rural areas, in the southern states, in lower socioeconomic groups and in institutions for the mentally retarded.[2] More recently, amebic dysentery was described in the male homosexual communities of New York and San Francisco.[3-5]

We report the cases of two homosexual men with amebic dysentery and liver abscess. These cases emphasize the difficulties of diagnosing intestinal disorders in homosexual men, and show that amebiasis in these patients may be a virulent illness.

Reports of Cases

CASE 1. A 37-year-old man entered Harborview Medical Center in Seattle, in August 1975, with a two-week history of bloody diarrhea, a week of fever, four days of right shoulder pain, and two days of right chest pain and dyspnea. He had a past history of treated syphilis; rectal culture for gonorrhea was negative two weeks before admission. He was an admitted homosexual who was visiting Seattle from New York City, with no history of travel outside of the United States. Physical examination showed a temperature of 38.8°C (101.8°F) with no chest or abdominal abnormalities. At sigmoidoscopy, the rectal mucosa was diffusely friable, with whitish exudate from the dentate line to 25 cm. Laboratory studies gave the following values: hematocrit was 48 percent; leukocyte count, 11,600 per cu mm with normal differential; bilirubin, 1.2 mg per dl; alkaline phosphatase, 138 IU per liter (normal, less than 90); serum glutamic oxaloacetic transaminase (SGOT), 24 units per ml (normal, less than 28); serum glutamic pyruvic transaminase (SGPT), 53 units per ml (normal, less than 30), and prothrombin time, 14.5 seconds (control, 13 seconds). An x-ray study of the chest showed atelectasis at the left lung base. Treatment with sulfasalazine (Azulfidine) for presumed ulcerative colitis was started.

Two days following the patient's admission, right upper quadrant abdominal pain and a pleural friction rub were noted. A technetium liver scan showed a single defect 4 to 5 cm in size in the dome of the right lobe. Sigmoidoscopy then showed a diffusely abnormal mucosa with small punctate ulcers; wet-mount examination showed trophozoites of *Entamoeba histolytica.* (Rectal biopsies also showed the organism.) Stool culture was negative for bacterial pathogens as was a rectal culture for *Neisseria gonorrhoeae.* Treatment with metronidazole (Flagyl), 750 mg three times per day, was started and there was substantial improvement by the following day. Three days later, the patient was discharged afebrile and without diarrhea or abdominal pain. He immediately left the Seattle area and has been lost to follow-up. After discharge, his acute indirect hemagglutination titer for amebae returned as positive at 1:128.

CASE 2. A 27-year-old man was admitted to the Seattle Veterans Administration Hospital in January 1977 with a four-day history of bloody diarrhea, fever, chills and crampy right upper quadrant abdominal pain, and a one-day history of right shoulder pain. In 1974 he had been evaluated for mild rectal bleeding; a barium enema study showed no abnormalities and sigmoidoscopy showed only hemorrhoids. Four months before admission to hospital, the patient reported bloody diarrhea and tenesmus, which had been diagnosed

From the Medical Service, Seattle Veterans Administration Medical Center and the University of Washington School of Medicine, Seattle.

Submitted, revised, June 18, 1979.

Dr. Ylvisaker's postgraduate training was supported by the Veterans Administration.

Reprint requests to: George B. McDonald, MD, Veterans Administration Medical Center, 4435 Beacon Avenue South, Seattle, WA 98108.

elsewhere as ulcerative colitis on the basis of a rectal biopsy. Treatment was begun with sulfasalazine and steroid enemas with resolution of symptoms over two to three weeks. Six weeks before admission the patient had recurrent mild rectal bleeding which resolved spontaneously.

His past history included recurrent asymptomatic rectal gonorrhea, his last positive culture being six months before his admission to hospital. In October 1974 hepatitis B developed in the patient, with persistent positive serum HBsAg. His last recorded SGOT was 180 units per ml in May 1975. He had lived in Seattle for the past four years and had not traveled outside the United States since being in Vietnam from 1970 to 1971—there had been no history of diarrhea or dysentery while there. He described homosexual activities with many different partners, one such contact occurring five months before admission. This partner had recently returned from Southeast Asia complaining of rectal pain and an examination had shown "proctitis without blood or ulcerations."

Physical examination of the patient showed an ill-appearing, thin man with a temperature, taken orally, of 37.9°C (100.2°F). Abdominal examination showed right upper quadrant tenderness without hepatomegaly. Sigmoidoscopy showed many well-circumscribed ulcers, with slightly friable and edematous intervening mucosa. Trophozoites of *Entamoeba histolytica* were found on examination of stool, and rectal biopsies showed many organisms as well (see Figure 1).

Cultures for *Neisseria gonorrhoeae* and other bacterial pathogens were negative. Serum HBsAg was positive; VDRL was negative. Other laboratory studies gave the following values: a hematocrit of 36 percent, leukocyte count of 14,200 per cu mm with a normal differential and an erythrocyte sedimentation rate (ESR) of 52 mm per hour. Liver function studies showed normal bilirubin and alkaline phosphatase values with SGOT minimally elevated at 52 units per ml. A chest x-ray study showed no abnormalities and a technetium liver scan showed a single 5-cm defect in the dome of the right lobe (Figure 2A).

The patient was treated with metronidazole 750 mg three times per day and tetracycline 500 mg four times a day with prompt clinical improvement. He was discharged afebrile three days after treatment was begun. Six weeks later, he was asymptomatic, findings of stool examination for amebae were negative and sigmoidoscopy gave normal findings. By June 1977, five months after discharge from hospital, the liver scan showed no abnormalities (Figure 2B). The indirect hemagglutination titer for amebae drawn during the acute illness was positive at 1:4,096.

Discussion

There have been several reports of intestinal amebiasis in the homosexual community,[6-9] including one of amebiasis in four homosexual men following one partner's travel to an endemic area.[10] The frequency of amebic dysentery in homosexual men in New York and San Francisco

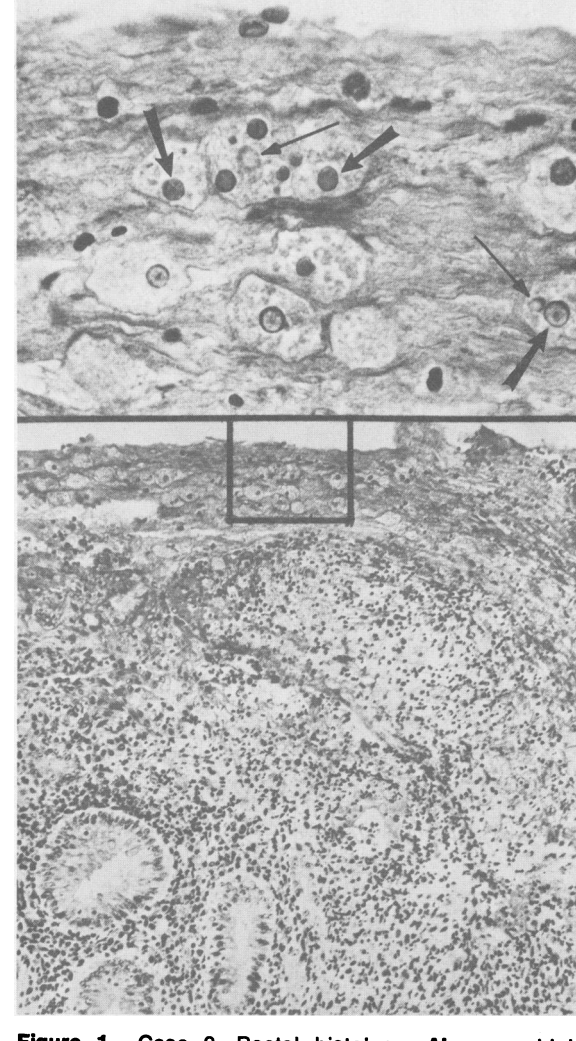

Figure 1.—Case 2. Rectal histology. **Above,** a high-power view of the boxed area, showing several trophozoites of *Entamoeba histolytica.* Large arrows point to typical spherical nuclei with central karyosomes and small arrows point to ingested red blood cells within cytoplasm. (Hematoxylin and eosin stain; reduced from ×200.) **Below,** a low-power view showing crypt destruction, inflammation and an overlying exudate. (Hematoxylin and eosin stain; reduced from ×40.)

has been noted[3-5] and, in fact, our first patient was visiting Seattle from New York. In contrast to the illness described in these series, amebiasis in our patients was severe, with tissue invasion of colon and liver. We have no ready explanation for the severity of their disease—an invasive stain of *Entamoeba histolytica* may have been acquired,[11] or perhaps rapid passage of an avirulent strain through several hosts may enhanced its invasiveness.[12-14] Promiscuous sexual behavior might create the opportunity for such rapid passage.

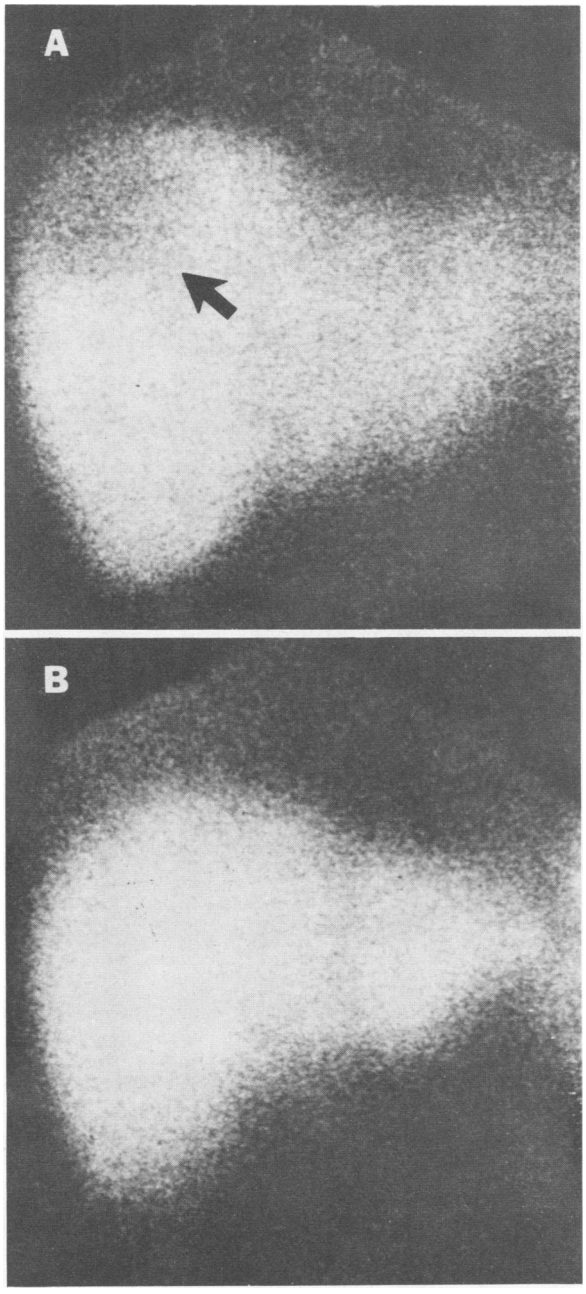

Figure 2.—Case 2. Technetium liver scans. **A,** during the patient's acute illness, showing a solitary 5-cm defect in the right lobe **(arrow). B,** five months later, showing a normal liver.

Venereal transmission of amebiasis can occur by several routes. Amebic balanitis (caused by *E histolytica*) can occur after sexual contact with an infected woman;[15] vaginal infections are presumed to arise in the colons of women who practice poor hygiene.[16,17] However, recent reports describe penile amebiasis as a disease of homosexual men.[18,19] In neither of our patients were penile lesions present, but both gave histories compatible with fecal-oral transmission of the organism, either by rectal intercourse followed by oral-genital or oral-rectal contact among several partners.

Making the diagnosis of amebiasis in homosexual men with diarrhea may be difficult because typhoid fever,[20] shigellosis[21,22] and giardiasis[23-25] have been recently described in this population. Gonorrhea and syphilis must be also considered, although the former is frequently asymptomatic.[26-29] Bloody diarrhea (dysentery) in a homosexual man should strongly suggest shigellosis or amebiasis; the finding of fecal leukocytes would be consistent with either of these invasive diseases as well as ulcerative colitis, Crohn disease and *Yersinia* enterocolitis. However, the diagnosis of amebic colitis is critically important for several reasons: it is not self-limited, like the bacterial dysenteries; it is easily cured, unlike Crohn disease and ulcerative colitis, and it should not be empirically treated with steroids because of the danger of dissemination of amebae.

Misdiagnosis of amebic colitis is common where the disease is not endemic—this includes most of the United States.[30] Multiple fresh-stool examinations and direct scrapings of ulcerated rectal mucosa will generally show cyst and trophozoite forms of the organism. However, excretion of *E histolytica* may be intermittent or rare, particularly after administration of antibiotics (including sulfonamides) and cathartics; specimens obtained two to three days apart should be examined. Barium, magnesium, kaolin, bismuth and oily compounds can obscure the parasites and may alter the appearance of trophozoites.[31] When the sigmoidoscopic appearance shows punched-out ulcerations with relatively normal mucosa in between, the diagnosis of amebiasis is strongly suggested.[1] However, other conditions, such as Crohn disease[32] and yersinosis,[33] may show similar

aphthous ulcerations of the colon. Unless wet mounts can be prepared and interpreted promptly, scrapings should be preserved for analysis in polyvinyl alcohol.

Confusion may arise when the rectal mucosa is diffusely abnormal, simulating idiopathic ulcerative colitis.[31,34] Rectal biopsies are not as sensitive as thorough stool and scraping examinations, and when the biopsy does not show the organism, the rest of the histologic findings are entirely nonspecific.[34,35] However, serologic findings (indirect hemagglutination) are positive in 82 percent to 98 percent of patients with acute amebic colitis,[30,31] and should be routinely ordered when the cause of colitis is uncertain.

The combination of colitis and liver abscess should point to a diagnosis of amebiasis, although colitis need not be present in patients with liver abscess.[36] In fact, only 14 percent of a large series of more than 2,000 patients had diarrhea or dysentery at the time the diagnosis was made.[37] In a study of cases of amebic liver abscess in the United States, less than a third of the patients had diarrhea and in only 6 of 41 patients were there organisms in stool specimens.[38] Positive serologic findings for amebiasis are the rule with amebic liver abscess.[36] Whether a more invasive strain of the organism was responsible for the colitis/abscess presentation in our patients in unclear, but this possibility has been suggested.[11-14]

In both of our patients there were good clinical responses to oral administration of metronidazole, as has been reported for both colitis and liver abscess.[37-40] However, treatment failures have also been documented, and in some patients treated with metronidazole alone for amebic colitis, liver abscesses have developed.[39]

Although metronidazole, in a dosage of 750 mg three times per day for five to ten days, is probably the drug of choice for both amebic dysentery and extraintestinal amebiasis, there is concern about its potential carcinogenicity. Alternative drugs are available and their indications, dosages and toxicity have been recently reviewed.[1,13,41] Aspiration of amebic abscesses may be required, particularly if rupture into the peritoneum is imminent; our patients recovered uneventfully after receiving metronidazole alone.

There are several lessons to be learned from these two cases: (1) Sexually acquired amebic infections may be severe, presenting as dysentery, liver abscess or both. (2) The diagnosis of amebic colitis must be strongly considered in homosexual men with diarrhea, and can be made by thorough examination of stool specimens and rectal scrapings, with accompanying serologic studies. (3) The occurrence of liver disease in a homosexual man with or without diarrhea should prompt consideration of amebic liver abscess.

Summary

We have presented the cases of two homosexual men, each of whom presented with amebic colitis and liver abscess. Both responded to treatment with metronidazole. These cases illustrate the difficulties of diagnosing intestinal disorders in homosexual men and provide evidence that sexually transmitted amebiasis can be a virulent illness.

REFERENCES

1. Curtis KJ, Sleisenger MH: Infectious and parasitic diseases, *In* Sleisenger MH, Fordtran JS (Eds): Gastrointestinal Disease. Philadelphia, W B Saunders Co, 1978, pp 1693-1705

2. Brooke MM: Epidemiology of amebiasis in the U.S. JAMA 188:519-521, May 11, 1964

3. Schmerin MJ, Gelston A, Jones TC: Amebiasis—An increasing problem among homosexuals in New York City. JAMA 238: 1386-1387, Sep 26, 1977

4. Dritz SK, Ainsworth TE, Back A, et al: Patterns of sexually transmitted enteric diseases in a city. Lancet 2:3-4, Jul 2, 1977

5. Unger KW: Amebiasis (Letter). N Engl J Med 298:1148, May 18, 1978

6. Kean BH: Venereal amebiasis. NY State J Med 76:930-931, Jun 1976

7. Hurwitz AL, Owen RL: Venereal transmission of intestinal parasites (Medical Information). West J Med 128:89-91, Jan 1978

8. Sohn N, Robilotti JG: The gay bowel syndrome. Am J Gastroenterol 67:478-484, May 1977

9. Mildvan D, Gelb A, William D: Venereal transmission of enteric pathogens in male homosexuals—Two case reports. JAMA 238:1387-1389, Sep 26, 1977

10. Most H: Manhattan: A tropical isle? Am J Trop Med Hyg 17:333-354, May 1968

11. Pathogenic Entamoeba histolytica (Editorial). Lancet 1: 303, Feb 10, 1979

12. Elsdon-Dew R: The epidemiology of amoebiasis, *In* Dawes B (Ed): Advances in Parasitology, Vol 6. New York, Academic Press, 1968, pp 1-62

13. Juniper K: Amoebiasis, *In* Intestinal parasites. Clin Gastroenterol 7:3-29, Jan 1978

14. Neal RA: Pathogenesis of amebiasis. Bull NY Acad Med 47:462-468, May 1971

15. Mylius RE, Tenseldam REJ: Venereal infection by Entamoeba histolytica in a New Guinea native couple. Trop Geographic Med 14:20-26, Mar 1962

16. Mungia H, Franco E, Valenzuela P: Diagnosis of genital amebiasis in women by the standard Papanicolaou technique. Am J Obstet Gynecol 94:181-188, Jan 15, 1966

17. Heinz KPW: Amoebic infection of the female genital tract: A report of three cases. S African Med J 47:1795-1798, Oct 6, 1973

18. Purpon I, Jiminez D, Engelking RL: Amebiasis of the penis. J Urol 98:372-374, Sep 1967

19. Thomas JA, Antony AJ: Amoebiasis of penis. Br J Urol 48:269-273, Aug 1976

20. Dritz SK, Braff EH: Sexually transmitted typhoid fever (Letter). N Engl J Med 296:1359-1360, Jun 9, 1977

21. Dritz SK, Back AF: Shigella enteritis venereally transmitted (Letter). N Engl J Med 291:1194, Nov 28, 1974

22. Drusin LM, Genvert G, Topf-Olstein B, et al: Shigellosis—Another sexually transmitted disease? Br J Vener Dis 52:348-350, Oct 1976

23. Meyers JD, Kuharic HA, Holmes KK: Giardia lamblia infection in homosexual men. Br J Vener Dis 53:54-55, Feb 1977

24. Kacker PP: A case of Giardia lamblia proctitis presenting in a V.D. clinic. Br J Vener Dis 49:318-319, Jun 1973

25. Schmerin MJ, Jones TC, Klein H: Giardiasis: Association with homosexuality. Ann Intern Med 88:801-803, Jun 1978

26. Owen RL, Hill JL: Rectal and pharyngeal gonorrhea in homosexual men. JAMA 220:1315-1318, Jun 5, 1972

27. Klein EJ, Fisher LS, Chow AW, et al: Anorectal gonococcal infection. Ann Intern Med 86:340-346, Mar 1977
28. Nazemi MM, Musher DM, Schell RF, et al: Syphilitic proctitis in a homosexual. JAMA 231:389, Jan 27, 1975
29. Akdamar K, Martin RJ, Ichinose H: Syphilitic proctitis. Am J Dig Dis 22:701-704, Aug 1977
30. Krogstad DJ, Spencer HC, Healy GR, et al: Amebiasis: Epidemiologic studies in the United States, 1971-1974. Ann Intern Med 88:89-97, Jan 1978
31. Tucker PC, Webster PD, Kilpatrick ZM: Amebic colitis mistaken for inflammatory bowel disease. Arch Intern Med 135: 681-685, May 1975
32. Meuwissen SGM, Pape KSSB, Agenant D, et al: Crohn's disease of the colon—Analysis of the diagnostic value of radiology, endoscopy, and histology. Am J Dig Dis 21:81-88, Feb 1976
33. Vantrappen G, Agg HO, Ponette E, et al: Yersinia enteritis and enterocolitis—Gastroenterologic aspects. Gastroenterology 72: 220-227, Feb 1977
34. Pittman FE, EL-Hashimi WK, Pittman JC: Studies of human amebiasis—I. Clinical and laboratory findings in eight cases of acute amebic colitis. Gastroenterology 65:581-587, Oct 1973
35. Pittman FE, Hennigar GR: Sigmoidoscopic and colonic mucosal biopsy findings in amebic colitis. Arch Pathol 97:155-158, Mar 1974
36. DeBakey MD, Jordan GL: Hepatic amebiasis, *In* Schiff L (Ed): Diseases of the Liver. Philadelphia, J B Lippincott Company, 1975, pp 119-136
37. Adams EB, MacLeod IN: Invasive amebiasis—II. Amebic liver abscess and its complications. Medicine 56:325-333, Jul 1977
38. Cohen JG, Reynolds TB: Comparison of metronidazole and chloroquin for the treatment of amebic liver abscess—A controlled trial. Gastroenterology 69:35-41, Jul 1975
39. Everett ED: Metronidazole and amebiasis. Am J Dig Dis 19: 626-636, Jul 1974
40. Adams EB, MacLeod IN: Invasive amebiasis—I. Amebic dysentery and its complications. Medicine 56:315-323, Jul 1977
41. Krogstad DJ, Spencer HC, Healy GR: Current concepts in parasitology—Amebiasis. N Engl J Med 298:262-265, Feb 2, 1978

Refer to: Wiest JW, Follette DM, Traverso LW: Toothpick perforation of the duodenum. West J Med 132:157-159, Feb 1980

Toothpick Perforation of the Duodenum

JOHN W. WIEST, MD
DAVID M. FOLLETTE, MD
L. WILLIAM TRAVERSO, MD
Los Angeles

TOOTHPICKS have acquired many uses in addition to their intended function of oral hygiene. They are widely used as eating utensils, for decoration and in the preparation of many foods. When employed to clean the teeth, toothpicks are rarely swallowed; those accidentally ingested have usually been involved in food preparation without the knowledge of the consumer.[1] The most important factor associated with ingestion of foreign bodies is the wearing of dentures;[2-4] persons with upper dental plates lack the tactile sensitivity of the palate that normally prevents such objects from being swallowed.

A swallowed toothpick becomes a surgical problem when it fails to pass spontaneously and perforates the intestine. This complication is not rare; toothpicks account for 10 percent of intestinal perforations by ingested foreign bodies.[5]

Report of a Case

A 54-year-old man was admitted to another hospital with an eight-day history of cramp-like abdominal pains and fever. A diagnosis of acute cholecystitis was made, and he was treated with intravenously given ampicillin and gentamicin without improvement. Exploratory laparotomy was done on the third hospital day and showed a normal gallbladder, although duodenitis was noted.

The patient continued to have spiking fevers to 40.5°C (105°F) postoperatively. X-ray studies of the upper gastrointestinal area done a week after the exploratory operation showed extravasation of retroduodenal contrast material from the second portion (Figures 1, 2). The patient was transferred to University of California, Los Angeles (UCLA), Hospital, where a diagnosis of perforated duodenal ulcer was made. Subsequent exploration showed considerable duodenal inflammation, especially along the lateral duodenal wall, with many retroperitoneal adhesions. No distinct abscess cavity could be isolated and intraoperative cholangiograms showed no abnormalities. The third portion of the duodenum was grossly strictured; this was opened, revealing an anterior ulcer, 1 cm in size, in the distal second portion. A probe was passed through the ulcer into the duodenal wall, tunneled into the pancreas, and finally passed into a cavity in the hepatoduodenal ligament (Figure 3). The ulcer base was oversewn. Further exploration in this area was deemed unsafe. The opened, inflamed duodenum was bypassed with a Billroth II gastrectomy. When the jejunum was opened during the gastrojejunal anastomosis, a wooden toothpick was discovered. The patient was discharged home on the 12th postoperative day.

Discussion

Ingestion of foreign bodies is a fairly common event which rarely causes problems; indeed, 80 percent to 90 percent of swallowed objects pass through the gut without complications.[2,6] How-

From the Department of Surgery, UCLA School of Medicine (University of California, Los Angeles).
Submitted, revised, March 21, 1979.
Reprint requests to: L. William Traverso, MD, c/o Mrs. Seba Kolb, Editor, Department of Surgery 72-125 CHS, UCLA School of Medicine, Los Angeles, CA 90024.