CLINICAL MICROBIOLOGY REVIEWS, Oct. 2002, p. 747–756 Vol. 15, No. 4
0893-8512/02/$04.00+0 DOI: 10.1128/CMR.15.4.747–756.2002
Copyright © 2002, American Society for Microbiology. All Rights Reserved.

Current Consensus Guidelines for Treatment of Neurocysticercosis

Hector H. García,[1,2]* Carlton A. W. Evans,[3,4] Theodore E. Nash,[5] Osvaldo M. Takayanagui,[6] A. Clinton White, Jr.,[7] David Botero,[8] Vedantam Rajshekhar,[9] Victor C. W. Tsang,[10] Peter M. Schantz,[10] James C. Allan,[11] Ana Flisser,[12] Dolores Correa,[13] Elsa Sarti,[14] Jon S. Friedland,[4] S. Manuel Martinez,[1] Armando E. Gonzalez,[15] Robert H. Gilman,[1,2,16] and Oscar H. Del Brutto[17]

Cysticercosis Unit, Instituto Nacional de Ciencias Neurológicas[1]; Departments of Microbiology and Pathology, Universidad Peruana Cayetano Heredia[2]; and School of Veterinary Medicine, Universidad Nacional Mayor de San Marcos,[15] Lima, Peru; University of Cambridge Clinical School, Cambridge[3]; Imperial College of Science, Technology and Medicine[4]; and Department of Biological Sciences, University of Salford, and Pfizer Inc., Sandwich,[11] United Kingdom; Laboratory of Parasitic Diseases, National Institute of Allergy and Infectious Diseases, National Institutes of Health, Bethesda[5], and Department of International Health, The Johns Hopkins University School of Hygiene and Public Health, Baltimore,[16] Maryland; Department of Neurology, School of Medicine of Ribeirao Preto, Universidade de Sao Paulo, Ribeirão Preto, Brazil[6]; Infectious Disease Section, Department of Medicine, Baylor College of Medicine, Houston, Texas[7]; Instituto Colombiano de Medicina Tropical, Medellín, Colombia[8]; Department of Neurological Sciences, Christian Medical College and Hospital, Vellore, India[9]; Division of Parasitic Diseases, National Center for Infectious Diseases, Centers for Disease Control, Atlanta, Georgia[10]; School of Medicine, Universidad Nacional Autonoma de Mexico[12]; Instituto Nacional de Pediatria, Secretaría de Salud[13]; and Instituto Nacional de Diagnóstico y Referencia Epidemiológicos, Secretaría de Salud,[14] Mexico D.F., Mexico; and Department of Neurological Sciences, Hospital-Clínica Kennedy, Guayaquil, Ecuador[17]

INTRODUCTION 747
The Parasite 748
The Disease 748
Diagnosis 749
Therapeutic Alternatives 749
Antiparasitic drugs 750
Surgery 751
Symptomatic and anti-inflammatory medication 751
DISCUSSION GUIDELINES AND METHODS 751
PANEL CONSENSUS—GENERAL CONCEPTS 752
OVERVIEW OF PARENCHYMAL BRAIN CYSTICERCOSIS 752
Viable Cysts 752
Enhancing Lesions 752
Calcifications 752
OVERVIEW OF EXTRAPARENCHYMAL CYSTICERCOSIS 752
COMMENTS 753
REFERENCES 754

INTRODUCTION

Cysticercosis, the infection caused by the larval stage of the tapeworm *Taenia solium*, is the most common parasitic disease of the nervous system in humans and the single most common cause of acquired epileptic seizures in the developing world, where prevalence rates of active epilepsy are twice those in developed countries (41, 53, 56, 91, 107).

Before the introduction of modern neuroimaging diagnostic techniques, knowledge of the natural history of human disease was limited and largely based on cases diagnosed either by the presence of subcutaneous nodules, by plain X-rays showing calcifications in the brain or soft tissues, by surgery of cases with intracranial hypertension, or from necropsy data (44–46, 60, 73). The image of an aggressive, lethal disease arose from this clearly biased (towards more severe infestations) group of cases. During the last two decades, the introduction of computed tomography (CT) and later magnetic resonance imaging (MRI) permitted the identification of mild cases with only a few parenchymal cysts, and the terms benign and malign cysticercosis were coined (26, 50). Later, studies in India showed that a vast majority of single enhancing lesions, until then attributed to tuberculosis, were in fact degenerating cysticerci (19, 20, 86, 87).

The introduction of praziquantel (88) and albendazole (49) as specific antiparasitic agents was enthusiastically adopted by many segments of the medical community. The value of these agents has been questioned by some authors (18, 57, 64-66, 76), and an intense controversy still exists. Unfortunately, this has led to confusion and poorly informed decisions in clinical management, especially in areas where neurocysticercosis is not a daily diagnosis. At a recent meeting on cysticercosis held in Lima, Peru, a panel of experts in different aspects of the disease reached a consensus as to the minimal treatment guide-

* Corresponding author. Mailing address: Cysticercosis Unit, Instituto de Ciencias Neurológicas, Jr. Ancash 1271, Barrios Altos, Lima 1, Peru. Phone: 511 3287360. Fax: 511 3287382. E-mail: hgarcia@terra.com.pe.

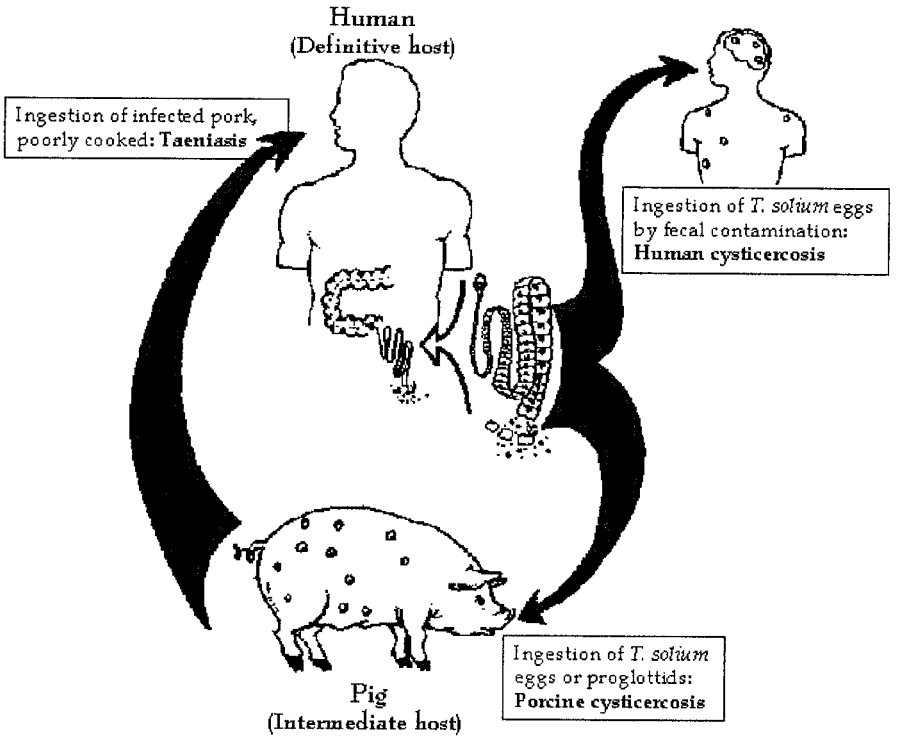

FIG. 1. Life cycle of *T. solium*.

lines for neurocysticercosis. Effort was made to identify about which types of neurocysticercosis there was agreement and a uniformly accepted approach. The panel also attempted to define the range of therapeutic approaches for those forms for which there was no consensus

The Parasite

Taenia solium is a two-host zoonotic cestode. The adult stage is a 2- to 4-m-long tapeworm that lives in the small intestine of humans. No other final hosts are known for *T. solium* tapeworms in nature. As in all cestodes, the gravid proglottids at the terminal end of the worm are full of eggs that are the source of infection with the larval stage, or cysticercosis. The natural intermediate host is the pig, harboring larval cysts anywhere in its body. Humans become infected with cysts by accidental ingestion of *T. solium* infective eggs by fecal-oral contamination (Fig. 1).

The Disease

After ingestion of *Taenia* eggs containing infective oncospheres, the parasites become established in the tissues as larval cysts and reach their mature size in about 3 months (15, 110). The parasite may locate almost anywhere in the body. The infection burden varies from a single lesion to several hundreds, and lesions may range in size from a few millimeters to several centimeters (41, 53, 56). Laboratory studies and information from other cestodes suggest that viable cysts actively modulate the host's immune system to evade destruction by it (51, 108).

Symptomatic disease results almost exclusively from the invasion of the nervous system (neurocysticercosis) and the eye and is clearly different in parenchymal neurocysticercosis and extraparenchymal neurocysticercosis. The usual presentation of parenchymal neurocysticercosis is with seizures, which can be controlled with antiepileptic drug therapy. Occasionally, the cysts may grow and produce a mass effect. Extraparenchymal infection may cause hydrocephalus by mechanical obstruction of the ventricles or the basal cisterns, either by the cysts themselves or by an inflammatory reaction (ependymitis and/or arachnoiditis). The so-called racemose variety occurs in the ventricles or basal cisterns and is characterized by abnormal growth of cystic membranes with degeneration of the parasite's head (scolex) (10, 84). These cases follow a progressive course, and even after ventricular shunting, the membranes or inflammatory cells and proteins frequently block the shunt.

In most patients, neurocysticercosis seems to produce symptoms years after the initial invasion of the nervous system by the parasite (44), by either inflammation around the parasite, mass effect, or residual scarring (39). There is a clear association between inflammation around one or more cysts and development of symptoms, especially with regard to seizures (108).

The natural history of parenchymal cysticercosis has been studied by pathological examination (48, 52, 100) and imaging studies using CT (66, 104) and MRI (47). Viable cysts are 10 to 20 mm in diameter, thin-walled sacks filled with clear cyst fluid. On imaging studies, the wall is not visible and the fluid is isodense with the cerebrospinal fluid. There is little or no evidence of perilesional inflammation, and they do not enhance with contrast media on neuroimaging (Fig. 2). As the

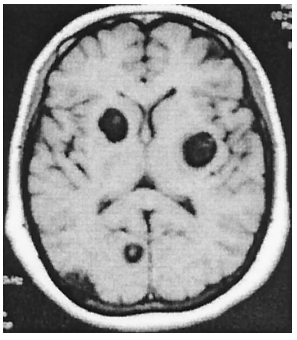

FIG. 2.

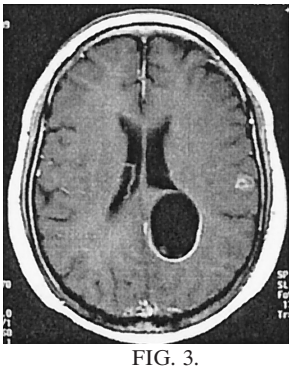

FIG. 3.

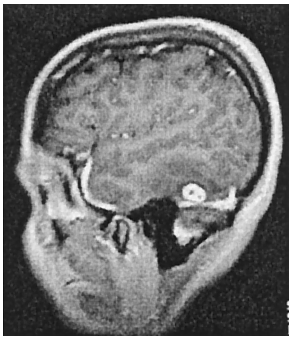

FIG. 4.

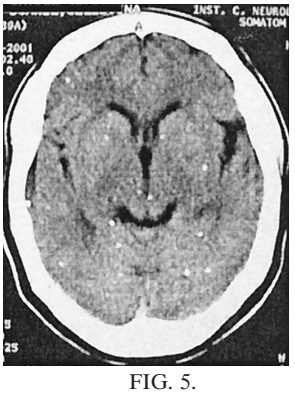

FIG. 5.

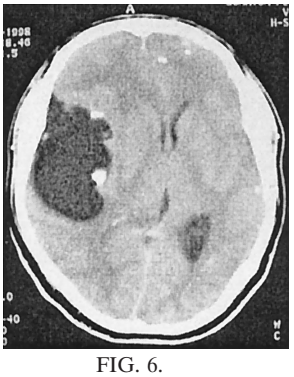

FIG. 6.

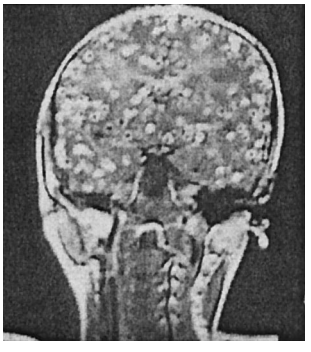

FIG. 7.

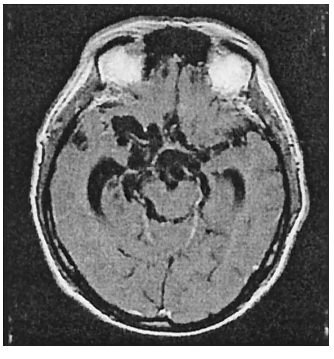

FIG. 8.

FIG. 9.

FIG. 2–9. Viable cysts (contrasted MRI; Fig. 2), cyst with perilesional contrast enhancement (contrasted MRI; Fig. 3), enhancing lesion (contrasted MRI; Fig. 4), calcifications (noncontrasted CT; Fig. 5), giant cyst (contrasted CT; Fig. 6), cysticercotic encephalitis (contrasted MRI; Fig. 7), basal subarachnoid cysticercosis (contrasted MRI; Fig. 8), and IV ventricle ependymitis (contrasted MRI; Fig. 9).

parasite loses the ability to control the host immune response, an inflammatory process begins. Initially, the cysts show slight pericystic contrast enhancement (Fig. 3). Later they become markedly inflamed and edematous and appear as ring-like or nodular areas of enhancement after the injection of contrast (Fig. 4). This phase has been called "granulomatous cysticercosis, "cysticerci in encephalitic phase," or "enhancing lesions." Finally, the cyst is processed by the cellular response, and its remnants either are not detectable by imaging or become calcified lesions (Fig. 5). "Giant" cysts, measuring more than 50 mm in diameter, are occasionally found, located primarily in the Sylvian fissure (Fig. 6). Cysticercotic encephalitis is a rare form of the disease in which patients have numerous inflamed cysticerci, leading to diffuse, severe cerebral edema (Fig. 7).

Extraparenchymal neurocysticercosis includes cysticerci in the ventricles and basal cisterns (racemose cysticercosis, Fig. 8). Since the cyst membrane is thin and the fluid is isodense with the cerebrospinal fluid, uninflamed extraparenchymal cysticerci are usually not visible on CT and may only reveal subtle, indirect findings on MRI. Scans may reveal hydrocephalus without noticeable cysts, ependymitis (Fig. 9), distorted basal cisterns, or basal meningitis.

Diagnosis

The diagnosis of neurocysticercosis is difficult because clinical manifestations are nonspecific, most neuroimaging findings are not pathognomonic, and some serologic tests have low sensitivity and specificity. A set of diagnostic criteria was proposed in 1996 (43) and recently revisited (37), based on objective clinical, imaging, immunological, and epidemiological data; these criteria consist of four categories that are stratified according to their diagnostic strength (Table 1).

These criteria provide two degrees of diagnostic certainty: definitive diagnosis, in patients who have one absolute criterion or in those who have two major plus one minor and one epidemiologic criteria; and probable diagnosis, in patients who have one major plus two minor criteria, in those who have one major plus one minor and one epidemiologic criteria, and in those who have three minor plus one epidemiologic criteria. This chart of diagnostic criteria for neurocysticercosis has not yet been tested in hospital-based studies.

Differential diagnosis between cysticercosis and other parasitic diseases may be difficult on clinical grounds. However, epidemiological data as well as evidence provided by neuroimaging studies and highly specific immune diagnostic tests usually provide useful diagnostic clues. Cystic hydatid disease almost always appears on CT/MRI as a single, large, spherical, and nonenhancing intracranial cyst. This is a very rare form of presentation of *T. solium* cysticercosis. Also, the current assay of choice, immunoblot, does not cross-react with echinococcosis. Other condition that may resemble *T. solium* cysticercosis from the clinical and neuroimaging points of view is coenurosis, an extremely rare condition caused by the cestode *Multiceps multiceps*.

Therapeutic Alternatives

Therapeutic measures include antiparasitic drugs, surgery, and symptomatic medication.

TABLE 1. Diagnostic criteria for neurocysticercosis[a]

Criterion
Absolute
Histologic demonstration of the parasite from biopsy of a brain or spinal cord lesion
Cystic lesions showing the scolex on CT or MRI
Direct visualization of subretinal parasites by fundoscopic examination
Major
Lesions highly suggestive of neurocysticercosis on neuroimaging studies
Positive serum immunoblot for the detection of anticysticercal antibodies
Resolution of intracranial cystic lesions after therapy with albendazole or praziquantel
Spontaneous resolution of small single enhancing lesions
Minor
Lesions compatible with neurocysticercosis on neuroimaging studies
Clinical manifestations suggestive of neurocysticercosis
Positive CSF ELISA for detection of anticysticercal antibodies or cysticercal antigens
Cysticercosis outside the central nervous system
Epidemiologic
Evidence of a household contact with *T. solium* infection
Individuals coming from or living in an area where cysticercosis is endemic
History of frequent travel to disease-endemic areas

[a] CSF, cerebrospinal fluid; ELISA, enzyme-linked immunosorbent assay.

Antiparasitic drugs. As demonstrated by experiments in animals, praziquantel and albendazole are effective antiparasitic drugs against *T. solium* cysticerci. Initial studies with praziquantel noted that doses as low as 5 to 10 mg/kg/day had some effect against cysts, and doses as high as 50 to 75 mg/kg/day were well tolerated. A dosage of 50 mg/kg/day for 2 weeks was adopted by most subsequent studies (11, 13, 16, 29, 32, 59, 63, 67, 68, 71, 94–96, 98, 103, 111), although a single-day regimen of praziquantel has recently been described (24, 25, 35, 69, 80, 81), with similar rates of cyst disappearance in some groups of patients. No dose ranging studies were performed with albendazole in cysticercosis. Instead, the dose previously used in hydatid disease (15 mg/kg/day) was used for cysticercosis. The initial length of therapy was 1 month, later reduced to 15 days and 1 week (2, 3, 14, 21, 29, 55, 63, 89, 90, 94, 95, 98, 111). There is limited experience with higher doses of both drugs (1, 11, 58). Between 60% and 85% of parenchymal brain cysticerci are killed after standard courses of treatment, with most trials showing a higher parasiticidal effect of albendazole.

Between the second and fifth days of antiparasitic therapy, there is usually an exacerbation of neurological symptoms, attributed to local inflammation due to the death of the larvae. For this reason, both albendazole and praziquantel are generally given simultaneously with steroids in order to control the edema and intracranial hypertension that may occur as a result of therapy. Praziquantel interacts with steroids, decreasing its serum concentrations (105), although there is no evidence that this pharmacological interaction affects its parasiticidal properties. Serum levels of phenytoin and carbamazepine may also be lowered as the result of simultaneous praziquantel administration (12). Albendazole has better penetration into cerebrospinal fluid, its concentrations are not affected when given with steroids (61, 62), and it is cheaper than praziquantel. Table 2 summarizes most trials of antiparasitic therapy for neurocysticercosis.

After the initial descriptions of successful use of praziquantel and albendazole in neurocysticercosis, several cases series noted that some types of parenchymal neurocysticercosis can resolve on imaging studies without being treated with antiparasitic drugs (74, 75). Since then, an alternative opinion has been voiced that the acute, severe brain inflammation resulting from their use is unnecessary because parenchymal brain cysticercosis follows a benign course and cysts will degenerate and heal by natural evolution of the disease (17, 18, 64–66). The arguments on both sides of the discussion are contrasted in Table 3.

Most published studies on treatment of neurocysticercosis are uncontrolled case series, often purely imaging studies. The main evidence for clinical improvement after antiparasitic treatment of parenchymal neurocysticercosis is based on two independent retrospective studies published in 1992. In one of them, all untreated patients (49 of 49) had seizures in the

TABLE 2. Studies on anti-parasitic therapy for neurocysticercosis

Drug, treatment length (days), dose (mg/kg)	Yr first used	Reference(s)
Parenchymal		
Cystic		
Praziquantel, 15, 50	1979	13, 18, 29, 31, 32, 38, 67, 71, 72, 88, 94–96, 102
Albendazole, 30, 15	1987	18, 29, 49, 89, 94
Albendazole, 8, 15	1988	14, 55, 78, 94
Albendazole, 21, 15	1989	1
Albendazole, 3, 15	1989	3
Praziquantel, 7, 50	1990	35, 94
Praziquantel, 10, 100	1990	11
Praziquantel, 21, 50	1992	98
Albendazole, 15, 15	1992	21, 28
Albendazole, 10, 15	1995	72
Albendazole, 15, 30	1995	1
Praziquantel, 1, 75	1996	24, 25, 35, 69, 81
Degenerating		
Albendazole, 15, 15	1993	6, 36, 85
Albendazole, 8, 15	1994	79
Albendazole, 30, 15	1998	5, 6
Praziquantel, 1, 75	2000	80
Subarachnoid, cystic/racemose, albendazole, 8, 15	1992	4, 33, 77, 90
Parenchymal/subarachnoid, giant cysts		
Albendazole, 7, 15	1992	40, 58
Praziquantel, 15, 50[a]	2001	82
Albendazole, 30, 15[a]	2001	82
Albendazole, 7, 30	2001	58
Ventricle, cystic		
Albendazole, 15, 15[a]	1997	31, 83
Praziquantel, 15, 100[a]	1999	83
Albendazole, 30, 15[a]	1999	83

[a] Repeated courses.

TABLE 3. Arguments in favor of and against antiparasitic treatment for neurocysticercosis

Argument	Reply
Protreatment	
Rapid disappearance of cysts	No evidence that faster disappearance of cysts will result in better epilepsy control
Severe cases seen less frequently now	Less severe cases reflect improved sanitation and fewer massive infections
Series of albendazole- or praziquantel-treated patients have better evolution (fewer seizures) than untreated patients seen at the same centers	Inadequate "control" groups in initial studies
Fewer residual calcifications	No evidence that antiparasitic therapy results in fewer calcifications
Antitreatment	
Neurocysticercosis becomes symptomatic after a period of years as a result of onset of the process of parasite death	Questionable methodology of "controlled" studies; some patients persist with symptoms and live cysts for years
Antiparasitic treatment leads to acute cerebral inflammation and is severe and unnecessary	Inflammation can be controlled with steroids; chronic, moderate inflammation may lead to scars similar or worse than those from a short, acute, severe process
Reactions to treatment may lead to the death of the patient	Less than 10 deaths reported (mainly massive infections) among many albendazole or praziquantel-treated cases

follow-up, compared to 46% (54 of 118) of albendazole-treated patients (mean follow-up, 3 years) (106). In the other, 74% (20 of 27) of untreated patients had seizures in the follow-up, compared to 17% (16 of 95) in albendazole-treated patients (mean follow-up, 2.5 years) (38). In these studies, the rate of seizure recurrence in those refusing treatment was much higher than noted in patients treated with antiepileptic drugs alone (18, 75, 92). The increased relapse rates in the comparison group could be explained by the fact that patients who did not receive albendazole in these centers were obviously biased towards poor compliance and would have only returned to the hospital in the event of later seizures (54, 109).

To date, there is only one published prospective trial evaluating the clinical evolution of patients with viable neurocysticercosis treated with antiparasitic agents compared to no treatment. Carpio and colleagues studied 138 patients with cystic neurocysticercosis in an open-label study of steroids alone or together with either albendazole or praziquantel (18). Overall, there were no significant differences in the proportion of patients free of cysts at 6 months or 1 year, in the proportion free of seizures for 2 years, or in the rates of sequelae. There was also a high rate of resolution among patients with single lesions, raising the question of whether patients with inflamed lesions were rigorously excluded from that trial. Disappearance of lesions in the control group only occurred in cases with a single lesion, whereas nearly half of the cases that were free of parasites in the treatment arms had multiple cysts. Thus, this study, while not demonstrating significant differences, suggests benefit for those with multiple lesions.

Among many case series (19, 20, 34, 36, 85–87, 99), only three randomized, controlled trials of albendazole have been reported on patients with single enhancing lesions. Two studies demonstrated no significant difference in radiographic resolution (79, 93). The other demonstrated more rapid resolution with albendazole but no significant difference in the frequency of clinical events (5, 6).

Surgery. Prior to the advent of antiparasitic drugs, surgery was the primary therapy for neurocysticercosis, mainly open surgery for excision of large cysts or cysts in the ventricles. The role of surgical therapy in the management of neurocysticercosis has significantly decreased over time and is now mainly restricted to placement of ventricular shunts for hydrocephalus secondary to neurocysticercosis. The main problem in these cases is the high prevalence of shunt dysfunction; indeed, it is common for patients with hydrocephalus secondary to neurocysticercosis to have two or three shunt revisions (70). The protracted clinical course of these patients and their high mortality rates (up to 50% in two years) were directly related to the number of surgical interventions to change the shunt (23). According to one report, maintenance steroid therapy may decrease the frequency of shunt blockages (97). Many authors advocate shunting combined with antiparasitic drugs to further reduce the incidence of shunt failure (4, 83). Recently, less invasive procedures have been described, specifically the use of neuroendoscopic resection for ventricular cysts (8, 30). Overall results have been excellent, with much less morbidity than with open surgery (9).

Symptomatic and anti-inflammatory medication. Corticosteroids are frequently used in patients with neurocysticercosis. The most frequent regimen is dexamethasone at doses of between 4.5 and 12 mg/day. Prednisone at 1 mg/kg/day may replace dexamethasone when long-term steroid therapy is required. Corticosteroids are frequently used to decrease neurological symptoms due to the death of the parasite and are the primary management for chronic cysticercosis arachnoiditis or encephalitis, where up to 32 mg of dexamethasone per day is needed to reduce the brain edema accompanying this condition (42). Mannitol, at doses of 2 g/kg/day, is also used for acute intracranial hypertension secondary to neurocysticercosis.

Other medications commonly used to treat symptoms in neurocysticercosis patients are antiepileptic drugs and analgesics. Seizures secondary to neurocysticercosis usually respond well to first-line antiepileptic. Withdrawal of antiepileptic drugs can be achieved, although residual calcifications on CT scan mark patients for whom the risk of recurrent seizures is high. To use only a short period of antiepileptic therapy in patients with a single degenerating cysticercus, assuming that they have acute symptomatic crisis, has been proposed (17), but there are no data to support this assumption.

DISCUSSION GUIDELINES AND METHODS

When the panel began to discuss the preferred treatment for neurocysticercosis, it immediately became clear that neurocys-

ticercosis is not a single disease for which one therapy can be recommended. There are marked differences in clinical presentation, pathogenesis, natural history, and treatment options for the different forms. In the following sections, the consensus and disagreements of the panel are summarized. There was general agreement that the number of parasites is an important factor for determining treatment decisions. The panel chose to categorize patients as those having a single lesion, a few lesions, moderate to heavy parasite loads, and massive infections. For the sake of clarity, a threshold of five or fewer parasites was chosen to represent cases with a few lesions, and a threshold of 100 parasites was chosen to represent massive infections. Since the management recommendations were the same for patients with a single lesion and those with a few parasites, these two categories were later collapsed into one.

The panel categorized all available information according to level of quality of evidence (101) as follows: I, evidence obtained from at least one properly randomized controlled trial; II-1, evidence obtained from well-designed controlled trials without randomization; II-2, evidence obtained from well-designed cohort or case-control analytic studies, preferably from more than one center or research group; II-3. evidence obtained from multiple time series with or without the intervention, including dramatic results in uncontrolled experiments; and III, opinions of respected authorities, based on clinical experience; descriptive studies and case reports; or reports of expert committees.

The information provided below represents the recommended management for patients with the pure forms of the disease. Whenever there was no agreement, the proposed alternatives are described as positions a, b, and c in order of preference, according to the number of experts in the group who favored each option. For patients with mixed presentations of neurocysticercosis, a consideration of risks and benefits must be done to choose the order of interventions.

PANEL CONSENSUS—GENERAL CONCEPTS

(i) Guidelines for treatment of neurocysticercosis must be individualized in terms of number and location of lesions, as well as based on the viability of the parasites within the nervous system

(ii) Growth of a parenchymal cysticercus is not a common event and may be life-threatening. A growing parasite deserves active management, either with antiparasitic drugs or by surgical excision.

(iii) In patients with intracranial hypertension secondary to neurocysticercosis, the priority is to manage the hypertension problem before considering any other form of therapy. Antiparasitic drug treatment is never the main priority in the setting of elevated intracranial pressure

(iv) Antiepileptic drugs are the principal therapy for seizures in neurocysticercosis. In general, seizures should be managed in a similar manner to other causes of secondary seizures (remote symptomatic seizures), since they are due to an organic focus that has been present for a long time. However, after resolution of the parasitic infection with normalization of imaging studies, most patients who are seizure-free can eventually discontinue antiepileptic drugs. Antiparasitic drugs should not be regarded as an alternative for antiepileptic drug therapy.

OVERVIEW OF PARENCHYMAL BRAIN CYSTICERCOSIS

Viable Cysts

There was agreement that albendazole and praziquantel are effective antiparasitic agents, destroying most viable cysts. Whereas there was some disagreement with regard to the best management of patients with few cysts, in patients with more than a few parasites, a balance of risks and benefits led the group to reach a consensus in that the risk of cyst growth, ventricular invasion, or multiple episodes of cyst degeneration with the corresponding symptomatic periods outweighs the potential (but theoretical) benefits of milder inflammation and minor scarring by natural evolution. The majority felt that there is no contraindication for the simultaneous use of steroids, but one expert raised the possibility of interfering with the clearance of parasite remnants. Consensus also broke down on whether to use antiparasitic drugs in patients with massive (hundreds of viable cysts) infections, mainly due to a perception of high risk for severe side effects.

Enhancing Lesions

The panel felt that patients with a single enhancing lesion are likely to do well with antiepileptic drugs independently of whether antiparasitic therapy is added. While most panel members do not routinely use antiparasitic drugs for single enhancing cysticerci, some felt that faster radiological resolution merits its routine use, and others felt that antiparasitic drugs may be used in selected cases, i.e., those in which antiepileptic therapy cannot be adequately monitored and the risks of adverse outcomes from seizures are high. Conversely, for patients with massive infections (cysticercosis encephalitis), there was agreement that they should not be used because it may exacerbate the inflammatory reaction in the brain parenchyma. There was, however, no consensus on whether to use antiparasitic drugs in these patients after resolution of cerebral edema.

Calcifications

For patients with only calcified lesions, there was also consensus that there was no role for antiparasitic agents because the cysts are already dead. The recent description of contrast enhancement and edema around calcified brain cysts led to discussion of whether there will be a role for anti-inflammatory medication in such patients, but no controlled data exist yet (Table 4).

OVERVIEW OF EXTRAPARENCHYMAL CYSTICERCOSIS

Whenever hydrocephalus or intracranial hypertension is present, its management should be the first priority. It can generally be managed by means of a ventricular shunt. Since extraparenchymal neurocysticercosis is associated with a worse prognosis, there was a consensus towards aggressive manage-

TABLE 4. Guidelines for use of antiparasitic treatment in neurocysticercosis[a]

Type	Infection burden	Recommendations	Evidence
Parenchymal neurocysticercosis			
Viable (live cysts)	Mild (1 to 5 cysts)	(a) Antiparasitic treatment, with steroids	II-3
		(b) Antiparasitic treatment; steroids used only if side effects related to therapy appear	II-3
		(c) No antiparasitic treatment; neuroimaging follow-up	II-3
	Moderate (more than 5 cysts)	**Consensus: antiparasitic treatment with steroids**	II-3
	Heavy (more than 100 cysts)	(a) Antiparasitic treatment with high-dose steroids	III
		(b) Chronic steroid management; no antiparasitic treatment; neuroimaging follow-up	III
Enhancing lesions (degenerating cysts)	Mild or moderate	(a) No antiparasitic treatment; neuroimaging follow-up	I
		(b) Antiparasitic treatment with steroids	II-3
		(c) Antiparasitic treatment; steroids only if side effects develop	II-3
	Heavy (cysticercotic encephalitis)	**Consensus: no antiparasitic treatment; high-dose steroids and osmotic diuretics**	III
Calcified cysticerci	Any number	**Consensus: no antiparasitic treatment**	
Extraparenchymal neurocysticercosis			
Ventricular cysticercosis		**Consensus: neuroendoscopic removal, when available.** If not available:	III
		(a) CSF diversion followed by antiparasitic treatment, with steroids	III
		(b) open surgery (mainly for ventricle cysts)	III
Subarachnoid cysts, including giant cysts or racemose cysticercosis, and chronic meningitis		**Consensus: antiparasitic treatment with steroids, ventricular shunt if there is hydrocephalus**	II-3
Hydrocephalus with no visible cysts on neuroimaging		**Consensus: ventricular shunt; no antiparasitic treatment**	III
Spinal cysticercosis, intra- or extramedullary[b]		**Consensus: primarily surgical; anecdotal reports of successful use of albendazole with steroids**	III
Ophthalmic cysticercosis[b]		**Consensus: surgical resection of cysts[c]**	II-3

[a] Levels of recommendations (a, b, and c) and quality of evidence (101) are defined in the text.
[b] Given the rarity of these presentations, treatment was discussed based on the published literature (22, 27).
[c] Experience in the use of albendazole with methylprednisolone for treatment of retinal cysticercosis and as a presurgical treatment for intravitreal cysticercosis has been published (7) but not yet replicated.

ment. The panel felt that patients with cysts located in the ventricular system should be treated surgically, especially if proper technology for neuroendoscopical resection is available. The location of the cysts and the presence of ependymitis need to be assessed prior to planning the surgical approach, and the possibility of acute blockage of the cerebrospinal fluid flow during antiparasitic treatment must be borne in mind.

As for growing parenchymal cysts, a warning was issued for basal subarachnoid cysticercosis. As far as is known, this type of neurocysticercosis is progressive and has a grim prognosis. There was consensus that cysticercosis of the basal cisterns should be treated with antiparasitic drugs. This is based on the limitations of surgical resection, the poor prognosis with diversion procedures alone, and case series that used shunting plus antiparasitic drugs (4, 33, 82). The optimal duration of antiparasitic treatment for this type of lesion is not known, but it was felt that therapy should be sustained for longer than is routine for parenchymal disease (Table 4). There was consensus that all patients with subarachnoid cysticercosis should be managed with corticosteroids as an adjunct to antiparasitic therapy. Large (giant) cysts in the Sylvian fissure seem to respond well to corticosteroids along with antiparasitic drugs (33, 40, 77, 82).

COMMENTS

Cysticercosis should no longer be considered an "exotic" disease. Besides being the leading cause of late-onset seizures in the developing world, it is now also frequently diagnosed in industrialized countries because of increased immigration from areas where it is endemic, with over 1,000 cases diagnosed annually in the United States alone (91, 107).

Probably the best advice on the treatment of neurocysticercosis would be not to generalize but to approach and assess each case individually. However, neurologists and infectious disease specialists who are not familiar with the disease need at least a basic set of principles to follow. In developing such principles, the panel have tried to avoid the trap of futile discussions and to expose, in the clearest way, the current preferred treatment options for each type of neurocysticercosis.

The selection of a treatment option must include in the consideration of risks and benefits the economic situation of the patient. In areas where neurocysticercosis is endemic, where most cases are seen, follow-up neuroimaging examinations may not be performed for economic reasons, and patients may not have access to modern surgical techniques or may be managed in centers where intensive care is not available. The

standard of care will change, but still the best option has to be defined.

The current controversy on whether the use of antiparasitic agents is of benefit in the long-term control of epileptic seizures in neurocysticercosis led to much confusion about whether such agents should be used in any form of the disease. This undesirable situation causes inappropriate use of antiparasitic drugs, i.e., in cases with already calcified parasites or in cysticercosis encephalitis. Even more dangerous, physicians may refrain from using antiparasitic treatment when it is the best treatment option, i.e., for a growing cyst. This "conservative" therapeutic approach may even lead to the death of the patient if the period of inaction extends long enough.

A further conclusion of the panel was the inadequacy of study designs and outcomes in the treatment of neurocysticercosis. This does not reflect so much poorly conducted trials (sometimes the case) as lack of agreement that would permit definition of specific research questions, to homogenize treatment groups in similar trials, or to perform multicentric trials to include larger numbers of patients with similar forms of neurocysticercosis. The inclusion of long-term outcomes, including the proportion of residual calcifications and the appearance of hydrocephalus, is mandatory to provide a fair evaluation of risk-benefit analysis.

REFERENCES

1. **Agapejev, S., M. D. Da Silva, and A. K. Ueda.** 1996. Severe forms of neurocysticercosis: treatment with albendazole. Arq. Neuropsiquiatr. **54:** 82–93.
2. **Agapejev, S., D. A. Meira, B. Barraviera, J. M. Machado, P. C. Pereira, R. P. Mendes, A. Kamegasawa, and P. R. Curi.** 1988. Neurocysticercosis: treatment with albendazole and dextrochloropheniramine (preliminary report). Rev. Inst. Med. Trop. Sao Paulo **30:**387–389.
3. **Alarcon, F., L. Escalante, G. Duenas, M. Montalvo, and M. Roman.** 1989. Neurocysticercosis. Short course of treatment with albendazole. Arch. Neurol. **46:**1231–1236.
4. **Bandres, J. C., A. C. White, Jr., T. Samo, E. C. Murphy, and R. L. Harris.** 1992. Extraparenchymal neurocysticercosis: report of five cases and review of management. Clin. Infect. Dis. **15:**799–811.
5. **Baranwal, A. K., P. D. Singhi, N. Khandelwal, and S. C. Singhi.** 1998. Albendazole therapy in children with focal seizures and single small enhancing computerized tomographic lesions: a randomized, placebo-controlled, double blind trial. Pediatr. Infect. Dis. J. **17:**696–700.
6. **Baranwal, A. K., P. D. Singhi, S. C. Singhi, and N. Khandelwal.** 2001. Seizure recurrence in children with focal seizures and single small enhancing computed tomographic lesions: prognostic factors on long-term follow-up. J. Child. Neurol. **16:**443–445.
7. **Berche, M., B. Hayot, M. Mokrane, G. Najjar, and E. Bouzas.** 1990. Ocular cysticercosis, typical forms and treatment. Ophthalmologie **4:**377–379. (In French.)
8. **Bergsneider, M.** 1999. Endoscopic removal of cysticercal cysts within the fourth ventricle. J. Neurosurg. **91:**340–345.
9. **Bergsneider, M., L. T. Holly, J. H. Lee, W. A. King, and J. G. Frazee.** 2000. Endoscopic management of cysticercal cysts within the lateral and third ventricles. J. Neurosurg. **92:**14–23.
10. **Bickerstaff, E. R., P. C. P. Cloake, B. Hughes, and W. T. Smith.** 1952. The racemose form of cerebral cysticercosis. Brain **75:**1–18.
11. **Bittencourt, P. R., C. M. Gracia, A. M. Gorz, S. Mazer, and T. V. Oliveira.** 1990. High-dose praziquantel for neurocysticercosis: efficacy and tolerability. Eur. Neurol. **30:**229–234.
12. **Bittencourt, P. R. M., C. M. Gracia, R. Martins, A. G. Fernandes, H. W. Diekmann, and W. Jung.** 1992. Phenytoin and carbamazepine decrease oral bioavailability of praziquantel. Neurology **42:**492–495.
13. **Botero, D., and S. Castano.** 1982. Treatment of cysticercosis with praziquantel in Colombia. Am. J. Trop. Med. Hyg. **31:**811–821.
14. **Botero, D., C. S. Uribe, J. L. Sanchez, T. Alzate, G. Velasquez, N. E. Ocampo, and L. A. Villa.** 1993. Short course albendazole treatment for neurocysticercosis in Columbia. Trans. R. Soc Trop. Med. Hyg. **87:**576–577.
15. **Brailsford, J. F.** 1941. Cysticercus cellulosae-Its radiographic detection in the musculature and the central nervous system. Br. J. Radiol. **XIV:**79–93.
16. **Brink, G., H. Schenone, V. Diaz, M. Parra, and M. Corrales.** 1980. Neurocisticercosis. Tratamiento con praziquantel. Estudio preliminar. Bol. Chil. Parasitol. **35:**66–70.
17. **Carpio, A., A. Escobar, and W. A. Hauser.** 1998. Cysticercosis and epilepsy: a critical review. Epilepsia **39:**1025–1040.
18. **Carpio, A., F. Santillan, P. Leon, C. Flores, and W. A. Hauser.** 1995. Is the course of neurocysticercosis modified by treatment with antihelminthic agents? Arch. Intern. Med **155:**1982–1988.
19. **Chandy, M. J., V. Rajshekhar, S. Ghosh, S. Prakash, T. Joseph, J. Abraham, and S. M. Chandi.** 1991. Single small enhancing CT lesions in Indian patients with epilepsy: clinical, radiological and pathological considerations. J. Neurol. Neurosurg. Psychiatry **54:**702–705.
20. **Chandy, M. J., V. Rajshekhar, S. Prakash, S. Ghosh, T. Joseph, J. Abraham, and S. M. Chandi.** 1989. Cysticercosis causing single, small CT lesions in Indian patients with seizures. Lancet **i:**390–391.
21. **Chotmongkol, V.** 1993. Treatment of neurocysticercosis with a two week course of albendazole. Southeast Asian J. Trop. Med. Public Health **24:** 396–398.
22. **Colli, B. O., J. A. Assirati Junior, H. R. Machado, F. dos Santos, and O. M. Takayanagui.** 1994. Cysticercosis of the central nervous system. II. Spinal cysticercosis. Arq. Neuropsiquiatr. **52:**187–199.
23. **Colli, B. O., N. Martelli, J. A. Assirati, Jr., H. R. Machado, and S. de Vergueiro Forjaz.** 1986. Results of surgical treatment of neurocysticercosis in 69 cases. J. Neurosurg. **65:**309–315.
24. **Corona, T., R. Lugo, R. Medina, and J. Sotelo.** 1999. Esquema corto de praziquantel para el tratamiento de la neurocisticercosis parenquimatosa. Gac. Med. Mex. **135:**369–372.
25. **Corona, T., R. Lugo, R. Medina, and J. Sotelo.** 1996. Single-day praziquantel therapy for neurocysticercosis. N. Engl. J. Med. **334:**125.
26. **Corona, T., D. Pascoe, D. Gonzalez-Barranco, P. Abad, L. Landa, and B. Estanol.** 1986. Anticysticercous antibodies in serum and cerebrospinal fluid in patients with cerebral cysticercosis. J. Neurol. Neurosurg. Psychiatry **49:**1044–1049.
27. **Corral, I., C. Quereda, A. Moreno, R. Lopez-Velez, J. Martinez-San-Millan, A. Guerrero, and J. Sotelo.** 1996. Intramedullary cysticercosis cured with drug treatment. A case report. Spine **21:**2284–2287.
28. **Cruz, I., M. E. Cruz, F. Carrasco, and J. Horton.** 1995. Neurocysticercosis: optimal dose treatment with albendazole. J. Neurol. Sci. **133:**152–154.
29. **Cruz, M., I. Cruz, and J. Horton.** 1991. Albendazole versus praziquantel in the treatment of cerebral cysticercosis: clinical evaluation. Trans. R. Soc. Trop. Med. Hyg. **85:**244–247.
30. **Cudlip, S. A., P. R. Wilkins, and H. T. Marsh.** 1998. Endoscopic removal of a third ventricular cysticercal cyst. Br. J. Neurosurg. **12:**452–454.
31. **Cuetter, A. C., J. Garcia-Bobadilla, L. G. Guerra, F. M. Martinez, and B. Kaim.** 1997. Neurocysticercosis: focus on intraventricular disease. Clin. Infect. Dis. **24:**157–164.
32. **De Ghetaldi, L. D., R. M. Norman, and A. W. Douville, Jr.** 1983. Cerebral cysticercosis treated biphasically with dexamethasone and praziquantel. Ann. Intern. Med. **99:**179–181.
33. **Del Brutto, O. H.** 1997. Albendazole therapy for subarachnoid cysticerci: clinical and neuroimaging analysis of 17 patients. J. Neurol. Neurosurg. Psychiatry **62:**659–661.
34. **Del Brutto, O. H.** 1993. The use of albendazole in patients with single lesions enhanced on contrast CT. N. Engl. J. Med. **328:**356–357.
35. **Del Brutto, O. H., X. Campos, J. Sanchez, and A. Mosquera.** 1999. Single-day praziquantel versus 1-week albendazole for neurocysticercosis. Neurology **52:**1079–1081.
36. **Del Brutto, O. H., and L. A. Quintero.** 1995. Cysticercosis mimicking brain tumor: the role of albendazole as a diagnostic tool. Clin. Neurol. Neurosurg. **97:**256–258.
37. **Del Brutto, O. H., V. Rajshekhar, A. C. White, Jr., V. C. Tsang, T. E. Nash, O. M. Takayanagui, P. M. Schantz, C. A. Evans, A. Flisser, D. Correa, D. Botero, J. C. Allan, E. Sarti, A. E. Gonzalez, R. H. Gilman, and H. H. Garcia.** 2001. Proposed diagnostic criteria for neurocysticercosis. Neurology **57:**177–183.
38. **Del Brutto, O. H., R. Santibanez, C. A. Noboa, R. Aguirre, E. Diaz, and T. A. Alarcon.** 1992. Epilepsy due to neurocysticercosis: analysis of 203 patients. Neurology **42:**389–392.
39. **Del Brutto, O. H., and J. Sotelo.** 1988. Neurocysticercosis: an update. Rev Infect. Dis. **10:**1075–1087.
40. **Del Brutto, O. H., J. Sotelo, R. Aguirre, E. Diaz-Calderon, and T. A. Alarcon.** 1992. Albendazole therapy for giant subarachnoid cysticerci. Arch. Neurol. **49:**535–538.
41. **Del Brutto, O. H., J. Sotelo, and G. C. Roman.** 1997. Neurocysticercosis: a clinical handbook. Swets and Zeitliger, Lisse, The Netherlands.
42. **Del Brutto, O. H., J. Sotelo, and G. C. Roman.** 1993. Therapy for neurocysticercosis: a reappraisal. Clin. Infect. Dis. **17:**730–735.
43. **Del Brutto, O. H., N. H. Wadia, M. Dumas, M. Cruz, V. C. Tsang, and P. M. Schantz.** 1996. Proposal of diagnostic criteria for human cysticercosis and neurocysticercosis. J. Neurol. Sci. **142:**1–6.
44. **Dixon, H. B., Lipscomb, F. M.** 1961. Cysticercosis: an analysis and follow-up of 450 cases, vol. 299. Medical Research Council, London, UK.
45. **Dixon, H. B. F., and W. H. Hargreaves.** 1944. Cysticercosis (*Taenia solium*): a further ten years' clinical study, covering 284 cases. Q. J. Med. **13:**107–121.

46. **Dixon, H. B. F., and D. W. Smithers.** 1934. Epilepsy in cysticercosis (*Taenia solium*). A study of seventy-one cases. Q. J. Med. **3:**603–616.
47. **Dumas, J. L., J. M. Vusy, and C. Belin.** 1997. Parenchymal neurocysticercosis: follow up and staging by MRI. Neuroradiology **39:**12–16.
48. **Escobar, A.** 1983. The pathology of neurocysticercosis, p. 27–54. *In* E. Palacios, J. Rodriguez-Carbajal, and J. M. Taveras (ed.), Cysticercosis of the central nervous system. Charles C. Thomas, Springfield, Ill.
49. **Escobedo, F., P. Penagos, J. Rodriguez, and J. Sotelo.** 1987. Albendazole therapy for neurocysticercosis. Arch. Intern. Med. **147:**738–741.
50. **Estanol, B., T. Corona, and P. Abad.** 1986. A prognostic classification of cerebral cysticercosis: therapeutic implications. J. Neurol. Neurosurg. Psychiatry **49:**1131–1134.
51. **Flisser, A.** 1994. Taeniasis and cysticercosis due to *Taenia solium*. Prog. Clin. Parasitol. **4:**77–116.
52. **Flisser, A., D. Gonzalez, M. Shkurovich, I. Madrazo, D. Correa, J. Rodriguez-Carbajal, S. Cohen, E. Rodriguez-del-Rosal, M. Collado, B. Fernandez, et al.** 1990. Praziquantel treatment of porcine brain and muscle Taenia solium cysticercosis. 1. Radiological, physiological and histopathological studies. Parasitol. Res. **76:**263–269.
53. **Garcia, H. H., and O. H. Del Brutto.** 2000. Taenia solium cysticercosis. Infect. Dis. Clin. North Am. **14:**97–119.
54. **Garcia, H. H., and R. H. Gilman.** 1995. Medical treatment of cysticercosis: ineffective vs effective. Arch. Neurol. **52:**941.
55. **Garcia, H. H., R. H. Gilman, J. Horton, M. Martinez, G. Herrera, J. Altamirano, J. M. Cuba, N. Rios-Saavedra, M. Verastegui, J. Boero, and A. E. Gonzalez.** 1997. Albendazole therapy for neurocysticercosis: a prospective double-blind trial comparing 7 versus 14 days of treatment. Cysticercosis Working Group in Peru. Neurology **48:**1421–1427.
56. **Garcia, H. H., and S. M. Martinez.** 1999. *Taenia solium* taeniasis/cysticercosis, 2nd ed. Universo, Lima, Peru.
57. **Goldberg, M. A.** 1984. Praziquantel for cysticercosis of the brain parenchyma. N. Engl. J. Med. **311:**732–734.
58. **Gongora, F., J. Santos, R. Hernandez, H. Jung, D. Gonzalez, J. L. Soto, and C. Marquez.** 2001. Albendazole therapy for subarachnoidal and intraventricular cysticercosis: a prospective double-blind trial comparing 15 versus 30 mg/kg/dayay. Neurology **56**(Suppl. 3)**:**A404.
59. **Groll, E. W.** 1982. Chemotherapy of human cysticercosis with praziquantel, p. 207–218. *In* A. Flisser et al. (ed.), Cysticercosis: present state of knowledge and perspectives. Academic Press, New York, N.Y.
60. **Henneberg, R.** 1912. Die tierischen parasiten des zentralnervensystem, p. 642–683. *In* M. Lewandowsky (ed.), Handbuch der neurologie, vol. III. Springer, Berlin, Germany.
61. **Jung, H., M. Hurtado, M. T. Medina, M. Sanchez, and J. Sotelo.** 1990. Dexamethasone increases plasma levels of albendazole. J. Neurol. **237:**279–280.
62. **Jung, H., M. Hurtado, M. Sanchez, M. T. Medina, and J. Sotelo.** 1990. Plasma and cerebrospinal fluid levels of albendazole and praziquantel in patients with neurocysticercosis. Clin. Neuropharmacol. **13:**559–564.
63. **Kim, S. K., K. C. Wang, S. H. Paek, K. S. Hong, and B. K. Cho.** 1999. Outcomes of medical treatment of neurocysticercosis: a study of 65 cases in Cheju Island, Korea. Surg. Neurol. **52:**563–569.
64. **Kramer, L. D.** 1990. Antihelminthic therapy for neurocysticercosis. Arch. Neurol. **47:**1059–1060.
65. **Kramer, L. D.** 1995. Medical treatment of cysticercosis–ineffective. Arch. Neurol. **52:**101–102.
66. **Kramer, L. D., G. E. Locke, S. E. Byrd, and J. Daryabagi.** 1989. Cerebral cysticercosis: documentation of natural history with CT. Radiology **171:**459–462.
67. **Lawner, P. M.** 1983. Medical management of neurocysticercosis with Praziquantel. Bull. Clin. Neurosci. **48:**102–105.
68. **Leblanc, R., K. F. Knowles, D. Melanson, J. D. MacLean, G. Rouleau, and J. P. Farmer.** 1986. Neurocysticercosis: surgical and medical management with praziquantel. Neurosurgery **18:**419–427.
69. **Lopez-Gomez, M., N. Castro, H. Jung, J. Sotelo, and T. Corona.** 2001. Optimization of the single-day praziquantel therapy for neurocysticercosis. Neurology **57:**1929–1930.
70. **Madrazo, I. and A. Flisser.** 1992. Cysticercosis, p. 1419–1430. *In* M. L. J. Apuzzo (ed.), Brain surgery: complication avoidance and management. Churchill Livingstone, New York, N.Y.
71. **Markwalder, K., K. Hess, A. Valavanis, and F. Witassek.** 1984. Cerebral cysticercosis: treatment with praziquantel. Report of two cases. Am. J. Trop. Med. Hyg. **33:**273–280.
72. **Martinez, H. R., R. Rangel-Guerra, J. H. Arredondo-Estrada, A. Marfil, and J. Onofre.** 1995. Medical and surgical treatment in neurocysticercosis a magnetic resonance study of 161 cases. J. Neurol. Sci. **130:**25–34.
73. **McArthur, W. P.** 1934. Cysticercosis as seen in the British army with special reference to the production of epilepsy. Trans. R. Soc. Trop. Med. Hyg. **27:**343–363.
74. **Miller, B., V. Grinnell, M. A. Goldberg, and D. Heiner.** 1983. Spontaneous radiographic disappearance of cerebral cysticercosis: three cases. Neurology **33:**1377–1379.
75. **Mitchell, W. G., and T. O. Crawford.** 1988. Intraparenchymal cerebral cysticercosis in children: diagnosis and treatment. Pediatrics **82:**76–82.
76. **Moodley, M., and A. Moosa.** 1989. Treatment of neurocysticercosis: is praziquantel the new hope? Lancet **i:**262–263.
77. **Noboa, C.** 1993. Albendazole therapy for giant subarachnoid cysticerci. Arch. Neurol. **50:**347–348.
78. **Padma, M. V., M. Behari, N. K. Misra, and G. K. Ahuja.** 1995. Albendazole in neurocysticercosis. Natl. Med. J. India **8:**255–258.
79. **Padma, M. V., M. Behari, N. K. Misra, and G. K. Ahuja.** 1994. Albendazole in single CT ring lesions in epilepsy. Neurology **44:**1344–1346.
80. **Pretell, E. J., H. H. Garcia, N. Custodio, C. Padilla, M. Alvarado, R. H. Gilman, and M. Martinez.** 2000. Short regimen of praziquantel in the treatment of single brain enhancing lesions. Clin. Neurol. Neurosurg. **102:**215–218.
81. **Pretell, E. J., H. H. Garcia, R. H. Gilman, H. Saavedra, M. Martinez, and the Cysticercosis Working Group in Peru.** 2001. Failure of one-day praziquantel treatment in patients with multiple neurocysticercosis lesions. Clin. Neurol. Neurosurg. **103:**175–177.
82. **Proano, J. V., I. Madrazo, F. Avelar, B. Lopez-Felix, G. Diaz, and I. Grijalva.** 2001. Medical treatment for neurocysticercosis characterized by giant subarachnoid cysts. N. Engl. J. Med. **345:**879–885.
83. **Proano, J. V., I. Madrazo, L. Garcia, E. Garcia-Torres, and D. Correa.** 1997. Albendazole and praziquantel treatment in neurocysticercosis of the fourth ventricle. J. Neurosurg. **87:**29–33.
84. **Rabiela, M. T., A. Rivas, and A. Flisser.** 1989. Morphological types of Taenia solium cysticerci. Parasitol. Today **5:**357–359.
85. **Rajshekhar, V.** 1993. Albendazole therapy for persistent, solitary cysticercus granulomas in patients with seizures. Neurology **43:**1238–1240.
86. **Rajshekhar, V.** 1991. Etiology and management of single small CT lesions in patients with seizures: understanding a controversy. Acta Neurol. Scand. **84:**465–470.
87. **Rajshekhar, V., and J. Abraham.** 1990. Disappearing CT lesions in Indian patients with epilepsy. J. Neurol. Neurosurg. Psychiatry **53:**818–819.
88. **Robles, C., and M. Chavarria Chavarria.** 1979. Presentacion de un caso clinico de cisticercosis cerebral tratado medicamente con un nuevo farmaco: praziquantel. Salud Publica Mex. **21:**603–618.
89. **Sanchetee, P. C., S. Venkataraman, R. M. Dhamija, and A. K. Roy.** 1994. Albendazole therapy for neurocysticercosis. J. Assoc. Physicians India **42:**116–117.
90. **Santoyo, H., R. Corona, and J. Sotelo.** 1991. Total recovery of visual function after treatment for cerebral cysticercosis. N. Engl. J. Med. **324:**1137–1139.
91. **Schantz, P. M., P. P. Wilkins, and V. C. W. Tsang.** 1998. Immigrants, imaging and immunoblots: the emergence of neurocysticercosis as a significant public health problem, p. 213–241. *In* W. M. Scheld, W. A. Craig, and J. M. Hughes (ed.), Emerging infections 2. ASM Press, Washington, D.C.
92. **Shandera, W. X., A. C. White, Jr., J. C. Chen, P. Diaz, and R. Armstrong.** 1994. Neurocysticercosis in Houston, Texas. A report of 112 cases. Medicine (Baltimore) **73:**37–52.
93. **Singhi, P., M. Ray, S. Singhi, and N. Khandelwal.** 2000. Clinical spectrum of 500 children with neurocysticercosis and response to albendazole therapy. J. Child. Neurol. **15:**207–213.
94. **Sotelo, J., O. H. del Brutto, P. Penagos, F. Escobedo, B. Torres, J. Rodriguez-Carbajal, and F. Rubio-Donnadieu.** 1990. Comparison of therapeutic regimen of anticysticercal drugs for parenchymal brain cysticercosis. J. Neurol. **237:**69–72.
95. **Sotelo, J., F. Escobedo, and P. Penagos.** 1988. Albendazole vs praziquantel for therapy for neurocysticercosis. A controlled trial. Arch. Neurol. **45:**532–534.
96. **Spina-Franca, A., J. P. Nobrega, J. A. Livramento, and L. R. Machado.** 1982. Administration of praziquantel in neurocysticercosis. Tropenmed. Parasitol. **33:**1–4.
97. **Suastegui Roman, R. A., J. L. Soto-Hernandez, and J. Sotelo.** 1996. Effects of prednisone on ventriculoperitoneal shunt function in hydrocephalus secondary to cysticercosis: a preliminary study. J. Neurosurg. **84:**629–633.
98. **Takayanagui, O. M., and E. Jardim.** 1992. Therapy for neurocysticercosis. Comparison between albendazole and praziquantel. Arch. Neurol. **49:**290–294.
99. **Thussu, A., A. Arora, V. Lal, S. Prabhakar, and I. M. Sawhney.** 2001. Albendazole therapy for solitary persistent cysticercus granuloma. Neurol. India **49:**95–97.
100. **Trelles, J. O., and L. Trelles.** 1978. Cysticercosis of the nervous system, p. 291–320. *In* P. J. Wynken and G. W. Bruyn (ed.), Handbook of clinical neurology. North-Holland, Amsterdam, The Netherlands.
101. **U.S. Preventive Services Task Force.** 1996. Guide to Clinical Preventive Services (CPS), 2nd ed. International Medical Publishing, Alexandria, Va.
102. **Van Dellen, J. R., and C. P. McKeown.** 1988. Praziquantel (pyrazinoisoquinolone) in active cerebral cysticercosis. Neurosurgery **22:**92–96.
103. **Vanijanonta, S., and D. Bunnag.** 1985. Treatment of cysticercosis with praziquantel at the Bangkok Hospital for Tropical Diseases. Southeast Asian J. Trop. Med. Public Health **16:**435–440.

104. **Vasconcelos, D.** 1990. Del quiste al granuloma cisticercoso mediante tomografia craneal computarizada. Gac. Med. Mex. **126:**401–404.
105. **Vazquez, M. L., H. Jung, and J. Sotelo.** 1987. Plasma levels of praziquantel decrease when dexamethasone is given simultaneously. Neurology **37:**1561–1562.
106. **Vazquez, V., and J. Sotelo.** 1992. The course of seizures after treatment for cerebral cysticercosis. N. Engl. J. Med. **327:**696–701.
107. **White, A. C., Jr.** 2000. Neurocysticercosis: updates on epidemiology, pathogenesis, diagnosis, and management. Annu. Rev. Med. **51:**187–206.
108. **White, A. C., Jr., P. Robinson, and R. Kuhn.** 1997. Taenia solium cysticercosis: host-parasite interactions and the immune response. Chem. Immunol. **66:**209–230.
109. **White, A. C., Jr., and W. X. Shandera.** 1992. Seizures and treatment for cerebral cysticercosis. N. Engl. J. Med. **327:**1955–1956.
110. **Yoshino, K.** 1933. Studies on the postembryonal development of *Taenia solium*: III. On the development of cysticercus cellulosae within the definitive intermediate host. J. Med. Assoc. Formosa **32:**166–169.
111. **Zhu, S.** 1992. A follow-up study of 420 cases of cerebral cysticercosis. Zhonghua Shen Jing Jing Shen Ke Za Zhi **25:**243–245, 255. (In Chinese.)