J. Anat. (1987), **152**, pp. 205–208
With 3 figures
Printed in Great Britain

Anatomical Note

Variations of the interparietal bone in man

G. P. PAL*

Department of Anatomy, The Medical College of Pennsylvania, Philadelphia, PA 19129 *USA*

(*Accepted* 1 *July* 1986)

The ossification of the interparietal bone, including the shape and site of occurrence of the pre-interparietal, has been reported by Pal, Tamanker, Routal & Bhagwat (1984). This note is intended to report a further variation in the pre-interparietal bone and to discuss the possibilities of various variations in the interparietal region. Differentiation of a pre-interparietal bone from a sutural bone and from other variations in the interparietal region is important because of the increased use of these bones in classification of non-metric cranial variants for separation of populations (Pal, Bhagwat & Routal, 1986).

The present variation was observed in one adult skull of unknown sex from the collection of the Mutter Museum in Philadelphia. Here, the pre-interparietal bone consisted of two small triangular ossicles posterior to the lambda (Fig. 1). These two bones are the result of a vertical suture running downward from the lambda to a transverse suture extending between the two lambdoidal sutures. The transverse suture was situated 4·5 cm above the external occipital protuberance.

The interparietal part of the squamous occipital bone above the highest nuchal line develops in membrane, usually from two pairs of centres (Ranke, 1913; Srivastava, 1977; Pal *et al.* 1984). The first pair of centres appears above the supraoccipital cartilage and forms two lateral plates of bone (*a* in Figs. 2, 3). A second pair of centres (one centre on either side of the midline) appears between the two lateral plates and these fuse to form the central portion of the interparietal bone. This is a large part of the bone extending from the lambda to a little distance above the external occipital protuberance (*b* in Fig. 2). In addition to these two pairs of centres, occasionally a third pair of centres (pre-interparietal) appears near the upper angle of the bone (Ranke, 1913; Breathnach, 1965; Srivastava, 1977; Pal *et al.* 1984). The presence of this third pair of centres has been confirmed embryologically by Sappey (1876). To begin with, the centres of the third pair appear on either side of the midline. Because of the presence of this pair of centres (pre-interparietal) the central portion of the interparietal bone (which is otherwise formed by the second pair alone) is formed by two pairs of centres, i.e. the lower part by the second pair and the upper part by the third pair (Pal *et al.* 1984). Failure of fusion between these two pairs of centres gives rise to a single triangular bone placed posterior to the lambda and separated from the bone developed from the second pair of centres by a transverse suture. This is a true pre-interparietal bone and has been reported and depicted (as Fig. 6) by Pal *et al.* (1984).

* Present address: Department of Anatomy, Government Medical College, Surat–395001, India.

Fig. 1. Two pieces of pre-interparietal bone resulted due to failure of fusion of third pair of centres with each other at the midline and below with the second pair of centres.

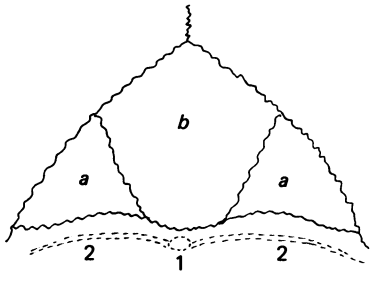

Fig. 2. Diagram showing lateral plate (*a*); central piece (*b*); external occipital protuberance (1); superior nuchal line (2).

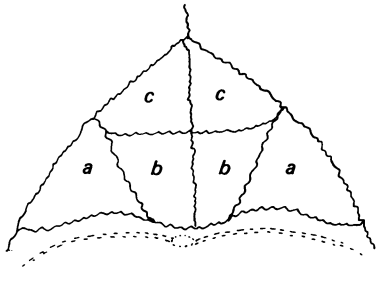

Fig. 3. Diagram showing maximum variations in the interparietal region which may result due to non-fusion of three pairs of centres with each other. Lateral plates (*a*); lower half of central piece (*b*); upper half of central piece (*c*).

Very recently, Saxena, Chowdhary & Jain (1986) have considered the central piece of bone (similar to *b* in Fig. 2) as a single pre-interparietal bone. Srivastava (1977) and Pal *et al.* (1984) consider this bone to be developed from the second pair of centres. A pre-interparietal bone is always separated from the remaining interparietal bone by a transverse suture extending between the two lambdoid sutures 4 cm above the external occipital protuberance (Pal *et al.* 1984). The pre-interparietal bone reported by Saxena *et al.* (1986) is bounded below by a suture whose apex is just above the external occipital protuberance. Apparently this suture is the lower limit of a central piece of bone formed by the second pair of centres and not that of the pre-interparietal bone as claimed by these authors. Pre-interparietal centres are only

occasional centres, their failure of fusion with the second pair of centres and the resulting single pre-interparietal bone must be extremely rare. Saxena *et al.* (1986) reported separate pre-interparietal bones in 4 skulls out of 40 (10 %). This seems too high a frequency for such rare centres to occur and then to fail to fuse with the remaining interparietal bone. It seems likely that their pre-interparietal bone is, in fact, the central piece of bone which develops from the second pair of centres.

The condition shown in Figure 1 resulted from the failure of fusion of the third pair of centres with each other in the midline and with the bone formed from the second pair of centres below. Thus in this skull the pre-interparietal bone has developed as two symmetrical halves. This variation was not observed in our previous study (Pal *et al.* 1984). Failure of fusion between the three pairs of centres and between these centres and the supraoccipital (cartilaginous part) can give rise to a maximum of six pieces of bones (three on either side) in the interparietal region (Fig. 3). These bony ossicles may occur singly or in groups and in various combinations. Through their size may vary from skull to skull, their position and shape will remain fixed. Saxena *et al.* (1986) have reported 3 segments of the pre-interparietal bone in one skull. A close examination of their illustration shows that the third piece on the right side is a sutural bone in the lambdoid suture and not a part of the pre-interparietal bone. However, the other two pieces, middle and left, are pieces of this bone and are exactly similar to the ossicles seen in Figure 1. The pre-interparietal bone being derived from a pair of centres cannot give rise to more than two ossicles. Thus, the presence of sutural bones in the lambdoid suture may be misleading. The various variations of interparietal (and pre-interparietal bones) should be identified by their shape and positions as shown in Figure 3. The presence of a sutural bone at the lambda or in the lambdoidal sutures may change the shape of these ossicles to a certain extent but cannot change their respective positions or numbers. Any variation other than that shown in Figure 3 has not yet been reported.

As has been suggested previously (Pal *et al.* 1984) the term 'pre-interparietal' is misleading and the bone(s) should be referred to as the upper central piece or pieces (if the third pair of centres fail to fuse) of the interparietal bone.

SUMMARY

In an adult skull a pre-interparietal bone was found to be present in two symmetrical pieces on either side of the midline. This is the result of failure of fusion of a third pair of centres with each other on the midline. The possibilities of variations due to non-fusion of various pairs of the centres in the interparietal area and their differentiation from surrounding sutural bones are discussed.

The author is grateful to Ms Gretchen Worden, curator of the Mutter Museum, College of Physicians of Philadelphia, for permission to study the collection in the museum. He also thanks Ms Carolyn Stewart for typing the manuscript.

REFERENCES

BREATHNACH, A. S. (1965). In *Frazer's Anatomy of the Human Skeleton*, 6th ed., p. 190. London: J. & A. Churchill.

PAL, G. P., TAMANKAR, B. P., ROUTAL, R. V. & BHAGWAT, S. S. (1984). The ossification of the membranous part of the squamous occipital bone in man. *Journal of Anatomy* **138**, 259–266.

PAL, G. P., BHAGWAT, S. S. & ROUTAL, R. V. (1986). A study of sutural bones in Gujarati (Indian) crania. *Anthropologischer Anzeiger* **44**, 67–76.

RANKE, J. (1913). Cited by E. A. Schafer, J. Symington & T. M. Bryce (1915) in *Quain's Elements of Anatomy*, 11th ed., vol. IV, part 1, pp. 53–55. London: Longmans, Green & Co.

SAPPEY, P. C. (1876). Cited by F. Keibel & F. P. Mall (1910) in *Manual of Human Embryology*, vol. 1, p. 425. Philadelphia and London: J. B. Lippincott Co.

SAXENA, S. K., CHOWDHARY, D. S. & JAIN, S. P. (1986). Interparietal bones in Nigerian Skulls. *Journal of Anatomy* **144**, 235–237.

SRIVASTAVA, H. C. (1977). Development of the ossification centres in the squamous portion of the occipital bone in man. *Journal of Anatomy* **124**, 643–649.