J. Anat. (1993) **183**, pp. 161–163, with 2 figures Printed in Great Britain

Short Report

Rare origin of the obturator, inferior epigastric and medial circumflex femoral arteries from a common trunk

J. R. SAÑUDO, M. ROIG, A. RODRIGUEZ, B. FERREIRA AND J. M. DOMENECH

Department of Morphological Sciences, Autonomous University of Barcelona, Spain

(*Accepted 8 March 1993*)

ABSTRACT

Two cases of arterial variation are described in which the obturator, inferior epigastric and medial circumflex femoral arteries arose from a common trunk from the external iliac artery. A possible ontogenetic explanation is provided.

INTRODUCTION

The existence of a common origin for the inferior epigastric and obturator arteries is a relatively frequent anomaly, occurring in 20–30% (Bergman et al. 1984; Lippert & Pabst, 1985). However, the involvement of a third artery, namely the medial circumflex femoral, arising from a common origin together with these 2 arteries is extremely infrequent. We have been able to find descriptions of only 6 cases in the literature (Wood, 1882/83; Quain, 1884; Duclaux, 1902; Adachi, 1928; Dschau, 1936/37). In all these cases the trunk arose in the femoral region from the femoral artery, whereas in both cases presented here the origin was intrapelvic, arising from the external iliac artery.

CASE REPORTS

The arterial anomalies were found during the course of routine dissections. In case 1 the anomaly was observed in the right lower limb of the cadaver of a 64 y male, and in case 2 in the left lower limb of the cadaver of a 73 y female. In both cases a common arterial trunk arose in the pelvic region from the external iliac artery proximal to the inguinal ligament. The trunk divided in 2 different ways (Fig. 1). In case 2, it divided directly into 3 arterial branches (Fig. 1*b*) and in case 1, it first divided into a single descending branch, the medial circumflex femoral artery, and another ascending branch which finally divided into the obturator and inferior epigastric arteries (Fig. 1*a*).

The inferior epigastric artery had its normal course and relationships in both cases whereas the other 2 arteries did not. The obturator followed a medial course, passing in turn over the external iliac vein and behind the lacunar ligament to reach the obturator foramen (Fig. 1*b*). In its course it supplied an anastomotic pubic branch to the inferior epigastric artery (Fig. 1*b*). In case 1, there was another obturator artery which, because of its small diameter, we have named the accessory obturator. This artery originated from the iliolumbar artery, ran below and parallel to the obturator nerve and finally anastomosed with the obturator artery as it entered the obturator foramen (Fig. 1*a*).

The medial circumflex artery descended as far as the femoral triangle. In case 2, it ran in front of the femoral vein; in case 1, it ran behind it after previously passing over its medial side. In both cases it joined the external pudendal artery.

DISCUSSION

This triple arterial association has been described according to 3 different patterns. In the most frequent, recorded in 3 cases, the inferior epigastric and obturator arteries arise as a common trunk from the medial circumflex femoral artery (Quain, 1884; Duclaux, 1902; Adachi, 1928). Another pattern, reported

Correspondence to Dr J. R. Sañudo, Departmento de Ciencias Morfológicas, Facultad de Medicina, Universidad Autónoma de Barcelona, 08193 Bellaterra, Barcelona, Spain.

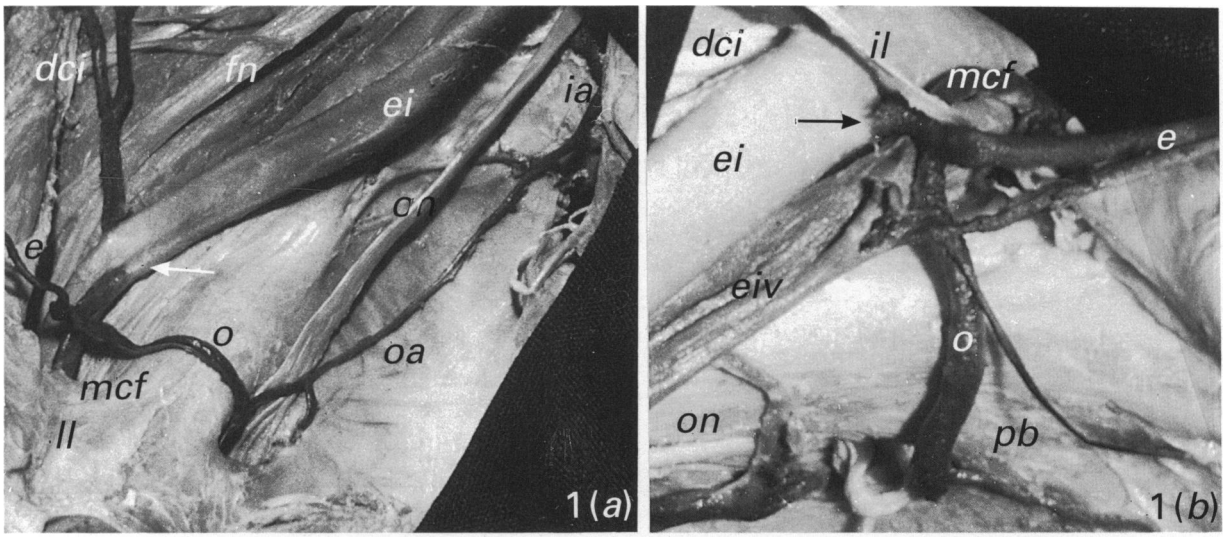

Fig. 1. Endopelvic views of the arterial trunk in cases 1(*a*) and 2(*b*). The external iliac vein has been removed. *dci*, Deep circumflex iliac artery; *e*, inferior epigastric artery; *ei*, external iliac artery; *eiv*, external iliac vein; *fn*, femoral nerve; *ia*, iliolumbar artery; *il*, inguinal ligament; *ll*, lacunar ligament; *mcf*, medial femoral circumflex artery; *o*, obturator artery; *oa*, accessory obturator artery; *on*, obturator nerve; *pb*, pubic branch; arrow, anomalous trunk.

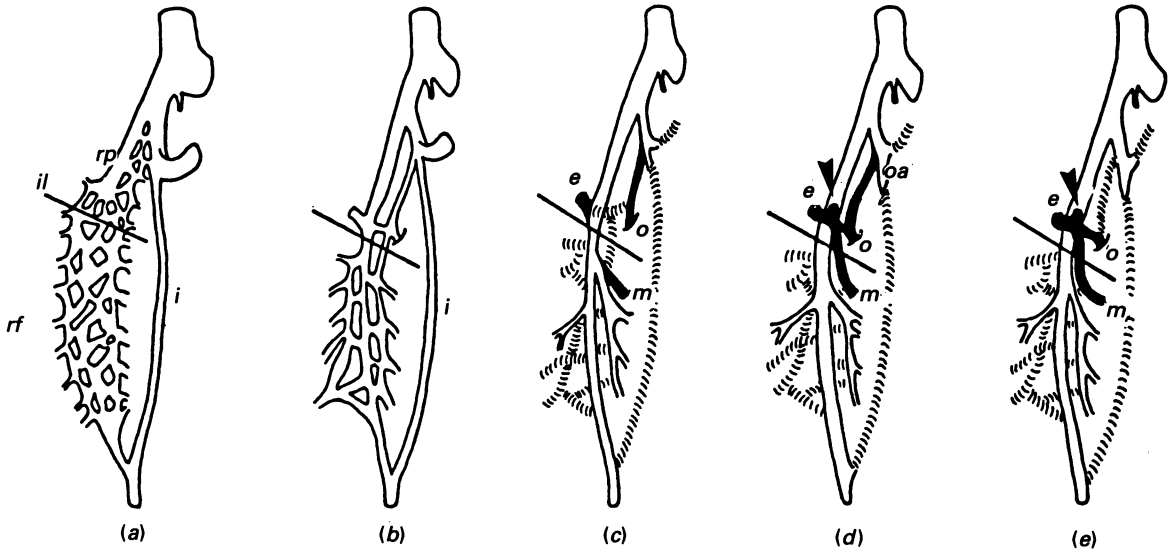

Fig. 2. Diagram of the arterial development of the lower limb. (*a*) Plexiform arterial pattern showing the 'rete pelvicum' (*rp*) which appears in 6 mm embryos, and the 'rete femorale' (*rt*) which appears in 8 mm embryos. (*b*) Simplification of the plexiform pattern by atrophy or enlargement of the vascular channels. (*c*) Normal arterial pattern. (*d*), (*e*) Diagrams of the 2 cases. *e*, Inferior epigastric artery; *i*, sciatic artery; *il*, inguinal ligament; *m*, medial circumflex femoral artery; *o*, obturator artery; *oa*, accessory obturator artery; arrow, anomalous trunk.

in 2 cases, shows the 3 arteries arising directly from a common trunk (Wood, 1882/83; Adachi, 1928). Finally, in 1 case, the inferior epigastric and obturator arise from the medial circumflex femoral artery as independent arteries (Dschau, 1936/37). Our cases correspond to the 1st and 2nd patterns.

The existence of a dual origin for the obturator artery is a more unusual anomaly, occurring with a frequency of 1% (Jastschinsky, 1891; Levi, 1902; Dubreuil-Chambardel, 1925; Adachi, 1928; Pick et al. 1942; Lippert & Pabst, 1985) and its association with the arterial trunk has been recorded only once (Dschau, 1936/37). There are studies which explain the common origin of the inferior epigastric and obturator arteries in different ways (Jastschinsky, 1891; Levi, 1902; Dubreuil-Chambardel, 1925; Senior, 1925; Pick et al. 1942). However, we have found no explanation for the anomaly here presented.

It is currently accepted that the anomalies which affect the arterial patterns of the limbs are based on an unusual selection of channels from a primary capillary plexus. The most appropriate channels enlarge whilst

others retract and disappear, thereby establishing the final arterial pattern (Arey, 1963; FitzGerald, 1978). In accordance with this and basing our explanation on Senior's embryological description (Senior, 1919, 1925), we advance the following ontogenetic interpretation of the anomaly (Fig. 2). Before the medial circumflex femoral and obturator arteries appear as independent blood vessels from the 'rete femorale' and 'rete pelvicum' (Fig. 2), the blood flow destined for their territory makes an unusual choice of source channels and instead of arising from the femoral or internal iliac artery as is usual, it arises from the inferior epigastric (Fig. 2). Consequently, this is the only 1 of the 3 arteries implicated in the anomaly which retains its normal origin and course. The presence of a dual origin for the obturator artery (case 1) may be interpreted as being due to the bloodflow having 2 source channels, one from the internal iliac artery and the other from the inferior epigastric artery (Fig. 2).

REFERENCES

ADACHI B (1928) *Das Arteriensystem der Japaner*, vol. II, pp. 111–196. Kyoto: Verlag der Kaiserlich Japanischen Universität.

AREY LB (1963) The development of peripheral blood vessels. In *The Peripheral Blood Vessels* (ed. J. L. Orbison & D. E. Smith), pp. 1–16. Baltimore: Williams and Wilkins.

BERGMAN RA, THOMPSOM SA, AFIFI AK (1984) *Catalog of Human Variation*, pp. 124–125. Baltimore: Urban & Schwarzenberg.

DSCHAU VF (1936/37) Eine bisher unbekannte Varietät der Arteria obturatoria und pudenda accesoria mit einter Varietät der Arteria circumflexa femoris medialis. *Anatomischer Anzeiger* **83**, 25–29.

DUBREUIL-CHAMBARDEL L (1925) Variations des artères du pelvis et du membre inferieur. In *Traité des Variations du Système Artériel*, vol. 1 (ed. Nicholas), pp. 92–163. Paris: Masson.

DUCLAUX H (1902) Anomalies de l'épigastrique et del'obturatrice. *Bulletin Société Anatomique Paris*, Janvier, 58–59.

FITZGERALD MJT (1978) *Human Embryology*, pp. 38–56. New York: Harper International.

JASTSCHINSKY SN (1891) Die Abweichungen der Arteria obturatoria nebst Erklärung ihres Entstehens. *Monatsschrift für Anatomie und Physiologie* **8**, 367–386.

LEVI G (1902) Morfologia delle arteria iliache. *Archivio di Anatomia di Embriologia* **II**, 523–538.

LIPPERT H, PABST R (1985) *Arterial Variations in Man: Classification and Frequency*, pp. 54–63. München: JF Bergmann.

PICK, JW, BARRY J, ANSON BJ, ASHLEY FL (1942) The origin of the obturator artery – a study of 640 body-halves. *American Journal of Anatomy* **70**, 317–343.

QUAIN R (1844) *Anatomy of the Arteries of the Human Body and its Application to Pathology and Operative Surgery*, pp. 447–526. London: Taylor and Walton.

SENIOR HD. (1919) An interpretation of the recorded arterial anomalies of the human pelvis and thigh. *American Journal of Anatomy* **25**, 55–96.

SENIOR, HD (1925) An interpretation of the recorded arterial anomalies of the human pelvis and thigh. *American Journal of Anatomy* **36**, 1–45.

WOOD, quoted by A. Thompson (1882/83) Origin of the internal circumflex from the deep epigastric artery. *Journal of Anatomy* **17**, 379–383.