Internal Medicine
The Japanese Society of Internal Medicine

doi: 10.2169/internalmedicine.9740-22
Intern Med 62: 2911-2917, 2023
http://internmed.jp

【 CASE REPORT 】

Mild Pulmonary Nocardiosis Caused by *Nocardia terpenica* in an Immunocompetent Patient

Jingjun Dong, Wei Guan, Anmei Hu and Qiong Luo

Abstract:
A 53-year-old immunocompetent man was admitted to our hospital because of paroxysmal cough with a low fever for more than 5 months. On admission, chest computed tomography showed multiple plaques and nodules, some with small central cavities, in both lungs and cystic and columnar bronchiectasis of the right middle bronchus. Treatment with various antibiotics was ineffective. Metagenomic next-generation sequencing of the bronchoalveolar lavage fluid showed *Nocardia terpenica*, and this organism was cultured from bronchoalveolar lavage fluid, resulting in a diagnosis of pulmonary nocardiosis. After administration of trimethoprim-sulfamethoxazole for 5 weeks, chest computed tomography showed a significant reduction in the lung lesions that had been detected on admission. Immunosuppressed patients are particularly prone to nocardiosis infection, which is usually severe. *N. terpenica* has rarely been detected in clinical samples, and its characteristics require further study with the accumulation of more clinical cases.

Key words: pulmonary nocardiosis, *Nocardia terpenica*, immunocompetent patient, metagenomic next-generation sequencing, case report

(Intern Med 62: 2911-2917, 2023)
(DOI: 10.2169/internalmedicine.9740-22)

Introduction

Nocardiosis is an infectious disease caused by *Nocardia*, an aerobic Gram-positive bacillus with branches that easily forms mycelia. Nocardiosis is an opportunistic infection in immunosuppressed patients and can affect almost every organ (1). The lungs are the most common site of infection in nocardiosis, followed by the skin, brain, and eyes (2). Pulmonary nocardiosis (PN) is a rare but potentially life-threatening infection and the published literature comprise mostly case reports and small case series.

With the aging of the population and the widespread use of immunosuppressants, the incidence of nocardiosis is on the rise. Immunosuppressed patients are particularly susceptible to nocardiosis, and their infections are often serious.

Immunocompetent patients with PN typically have several risk factors, such as corticosteroid therapy, chronic obstructive pulmonary disease (COPD), cystic fibrosis, and bronchiectasis (3). *Nocardia terpenica* was first reported in Japan in 2007; however, it is rarely isolated from clinical specimens (4).

We herein report a mild case of PN caused by *N. terpenica* in an immunocompetent patient without the aforementioned risk factors and present a review of relevant published reports.

Case Report

A 53-year-old Chinese man presented to our fever clinic with a fever and headache of no identified cause. His body temperature was 38.1°C, accompanied by chills, pharyngeal itching, and occasional coughing with small amounts of sticky yellow sputum. A complete blood count showed a white blood cell count of 10.85×10^9/L, neutrophils 0.69, lymphocytes 0.19, and monocytes 0.09. Treatment with roxithromycin and clindamycin produced no obvious effect. One week later, chest radiography showed patchy high-density shadows in both lungs, and the patient was hospitalized with a diagnosis of pulmonary infection.

Chest computed tomography (CT) after admission showed multiple plaques and nodules with blurred edges in both

Department of Respiratory and Critical Medicine, Baoan Central Hospital of Shenzhen, China
Received: March 15, 2022; Accepted: January 4, 2023; Advance Publication by J-STAGE: February 15, 2023
Correspondence to Dr. Jingjun Dong, tony5204100@163.com

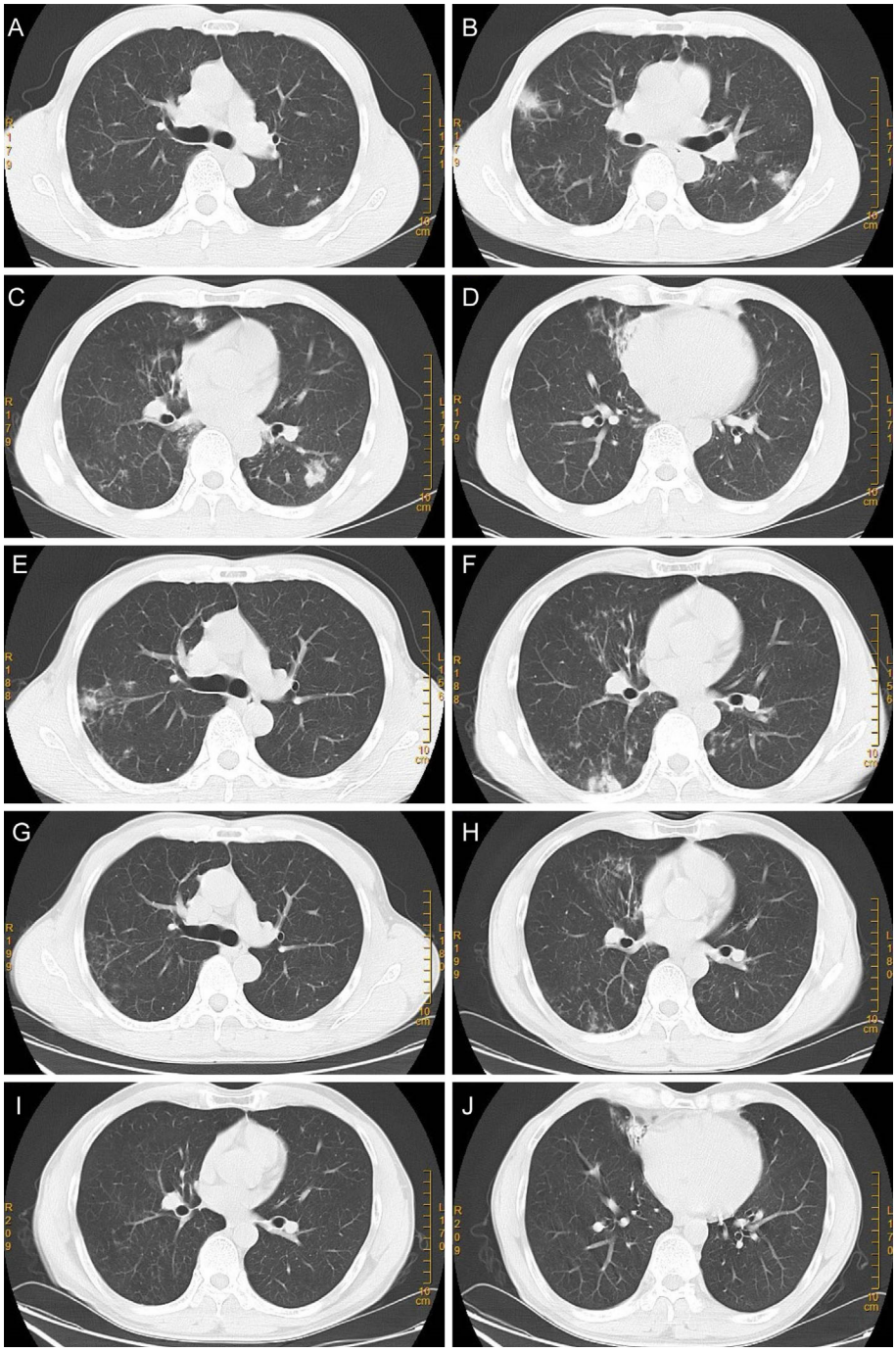

Figure 1. Chest computed tomography (CT) on presentation showing multiple bilateral plaques and nodules, some with small central cavities, and cystic and columnar bronchiectasis of the right middle bronchus (A-D). Chest CT five months after presentation (E, F) showing a slight increase in exudative lesions in the right lung compared with approximately 10 weeks after presentation. After antibiotic treatment for 5 weeks, the pulmonary infiltration and nodules improved (G, H). CT scan approximately 21 months after the original presentation, showing only minor bronchiectasis with a few patchy shadows in the right lung (I, J).

lungs and cystic changes in some lesions. Columnar bronchiectasis was seen in the middle lobe of the right lung (Fig. 1). His erythrocyte sedimentation rate was 89 mm/h, and the following values were all normal: C-reactive protein, procalcitonin, the hepatic and renal function, fungal D-glucan detection test, galactomannan antigen of Aspergillus (GM test), and tuberculosis infection T lymphocytes. Sputum smears and cultures for bacterial and fungal infections were all negative. The lung function was generally normal, with a forced expiratory volume/forced vital capacity of 82.3% and forced expiratory volume of 3.25 L (97.7% of the estimated value). Electrocardiography showed incomplete right bundle branch block.

After seven days of treatment with amoxicillin clavulanic

potassium combined with azithromycin, his symptoms had improved significantly; however, chest CT showed no detectable change in the bilateral lung lesions. Bronchoscopy was performed five weeks after admission, revealing yellow phlegm in the bilateral bronchi. Bronchial brush smears were negative for bacteria, including acid-fast bacilli, and fungi. An examination of the bronchoalveolar lavage fluid (BALF) showed numerous neutrophils. The findings of a GM test, *Mycobacterium tuberculosis*, rapid detection of rifampin resistance, and *Mycoplasma pneumoniae* DNA were all within the normal range. The patient was discharged home.

Seven weeks later, he developed a low-grade fever without cough, sputum, chest tightness, or shortness of breath. His white blood cell count and C-reactive protein concentration were normal. CT of the chest showed multiple patchy shadows in the right lung and local bronchiectasis in the middle lobe. He was readmitted and administered piperacillin-sulbactam for two weeks. After discharge, moxifloxacin was administered orally for another 2 weeks (0.4 g once daily) followed by azithromycin (0.25 g once daily) for a further month, at which stage he still had an occasional cough and a small amount of yellow phlegm. Approximately 3 weeks after completing the course of azithromycin, chest CT performed during a follow-up visit showed a slight increase in exudative lesions in the right lung compared with the CT findings approximately 10 weeks previously. He was readmitted with a diagnosis of bronchiectasis and lung infection.

The patient was a sanitation worker and had smoked approximately 20 puffs per day using a hookah (a Chinese waterpipe) for more than 10 years. He had quit this smoking habit two months prior to this admission.

The results of a physical examination on admission were as follows: body temperature, 36.0°C; pulse rate, 65 beats/min; respiration, 19 breaths/min; and blood pressure, 99/58 mmHg. Chest auscultation showed no dry or moist rales in either lung. Laboratory findings showed normal peripheral blood leukocyte count, along with serum cholesterol 5.19 mmol/L and LDL-C 3.38 mmol/L. HBsAg, TP-CLIA, HCV-IgG, HIV Ag/Ab were negative. A fungal D-glucan detection test, serum GM test, and tests for the vasculitis-associated variables of pANCA, ANCA-PR3, C-ANCA, and ANCA-MPO were all negative. Antinuclear antibody, anti-JO1, anti-SSA, anti-SSB, anti-Sm, CCP, IgA, IgM, IgG, C3, C4, and the thyroid function were all normal (Table). CT of the skull showed left maxillary sinusitis.

Four days after admission, bronchoscopy was performed, and bronchoscopic brush smears were negative for acid-fast bacilli, bacteria, and fungi. The findings for TB-DNA, GM test, and Xpert of the BALF were also normal. Metagenomic next-generation sequencing (mNGS) of the BALF specimen showed *N. terpenica* with a detection sequence number of 51 (no other pathogens were detected), and culture of the BALF yielded *Nocardia* (Fig. 2). mNGS was performed as specified by BGI Genomics (Shenzhen, China). In brief, DNA and RNA were extracted from BALF using a QIAamp® Kit (Qiagen China, Shanghai, China) in accordance with the manufacturer's instructions. cDNA was generated using reverse transcriptase and deoxynucleotide triphosphates (Thermo Fisher Scientific, Waltham, USA). Libraries were constructed for the DNA and cDNA samples using a Nextera XT DNA Library Prep Kit (Illumina, San Diego, USA). Library pools were then loaded onto an Illumina Nextseq 550Dx sequencer for 75 cycles of single-end sequencing. A set of criteria was designed for selecting a representative assembly for microorganisms from the National Center for Biotechnology Information Nucleotide and Genome databases. The final database consisted of approximately 18,562 genomes. Microbial reads were aligned to the database using the Scalable Nucleotide Alignment Program. *Nocardia* was cultivated using a broth dilution method. Sensitivity tests showed it was susceptible to trimethoprim-sulfamethoxazole (TMP-SMZ), imipenem, levofloxacin, moxifloxacin, amikacin, vancomycin, and linezolid. A possible diagnosis of PN was considered, and TMP-SMZ was administered [500 mg/dose (calculated at trimethoprim) twice daily].

Chest CT performed approximately 14 weeks after admission showed significant resolution of the right lung nodules (Fig. 1). The creatinine concentration was 103 μmol/L (reference value <90 umol/L) on rechecking, so the oral TMP-SMZ dose was adjusted to 600 mg/day (calculated at trimethoprim). The patient stopped taking this drug after a further CT scan review approximately six months later. His condition has remained stable ever since. We have depicted the clinical course in followed figure (Fig. 3). A reexamination by chest CT six months after stopping TMP-SMZ revealed only a small amount of bronchiectasis with a few small patchy shadows in the right lung (Fig. 1).

Discussion

There are more than 50 *Nocardia* strains, with the most common clinical isolates being *N. asteroids, N. brasiliensis, N. abscessus, N. farcinica,* and *N. otitidiscaviarum.* The main pathogen in humans is *N. asteroids*, followed by *N. brasiliensis*. *N. terpenica*, a saprophytic, aerobic, Gram-positive bacterium, is widely found in the air, soil, decaying plants, and animal excreta. Though commonly detected in patients with cellular immunodeficiency, this conditional pathogen is rarely isolated from clinical specimens. COPD is commonly associated with PN, characteristically in the context of concomitant corticosteroid use. Comorbidities such as diabetes mellitus, cytomegalovirus infection, and alcohol abuse may also contribute to the development of PN. In a study of 31 adults with PN, the predisposing conditions were found to be COPD (23%), organ transplantation (29%), HIV infection (19%), alcohol abuse (6.5%), and steroid therapy (64.5%), with only 15% of patients having no identified comorbidity or an impaired immune function (5). Our patient had a normal immune function but was a sanita-

Table. Laboratory Data of Peripheral Blood of the Patient.

Clinical laboratory test	Result	Unit	Reference value
WBC count	6.05	×10E9/L	4-10
RBC count	4.68	×10E12/L	4-5.5
Hemoglobin	142	g/L	120-160
Platelet count	235	×10E9/L	100-350
Neutrophil count	3.5	×10E9/L	1.8-7.2
Eosinophil count	0.31	×10E9/L	0.02-0.5
C-reactive protein	<0.80	mg/L	0-10
Sodium	137	mmol/L	135-145
Potassium	4.1	mmol/L	3.50-5.50
Calcium	2.18	mmol/L	2.08-2.60
Glucose	4.1	mmol/L	3.9-6.1
Creatinine	74	μmol/L	40-104
Urea nitrogen	4.1	mmol/L	1.9-8.1
Uric acid	249	μmol/L	208-408
Total bilirubin	10.5	μmol/L	5.1-19.0
Direct bilirubin	2.7	μmol/L	0-6.8
Indirect bilirubin	7.8	μmol/L	0-17
Total cholesterol	5.19	mmol/L	2.17-5.17
Triglyceride	1.15	mmol/L	0.40-1.71
High-density lipoprotein cholesterol (HDL-C)	1.15	mmol/L	1.16-1.42
Low-density lipoprotein cholesterol (LDL-C)	3.38	mmol/L	1.40-3.10
Alanine transaminase (ALT)	9	U/L	0-40
Aspartate aminotransferase (AST)	13	U/L	0-40
Glutamic acyltransferase (GGT)	14	U/L	0-50
Creatine kinase (CK)	111	U/L	38-174
Lactate dehydrogenase (LDH)	177	U/L	109-245
MP-IgM	Negative		Negative
CP-IgM	Negative		Negative
HBsAg	0.01	IU/mL	<0.05
TP-CLIA	0.01	S/CO	<1.0
HCV-IgG	0.02	S/CO	<1.0
HIV Ag/Ab	0.01	S/CO	<1.0
Carcinoembryonic antigen (CEA)	4.01	ng/mL	0-5.00
Alpha-fetoprotein (AFP)	2.10	ng/mL	0-20.00
Carbohydrate antigen 199	19.30	U/mL	0-37.00
Carbohydrate antigen 153	10.14	U/mL	0-28.0
Carbohydrate antigen 125	28.07	U/mL	0-35.00
Fungal D-glucan detection	58.13	pg/mL	0-60
Galactomannan antigen of Aspergillus	<0.25	ug/L	<0.80
Total IgE	153	IU/mL	<87
Procalcitonin (PCT)	<0.01	ng/mL	0-0.05
Thyroid stimulating hormone (TSH)	5.00	mIU/L	0.56-5.91
Total triiodothyronine (TT3)	1.22	nmol/L	1.01-2.48
Total thyroxine (TT4)	76.43	nmol/L	69.97-152.52
Free triiodothyronine (FT3)	3.98	pmol/L	3.28-6.47
Free thyroxin (FT4)	10.42	pmol/L	7.64-16.03
Antinuclear antibody	Negative (-)		Negative (-)
Anti-ds-DNA qualitative	Negative (-)		Negative (-)
anti-Sm antibody	Negative (-)		Negative (-)
Anti-SSA antibody	Negative (-)		Negative (-)
Anti-SSB antibody	Negative (-)		Negative (-)
Anti-scl-70 antibody	Negative (-)		Negative (-)
Anti-U1RNP antibody	Negative (-)		Negative (-)
Anti-JO1 antibody	Negative (-)		Negative (-)
Anti-cyclic citrullinated peptide antibody	<7.0	U/mL	<20.0
Anti-nucleosome antibody	Negative (-)		Negative (-)
Rheumatoid factor	<9.4	kU/L	0.0-15.9
pANCA	Negative (-)		Negative (-)
ANCA-PR3	Negative (-)		Negative (-)
cANCA	Negative (-)		Negative (-)
ANCA-MPO	Negative (-)		Negative (-)
CD3+T Cell	66.45	%	56-84
CD3+CD4+T Cell	31.12	%	31-52
CD3+CD8+TCell	28.90	%	18-35
CD3+CD4+CD8+T Cell	0.50	%	<5
CD3+CD4+T Cell/CD3+CD8+T Cell	1.08		0.71-2.78
CD3-CD19+BCell	11.88	%	5-18
CD3-CD(16+56)+NK Ce11	21.07	%	7-40
Immunoglobulin G (IgG)	13.70	g/L	7-16
Immunoglobulin A (IgA)	1.60	g/L	0.7-4.0
Immunoglobulin M (IgM)	1.80	g/L	0.4-2.3
Complement C3	1.27	g/L	0.8-1.6
Complement C4	0.18	g/L	0.1-0.4

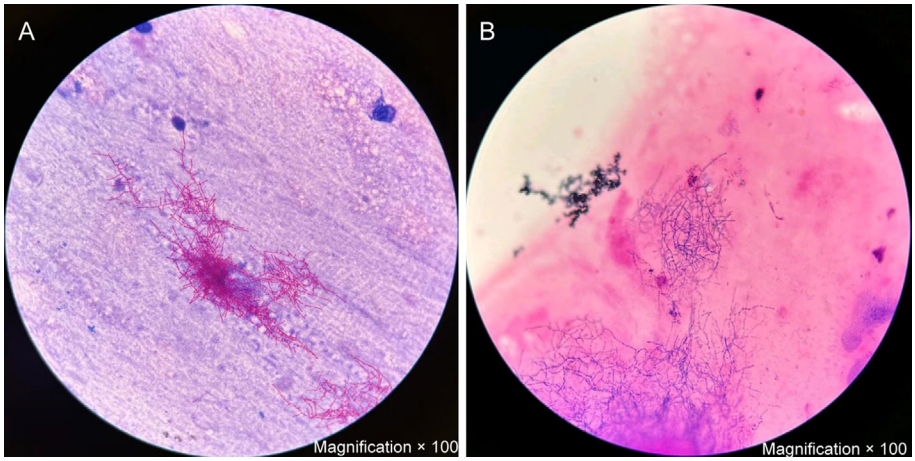

Figure 2. Photomicrographs of Gram-stained (A) and weak acid-fast-stained (B) bronchoalveolar lavage fluid shows gram-positive bacilli and branching hyphae typical of *Nocardia*.

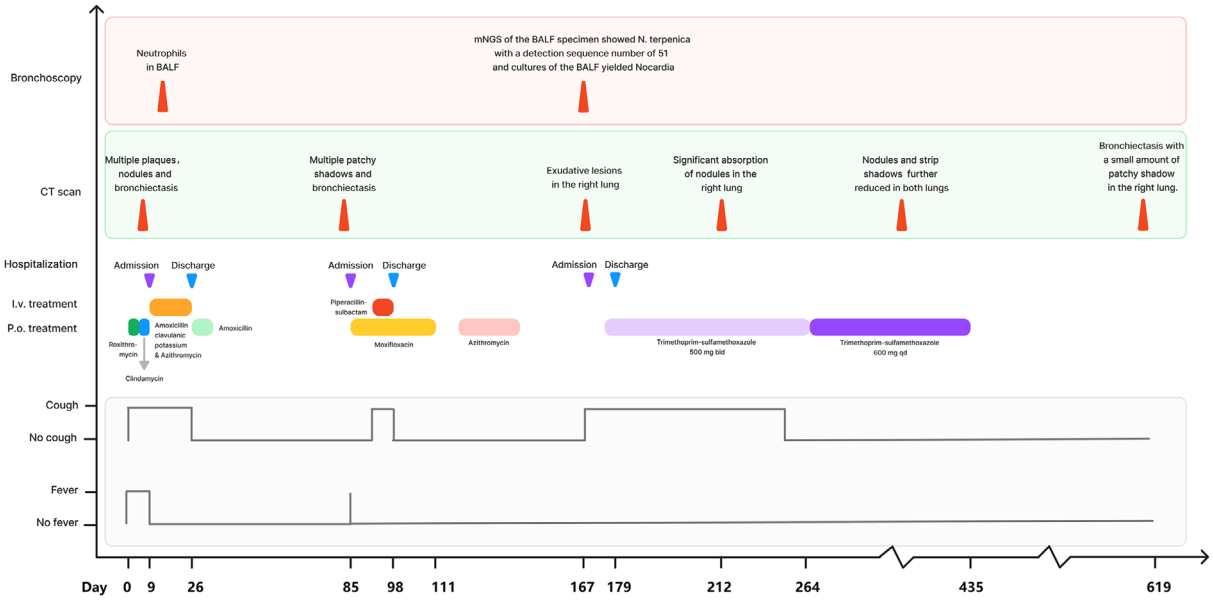

Figure 3. The patient's clinical course.

tion worker with long-term exposure to decaying plant matter and animal excrement. Another possible risk factor is that he had smoked a hookah daily for more than 10 years. Studies have shown that hookah smoking releases more tar and nicotine than does cigarette smoking and that these substances can destroy airway defense barriers, leading to immune suppression, inflammatory changes, airway remodeling, and dysbacteriosis (6). We therefore concluded that working in waste disposal, which likely entails frequently exposure to *Nocardia*, and his smoking habit were as-yet-unrecognized risk factors for nocardiosis.

While bronchiectasis is a known risk factor for PN, our patient had no signs of bronchiectasis prior to developing PN. This may be a typical chest CT manifestation in immunocompetent patients with PN (7). PN is usually acquired through inhalation of contaminated aerosol droplets. Most patients with PN are immunocompromised, and about a third of them have widespread infection, which can be acute, subacute, or chronic (8). Pulmonary involvement may present with a fever, cough, and hemoptysis, with polymorphic radiographic findings including infiltration, multiple nodules, and cavitation (9). Abscess formation, a feature of nocardiosis, can resemble a pyogenic bacterial infection or evolve into chronic granulomas or mixed progressive inflammatory masses (10). Peng et al. reported a case of chronic pulmonary nocardiosis with Sjögren's syndrome whose symptoms included hemoptysis, cough, and expectoration. Chest CT in that case showed multiple nodules and bronchiectasis in both lungs, and inflammatory foci were scattered in both lungs (11). Matsuo et al. reported a case of acute disseminated nocardiosis caused by *N. terpenica* with a medical history of type 2 diabetes, COPD, and arrhythmia. The patient had a fever, altered mental status, and difficulty breathing, and chest CT revealed multiple lung nodules of

varying sizes with interlobular septal thickening that was upper lobe-dominant and bilateral in distribution (12). Both of the patients in these two case reports were immunosuppressed. Chest CT findings indicate a higher incidence of bronchiectasis and centrilobular nodular insufficiency in immunocompetent than in immunosuppressed patients with PN, and these two conditions are also characteristic of pulmonary nontuberculous mycobacterial disease. Therefore, physicians should take care to differentiate PN from pulmonary nontuberculous mycobacteriosis in immunocompetent patients (13). Our patient had a long disease course, and early chest CT showed both bronchiectasis and multiple, bilateral, mainly subpleural nodules with small central cavities, which helped make his diagnosis difficult to distinguish from nontuberculous mycobacterial infection.

The diagnosis of nocardiosis depends on culture findings. However, *Nocardia* grows slowly in culture medium and is often inhibited by other fast-growing bacteria. Thus, when nocardial infection is suspected clinically, prolonged culture improves the accuracy and success rate. Although Gram staining, modified acid-fast staining, and culture remain the standard diagnostic tools, novel molecular techniques have facilitated the identification of *Nocardia* (14). 16S rRNA gene sequencing of BALF is a commonly used means of detecting the pathogens responsible for pneumonia. In brief, a 16S rRNA gene of approximately 600 bp was extracted from a DNA sample of BALF and amplified by polymerase chain reaction (PCR) using universal primers. The PCR products were then cloned to construct a clone library, and 96 clones were randomly selected from that library to determine their 16S rRNA gene sequences. A search tool algorithm for basic local comparisons was used to perform a homology search (1). This is generally considered the gold standard for bacterial identification (15, 16). However, rRNA gene sequencing fails to discriminate between some species of *Nocardia*, likely because DNA-DNA hybridization studies have shown there is high sequence similarity between Nocardia species (17). This procedure is unsuitable for isolate-specific identification because it focuses on one marker gene, neglecting other genomic biomarkers markers (18). In comparison, mNGS involves randomly breaking microbial genomic DNA into small fragments of 500 bp and then adding universal primers for PCR amplification and sequencing before finally splicing the small fragments into longer sequences by assembly. High-throughput sequencing is performed on the total DNA of all microorganisms in a sample to identify any pathogenic microorganisms, conferring a considerable advantage in identifying species (19, 20). Because it eliminates potential bias in sampling by testing the total DNA of all microorganisms in a sample, mNGS can identify a wide range of known and unexpected pathogens. It can also provide quantitative or semi-quantitative data on the concentrations of microorganisms in a sample by sequence read counting, which is useful for multiple microbial samples or in cases involving multiple pathogens. However, mNGS has the inherent disadvantage of a predominance of microbial nucleic acids in human host backgrounds in most patient samples. Therefore, targeted sequencing combined with mNGS may be particularly useful for non-sterile specimens (21). With the widespread application of mNGS in BALF, the rate of detection of rare respiratory pathogens, including *N. terpenica*, has greatly increased in recent years NGS is more sensitive and rapid than 16S rDNA sequencing for the diagnosis of unspecified pathogens (11, 12).

The anti-infective treatment of choice for PN is TMP-SMX administered orally at 15 mg/kg/day (calculated at trimethoprim), divided into 2 to 4 doses daily, and 10 mg/kg/day after 3 to 4 weeks of treatment. The second-line antibiotic regimen is imipenem cilastatin plus amikacin, followed by TMP-SMX therapy after three to four weeks of treatment, with the entire course for primary PN lasting three to four months (22). However, because the rate of resistance to sulfonamides has recently been increasing, whereas sensitivity to linezolid and amikacin is high, combination therapy is recommended, especially for patients who are critically ill and immunosuppressed. Linezolid, which is able to penetrate the blood-brain barrier, is recommended for central nervous system infections. The drugs, doses, and course of treatment used vary widely from case to case (23-25). Patients should thus be treated individually according to the location and severity of their nocardial infection (8). The curative effect of TMP-SMX is obvious to some chronic nocardiosis patients, but a few researchers have reported that 25% of nocardiosis cases were resistant to TMP-SMX. Antimicrobial susceptibility testing is very important for the treatment of nocardiosis. It can provide clinicians with the right choice of drugs, in combination if necessary, for an adequate course of treatment (12). In the present case, moxifloxacin, azithromycin, and other antibiotics were used at an early stage, resulting in some improvement in symptoms and partial resolution of some pulmonary nodules bilaterally. Because the patient was not seriously ill, we initially administered TMP-SMX alone. Repeat chest CT after one month showed obvious improvement.

In conclusion, we encountered a case of PN caused by *N. terpenica* in an immunocompetent patient with no comorbidities, such as diabetes, COPD, or cystic fibrosis. *N. terpenica* is rarely detected in clinical samples, and few infections with this pathogen have been reported. Generally, PN occurs in immunocompromised patients or individuals with comorbidities, and the infection is usually serious. Because our patient had no underlying comorbidities or recognized risk factors, his infection was mild. The characteristics of *N. terpenica* and effective treatment regimens require further research and the accumulation of more clinical cases.

Written informed consent was obtained from the patient for publication of this case report and accompanying images.

The authors state that they have no Conflict of Interest (COI).

Acknowledgement

We thank Dr Trish Reynolds, MBBS, FRACP, from Liwen Bianji for editing the English text of a draft of this manuscript.

References

1. Imai K, Koibuchi T, Kikuchi T, et al. Pulmonary nocardiosis caused by *Nocardia exalbida* complicating *Pneumocystis* pneumonia in an HIV-infected patient. J Infect Chemother **17**: 547-551, 2011.
2. Ray KJ, Prajna L, Srinivasan M, et al. Fluoroquinolone treatment and susceptibility of isolates from bacterial keratitis. JAMA Ophthalmol **131**: 310-313, 2013.
3. Rivière F, Billhot M, Soler C, et al. Pulmonary nocardiosis in immunocompetent patients: can COPD be the only risk factor? Eur Respir Rev **20**: 210-212, 2011.
4. Hoshino Y, Watanabe K, Iida S, et al. *Nocardia terpenica* sp. nov., isolated from Japanese patients with nocardiosis. Int J Syst Evol Microbiol **57**: 1456-1460, 2007.
5. Ott SR, Meier N, Kolditz M, et al. Pulmonary nocardiosis in Western Europe - clinical evaluation of 43 patients and population-based estimates of hospitalization rates. Int J Infect Dis **81**: 140-148, 2019.
6. Jiang J, zhang J, Jiang L, et al. Determination of fifteen kinds of components in mainstream smoke of waterpipe tobacco and filtration efficiency of Chinese waterpipe. J Environ Health **29**: 365-367, 2012.
7. Muñoz J, Mirelis B, Aragón LM, et al. Clinical and microbiological features of nocardiosis 1997-2003. J Med Microbiol **56**: 545-550, 2007.
8. Rawat D, Rajasurya V, Chakraborty RK, Sharma S. Nocardiosis. In: StatPearls. StatPearls Publishing, Treasure Island (FL).
9. Wang T, Jia Y, Chu B, et al. Nocardiosis in kidney disease patients under immunosuppressive therapy: case report and literature review. Int J Med Sci **16**: 838-844, 2019.
10. Martínez R, Reyes S, Menéndez R. Pulmonary nocardiosis: risk factors, clinical features, diagnosis and prognosis. Curr Opin Pulm Med **14**: 219-227, 2008.
11. Peng Y, Dong X, Zhu Y, et al. A rare case of pulmonary nocardiosis comorbid with Sjogren's syndrome. J Clin Lab Anal **35**: e 23902, 2021.
12. Matsuo T, Nakaoka H, Mori N, et al. Disseminated nocardiosis due to *Nocardia terpenica*. J Infect Chemother **27**: 1365-1368, 2021.
13. Fujita T, Ikari J, Watanabe A, et al. Clinical characteristics of pulmonary nocardiosis in immunocompetent patients. J Infect Chemother **22**: 738-743, 2016.
14. Ambrosioni J, Lew D, Garbino J. Nocardiosis: updated clinical review and experience at a tertiary center. Infection **38**: 89-97, 2010.
15. Conville PS, Brown-Elliott BA, Smith T, Zelazny AM. The complexities of *Nocardia* taxonomy and identification. J Clin Microbiol **56**: e01419-17, 2017.
16. Kato K, Noguchi S, Naito K, et al. Pulmonary nocardiosis caused by *Nocardia exalbida* in a patient with lung cancer and radiation pneumonitis: a case report and literature review. Intern Med **58**: 1605-1611, 2019.
17. Brown-Elliott BA, Brown JM, Conville PS, et al. Clinical and laboratory features of the *Nocardia* spp. based on current molecular taxonomy. Clin Microbiol Rev **19**: 259-282, 2006.
18. Boers SA, Jansen R, Hays JP. Understanding and overcoming the pitfalls and biases of next-generation sequencing (NGS) methods for use in the routine clinical microbiological diagnostic laboratory. Eur J Clin Microbiol Infect Dis **38**: 1059-1070, 2019.
19. Li S, Song Xy, Zhao Yy, et al. Clinical analysis of pulmonary nocardiosis in patients with autoimmune disease. Medicine **94**: 1561-1561, 2015.
20. Cao Y, Fanning S, Proos S, et al. A review on the applications of next generation sequencing technologies as applied to food-related microbiome studies. Front Microbiol **8**: 1829, 2017.
21. Gu W, Miller S, Chiu CY. Clinical metagenomic next-generation sequencing for pathogen detection. Annu Rev Pathol **14**: 319-338, 2019.
22. Cao B, Huang Y, She DY, et al. Diagnosis and treatment of community-acquired pneumonia in adults: 2016 clinical practice guidelines by the Chinese Thoracic Society, Chinese Medical Association. Clin Respir J **12**: 1320-1360, 2018.
23. Wang S, Jiang B, Li Y, et al. A case report of disseminated nocardiosis with ocular involvement in a myasthenia gravis patient and literature review. BMC Neurol **19**: 243, 2019.
24. Kurahara Y, Tachibana K, Tsuyuguchi K, et al. Pulmonary nocardiosis: a clinical analysis of 59 cases. Respir Investig **52**: 160-166, 2014.
25. Yagi K, Ishii M, Namkoong H, et al. Pulmonary nocardiosis caused by *Nocardia cyriacigeorgica* in patients with *Mycobacterium avium* complex lung disease: two case reports. BMC Infect Dis **14**: 684, 2014.

The Internal Medicine is an Open Access journal distributed under the Creative Commons Attribution-NonCommercial-NoDerivatives 4.0 International License. To view the details of this license, please visit (https://creativecommons.org/licenses/by-nc-nd/4.0/).

© 2023 The Japanese Society of Internal Medicine