

Damage to the corneal endothelium during Nd/YAG photodisruption

M G KERR MUIR AND E S SHERRARD

From the Pocklington Eye Transplant Research Unit, Institute of Ophthalmology, Moorfields Eye Hospital, London

SUMMARY Damage to the human corneal endothelium, as seen by specular microscopy, associated with short pulsed neodymium: yttrium-aluminium-garnet (Nd/YAG) laser iridotomy and capsulotomy, is described. A specular and scanning electron microscopical study of fresh in vitro rabbit eyes submitted to Nd/YAG iridotomy was performed to investigate the nature of the endothelial damage. The majority of lesions showed irreversible changes ranging from individual cell destruction to disruption of large areas of the endothelium, while cells adjacent to these lesions had changes of an apparently reversible nature. It was possible to correlate accurately these scanning electron microscopic changes with the appearances seen with the clinical specular microscope. The extent of such damage appears to be related to the quantity of power delivered, its delivery mode, the number of laser bursts, and the target tissue/endothelium distance. The possible causes for such damage are discussed.

The recent introduction of short pulsed (Q-switched) Nd/YAG laser photodisruptors into clinical practice has been welcomed because of the facility for non-invasive division of transparent or opaque tissues occluding the visual axis, for creating iridotomies in the management of certain forms of glaucoma, for the division of vitreous membranes, and for preparatory anterior capsulotomies of the lens.¹⁻⁴

Obvious advantages are that there is no surgical entry into the eye or need for a general anaesthetic, and there is therefore less demand on operating theatre time. Furthermore the laser technique is appropriate for either inpatient treatment or as an entirely outpatient service. The reported disadvantages relate to radiation and shock wave damage to structures in the vicinity of the laser focus, that is, to the crystalline lens during iridotomy, to an intra-ocular lens implant, and the anterior vitreous face (with the potential for increasing the likelihood of cystoid macular oedema) during capsulotomy, and to retinal photoreceptor and pigment epithelial cell damage during photodisruption of vitreous membranes.⁵⁻⁸ A further disadvantage is the rise in intra-ocular pressure that sometimes follows iridotomy or capsulotomy. This is of particular importance

because of the risk of further axonal loss in glaucomatous eyes with antecedent optic nerve damage.

There are a few reports of corneal damage. A transient corneal haze overlying the site of iridotomies in narrow-angled chambers has been described in man¹ and in other primates.⁹ A Q-switched ruby laser was used for the latter.

Puliafito and Steinert¹⁰ in a scanning electron microscopical study of rabbit eyes after anterior capsulotomy found no change in the morphology or density of the endothelial cells either in the passage of the laser beam or elsewhere, while an endothelial specular microscopical study in man by Aron-Rosa revealed no changes following capsulotomy.^{3,4}

When the short pulsed (Q-switched) Nd/YAG laser came into clinical use at this hospital two slit-lamp features after both posterior capsulotomy and iridotomy were noted. First, the particulate disruption of target tissue which dispersed throughout the anterior chamber immediately following optical breakdown (*vide infra*). The particles were often in static suspension and returned to normal aqueous flow patterns within 1–60 minutes; second, the appearance of widely distributed clusters of sharply demarcated, non-reflecting areas within the specular image of the endothelium.

These findings prompted the present preliminary

Correspondence to Mr M G Kerr Muir, Professorial Unit, Moorfields Eye Hospital, City Road, London EC1.

study which is aimed at elucidating the incidence and nature of Nd/YAG laser photodisruptor induced damage to the human corneal endothelium by specular microscopy and by the correlation of these findings with the specular and scanning electron microscopical appearances of in vitro rabbit endothelium after Nd/YAG iridotomy.

Materials and methods

The short pulsed, Q-switched Nd/YAG laser photodisruptor used in this study was a Lasag Sirius Microruptor II.

Human study. Patients had been preselected for Nd/YAG laser treatment by the referring clinician. Fifteen of the 16 eyes that had laser iridotomy were being treated for chronic narrow angle glaucoma, resolving acute narrow angle glaucoma, or as prophylaxis in the fellow eye after an acute narrow angle attack. One patient had laser treatment for marked iris bombé with extensive iridocorneal contact. Of the eight capsulotomies two had posterior chamber intraocular lens implants, two had had previous lens aspiration for congenital cataract, while the remainder had opaque capsules following extracapsular cataract surgery. Prior to Nd/YAG treatment the corneal endothelium was examined and photographed, centrally and in all four quadrants, with the Pocklington specular microscope (PSM).¹¹ Immediately after laser treatment a slit-lamp examination of the anterior segment was followed by further endothelial specular photomicroscopy (ESP). In some patients ESP was repeated over several days to monitor the evolution of the YAG induced changes. The laser treatment modalities are shown in Tables 1 and 2.

Animal study. Each of four fresh in vitro Dutch rabbit eyes had three full thickness Nd/YAG

Table 1 Nd/YAG iridotomy laser modalities

No	Mode	Bursts	Pulses per burst	mJ
1	MM	3	4	3.1 (×1)/5.8 (×2)
2	MM	20	NA	5.0
3	MM	1	3	8.3
4	MM	3	4	3.1
5	MM	2	4	4.5
6	MM	2	2	12.0 (×1)/5.4 (×1)
7	MM	3	2	6.4
8	MM	2	3	6.0
9	MM	2	4	8.0
10	MM	1	4	8.5
11	NA	2	NA	1.02
12	FM	1	4	4.9
13	FM	1	4	5.6
14	FM	2	4	5.3
15	FM	2	4	4.6 (×1)/5.7 (×1)
16	FM	4	1	2.0

MM=multimode, FM=fundamental mode, NA=not available.

Table 2 Nd/YAG capsulotomy laser modalities

No	Mode	Bursts	Pulses per burst	mJ
1	FM	3	3	1
2	FM	2	NA	3.0
3*	NA	NA	1	3.0
4	FM	20	3	3.5
5	FM	6	3	3.1
6	FM	15	3	1.0
7	FM	40	4	1.4
8*	FM	2	1	0.9

FM=fundamental mode, MM=multimode, *intraocular lens in situ, NA=not available.

iridotomies with single bursts of three pulses delivering 3 mJ of energy in multimode operation.

ESP was done immediately before and after the iridotomies, and then the cornea was prepared for

Fig. 1 Specular photomicrograph of the in vivo corneal endothelium of an 11-year-old boy four years after congenital cataract surgery.

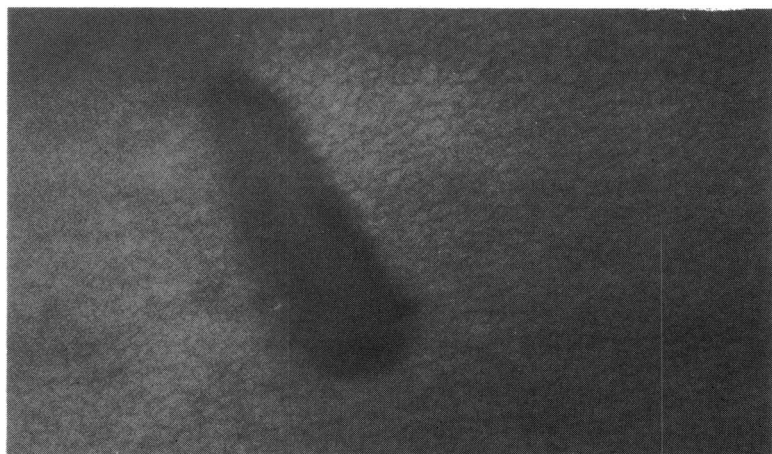


Fig. 1A Pre-YAG capsulotomy. Large dark area=KP-relocation marker. (×12).

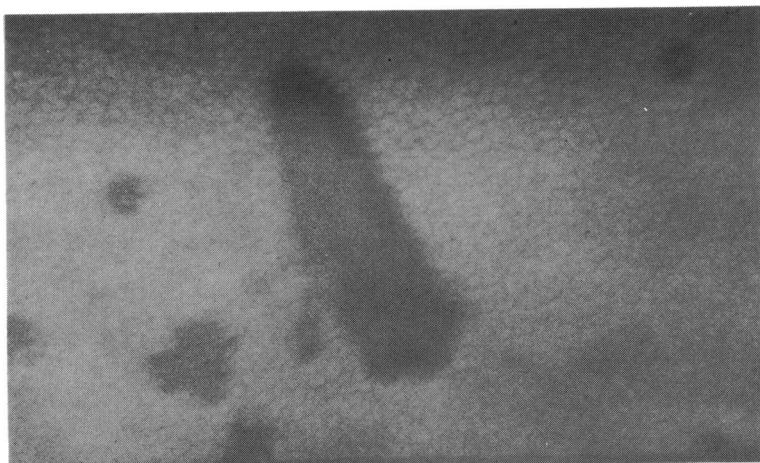


Fig. 1B *Same area as in 1A immediately after YAG capsulotomy. Additional dark areas=YAG induced lesions. ($\times 12$).*

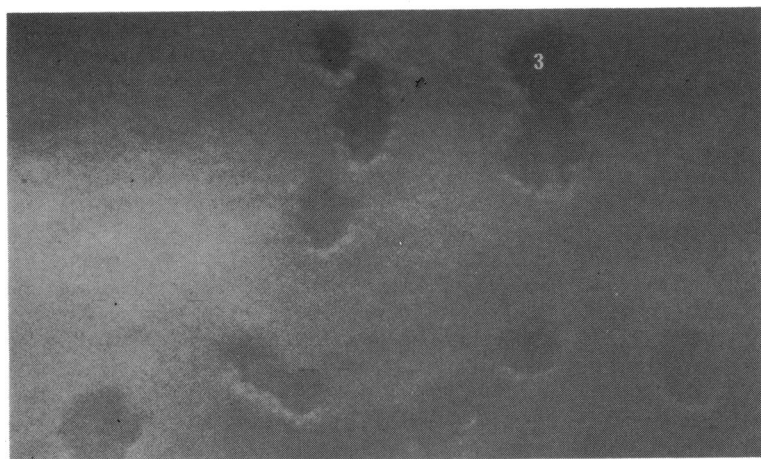

Fig. 1C *Different area of same endothelium as in 1A, see Fig. 1E (3) for location. Note bright margins. ($\times 12$).*

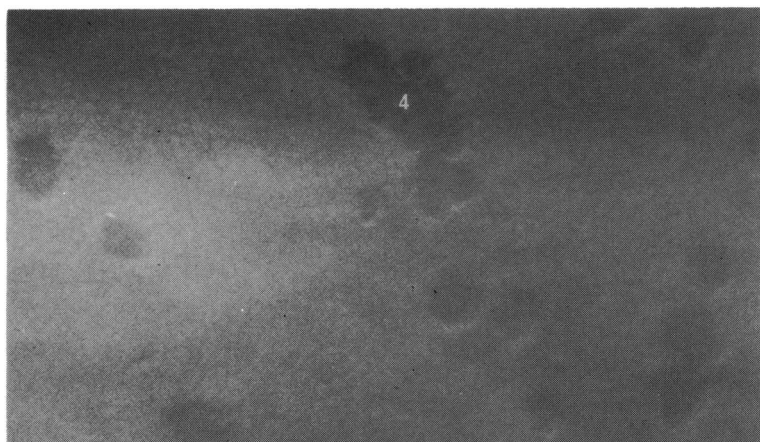

Fig. 1D *Another area of same endothelium as in 1A see Fig. 1E (4) for location. ($\times 12$).*

scanning electron microscopy (SEM) as detailed elsewhere.¹²

Results

Human studies. Specular photomicroscopy of the corneal endothelium in all cases before Nd/YAG treatment showed normal or enlarged cells. The degree of enlargement was attributable to and correlated with the previous ocular disorder such as surgery, trauma, or glaucoma.

After eight YAG capsulotomies the six without an intraocular lens implant all showed changes in the specular image of the corneal endothelium. These were mainly axial in distribution with a wide dispersal into all quadrants.

The example shown is from an 11-year-old boy who had posterior capsular remnants after congenital cataract surgery four years previously. Before YAG capsulotomy (Fig. 1A) the endothelium had a pre-existing axial feature (keratic precipitate) which served as a useful landmark for relocation after laser treatment, when the same feature was seen to be surrounded by multiple 'punched-out' lesions with scalloped borders (Fig. 1B). Similar lesions involved all four quadrants. Fig. 1E is a tracing from a montage of specular photomicrographs which shows the distribution of some of the lesions around the relocation landmark. They occurred either singly or in clusters and often showed a linear pattern. They had distinctive features (Figs. 1C, 1D). They appeared as multiple well delineated dark areas with, in most cases, a margin of brightly reflecting cells whose inner border was scalloped by a darker zone. The centre of the lesions showed some variation with from one to several black featureless circular zones, to a grey amorphous or finely speckled pattern, and the surrounding area was usually grey.

Of the two capsulotomies in the presence of a

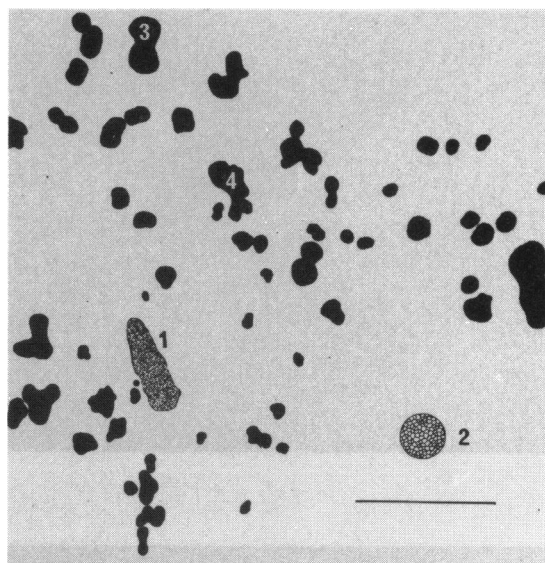


Fig. 1E Tracing of YAG induced lesions from montage of specular photomicrographs (6 frames) illustrating their distribution. 11-year-old boy; YAG capsulotomy: 40 bursts/4 pulses per burst/1.4 mJ. Same case as Fig. 1. 1=relocation marker (see Fig. 1A, B). 2=Tracing from same endothelium at same scale, (136 cells). 3=Lesion identified in Fig. 1C. 4=Lesion identified in Fig. 1D. Bar=0.5 mm.

posterior chamber intraocular lens implant, the endothelium, with a reduced cell population before YAG treatment, showed in one a single non-reflecting area in the inferior periphery by slit-lamp examination. However, no lesions were found with the PSM. The other had a single YAG lesion in the superior corneal periphery which was seen with the PSM.

After Nd/YAG laser iridotomy all of the 16 eyes studied showed lesions in the specular image of the

Fig. 2 Specular photomicrograph of *in vivo* corneal endothelium. 24-year-old woman with iris bombé nine months after lensectomy for traumatic cataract.




Fig. 2A Central endothelium before iridotomy. Cells are enlarged. ($\times 12$).

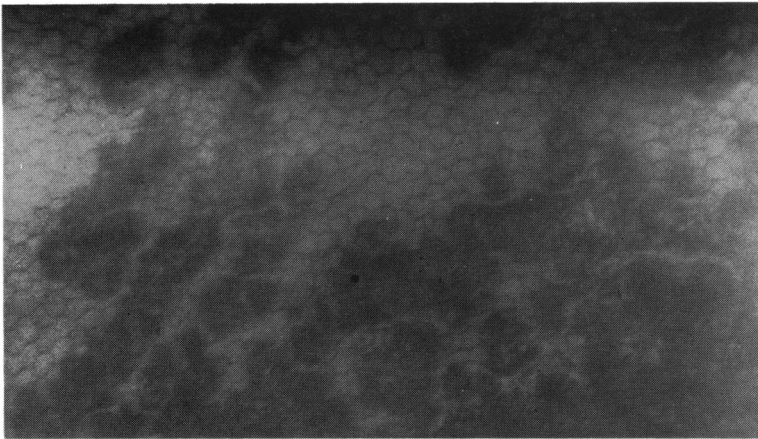


Fig. 2B After YAG treatment. Portion of upper margin of central confluent lesions. ($\times 12$).

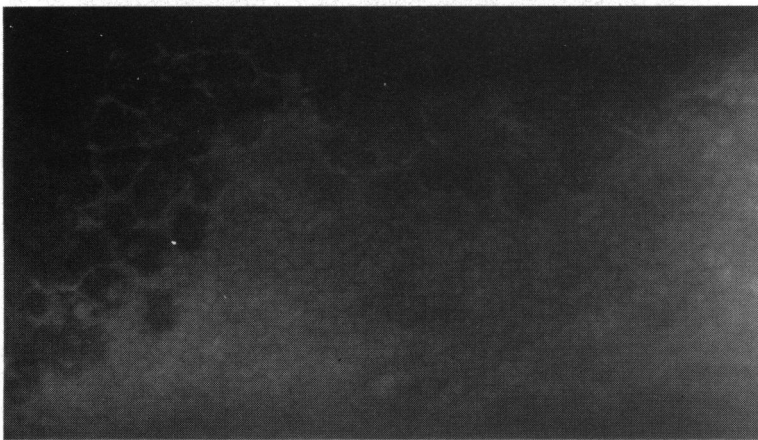

Fig. 2C After YAG treatment. Portion of lower margin of central confluent lesions. ($\times 12$). Note: Differential cell size in B and C was evident before laser treatment.

endothelium whose appearance was identical to those induced by capsulotomy. These were concentrated in the quadrant of the iridotomy, but in the majority of cases they were distributed in other quadrants also. The example shown (Fig. 2) is from the patient with iris bombé with extensive iridocorneal contact, in whom the target tissue/endothelium distance was 1.5 mm. Fig. 2A shows the endothelium, with enlarged cells, before laser treatment. After laser treatment a large area of confluent lesions was seen in the axial region. A portion of the upper margin is shown in Fig. 2B and the lower margin in Fig. 2C. One hour after treatment the axial cornea had thickened by 0.1 mm. This extensive damage occurred in an endothelium with an already depleted cell population (Fig. 2A).

Repeated ESP of four eyes over several days showed normal adjacent endothelium spreading into the area of YAG induced damage.

Target tissue particles were dispersed throughout the anterior chamber in all cases with a greater con-

centration after the iridotomies, when they were associated with a turbid aqueous humour.

Animal studies. A particular feature of rabbit corneal endothelium is the presence of occasional giant cells (Fig. 3A). These serve as excellent markers for the relocation of exact areas of the endothelium and allow precise cell to cell correlation of specular photomicrographs taken before and after YAG laser iridotomy. Furthermore they permit cell to cell correlation in specular and scanning electron photomicrographs.¹²

Fig. 3A is a specular photomicrograph of normal *in vitro* rabbit endothelium. Scanning with the PSM revealed no abnormal features, and the giant cells in the centre of the field were selected as relocation markers. Fig. 3B shows the same giant cells relocated by scanning electron microscopy. Fig. 3C is the same endothelium, as identified by the giant cells, after YAG iridotomy, and it now shows several 'dark' YAG induced changes.

A specular photomicrograph of a typical YAG

Fig. 3 Specular and scanning electron micrograph of *in vitro* rabbit endothelium.

Fig. 3A Specular photomicrograph before laser iridotomy. The endothelium is normal and shows typical giant cells, one of which, arrowed, was centred for later relocation. ($\times 12$).

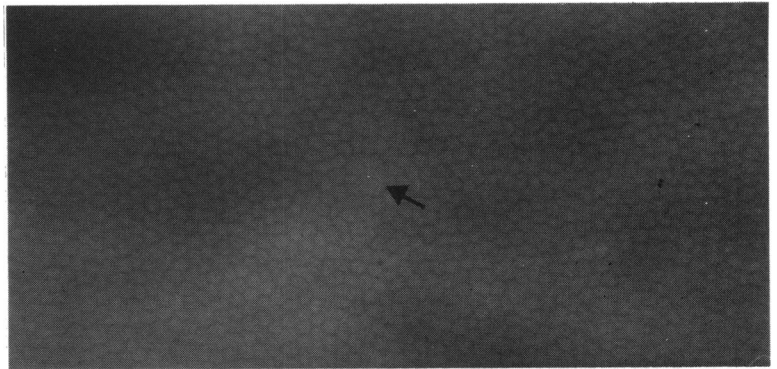
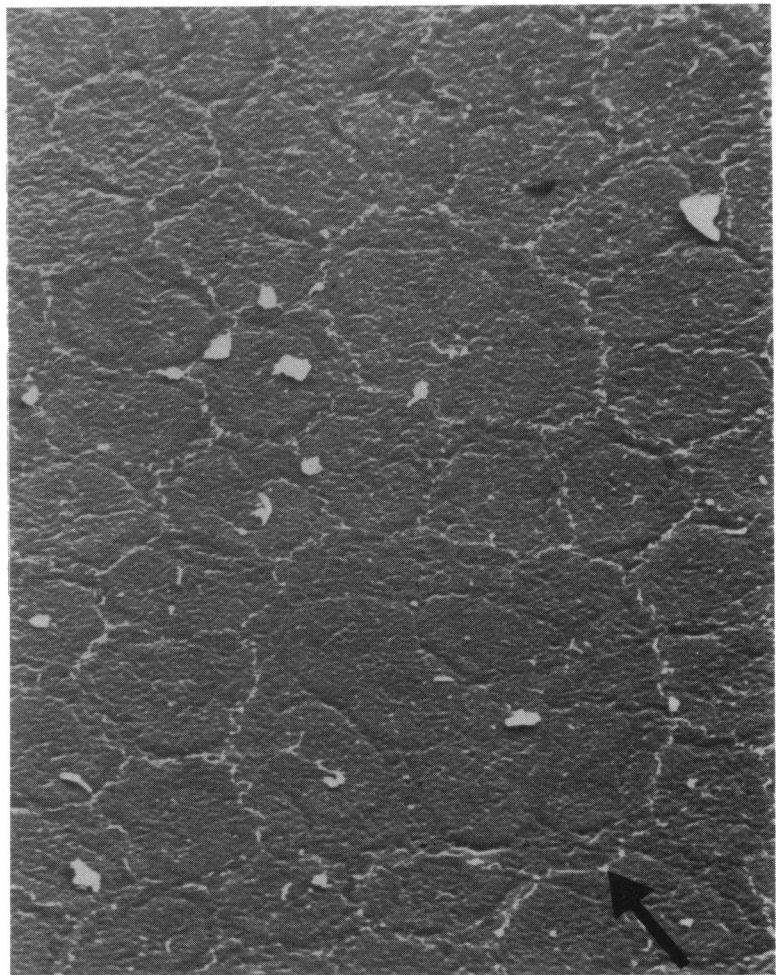


Fig. 3B Scanning electron micrograph of portion of endothelium in 1A including the same giant cell (arrowed) at same orientation. ($\times 870$).



induced lesion is seen in Fig. 3C. The open arrows indicate black featureless areas that are surrounded by an amorphous or finely speckled grey band, which

gives way at the periphery to a narrow dark zone that abuts adjacent recognisable endothelial cells, which, however, appear compressed or scalloped and give




Fig. 3C *Specular photomicrograph after laser iridotomy. The field to the right of the marker giant cell now includes several YAG induced lesions. Open arrows=open arrows in 3D. ($\times 12$).*

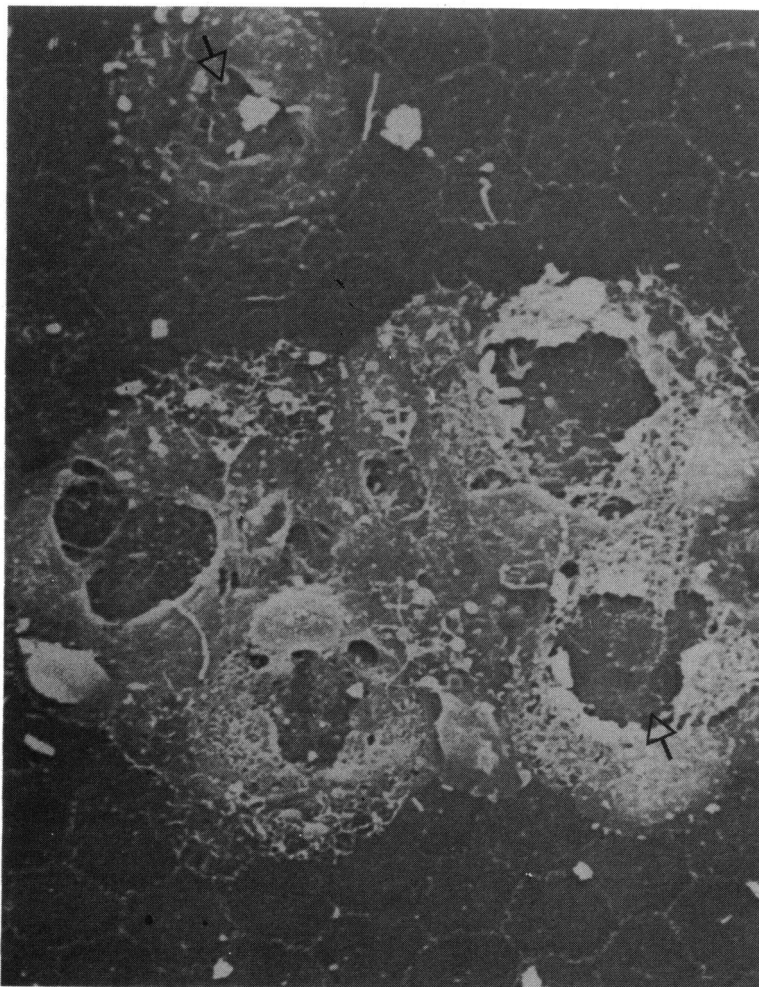


Fig. 3D *Scanning electron micrograph of portion of endothelium in C. Arrows identify arrowed lesions in C. ($\times 610$).*

a bright specular reflex. Fig. 3D is the scanning electron micrograph of the same 'lesion' and shows that the four featureless areas in specular photomi-

croscopy represent exposed Descemet's membrane, where groups of endothelial cells have been destroyed. The sharp bright image in Fig. 3D of the

adjacent tissue represents the inner boundary of a broad band of undercut and raised cells with a finely porous appearance. These correspond to the grey band in the specular image. These cells are undoubtedly irreversibly damaged.¹³ The outer limit of the lesion, seen as a dark haze in specular view (Fig. 3C), is well demarcated from adjacent endothelial cells and has either a microvillous or undulating pattern to the posterior endothelial surface (Fig. 3D). This appearance is not associated with permanent cell damage.¹³

Discussion

Both continuous wave (argon or krypton) and short pulsed (Nd/YAG) lasers deliver focused light energy to target tissues. The objective of continuous wave lasers is the deposition of energy within the tissue to induce a temperature rise of sufficient magnitude to coagulate target tissues. This process is dependent upon the degree of tissue pigmentation and density.^{14 15} By contrast, the objective of short pulsed lasers is not coagulation but disruption of target tissue by delivering very high power to a very small focus in a highly localised focal plane, which results in the formation of a 'plasma'—a small volume around the focus where irradiated tissues become ionised into a gaseous state (optical breakdown).¹⁶ Target tissues may be transparent, opaque, and/or pigmented. The high powers required for this disruptive facility are achieved in the Q-switched laser by an electro-optical shutter within the laser cavity which permits an accumulation of light energy, so that when the shutter becomes transparent a very short pulse (2–30 ns) of energy can be delivered to the laser focus. It is believed that photodisruption of target tissues is achieved by three interrelated mechanisms.¹⁶ First, focal disintegration of tissue within the plasma due to electron stripping and ionisation; second, shock and acoustic pressure waves created by the tissue recoil around the plasma microexplosion with a maximal effect in tissues adjacent to the plasma; and third, inherent elasticity of the tissues which may enhance the damage created by the first two mechanisms.

Reports of actual and potential unwanted damage to intraocular structures have been directed towards the retina and pigment epithelium with vitreous membrane disruption, to the intraocular lens and retina during capsulotomy, and to the crystalline lens during iridotomy.^{5–8 17}

Previous reports of corneal injury describe a clinically insignificant transient haze immediately related to the iridotomies in narrow angled chambers,¹ and endothelial specular microscopical lesions, similar to those in the present paper, after argon laser photo-

coagulation. The authors attributed the latter changes to the use of a Goldmann contact lens.¹⁸

In this preliminary study in man, YAG induced corneal endothelial damage occurred in all the iridotomies, and, although concentrated in the immediate vicinity of the laser focus, they were often distributed far beyond. More endothelial damage occurred with multimode operation (focus diameter 70 μm)⁵ than the fundamental mode (focus diameter 7 μm)⁵ operation.

Specific corneal endothelial damage after laser iridotomy and capsulotomy has not been described previously, yet in this study all iridotomies and all capsulotomies without an intraocular lens implant in situ developed multiple endothelial lesions.

Although the extent and site of the lesions varied following iridotomy and capsulotomy, they appeared similar by specular microscopy.

With the explosive nature of Nd/YAG photodisruption and the post plasma particulate dispersion throughout the anterior chamber borne in mind, the specular microscopical changes suggest a high velocity impact injury to the endothelium with maximal damage in the centre of the lesion and graduated centrifugal changes. The scarcity of lesions following laser capsulotomy in the pseudophakic eye suggests that the implant may act as a barrier against particulate dispersion.

From the specular appearance alone it is not always possible to determine the nature of the endothelial lesion. For example, a temporary alteration in cell structure, such as microvilli of the posterior endothelial surface, may distort the specular image in a similar pattern to that induced by an irreversibly damaged cell.¹²

However, the similarity of the specular microscopical appearances of the induced lesions in the *in vitro* rabbit endothelium to those in patients indicates that their nature is the same. Because of the facility for precise cell to cell correlation of rabbit specular and scanning electron microscopical appearances it is possible to determine which specular changes represent reversible, and which irreversible, endothelial damage and to a degree to interpret the specular images in man. For example, isolated cells which appear dark and poorly defined in the specular image, that may obscure parts of the adjacent cells or form the peripheral dark collarette of the larger lesions, are found in both rabbits and man. SEM of the former shows these to be due to an excess of microvilli—and this is a reversible change.¹²

By contrast lesions of an irreversible nature, which may involve single or large groups of cells, are well demarcated and often have dark featureless centres surrounded by a variable grey band interspersed with fine brighter reflecting particles. SEM of the rabbit

specimens shows these to be circular areas of exposed Descemet's membrane surrounded by a number of disrupted cells with an outer collarette of cells bearing excess microvilli.

The variation in the absolute numbers of cells lost may be attributable to several factors: the target tissue/endothelium distance, the nature of the tissue being disrupted, differences in delivery of the laser energy (for example the number of bursts, the number of pulses per burst, and the mode of delivery), and the quantity of energy itself. Further studies are necessary to identify the significance of each of these factors.

The majority of eyes that receive YAG laser treatment to the anterior segment have had either previous surgery or a condition which may result in a depletion of endothelial cells.¹⁹ Thus the additional cell loss associated with the YAG laser will be less well tolerated and may, in time, lead to corneal decompensation as a result of normal age related cell loss.²⁰ Or, as in one of the cases described above, the confluence of lesions led to corneal oedema within one hour of YAG treatment—with a change in the corneal thickness from 0.52 mm to 0.62 mm. At six weeks this cornea remained decompensated with a thickness of 0.58 mm.

CONCLUSION

To quote Saiichi Mishima: 'endothelial damage must be evaluated in its long-term course, and we cannot emphasise too much the importance of minimising trauma to the endothelium during intra-ocular surgery'²¹—and, we would add, laser photodisruption.

We thank the surgeons of Moorfields Eye Hospital for referring their patients for endothelial specular microscopy, Mr Roger Buckley and Professor John Marshall for helpful criticism, Miss C Smyth for typing the manuscript, and Mr W Ng for technical assistance.

References

- 1 Fankhauser F, Roussel P, Steffen J, Van der Zypen E, Chrenkova A. Clinical studies on the efficiency of high power laser radiation upon some structures of the anterior segment of the eye. *Int Ophthalmol* 1981; **3**: 129–39.
- 2 Fankhauser F, Lortscher H, Van der Zypen E. Clinical studies on high and low power laser radiation upon some structures of the anterior and posterior segments of eye. *Int Ophthalmol* 1982; **5**: 15–32.
- 3 Aron-Rosa D, Aron JJ, Grisemann M, Thyzel R. Use of the neodymium YAG laser to open the posterior capsule after lens implant surgery: a preliminary report. *Am Intraocular Implant Soc J* 1980; **6**: 352–4.
- 4 Aron-Rosa D. Use of a pulsed neodymium YAG laser for anterior capsulotomy before extracapsular cataract extraction. *Am Intraocular Implant Soc J* 1981; **7**: 332–3.
- 5 Fankhauser H. *Working principles and clinical results with the Q-switched laser*. LASAG AG Instruction manual for Sirius Microruptor II. LASAG AG: 1982.
- 6 Ready JF. *Effects of high-power laser radiation*. New York: Academic Press, 1971; 213–316.
- 7 Marshall J. Thermal and mechanical mechanisms in laser damage to the retina. *Invest Ophthalmol Visual Sci* 1970; **9**: 97–115.
- 8 Jampol LM, Goldberg MF, Jednock N. Retinal damage from a Q-switched YAG laser. *Am J Ophthalmol* 1983; **96**: 326–9.
- 9 Bonney CH, Gaasterland DE. Low-energy Q-switched ruby laser iridectomies in Macaca mulatta. *Invest Ophthalmol Visual Sci* 1979; **18**: 278–87.
- 10 Puliafito CA, Steinert RF. Laser surgery of the lens; experimental studies. *Ophthalmology* 1983; **90**: 1007–12.
- 11 Sherrard ES, Buckley RJ. Contact clinical specular microscopy of the corneal endothelium: optical modifications to the appanating objective cone. *Invest Ophthalmol Visual Sci* 1981; **20**: 816–20.
- 12 Sherrard ES. Interpretation of specular microscopical images of insulted corneal endothelium by scanning electron microscopy. *Exp Eye Res* in press.
- 13 Sherrard ES. Intraocular lens damage to the endothelium of *in vitro* rabbit corneae: a specular and scanning electron microscopical study. *Trans Ophthalmol Soc UK* in press.
- 14 Mainster MA, White TJ, Tips JH, Wilson PW. Retinal temperature increases produced by intense light sources. *J Opt Soc Am* 1970; **60**: 264–7.
- 15 Mainster MA, White TJ, Allen RG. Spectral dependence of retinal damage produced by intense light sources. *J Opt Soc Am* 1970; **60**: 848–55.
- 16 Mainster MA, Sliney DH, Belcher CD, Buzney SM. Laser photodisruptors; damage mechanisms, instrument design and safety. *Ophthalmology* 1983; **90**: 973–91.
- 17 Goldman AI, Ham WT, Mueller HA. Mechanisms of retinal damage from the exposure of rhesus monkeys to ultrashort laser pulses. *Exp Eye Res* 1975; **21**: 457–69.
- 18 Makitie J, Vannas A, Ahonen R, Teir H. Effects of contact glass and photocoagulation on the corneal endothelium. In: *Acta XXIV International Congress of Ophthalmology*. Philadelphia: Lippincott, 1982; **1**: 267–72.
- 19 Bigar F, Witmer R. Corneal endothelial changes in primary acute angle-closure glaucoma. *Ophthalmology* 1982; **89**: 596–9.
- 20 Laing RA. Specular microscopy of the cornea. In: Zadunaisky JA, Davson H. eds. *Current topics in eye research*. New York: Academic Press, 1980; **3**: 157–218.
- 21 Mishima S. Clinical investigations on the corneal endothelium. *Ophthalmology* 1982; **89**: 525–30.