Clinicopathologic Conference

Rapidly Progressive Dementia Caused by Spongiform Encephalopathy

Discussants
BRUCE E. ENOS, MD, *and* HARRY V. VINTERS, MD

HARRY V. VINTERS, MD*: A 53-year-old woman, a receptionist, was in good health until six weeks before hospital admission, at which time she stopped going to work because she was "feeling bad." She had frequent episodes of dizziness and buzzing in the ears and an intermittent feeling of fullness in the ears. An otolaryngologist noted her blood pressure to be 180/96 mm of mercury. A week after her symptoms began, she was sleeping excessively during the day, irritable, extremely sensitive, unusually quiet at times, but oriented to time and person. At Christmas, about two weeks after the onset of her symptoms, she neglected to give gifts to family members, which was attributed to situational stress. A physician noted that she had an ataxic gait, slurred speech, and fell to the right when attempting a tandem gait. There was diminished ability to perform rapid alternating movements with the right hand.

At her initial hospital admission, a general physical examination showed no abnormalities. On neurologic examination she had slow speech, but she was able to follow commands and was fully oriented. Her gait was ataxic, and there was an especially pronounced difficulty in doing tandem gait, with a tendency to fall to the right. There was upward drift of the right hand on extension. The results of routine biochemical studies and a toxicology screen were normal. A lumbar puncture yielded clear colorless cerebrospinal fluid (CSF) that showed no abnormalities. An electroencephalogram (EEG) showed diffuse slowing, with some tendency for slow activity to be localized to the left cerebral hemisphere. An isotope brain scan was normal. In hospital, the patient remained independent and kept herself groomed, but she lost interest in daily activities such as reading and watching television and was indifferent to current events. She showed rapidly deteriorating memory, ambulation, and personality. Insight into her problem decreased. She had difficulty grasping objects with the right hand. She was discharged home briefly and readmitted to hospital because she had "no feeling" on the right side. She remained awake and alert but was now notably confused, with poor immediate and remote recall. Her affect was blunted, and she was unable to write or calculate but had no right/left confusion.

The patient had smoked a pack of cigarettes per day but did not abuse drugs or alcohol. She had an appendectomy in 1949 and a hysterectomy in 1968. Her family history was noncontributory. The patient's medications included conjugated estrogen (Premarin), hydrochlorothiazide, and levothyroxine sodium (Synthroid).

On physical examination 1½ months after her symptoms began, she had a blood pressure of 130/80 mm of mercury with no orthostatic change, and her pulse was 85 per minute and regular. She cooperated poorly, was agitated and hostile throughout the examination, but appeared well developed and well nourished for her stated age. She was alert but notably confused. There was poor recall for immediate, recent, or remote events. Her affect was blunted, and the patient was not hallucinating or delusional. Her speech was occasionally interrupted and nonfluent. The patient was unable to write or calculate.

Cranial nerves on examination were normal, and the fundi showed no abnormalities. A motor examination revealed that muscle tone was slightly diminished throughout. There was no focal atrophy, and no fasciculations were noted. With her upper extremities outstretched, she had pendular movements with hyperabduction of the right arm. Testing of strength was not feasible, though there was no apparent focal weakness. Deep tendon reflexes were 1 to 2+ throughout, and plantar responses were equivocal. Sensory testing was difficult apart from assessing perception of pinprick, which showed no abnormalities. She showed poor performance of finger-to-nose and heel-to-shin testing bilaterally, though this was more pronounced on the right side, and she had slight truncal ataxia. Her gait was slightly broad based, and the patient was unable to tandem walk.

Further studies in hospital included an EEG that, in addition to the diffuse slowing of the background rhythm, showed superimposed triphasic waves throughout. Assays for heavy metals (arsenic, lead, mercury) were all within normal limits. Urinary porphyrin studies showed no abnormalities. Serum electrophoresis and thyroid-stimulating hormone, tri-

*Assistant Professor of Pathology (Neuropathology), UCLA Medical Center, Los Angeles.

(Enos BE, Vinters HV: Rapidly progressive dementia caused by spongiform encephalopathy [Clinicopathologic Conference]. West J Med 1988 Mar; 148:313-319)

From the Departments of Neurology (Dr Enos) and Pathology (Neuropathology) (Dr Vinters), University of California, Los Angeles, Medical Center.
Reprint requests to Harry V. Vinters, MD, Department of Pathology, UCLA Medical Center, CHS Room 18-170, Los Angeles, CA 90024-1732.

ABBREVIATIONS USED IN TEXT

CNS = central nervous system
CSF = cerebrospinal fluid
CT = computed tomographic
EEG = electroencephalogram

iodothyronine, thyroxine, serum B_{12}, and folate levels were normal. The VDRL was nonreactive in serum and CSF, and results of serologic studies aimed at detecting an autoimmune disorder were noncontributory. Serum and CSF antibody titers to several viruses were within normal limits. The CSF myelin basic protein level was normal, and oligoclonal bands were not seen. A computed tomographic (CT) scan of the head with and without contrast was normal. Brain-stem auditory evoked potentials were unremarkable. Delayed latencies were noted on the flash visual evoked potential test. Serial EEGs showed pronounced abnormalities due to the presence of pseudoperiodic complexes in the parasagittal regions, which were at times asymmetric—that is, present in the left temporal distribution while absent on the right. This was superimposed on diffuse background slowing. Periodic and pseudoperiodic complexes with a triphasic appearance were noted, as were frequent multifocal and generalized spikes. The patient was discharged from hospital on a medication regimen that included phenytoin and multivitamins (Theragran).

Following this neurologic assessment, she survived about 22 months. During this time, myoclonic jerks were said to develop, and her dementia progressed, as did ataxia and rigidity. The circumstances of her death are unknown.

BRUCE E. ENOS, MD*: In summary, the case is that of a previously healthy 53-year-old woman with a subacute onset of mental deterioration and ataxia, followed by a more protracted course of progressive dementia, ataxia, rigidity, and myoclonus. The entire time span from the beginning of her neurologic deterioration to death was about two years.

Early on, prodromal symptoms began suddenly, followed by a fairly rapid change in life habits accompanied by vague symptoms of intermittent dizziness, tinnitus, and ear fullness. Over two weeks she became irritable, labile, somnolent, and forgetful. About one to two months into her course, right-sided sensory changes developed. On examination there was little in the way of objective focal findings except for some updrift of the right hand on extension, suggesting some relatively right-sided proprioceptive loss. An EEG done at that time showed asymmetric bihemispheric slowing more prominent on the left. There was a progressive dementia with changes in personality, memory, language, and cognitive function. Emotional lability, hostility, and agitation were evident. The patient subsequently had more profound dementia and ataxia, as well as superimposed rigidity and myoclonus.

Deficits noted on the neurologic examination were referable to several regions of the neuraxis. The prominent ataxia implicates involvement of the cerebellum or its connections (or both). Dementia usually reflects diffuse cortical impairment or damage to deep subcortical structures that have diffuse cortical projections. This may occur from a variety of causes to be discussed later. The myoclonus that developed later in the course may also be a reflection of cortical involvement, although disease of the brain stem or possibly spinal cord might explain this, depending on the clinical characteristics of the myoclonus.[1] Emotional lability may reflect damage to the frontal cortex or to deep limbic structures. In the absence of significant weakness, sensory abnormalities, visual field deficits, or tone or reflex changes, there was little evidence of early involvement of long tracts or fiber systems of the cerebral white matter. In summary, the clinical course and neurologic findings are most consistent with a progressive, diffuse polioencephalopathy.

The early clinical course included an abrupt or subacute onset; ataxia; focal, right-sided, subjective sensory changes; and emotional lability. Diverse causes such as acute toxic and metabolic encephalopathies, central nervous system (CNS) infection, mass lesion (including multiple metastases), and vascular insufficiency must have occurred to the physicians who first assessed this patient. Laboratory tests to confirm a metabolic derangement or heavy metal toxicity gave normal values. Lumbar punctures on at least two occasions failed to show evidence of malignant cells or inflammatory change within the CNS or subarachnoid space. A CT scan failed to show a mass lesion. Focal symptoms that began abruptly may have suggested multiple strokes, but the superimposed gradual neurologic deterioration that occurred over the next two years effectively removes this as the explanation for her decline. A vasculitis affecting small cerebral blood vessels may cause focal or diffuse neurologic signs and symptoms and may be associated with normal CSF findings.[2-4] However, there were no signs of systemic vasculitis on examination, and the protracted clinical course tends to remove an isolated CNS vasculitis from serious diagnostic consideration.

The differential diagnosis of dementia is extensive. It includes primary cerebral cortical degenerations—such as Pick's disease and Alzheimer's disease—extrapyramidal syndromes, multi-infarct dementia, viral or other infectious causes, hydrocephalus, toxic-metabolic disturbance, neoplasm (within the brain or as a remote effect of visceral malignancy), and demyelinating disease. Considering the clinical course, findings on physical examination, normal serum biochemical values, normal CSF, and the absence of a mass lesion on imaging studies, I presume that this dementia represents a noninflammatory degenerative process affecting the cerebral cortex diffusely or deep subcortical structures with diffuse cortical projections.

We are left, then, with the possibility of a storage disorder, a paraneoplastic syndrome, primary parenchymal degeneration, or CNS infection by an unconventional infectious agent as a possible cause of this patient's clinical presentation and progression. Several storage disorders such as GM_2 gangliosidosis, atypical Gaucher's disease, and ceroid lipofuscinosis may produce a late-onset polioencephalopathy with a clinical syndrome of dementia, myoclonus, ataxia, and rigidity.[5] This patient's progression and onset of symptoms at age 53 years, however, would be incompatible with these disorders. Paraneoplastic syndromes may produce heterogeneous neurologic syndromes. Various syndromes have been described affecting the cerebellum, brain stem, peripheral nerves, spinal cord and dorsal root ganglia, and the limbic system.[6,7] Pathologic changes, when present, are relatively nonspecific and include perivascular accumulation of mononuclear cells, focal necrosis of neurons, and microglial infiltrates and gliosis.[7] The inflammatory nature of this syndrome, however, is occasionally reflected in an increased number of cells or protein within the CSF, which was not seen in this patient. I am also

*Resident, Department of Neurology, UCLA Medical Center.

unaware of reports describing patients who present with a paraneoplastic syndrome involving dementia, myoclonus, and periodic complexes on an EEG. The primary cortical degenerations causing dementia (Alzheimer's disease, Pick's disease) are unlikely considerations in this case for several reasons. Ataxia is not a feature of their presentation. Even those cases that are the most rapidly progressive are of longer duration than was the case with this patient. In addition, the syndromes usually progress with a fairly typical clinical course much different from that seen in this woman.[5]

The most likely explanation of this patient's findings would be brain infection by a "slow virus" or an unconventional infectious agent, specifically Creutzfeldt-Jakob disease. Prodromal symptoms occur in about 40% of patients with this disease and include asthenia, sleep disturbance, and depression. A gradual onset is more common than a sudden onset, but the latter may occur in about 20% of affected persons. In about 10%, the abrupt occurrence of a single symptom may even resemble a transient ischemic attack or stroke.[8,9] Focal signs and symptoms are not uncommon. The mean survival after onset is about eight months, but cases lasting two years or longer have been described.[10-12] The clinical course is marked by progressive dementia and behavioral changes. Myoclonus and rigidity typically supervene later. Serum biochemical values and results of CSF examination are normal.

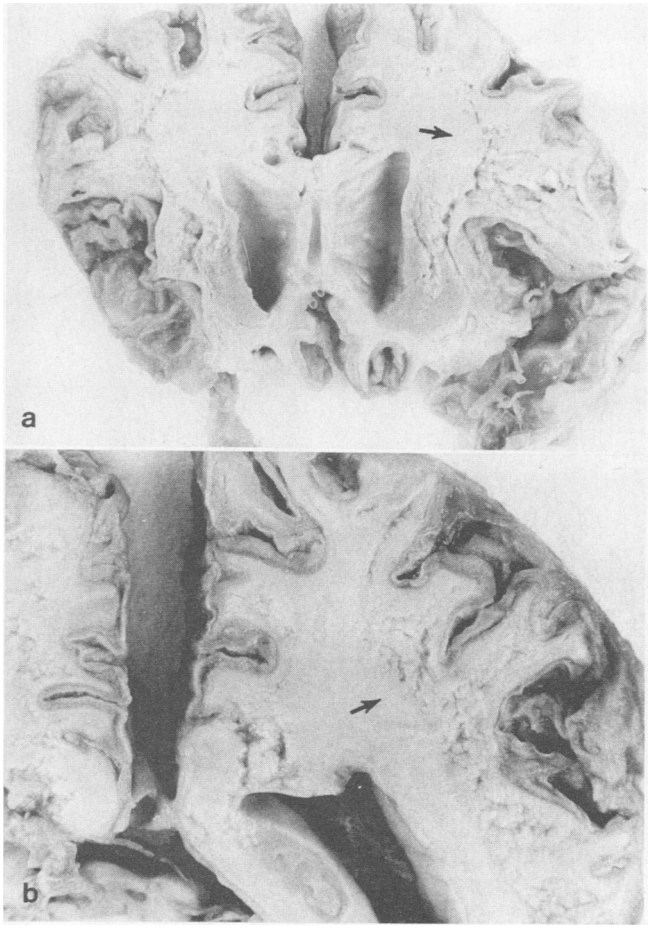

Figure 1.—Coronal sections of fixed brain from the region of the frontal lobes **(a)** and parietal lobes **(b)** show severe diffuse cortical atrophy and multifocal cystic collapse of white matter of the centrum semiovale bilaterally **(arrows).** Dilatation of the lateral ventricles is also seen.

The EEG findings in this case are helpful in establishing the correct diagnosis and effectively ruling out other parenchymal brain diseases that may produce dementia, such as Alzheimer's disease and Pick's disease. Pseudoperiodic triphasic waves, more prominent in the left hemisphere, appeared six weeks into the patient's clinical course. These were superimposed on a diffusely slow background rhythm. Triphasic waves are associated with relatively few clinical disorders, including metabolic encephalopathies, postictal states, and Creutzfeldt-Jakob disease.[13,14] Creutzfeldt-Jakob disease is associated with runs of pseudoperiodic triphasic waves with frequencies in the range of 1 to 2 Hz. Even considering that triphasic waves may be associated with other clinical disorders, when they occur in a patient with progressive dementia, myoclonus, and rigidity, they are virtually pathognomonic for the disease. In a vast majority of patients, they occur within 12 weeks of the start of symptoms. Triphasic waves may be more prominent contralateral to the side of major clinical involvement, as was the case in this patient.[13]

Familial or sporadic dementias with myoclonus may present in a fashion clinically indistinguishable from Creutzfeldt-Jakob disease, though they often show a more protracted clinical course extending over years. Several clinical and electrophysiologic features tend to distinguish these rare disorders from Creutzfeldt-Jakob disease.[15] Subacute sclerosing panencephalitis is a degenerative disorder characterized by a rapid onset of dementia with associated myoclonus and rigidity seen



Figure 2.—Midsagittal section of cerebellum shows severe atrophy throughout the vermis, most pronounced in its anterior superior portion **(arrow).**

late in the clinical course, but the dementia usually starts in the late first or early second decade. A CSF examination shows immunoglobulin G against the measles virus. The EEG has a pseudoperiodic pattern, but the repetitive transients are not simply triphasic and usually are complex polyspike, multiphasic discharges occurring every four to ten seconds.[14]

In summary, the clinical history and laboratory findings in this case are most consistent with Creutzfeldt-Jakob disease or spongiform encephalopathy.

Autopsy Findings

Only the brain was available for examination. The fixed brain showed diffuse atrophy of the cerebral hemispheres, most prominent in the frontal and temporal lobes with some sparing of the occipital regions. The leptomeninges were minimally opacified. The circle of Willis appeared normal. The cerebellum appeared diffusely atrophic, but the brain stem was relatively intact. Coronal sections of the cerebral hemispheres confirmed the severe, diffuse cortical atrophy throughout all lobes (Figure 1). The atrophy was focally accentuated to the point where only 0.5 to 1.0 mm of residual cortex was identified in many regions. The white matter showed multifocal encephalomalacia, with a moth-eaten appearance in a patchy distribution throughout the white matter of the centrum semiovale in both hemispheres (Figure 1). The cystic regions within the white matter were poorly demarcated, subconfluent spongy areas that varied in size from a few millimeters to several centimeters in greatest dimension. In many areas, the abnormal white matter extended to the cerebral cortex and was in continuity with areas of severe cortical atrophy. The collapse of the cortex and white matter in some regions was so pronounced as to simulate the appearance of an infarct, such as in the left insular region. Deep central grey structures including caudate and lentiform nuclei were collapsed and atrophic. Degeneration of the white matter extended symmetrically into both internal capsules and the corpus callosum. The diencephalon, however, including the mamillary bodies was relatively normal. The lateral ventricles were greatly dilated, and the third ventricle was slightly dilated. A small cavity of the septum pellucidum was identified. The hippocampi and the lateral geniculate nuclei appeared normal.

Mid- and parasagittal sections of the cerebellar hemispheres again confirmed severe, diffuse atrophy throughout the folia, most pronounced in the superior cerebellar hemispheres and especially in the anterior superior vermis (Figure 2). Horizontal sections of the brain stem showed an appearance of white matter similar to that identified above in the centrum semiovale, within the basis pontis and the cerebral peduncles, though apparently sparing the cerebellar peduncles and deep cerebellar white matter. The cerebral aqueduct and fourth ventricle were of normal size and configuration, and the pigmented nuclei (locus ceruleus and substantia nigra) were normal.

Microscopic sections of the neocortex and subcortical white matter from several regions of cerebral hemispheres showed similar features, though the severity of involvement varied from section to section. There was severe diffuse

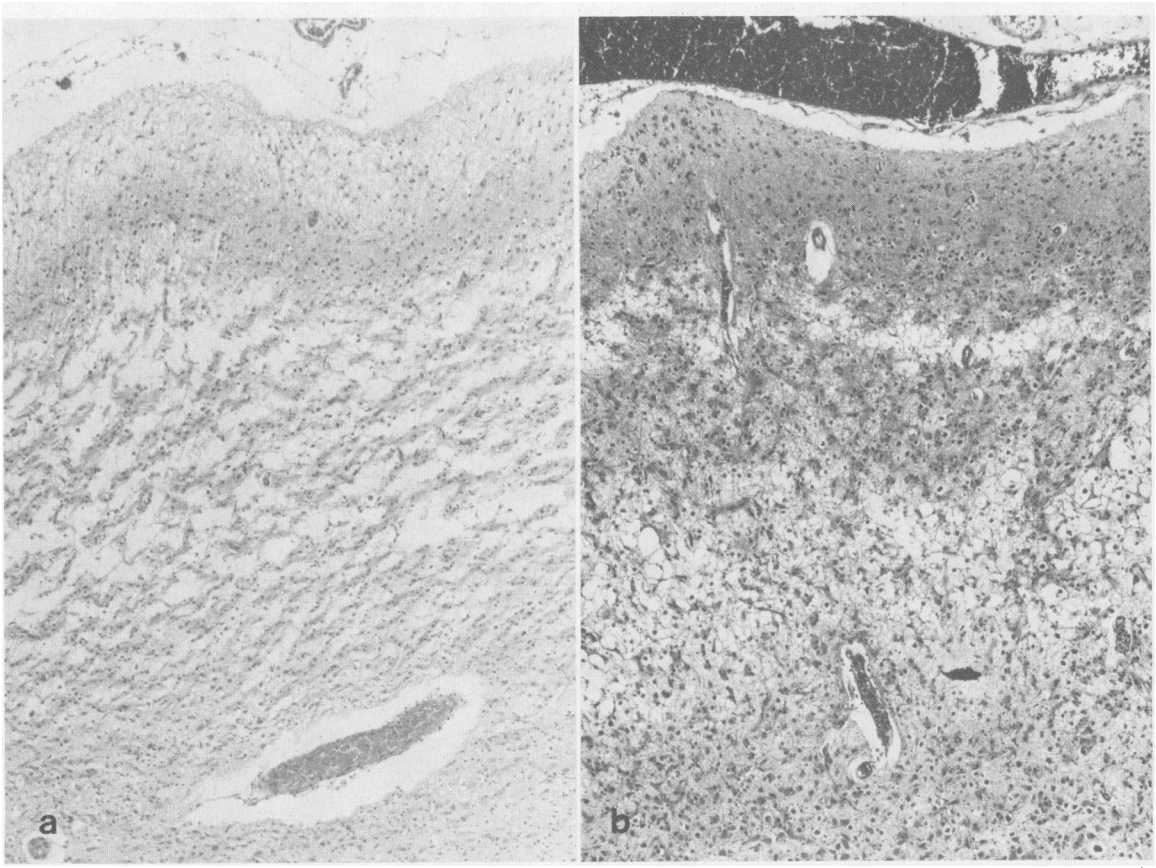

Figure 3.—Two sections of cortex from different regions, both showing virtually total loss of neurons and reactive astrocytic gliosis. In **a**, there is status spongiosus of the cortex, whereas **b** shows more characteristic vacuoles of varying sizes within the neuropil. Note the relative preservation of the molecular layer in both sections (**a**, hematoxylin and eosin, original magnification × 80; **b**, Bielschowsky's, original magnification × 80).

status spongiosus of the cortex with relative sparing of the molecular layer. The spongy change showed the appearance of either vacuoles within the neuropil or more poorly defined regions of rarefaction within the parenchyma (Figure 3). In some areas of cortex, there was essentially a total absence of neurons and, instead, the cortex had taken on a cribriform appearance (Figure 4). Substantial reactive astrocytosis was present, and the astrocytes seen were often of the gemistocytic variety.

Throughout the subcortical white matter—reflecting the changes noted at the time of brain cutting—there was severe degeneration of the white matter with apparent loss of myelin, axon cylinders, and a dense proliferation of gemistocytic astrocytes (Figure 5). All areas of the deep central white matter were affected by this process. In contradistinction to the cortex, the white matter showed numerous clusters of compound granular corpuscles (histiocytes), and an occasional macrophage contained material with the appearance of hemosiderin (Figure 6). Several thin-walled venules showed the presence of slight to moderate perivascular lymphocyte cuffing (Figure 5), and this was seen in a patchy distribution throughout the cerebral hemispheres.

The one region of cortex that was relatively spared was the hippocampus, which showed preservation of the granule cell layer and most portions of the pyramidal cell layer. The pyramidal cell layer was intact from the end-plate region distally to the level of the prosubiculum-subiculum junction, and a few intact neurons were identified in the parahippocampal gyrus. No senile plaques or neurofibrillary tangles were present in the hippocampus. The lateral geniculate nucleus was devoid of neurons and showed pronounced reactive astrocytosis. Deep central grey structures including the mamillary bodies showed severe neuron loss and spongy change with gliosis—that is, changes similar to those described above—though an occasional island of spared neurons was identified.

Sections of the midbrain showed severe degeneration that was essentially confined to the cerebral peduncles, with numerous compound granular corpuscles and reactive astrocytes identified. The colliculi showed severe neuron loss and gliosis. Oculomotor nerve nuclei were preserved, as were pigmented neurons of the substantia nigra. The pons (Figure 7) showed severe degeneration within the basis pontis, especially involving the corticospinal tracts, but severe neuron loss and astrocytic gliosis were noted within the territory of the pontine nuclei. The floor region of the fourth ventricle was relatively preserved. The medulla oblongata and pontine tegmentum showed no abnormality apart from the presence of severe secondary pyramidal tract degeneration. The inferior olivary nuclei showed slight neuron loss and astrocytic gliosis.

Sections of the cerebellar cortex showed severe atrophy, but the most severe loss was noted within the granule cell layer (Figure 8). Purkinje's cells were remarkably well preserved, but there was Bergmann's cell gliosis within the Purkinje cell layer despite the relative preservation of neurons. Severe gliosis was noted within the deep white matter of the cerebellum, which showed the loss of myelinated fibers. No area of the brain showed either parenchymal or microvascular amyloid—that is, senile plaque amyloid or amyloid-congophilic angiopathy. The only vascular abnormality noted was occasional slight to moderate fibromuscular intimal hyperplasia in a large leptomeningeal artery. The leptomeninges were otherwise normal.

Discussion

The histopathologic changes in this brain are typical of those seen in spongiform encephalopathy or Creutzfeldt-Jakob disease,[16,17] though several unusual features are present and deserve comment. The extensive parenchymal spongiform change, together with neuron loss and profound reactive

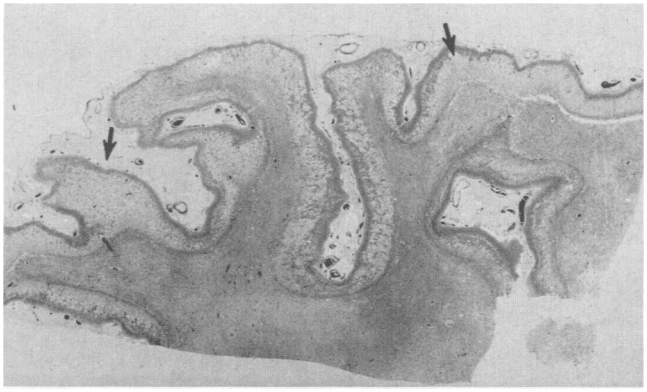

Figure 4.—A whole mount of cortex and subcortical white matter shows cribriform appearance of all areas of cortex **(arrows)** and multifocal pallor of underlying white matter (Bielschowsky's, original magnification × 5).

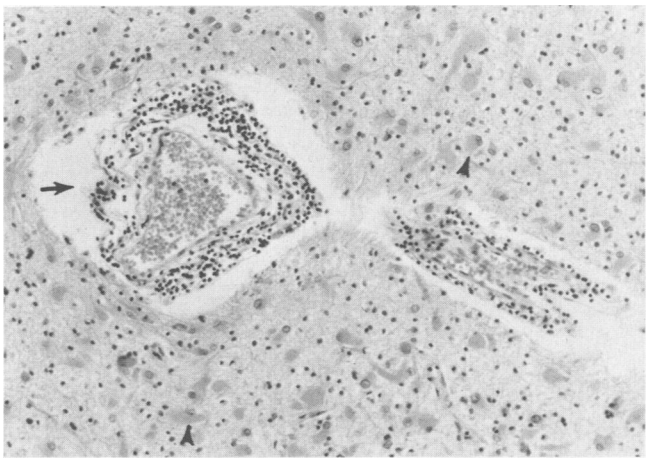

Figure 5.—The subcortical white matter shows extensive proliferation of gemistocytic astrocytes **(arrowheads)** and perivascular cuffing by mononuclear inflammatory cells **(arrow)** (hematoxylin and eosin, original magnification × 200).

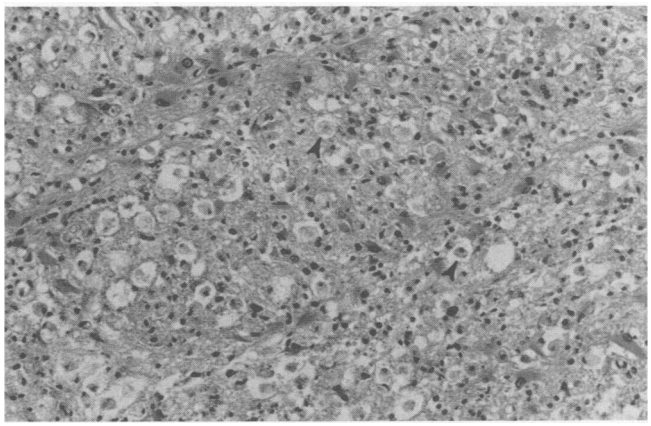

Figure 6.—A section of internal capsule shows severe degeneration of white matter, with abundant astrocytes (as in Figure 4) and many lipid-laden foamy macrophages **(arrowheads)** (hematoxylin and eosin, original magnification × 200).

astrocytic gliosis, confirm the clinical diagnosis. It should be stressed that status spongiosus of the brain can be a nonspecific finding and is often associated with severe and long-standing gliosis.[18] The severe neuron loss and reactive astrocyte proliferation seen in this patient's brain are undoubtedly also partly responsible for the cribriform appearance of much of the cerebral cortex—that is, vacuoles within cell processes

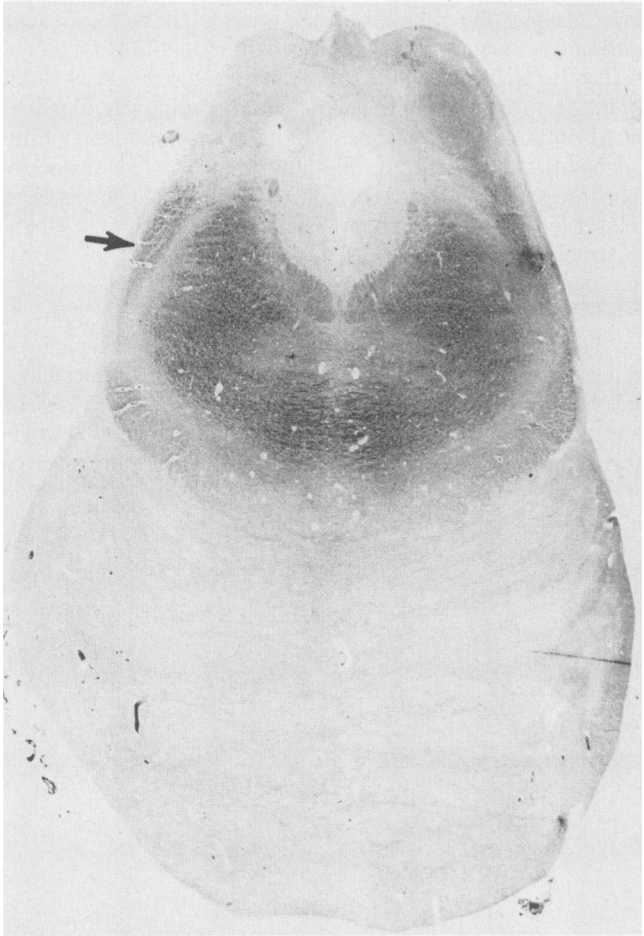

Figure 7.—A section of pons is stained to show myelin. All components of the basis pontis show extreme pallor, whereas the tegmentum **(arrow)** is relatively preserved (luxol fast blue, original magnification × 5).

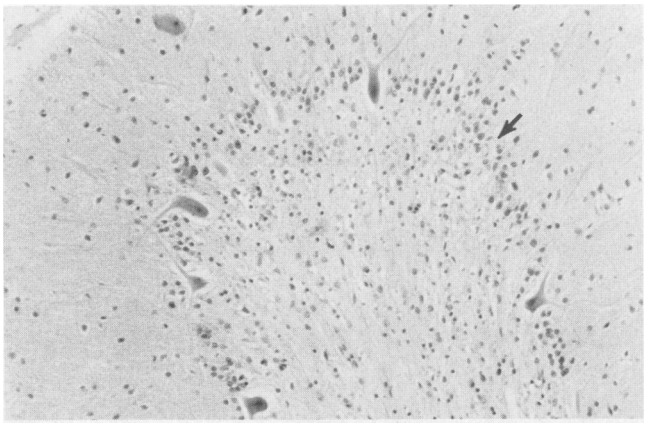

Figure 8.—The cerebellum shows severe cell loss in the granule cell layer but relatively preserved Purkinje's cells. Note the absence of spongiform change. There is proliferation of Bergmann's astrocytes **(arrow)** in the Purkinje's cell layer (hematoxylin and eosin, original magnification × 200).

(typical of this disease) were not easily identified because of the severe cortical destruction. The definitive diagnosis is made by inoculating diseased brain tissue into animals, such as primates, and effectively transmitting the neurologic disease, including inducing the appropriate histopathologic findings within the brain.[19] This procedure was not carried out in the present case. It is of further interest that this patient, with a relatively long clinical duration of disease, showed profound neocortical neuron loss—a finding that reinforces the results of a study that correlated specific histologic features within the CNS with the duration of illness in patients with this disease.[18] The relative sparing of the dentate gyrus and Ammon's horn have also been previously described.[18]

The severe degree of white matter change noted both grossly and microscopically in this patient's brain are most unusual. The gross appearances were so severe as to briefly suggest the presence of multifocal infarcts within the brain parenchyma, though histologic sections proved that the changes were not due to ischemia. Similar features of leukoencephalopathy have occasionally been noted in other patients with Creutzfeldt-Jakob disease[20,21] and were thought to represent white matter alterations that could *not* be explained purely on the basis of wallerian degeneration of axons due to neocortical neuron loss. Conversely, our case suggests that the white matter abnormality may indeed be on this basis. Several features support this contention: the profound loss of neurons from virtually all regions of the neocortex; the presence of lipid-laden histiocytes within white matter but not within the cortex, suggesting that the myelin and axon loss within the centrum semiovale postdated cell loss within the cortex; and the topography of the white matter change—that is, the corticospinal tracts were most severely involved, and other anatomic structures affected, such as pontine nuclei and pontocerebellar fibers within the basis pontis, may reflect a severe degree of transsynaptic secondary degeneration. (By contrast, ascending fiber systems, such as those in the pontine tegmentum, showed no significant abnormality.) A second unusual histologic feature was the moderately severe degree of perivascular cuffing by mononuclear inflammatory cells noted in a patchy distribution throughout the cerebral hemispheres. The essence of brain involvement by unconventional infectious agents is that inflammation does not occur.[22] Possibly this finding in the present case reflected an intercurrent brain infection by another (unidentified) conventional viral organism or simply a reaction to the severe degree of surrounding tissue breakdown.

Despite the relatively long duration of a dementing illness in this patient, she did not show the typical features of the Gerstmann-Sträussler-Scheinker syndrome.[23-25] The syndrome shares some morphologic features with the Creutzfeldt-Jakob disease but is characterized by the presence of extensive amyloid deposition within the neural parenchyma. Amyloid was not found in the brain of our patient despite a careful search for this extracellular material.

Several excellent reviews have summarized recent theories concerning the pathogenesis of the spongiform encephalopathies and the "prion" agent that is hypothesized to be important in their causation.[26-30]

REFERENCES

1. Adams RD, Victor M: Tremor, myoclonus, spasms, and tics, chap 5, Principles of Neurology, 2nd Ed. New York-St. Louis, McGraw-Hill, 1981, pp 69-79

2. Cupps TR, Fauci AS: The Vasculitides, Vol 21, *In* Smith LH Jr (Ed): Major Problems in Internal Medicine. Philadelphia-London, WB Saunders, 1981

3. Cupps TR, Moore PM, Fauci AS: Isolated angiitis of the central nervous system—Prospective diagnostic and therapeutic experience. Am J Med 1983; 74:97-105

4. Moore PM, Fauci AS: Neurologic manifestations of systemic vasculitis—A retrospective and prospective study of the clinicopathologic features and responses to therapy in 25 patients. Am J Med 1981; 71:517-524

5. Cummings JL, Benson DF: Dementia: A Clinical Approach. Boston, Butterworth's, 1983

6. Henson RA, Urich H: Cancer and the Nervous System—The Neurological Manifestations of Systemic Malignant Disease. Oxford-London-Edinburgh, Blackwell Scientific, 1982

7. Posner JB: Neurological complications of systemic cancer. Med Clin North Am 1979; 63:783-800

8. Brown P, Cathala F, Sadowsky D, et al: Creutzfeldt-Jakob disease in France: II. Clinical characteristics of 124 consecutive verified cases during the decade 1968-1977. Ann Neurol 1979; 6:430-437

9. Brown P, Cathala F, Castaigne P, et al: Creutzfeldt-Jakob disease: Clinical analysis of a consecutive series of 230 neuropathologically verified cases. Ann Neurol 1986; 20:597-602

10. Brown P, Cathala F, Gajdusek DC: Creutzfeldt-Jakob disease in France: III. Epidemiological study of 170 patients dying during the decade 1968-1977. Ann Neurol 1979; 6:438-446

11. Brown P, Cathala F, Raubertas RF, et al: The epidemiology of Creutzfeldt-Jakob disease: Conclusion of a 15-year investigation in France and review of the world literature. Neurology 1987; 37:895-904

12. Brown P, Rodgers-Johnson P, Cathala F, et al: Creutzfeldt-Jakob disease of long duration: Clinicopathological characteristics, transmissibility, and differential diagnosis. Ann Neurol 1984; 16:295-304

13. Levy SR, Chiappa KH, Burke CJ, et al: Early evolution and incidence of electroencephalographic abnormalities in Creutzfeldt-Jakob disease. J Clin Neurophysiol 1986; 3:1-21

14. Markand ON: Electroencephalography in diffuse encephalopathies. J Clin Neurophysiol 1984; 1:357-407

15. Little BW, Brown PW, Rodgers-Johnson P, et al: Familial myoclonic dementia masquerading as Creutzfeldt-Jakob disease. Ann Neurol 1986; 20:231-239

16. Lampert PW, Gajdusek DC, Gibbs CJ Jr: Subacute spongiform virus encephalopathies—Scrapie, kuru and Creutzfeldt-Jakob disease: A review. Am J Pathol 1972; 68:626-652

17. Katzman R, Kagan EH, Zimmerman HM: A case of Jakob-Creutzfeldt disease—1. Clinicopathological analysis. J Neuropathol Exp Neurol 1961; 20:78-94

18. Masters CL, Richardson EP Jr: Subacute spongiform encephalopathy (Creutzfeldt-Jakob disease)—The nature and progression of spongiform change. Brain 1978; 101:333-344

19. Beck E, Daniel PM, Matthews WB, et al: Creutzfeldt-Jakob disease—The neuropathology of a transmission experiment. Brain 1969; 92:699-716

20. Park TS, Kleinman GM, Richardson EP: Creutzfeldt-Jakob disease with extensive degeneration of white matter. Acta Neuropathol (Berl) 1980; 52:239-242

21. Miyakawa T, Katsuragi S, Koga Y, et al: Status spongiosus in Creutzfeldt-Jakob disease. Clin Neuropathol 1986; 5:146-152

22. Gajdusek DC: Unconventional viruses and the origin and disappearance of kuru. Science 1977; 197:943-960

23. Masters CL, Gajdusek DC, Gibbs CJ Jr: Creutzfeldt-Jakob disease virus isolations from the Gerstmann-Sträussler syndrome with an analysis of the various forms of amyloid plaque deposition in the virus-induced spongiform encephalopathies. Brain 1981; 104:559-588

24. Hudson AJ, Farrell MA, Kalnins R, et al: Gerstmann-Sträussler-Scheinker disease with coincidental familial onset. Ann Neurol 1983; 14:670-678

25. Vinters HV, Hudson AJ, Kaufmann JCE: Gerstmann-Sträussler-Scheinker disease: Autopsy study of a familial case. Ann Neurol 1986; 20:540-543

26. Bendheim PE: The human spongiform encephalopathies. Neurol Clin 1984; 2:281-298

27. Prusiner SB, Barry RA, McKinley MP, et al: Scrapie and Creutzfeldt-Jakob disease prions. Microbiol Sci 1985; 2:35-39

28. Matthews WB: Unconventional virus infection and neurological disease. Neuropathol Appl Neurobiol 1986; 12:111-116

29. Gray EG: Spongiform encephalopathy: A neurocytologist's viewpoint with a note on Alzheimer's disease. Neuropathol Appl Neurobiol 1986; 12:149-172

30. Prusiner SB, Gabizon R, McKinley MP: On the biology of prions. Acta Neuropathol (Berl) 1987; 72:299-314

Alzheimer's Disease and Down's Syndrome

A NUMBER OF IMPORTANT POINTS have come up about Alzheimer's disease. Down's syndrome is a very significant concept—and a very important model that is giving us a lot of information about the possibilities of familial Alzheimer's.

Now, in the last five years, after 100 years of this disease being in existence, we have found out where the major lesions are in the disease—that is, the nucleus basalis, which projects to the hippocampus and to other structures—the locus ceruleus, for instance.

We have found that primarily cholinergic neurons are involved, and, therefore, all of the experimental treatments are oriented to cholinergic approaches.

There are abnormal peptides that are being discovered. The PET scan is an early diagnostic test for Alzheimer's. In addition to that, we find that there is a protein that has been isolated by Peter Davies called Alz-50, which, in preliminary studies, seems to be present in the spinal fluid of Alzheimer's patients and not in the spinal fluid of other patients.

Now, that leads us to the question of the chromosome 21. If you live to be 40 years of age and you have Down's, you will get Alzheimer's disease. Alzheimer's disease in Down's is diagnostically difficult clinically, but pathologically, it is indistinguishable.

It is amazing that you can tell if a Down's patient is demented. Even though they are initially starting at very low levels, there is clinical evidence that they have dementia.

—LESLIE P. WEINER, MD

Extracted from *Audio-Digest Family Practice,* Vol. 35, No. 40, in the Audio-Digest Foundation's series of tape-recorded programs. For subscription information: 1577 E Chevy Chase Dr, Glendale, CA 91206