JNS

LABORATORY INVESTIGATION

A new classification of parasagittal bridging veins based on their configurations and drainage routes pertinent to interhemispheric approaches: a surgical anatomical study

***Derya Karatas, MD,[1] Jaime L. Martínez Santos, MD,[2] Saygı Uygur, MD,[1] Ahmet Dagtekin, MD,[1] Zeliha Kurtoglu Olgunus, MD,[3] Emel Avci, MD,[1] and Mustafa K. Baskaya, MD[2]**

Departments of [1]Neurosurgery and [3]Anatomy, Mersin University School of Medicine, Mersin, Turkey; and [2]Department of Neurological Surgery, University of Wisconsin School of Medicine & Public Health, Madison, Wisconsin

OBJECTIVE Opening the roof of the interhemispheric microsurgical corridor to access various neurooncological or neurovascular lesions can be demanding because of the multiple bridging veins that drain into the sinus with their highly variable, location-specific anatomy. The objective of this study was to propose a new classification system for these parasagittal bridging veins, which are herein described as being arranged in 3 configurations with 4 drainage routes.

METHODS Twenty adult cadaveric heads (40 hemispheres) were examined. From this examination, the authors describe 3 types of configurations of the parasagittal bridging veins relative to specific anatomical landmarks (coronal suture, postcentral sulcus) and their drainage routes into the superior sagittal sinus, convexity dura, lacunae, and falx. They also quantify the relative incidence and extension of these anatomical variations and provide several preoperative, postoperative, and microneurosurgical clinical case study examples.

RESULTS The authors describe 3 anatomical configurations for venous drainage, which improves on the 2 types that have been previously described. In type 1, a single vein joins; in type 2, 2 or more contiguous veins join; and in type 3, a venous complex joins at the same point. Anterior to the coronal suture, the most common configuration was type 1 dural drainage, occurring in 57% of hemispheres. Between the coronal suture and the postcentral sulcus, most veins (including 73% of superior anastomotic veins of Trolard) drain first into a venous lacuna, which are larger and more numerous in this region. Posterior to the postcentral sulcus, the most common drainage route was through the falx.

CONCLUSIONS The authors propose a systematic classification for the parasagittal venous network. Using anatomical landmarks, they define 3 venous configurations and 4 drainage routes. Analysis of these configurations with respect to surgical routes indicates 2 highly risky interhemispheric surgical fissure routes. The risks are attributable to the presence of large lacunae that receive multiple veins (type 2) or venous complex (type 3) configurations that negatively impact a surgeon's working space and degree of movement and thus are predisposed to inadvertent avulsions, bleeding, and venous thrombosis.

https://thejns.org/doi/abs/10.3171/2023.4.JNS222866

KEYWORDS anatomy; bridging veins; interhemispheric approach; microsurgery; superior cerebral veins; venous lacunae; surgical technique

The interhemispheric surgical corridor is the gateway to a wide gamut of neurosurgical pathologies. These include distal anterior communicating artery aneurysms, arteriovenous malformations, cavernomas, tumors of the falx, tumors involving the medial surface of the brain, intraventricular tumors requiring transcallosal approaches, and many others. A strategic arachnoid dissection detaches the cerebral cortex from the falx and from parasagittal venous tributaries to the superior sagittal sinus (SSS), which allows that hemisphere to fall out of the way. The parasagittal venous anatomy and drainage routes are highly variable between individuals, between hemispheres, in anterior-to-posterior parasagittal locations, and in the presence of an oncological or vascular pathology. The parasagittal bridging veins can drain into the SSS directly or indirectly by first draining into a venous lacuna

ABBREVIATIONS SSS = superior sagittal sinus.

SUBMITTED January 3, 2023. **ACCEPTED** April 17, 2023.
INCLUDE WHEN CITING Published online June 2, 2023; DOI: 10.3171/2023.4.JNS222866.

* D.K. and J.L.M.S. contributed equally to this work.

©AANS 2023, except where prohibited by US copyright law

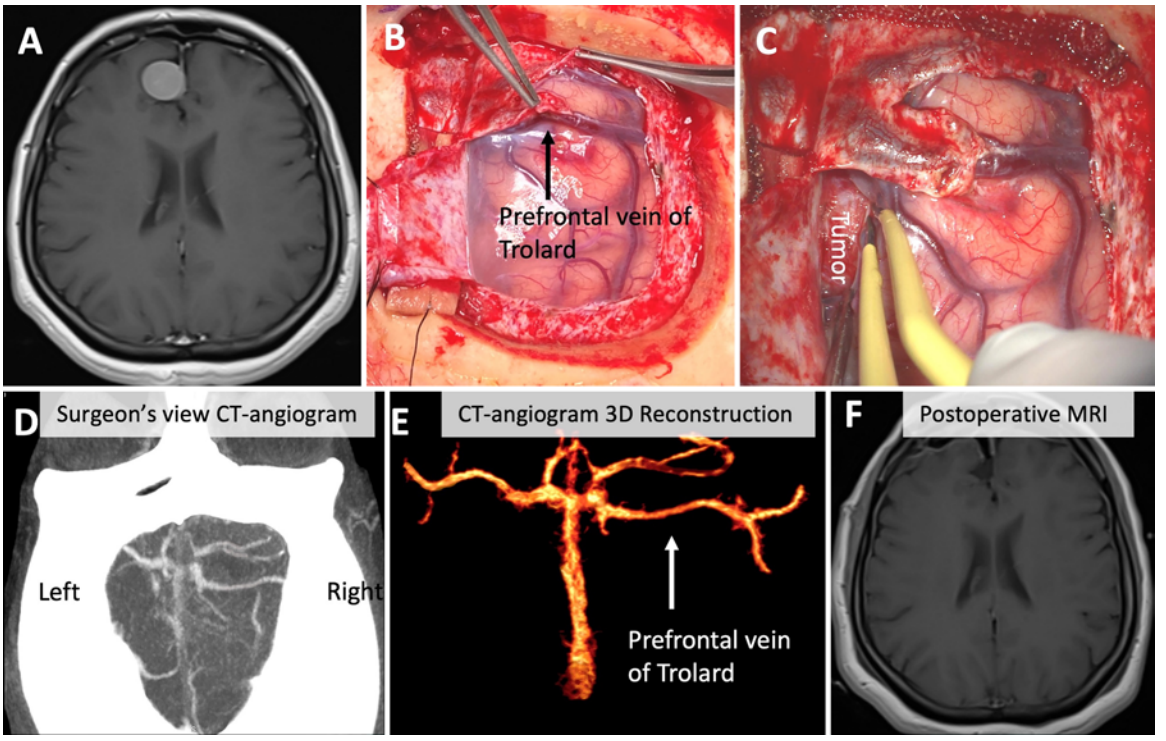

FIG. 1. Type 2 case example in a 45-year-old female. Preoperative postcontrast MR image showing a right frontal falcine meningioma (**A**). A right frontal central craniotomy crossing the midline was performed to expose the SSS. Type 2 drainage is identified upon opening the dura, involving a prefrontal superior anastomotic vein of Trolard indirectly draining into the sinus by first coursing through the convexity dura anterior to the coronal suture (**B**). The dura is cut parallel to the 2 draining veins, and the underlying arachnoid tethering is dissected to better mobilize the veins anteriorly. An interhemispheric approach is then performed posterior to the veins for tumor resection (**C**). Preoperative CT angiogram (**D**) and 3D reconstruction (**E**) demonstrate this venous configuration. Postoperative postcontrast MR image shows gross-total resection (**F**).

or by coursing through the dura over the convexity lateral to the SSS or the dura of the falx inferior to the SSS. The patient-specific parasagittal venous anatomy cannot always be elucidated using preoperative imaging and, therefore, is oftentimes defined intraoperatively. This greatly influences the operative strategy for developing effective interhemispheric microsurgical corridors that maximize exposure and the angles of attack.[1–3]

Despite the attempts of many authors at classifying and conceptualizing the anatomy and drainage routes of parasagittal venous structures, including bridging veins and venous lacunae,[1,4–11] there is still no anatomical classification consensus. In this study, our objective was first to understand all the possible configurations and drainage routes of parasagittal bridging veins and then to define the more frequent configurations and routes both anterior and posterior to the coronal suture. These findings are intended to provide guidelines for deciphering the highly variable patient-specific venous anatomy and, ultimately, to help develop safe and efficient interhemispheric approaches.

Methods

Twenty formalin-fixed adult human cadaveric heads (40 hemispheres) (mean age at death 74 ± 1 years, range 46–92 years; 8 male, 12 female) were injected with colored silicone. Large hemispheric craniotomies were then performed bilaterally. Microsurgical anatomical dissections were performed using a Leica Wild M695 surgical microscope under magnification ×3–×40, and measurements were made with a digital caliper. The following parameters were examined: the number, location (relative to the coronal suture), drainage routes, and configurations of the bridging veins; and the number, size, and location (relative to the coronal suture) of the venous lacunae. In addition, we evaluated how challenging these various parasagittal venous configurations may be with respect to providing safe and adequate interhemispheric microsurgical corridors.

Three clinical cases with different parasagittal venous configurations and their microneurosurgical management are shown as examples (Figs. 1–3). These patients, 1 female and 2 males, were 45, 12, and 41 years of age, respectively. All underwent craniotomies extending across the midline and microneurosurgical interhemispheric fissure dissections. The treated pathologies were a superficial falcine meningioma (Fig. 1) and 2 deep intraventricular lesions, including a quadrigeminal cistern epidermoid cyst (Fig. 2) and a right lateral ventricle cavernoma (Fig. 3). All patients consented to the use of their anonymized images, and this study was approved by the institutional review boards of the hospitals where these images were obtained.

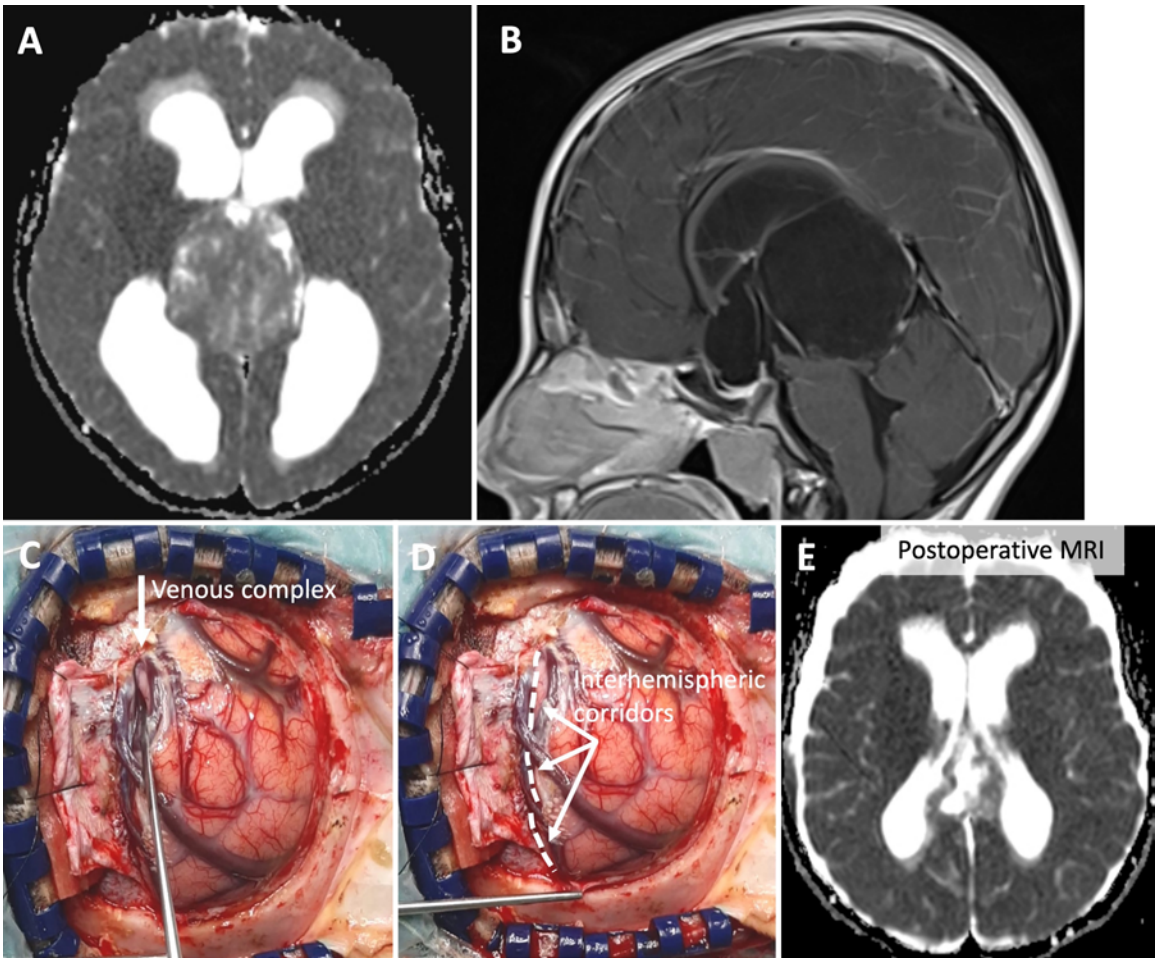

FIG. 2. Type 3 case example in a 12-year-old male. Preoperative axial diffusion-weighted image (**A**) and postcontrast sagittal MR image (**B**) showing a sizable epidermoid tumor of the quadrigeminal cistern. A right parietal craniotomy crossing the midline SSS with an interhemispheric approach was performed after placement of an external ventricular drain (**C**). Upon opening the dura, a type 3 venous complex configuration draining into the SSS posterior to the coronal suture was identified. Individual draining veins were skeletonized, and an interhemispheric corridor was developed for microsurgical tumor resection (**D and E**).

Results

Morphology and Morphometry of the Venous Lacunae

Venous lacunae (lateral lakes of Trolard) are dura-layered lateral extensions of the SSS (Fig. 4A). These lacunae merge with the SSS via a large opening (especially in the elderly) or via single or multiple small slit-like openings. In general, most venous lacunae are located between the coronal and lambdoid sutures. Venous lacunae were found anterior to the postcentral sulcus in 95% of the specimens. In 20% of the specimens, these large lacunae extended anterior to the coronal suture, with the largest lacunae located near the central sulcus. Lacunae extended as far as 34 mm lateral to the midline and were spread over the precentral, central, and postcentral gyri. Their mean length was 5.2 cm on the right side and 5 cm on the left side, and their mean widths were 1.5 cm on the right and 1.7 cm on the left. In this study, all lacunae connected to the SSS via multiple (> 2) small slit-like openings. Twenty percent of specimens had lacunae anterior to the coronal suture, and interestingly, we found no venous lacuna posterior to the lambdoid suture in any of the specimens. Five percent of specimens had no venous lacuna.

Bridging Vein Configurations and Drainage Routes

We identified 3 types of parasagittal bridging vein configurations: a single vein (type 1), 2 or more contiguous veins (type 2), or venous complexes (type 3; Fig. 4B). These configurations have 4 different routes prior to draining into the SSS, as diagrammed in Fig. 5 using cadaveric photographs, drawings, and CT reconstructions. These included direct drainage into the SSS (Fig. 5A–I), indirect drainage by first coursing within the convexity dura (Fig. 5J–O), indirect drainage by first coursing within venous lacunae (Fig. 5P–U), and indirect drainage by first coursing within the falx (Fig. 6).

Venous complexes consisting of more than 2 bridging veins joined to form an arboriform-shaped trunk that drains 2 or more cerebral gyri (Fig. 4B). Venous complexes were more commonly found posterior to the coronal suture. This configuration was absent anterior to the coronal

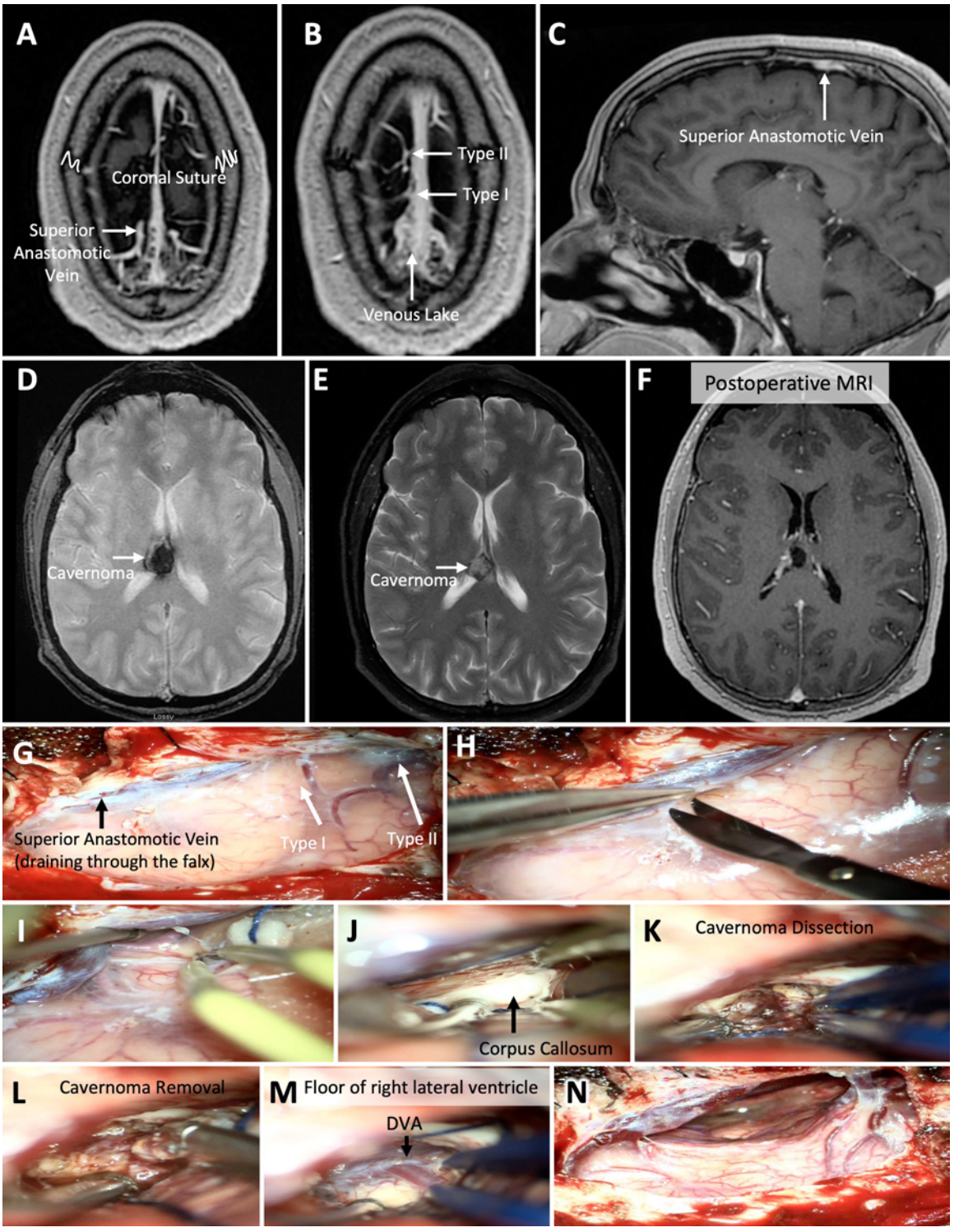

FIG. 3. Type 1 and 2 case examples in a 41-year-old male. Preoperative postcontrast axial (**A and B**) and sagittal (**C**) T1-weighted MR images showing type 1 (I) and 2 (II) venous configurations posterior to the coronal suture (*squiggly lines*), with a large venous lake and a large superior anastomotic vein of Trolard draining into the SSS indirectly through the falx. Preoperative gradient echo (**D**) and T2-weighted (**E**) sequences show a cavernous malformation in the right lateral ventricle attached to the forniceal commissure and undersurface of the corpus callosum. Postoperative postcontrast T1-weighted MR image (**F**) shows complete resection of the cavernous malformation after a parietal central craniotomy and interhemispheric approach. Intraoperative photographs show a stepwise interhemispheric approach for resection of a right lateral ventricle cavernous malformation in the setting of a challenging superior anastomotic vein draining into the SSS by first traveling through the falx (**G**) with type 1 and 2 venous configurations in proximity, making up for an initially very narrow surgical corridor. The arachnoid is first sharply (**H**) and bluntly (**I**) dissected to untether the right cerebral hemisphere so that gravity maintains the interhemispheric fissure open with the aid of small cotton patties. The cingulate gyri are detached, and the pericallosal arteries are mobilized, laterally exposing the corpus callosum (**J**). **FIG. 3.** (*continued*)→

FIG. 3. A 1-cm-long callosotomy is made with bipolar cautery, and the cavernous malformation is exposed at the undersurface of the corpus callosum. The cavernous malformation is then dissected off the fornix and ventricular wall (**K**) and removed with a microrongeur (**L**) while preserving a developmental venous anomaly (DVA) draining into the thalamostriate vein laterally (**M**). A final view (**N**) shows the expanded interhemispheric corridor after strategically dissecting the arachnoid, draining CSF, and relaxing the brain. No continuous brain retraction was utilized.

suture in 15% of the specimens and was seen posterior to the postcentral sulcus in 10% of specimens.

All possible combinations of bridging vein types and drainage routes toward the SSS were studied (Table 1). The most common was type 1 (single vein) that drained directly into the SSS, comprising 23.5% of all bridging veins. The type 1 (single vein) that drained into a lacuna comprised 18.5% of all bridging veins, and the type 1 (single vein) that coursed through the convexity dura comprised 11.8%. The least common drainage routes were type 2 (with 2 contiguous veins) that drained into a lacuna and type 3 (venous complex) that coursed through the falx, which was present in 3.6% of all bridging veins. None of the specimens had a type 2 configuration that drained into the falx.

Characteristics of Bridging Veins Anterior to the Coronal Suture

Anterior to the coronal suture, all specimens had bridging veins coursing through the convexity dura, either bilaterally in 92.5% or unilaterally in 7.5%. The type 1 (single vein) dural drainage route (Fig. 5A–C) was the most common, present in 57% of all hemispheres anterior to the coronal suture. This was followed by type 2 (multiple contiguous veins), found in 28.6% of specimens, and type 3 (venous complexes), found in 21.4%. The average distance between the midline and the entry point of the bridging veins into the convexity dura was 12 mm (range 3–19.6 mm) on the right side and 12.4 mm (range 2.5–21 mm) on the left side.

A prefrontal anastomotic vein of Trolard with a diameter greater than 2 mm, which by definition connects the SSS with the superficial middle cerebral vein (sylvian system), was observed bilaterally in 20% of specimens and unilaterally in 60% (Figs. 5A–C and 7A). The average diameter of the prefrontal anastomotic veins was 2.7 mm.

None of the specimens had bridging veins coursing into the falx anterior to the coronal suture. Here, 80% of the specimens had antegrade (anterior to posterior) or perpendicular (straight angle) drainage into the SSS, whereas 20% had retrograde (posterior to anterior) drainage.

Case Illustration of Bridging Veins Anterior to the Coronal Suture

Figure 1 shows a case example of a type 2 drainage configuration involving a prefrontal superior anastomotic vein of Trolard, indirectly draining into the sinus by first coursing through the convexity dura anterior to the coronal suture. The microneurosurgical strategy to reach this right falcine meningioma (Fig. 1A) was first to identify the dural course of the veins and to cut the dura parallel

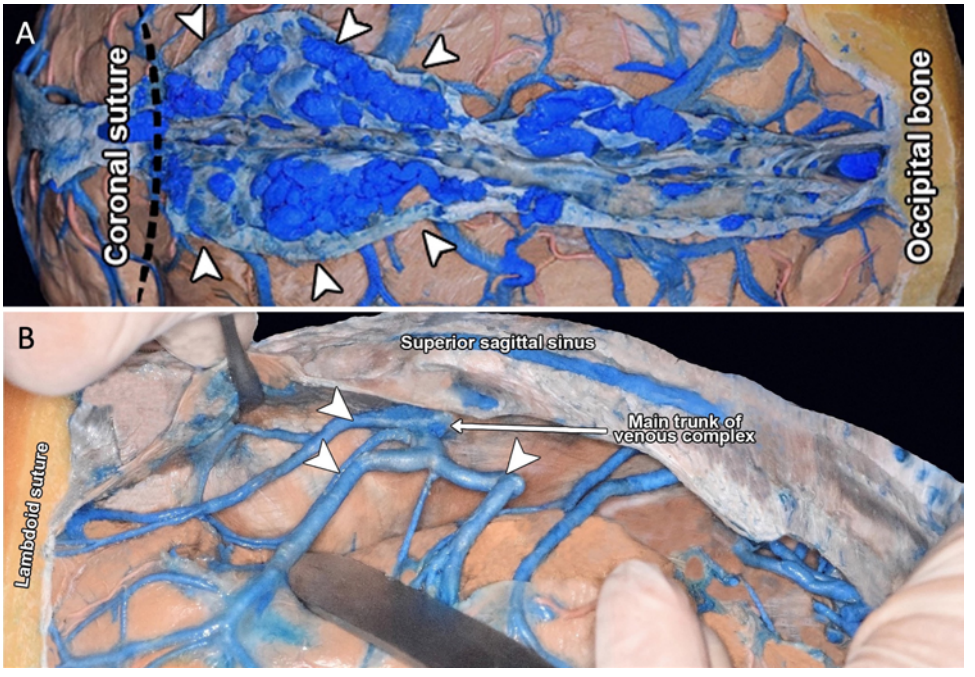

FIG. 4. A: The SSS after bilateral hemispheric craniotomy and removal of blue silicone within the SSS. Note the large bilateral lacunae (*arrowheads*). *Dashed line* indicates the location of the coronal suture. **B:** Right lateral interhemispheric view of cadaveric dissection shows a venous complex draining into the SSS. Note that more than 2 veins (*arrowheads*) join to form a large main-trunk venous complex. © Mustafa Baskaya, published with permission.

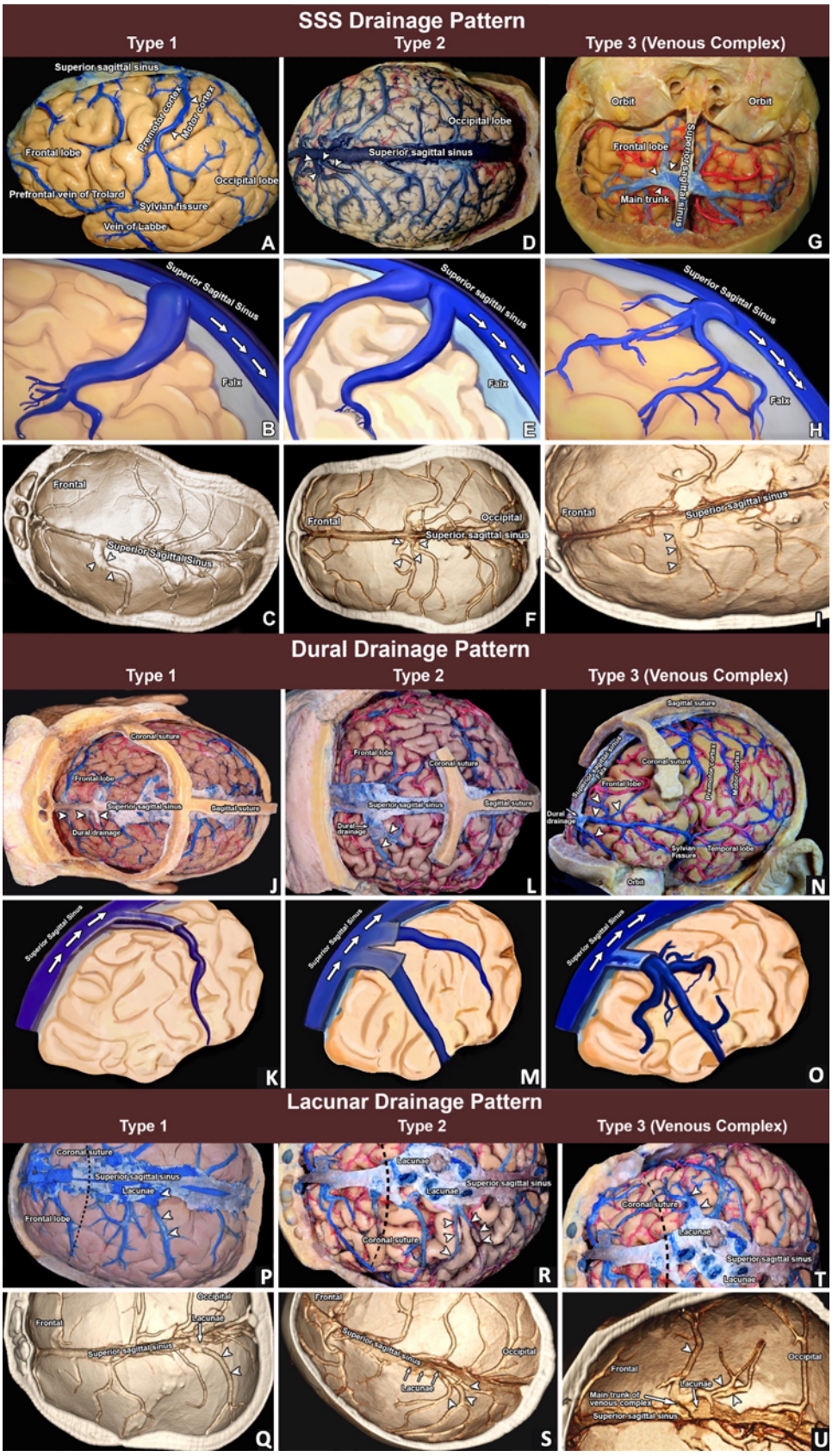

FIG. 5. Classification of parasagittal bridging veins. SSS drainage routes (A–I). Cadaveric specimen (**A**) showing a single vein emptying into the SSS (*arrowheads*, type 1). Note the prefrontal vein of Trolard. Illustration (**B**) showing type 1 configuration with flow direction of the SSS (*arrows*). CT reconstruction (**C**) showing a type 1 single prefrontal vein of Trolard (*arrowheads*) draining into the SSS. Cadaveric specimen (**D**) showing multiple veins emptying into the SSS at the same point on the left side (*arrowheads*, type 2). Illustration (**E**) showing type 2 configuration with flow direction of the SSS (*arrows*). CT reconstruction (**F**) showing a type 2 configuration with 2 contiguous bridging veins (*arrowheads*) draining into the SSS. Left side of a cadaveric specimen (**G**) showing a venous complex emptying at the same point (*arrowheads*, type 3). Illustration (**H**) showing a type 3 configuration with flow direction of the SSS (*arrows*). CT reconstruction (**I**) showing a prefrontal type 3 venous complex configuration (*arrowheads*). Dural drainage routes (J–O). Cadaveric specimen (**J**) showing a single vein coursing to the dura mater on the left hemispheric surface (*arrowheads*, type 1). Illustration (**K**) of a single-vein course into the dura with flow direction of the SSS (*arrows*). Cadaveric specimen (**L**) and illustration (**M**) showing multiple veins coursing to the dura mater at the same point (*arrowheads*, type 2. *Arrows* indicate flow direction of the SSS. Cadaveric left interhemispheric view (**N**) and illustration (**O**) showing a venous complex (*arrowheads*, type 3) coursing to the dura mater at the same point. *Arrows* indicate flow direction of the SSS. Lacunar drainage routes (P–U). Cadaveric dissection on the left hemisphere (**P**) and CT reconstruction (**Q**) showing a single vein joining into lacunae (*arrowheads*, type 1). Cadaveric dissection on the left hemisphere (**R**) and CT reconstruction (**S**) showing multiple veins joining into lacunae at the same point (*arrowheads*, type 2). Cadaveric dissection of the left hemisphere (**T**) and CT reconstruction (**U**) showing a lacunar drainage route with a venous complex emptying at the same point (*arrowheads*, type 3). © Mustafa Baskaya, published with permission.

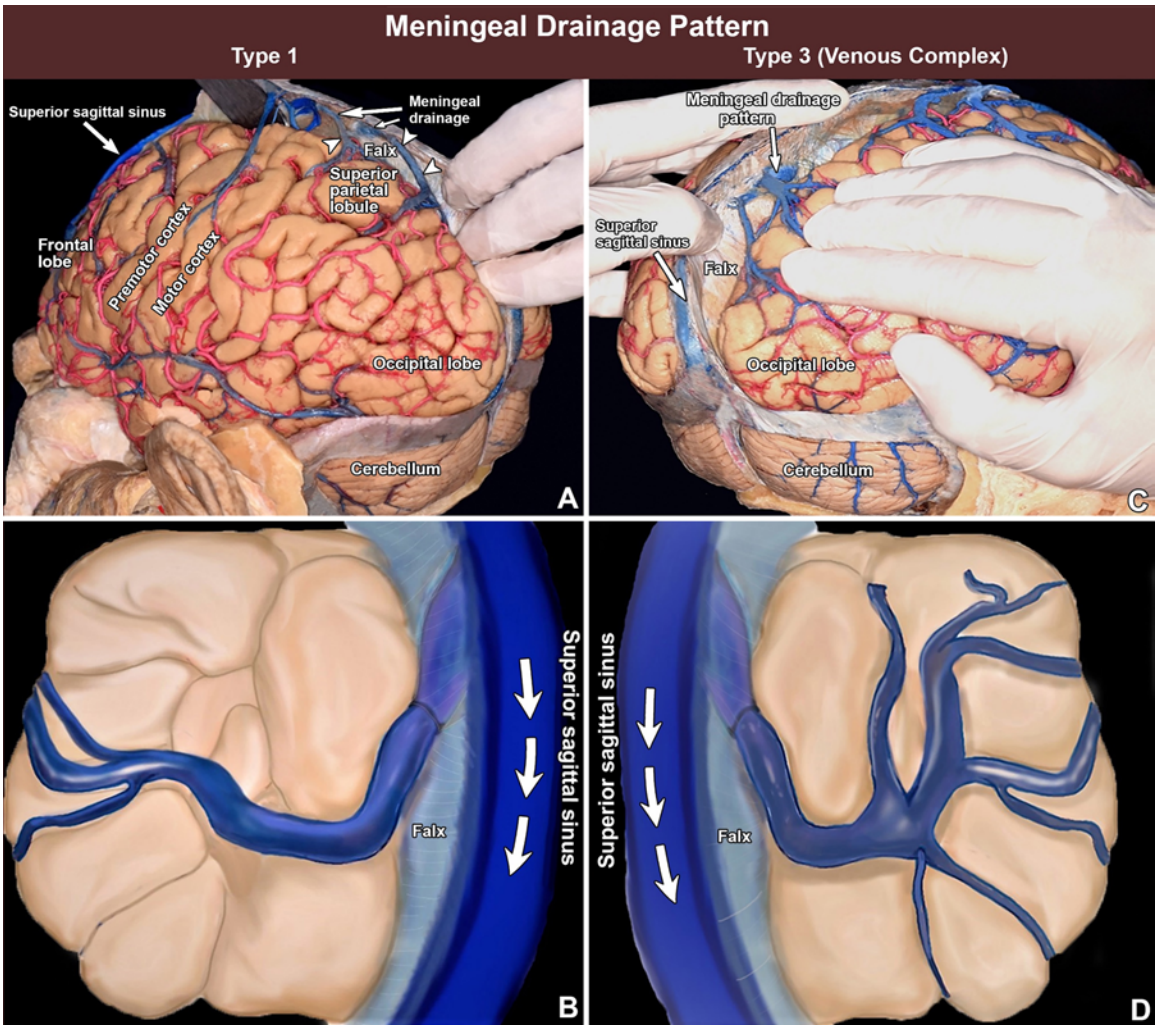

FIG. 6. Meningeal drainage routes. Cadaveric dissection of the left hemisphere (**A**) showing a single vein joining into the falx (*arrowheads*, type 1). Illustration (**B**) showing a single vein joining into the falx with a retrograde direction (*arrows*). Cadaveric dissection (**C**, type 3) showing a venous complex draining into the cerebral falx at the same point. Illustration (**D**) of multiple veins draining into the falx with a retrograde direction at the same point (*arrows*). © Mustafa Baskaya, published with permission.

to the veins (Fig. 1B). Next, the veins were freed from the cerebral cortex further laterally by dissecting the arachnoid. Last, the veins were mobilized anteriorly, and an interhemispheric corridor was developed posterior to the veins (Fig. 1C).

Characteristics of Bridging Veins Posterior to the Coronal Suture

Between the coronal suture and the postcentral sulcus, the most common bridging vein drainage route was through a lacuna. The largest bridging veins and lacunae were found in this region.

The largest bridging vein in this region was the superior anastomotic vein of Trolard, which was observed in 80% of specimens, with the remaining 20% having a large bridging vein that did not connect with the sylvian system. Unilateral double anastomotic veins of Trolard (connecting with the sylvian system) were found in 15% of all hemispheres (Fig. 7B). On the right side, the vein of Trolard was found in the precentral sulcus in 30% of specimens, in the central sulcus in 30%, and in the postcentral sulcus in 40%. On the left side, the vein of Trolard was located in the precentral sulcus in 59% of specimens and in the postcentral sulcus in 41% of specimens. The average diameter of the vein of Trolard was 4.4 mm on the right side and 3.8 mm on the left. The most common drainage configuration for the vein of Trolard, found in 73% of specimens, was type 1 (single vein) with draining into a venous lacuna.

Posterior to the postcentral sulcus, most bridging veins coursed through the falx (Fig. 7) with a falx drainage route only seen in this location. Interestingly, in this region, the bridging veins had a long retrograde (posterior to anterior) course toward the SSS within the interhemispheric fissure (Fig. 7B and D). Posterior to the postcentral sulcus, none of the specimens had bridging veins coursing through the convexity dura.

TABLE 1. Classification of parasagittal bridge veins based on drainage routes and configurations

Configuration Type	Drainage Routes	Common Locations	Prevalence Among Hemispheres
1, a single vein	Directly into SSS	Pst to coronal suture in 54%	43% pst to coronal suture, 28.6% ant, 14.2% both, & 14.2% none
	Coursing through convexity dura	Ant to coronal suture in 88.5%	57% of all hemispheres ant to coronal suture, 42% none
	Draining into lacunae	Pst to coronal suture in 83%	57% pst to coronal suture, 3.6% ant, 10.7% both, & 28.7% none
	Coursing through falx	Pst to postcentral sulcus totally	50% pst to postcentral sulcus & 50% none
2, multiple contiguous veins	Directly into SSS	Ant to coronal suture in 70%	17.9% ant to coronal suture, 3.6% pst, & 78.5% none
	Coursing through convexity dura	Ant to coronal suture in 82%	28.6% ant to coronal suture, 7.1% both, & 64.3% none
	Draining into lacunae	Pst to coronal suture in 62.5%	10.8% ant to coronal suture, 7.1% pst, 7.1% both, & 75% none
	Coursing through falx	None	None
3, venous complexes	Directly into SSS	Pst to coronal suture in 59%	28.6% pst to coronal suture, 14.3% ant, 3.4% both, & 53.7% none
	Coursing through convexity dura	Ant to coronal suture totally	21.4% ant to coronal suture & 78.6% none
	Draining into lacunae	Pst to coronal suture in 82.6%	46.4% pst to coronal suture, 7.2% both, & 46.4% none
	Coursing through falx	Pst to postcentral sulcus totally	14.3% pst to postcentral sulcus, 85.7% none

ant = anterior; pst = posterior.

Case Illustrations of Bridging Veins Posterior to the Coronal Suture

The second case example (Fig. 2) shows a type 3 venous complex configuration draining into the SSS posterior to the coronal suture. The microneurosurgical strategy to reach this deep quadrigeminal cistern epidermoid cyst was to meticulously dissect the arachnoid around each individual superior cerebral vein and skeletonize them to develop 3 alternative corridors in between the veins and between the veins and the falx (Fig. 2D). We ultimately selected the more anterior corridor for a more direct course to the lesion based on navigation. The interhemispheric fissure was opened, and the cyst was removed without difficulty.

The third case example (Fig. 3) shows a challenging superior anastomotic vein draining into the SSS by first traveling through the falx (Fig. 3G) with type 1 and 2 venous configurations in proximity (Fig. 3B), making up for an initially very narrow surgical corridor. The microneurosurgical strategy to reach this deep right intraventricular cavernoma was to meticulously dissect the arachnoid, skeletonize the veins, and then de-tether the cerebral cortex from the larger draining vein going into the falx (Fig. 3H and I). This allowed us to develop an interhemispheric surgical corridor posterior to the type 1 and 2 venous configurations while medially retracting the dura and the falx along with the large superior anastomotic vein draining into it (Fig. 3J–N). The callosal cistern was reached and CSF was drained for brain relaxation. These maneuvers helped the right cerebral hemisphere to fall with gravity. We then kept the interhemispheric fissure open with cotton patties. Note that no fixed retractors were used in any of the cases. A 1-cm callosotomy was made, additional CSF was drained, and the cavernoma was dissected circumferentially and removed (Fig. 3K–N).

Challenging Parasagittal Venous Configurations

Creating an interhemispheric microsurgical corridor can be challenging in the regions where multiple bridging veins drain into the sinus in close proximity (Figs. 4, 5E, and 7C) and where there are very large lacunae that receive multiple (type 2) or complex (type 3) arrangements of bridging veins (Figs. 5T and 7D). These venous configurations limit the surgeon's working space, angles, and freedom of movement, thus risking inadvertent avulsions, bleeding, and venous thrombosis. The area overlying the cerebral central sulcus (of Rolando) is particularly challenging because veins here drain the highly eloquent sensorimotor cortex and at the same time have variable and complex arrangements and drainage routes. Whenever possible, the surgeon should attempt to create surgical corridors anterior to this high-stakes area.

Discussion

Human venous anatomy is known to be highly variable, especially the superficial venous drainage systems of the brain. Preoperative neuroimaging including CT venography, MRI, MR venography, and catheter angiographies can help to elucidate gross details of some of an individual's venous anatomy, principally the SSS, the large superior and inferior anastomotic veins (Trolard and Labbé, respectively), and larger bridging veins. However, the location and drainage routes of smaller parasagittal bridging veins can only be accurately ascertained intraoperatively. The patient-specific parasagittal venous anatomy would greatly influence the strategy and access points for developing effective interhemispheric microsurgical corridors and maximize the angles of attack. There has been considerable recent interest in the anatomical configurations, drainage routes, and variations of parasagittal bridging veins.[6,12–14] Sampei et al. studied the anterior frontal cortical veins and their drainage routes into the SSS.[15] These authors defined 2 types of bridging veins: a single trunk draining into the SSS (type 1) and multiple (> 2) trunks draining into the SSS at the same point (type 2) that sometimes formed a "bulge" (venous pouch) on the SSS side wall. In our study, we identified another type of bridging vein configuration: type 3, the venous complex. We also defined 4 possible drainage routes into the SSS: 1) direct-

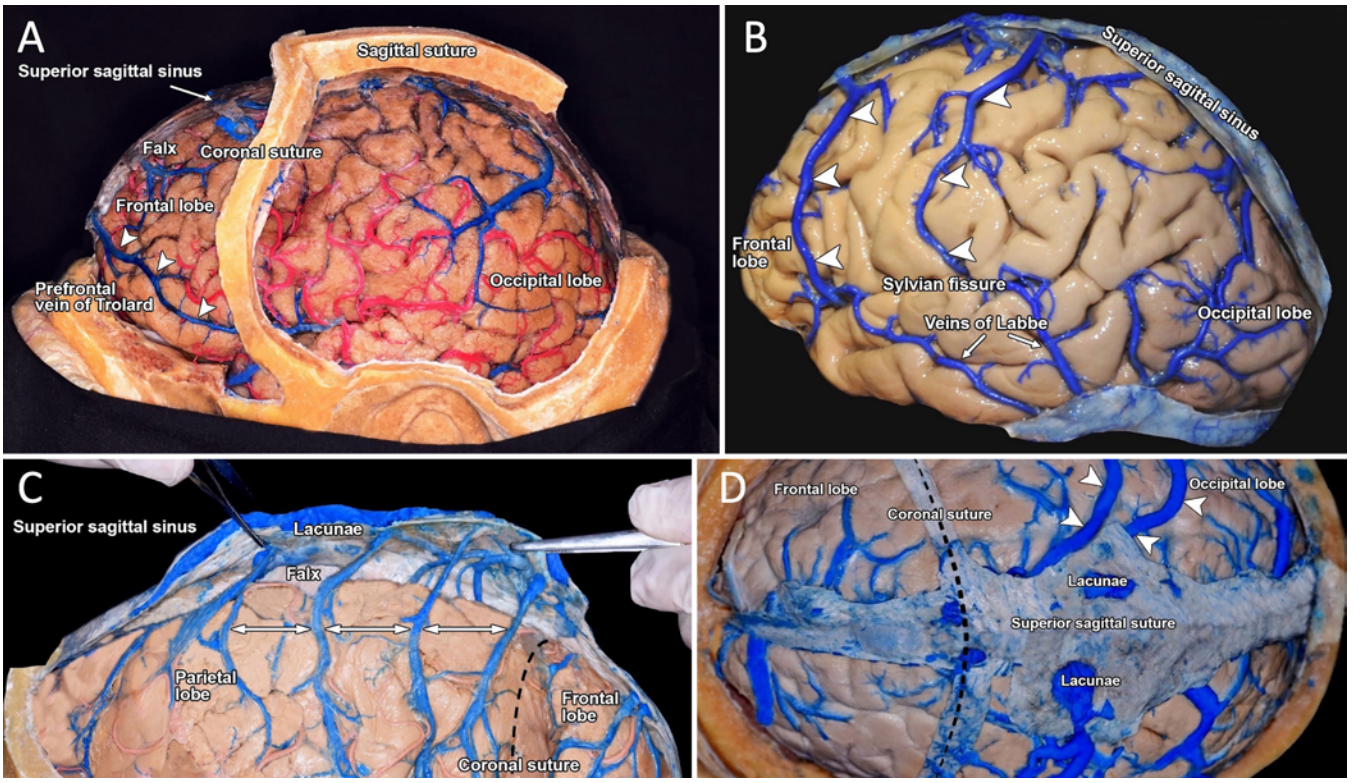

FIG. 7. *Arrowheads* (**A**) indicate the prefrontal vein of Trolard on the cadaveric left side. Double anastomoses of the vein of Trolard (*arrowheads*, **B**) with the sylvian system consisting of the prefrontal vein of Trolard anteriorly and the superior anastomotic vein posteriorly on the cadaveric left side. The cadaveric right side shows lacunae with consecutive large venous alignments (**C and D**). Note the narrow gaps (*double-sided arrows*, C) measured as 11, 27, and 18 mm from anterior to posterior, which restrict surgical corridors for interhemispheric approaches. Location of the coronal suture is indicated by a *dashed line* (D). Cadaver with wide lacunae and type 2 drainage route (*arrowheads*, D). © Mustafa Baskaya, published with permission.

ly into the SSS, 2) indirectly through the convexity dura, 3) indirectly through a venous lacuna, and 4) indirectly through the falx. In our classification, type 1 consists of a single bridging vein, type 2 consists of multiple (2 or more) veins draining contiguously, and type 3 (venous complex) consists of more than 2 bridging veins joining to form an arboriform-shaped trunk that drains venous blood from 2 or more cerebral gyri (Fig. 4B). Type 3 configurations must be identified and safeguarded intraoperatively, as injury or sacrifice could result in neurological sequelae, especially since we found that these configurations are commonly located adjacent to highly eloquent cerebral cortices such as sensorimotor cortices.

Another important finding of the present study is that the configurations and drainage routes of the bridging veins were consistently different depending on their location in relation to the coronal suture.

Interhemispheric Approaches Anterior to the Coronal Suture

This region is the most favorable for interhemispheric approaches for several reasons. First, there is a paucity of venous lacunae. Eighty percent of our specimens had no venous lacunae anterior to the coronal suture, and the remaining 20% had only very small lacunae in this location. Second, the most common type of bridging vein was type 1 (single vein) coursing through the convexity dura prior to entering the SSS. And third, the adjacent prefrontal cerebral cortices are less eloquent. When devoid of an associated venous lacuna, individual (type 1) and sometimes even groups of multiple veins (type 2) or trunks (type 3) can be mobilized either by dissecting the vein sharply from the dura or by cutting the dura parallel to the vein (Fig. 1B). Prior to dissecting the vein off the dura, the individual tributaries and their drainage territory must be first identified. Smaller anterior frontal branches can be sacrificed when these are absolutely in the way, whereas larger veins draining more posterior areas should always be preserved. The entry point to the convexity dura of the bridging veins anterior to the coronal suture was maximally 21 mm from the midline (12 mm on average). Therefore, when performing interhemispheric approaches in this region, we recommend opening the dura more than 2 cm lateral to the midline, while doing so under the operative microscope for optimal illumination and magnification.

Brockmann et al. reported that an antegrade (anterior to posterior) inflow direction was observed 3 cm anterior to the coronal suture in 71% of cases.[12,13] We had similar findings, noting that in the majority (80%) of specimens, all bridging veins anterior to the coronal suture had an antegrade or perpendicular trajectory to the SSS. This

can also be considered another favorable finding for veins in this region because this allows for the development of anterior-to-posterior interhemispheric corridors toward lesions located under and even posterior to the coronal suture, where interhemispheric dissection is more challenging, as we discuss in the next section.

Sindou and Auque reported that larger superficial veins play functional roles since they represent a major supply network.[2] Di Chiro examined the angiographic patterns of the convexity veins and found that the vein of Trolard was occasionally directed anteriorly toward the frontal lobe from the sylvian system, which was thus called the "prefrontal vein of Trolard."[16] In our study, we found that 60% of specimens had a unilateral and 20% of specimens had a bilateral superior anastomotic vein anterior to the coronal suture (prefrontal vein of Trolard; Figs. 5A, 5N, and 7A). This vein entered the convexity dura (in 47%), the SSS (in 29%), or the lacunae (in 24%) individually, which should be accounted for during dissection and preservation.

Interhemispheric Approaches Posterior to the Coronal Suture

Interhemispheric approaches between the coronal and the lambdoid sutures are higher risk owing to the higher density of parasagittal venous structures and the eloquence of surrounding brain. Here, the venous lacunae are larger and more numerous, and the bridging veins that drain into either these lacunae or the SSS tend to have more complex (type 3) drainage configurations. It has been proposed that lacunae do not directly receive bridging veins,[17] and there are some limited anatomical studies demonstrating this.[18–20] In the present study, however, we showed that all 3 types of bridging vein configurations drain into parasagittal venous lacunae (Figs. 5P–U, 7C, and 7D). Additionally, the (single) superior anastomotic vein or the (multiple) veins of Trolard are frequently located in this region and drain into a venous lacuna, as found in 73% of all types of Trolard veins.

Venous lacunae were found in 95% of specimens, and in all specimens, they were located anterior to the postcentral sulcus. The maximal lateral extension of venous lacunae was 3.4 cm from the midline, but the average lateral extension was 1.5 cm on the right and 1.7 cm on the left. In these higher-stakes regions, we recommend more generous craniotomies between the coronal and the lambdoid sutures, opening the dura > 3.5 cm from the midline and doing this under the operative microscope. It is of the utmost importance to pay close attention to the bridging veins in this area when cutting the dura and when reflecting the dura medially toward the SSS, as these bridging veins often have more complex (type 2 and 3) configurations. Extra care must be taken to preserve the veins of Trolard, which are usually referred to as the most important parasagittal "venous capital."[2] Complex venous configurations (types 2 and 3) with wide lacunae (Figs. 5R and 7D) and numerous parasagittal venous structures near each other (Figs. 5D, 5P–U, 7C, and 7D) can represent a microsurgical challenge. We called these configurations "highly risky venous alignments." Posterior to the coronal suture, unpredictable complex interconnections and highly variable routing of hidden bridge veins underneath lacunae were also challenging for the release of parasagittal veins. Larger approaches that provide greater freedom of movement and angles of attack, along with early identification and safe skeletonization of individual veins and elucidation of their drainage routes and cortical territories, are helpful strategies for these challenging venous morphologies (Figs. 1–3).

In addition, we found 2 important anatomical findings at the level of the superior parietal lobule (posterior to the postcentral sulcus). First, bridging veins tend to have a longer posterior-to-anterior course within the superficial interhemispheric fissure (Fig. 6), parallel to the SSS. Second, drainage into the falx was seen only in this region. While the longer course of these veins makes brain retraction easier, falx drainage routes might hinder the identification of bridging veins in the presence of a space-occupying mass.

The region underlying the lambdoid suture and posterior to it is another favorable location for creating interhemispheric surgical corridors. We found no lacunae, while venous complexes were observed in only 10% of all specimens here.

Conclusions

In this anatomical study, we added a third classification for parasagittal bridging vein configurations to the 2 previously described types. These are single vein (type 1), multiple contiguous veins (type 2), and venous complexes (type 3). We also described 4 drainage routes into the SSS: direct, dural, lacunar, and falcine. We also reported the most frequent configurations and drainage routes anterior and posterior to the coronal suture along the interhemispheric fissure. The regions anterior to the coronal suture have a more favorable level of surgical accessibility because of their simpler type 1 venous configurations with infrequent lacunae. In contrast, the complex parasagittal venous anatomy under the parietal bone (between the coronal and lambdoid sutures) can pose a challenge to developing sufficiently wide interhemispheric corridors, owing to the higher number and larger sizes of venous lacunae and the presence of more complex type 2 and type 3 configurations.

Acknowledgments

We express our immense gratitude for those who donated their bodies for research. This study would not have been possible without their most respectable and selfless act. We similarly express our gratitude to the patients who have allowed their clinical imaging examples to be included in this work.

This study was supported by the Mersin University scientific research projects coordination unit.

References

1. Frigeri T, Paglioli E, de Oliveira E, Rhoton AL Jr. Microsurgical anatomy of the central lobe. *J Neurosurg*. 2015;122(3): 483-498.
2. Sindou M, Auque J. *The Intracranial Venous System as a Neurosurgeon's Perspective*. Springer-Verlag; 2000:158.
3. Wang S, Ying J, Wei L, Li S, Jing J. Effects of parasagittal meningiomas on intracranial venous circulation assessed by the virtual reality technology. *Int J Clin Exp Med*. 2015;8(8): 12706-12715.

4. Andrews BT, Dujovny M, Mirchandani HG, Ausman JI. Microsurgical anatomy of the venous drainage into the superior sagittal sinus. *Neurosurgery*. 1989;24(4):514-520.
5. Browder J, Browder A, Kaplan HA. The venous sinuses of the cerebral dura mater. I. Anatomical structures within the superior sagittal sinus. *Arch Neurol*. 1972;26(2):175-180.
6. Bruno-Mascarenhas MA, Ramesh VG, Venkatraman S, Mahendran JV, Sundaram S. Microsurgical anatomy of the superior sagittal sinus and draining veins. *Neurol India*. 2017; 65(4):794-800.
7. Harput MV, Gonzalez-Lopez P, Türe U. Three-dimensional reconstruction of the topographical cerebral surface anatomy for presurgical planning with free OsiriX Software. *Neurosurgery*. 2014;10(suppl 3):426-435.
8. İzci Y, Agrawal B, Ateş O, Başkaya MK. Superficial vascular anatomy of the medial prefrontal cortex: an anatomical study. *Surg Neurol*. 2009;72(4):383-388.
9. O'Connell JEA. Some observations on the cerebral veins. *Brain*. 1934;57(4):484-503.
10. Oka K, Rhoton AL Jr, Barry M, Rodriguez R. Microsurgical anatomy of the superficial veins of the cerebrum. *Neurosurgery*. 1985;17(5):711-748.
11. Sargent P. Some points in the anatomy of the intracranial blood-sinuses. *J Anat Physiol*. 1911;45(Pt 2):69-72.
12. Brockmann C, Kunze S, Scharf J. Computed tomographic angiography of the superior sagittal sinus and bridging veins. *Surg Radiol Anat*. 2011;33(2):129-134.
13. Brockmann C, Kunze SC, Schmiedek P, Groden C, Scharf J. Variations of the superior sagittal sinus and bridging veins in human dissections and computed tomography venography. *Clin Imaging*. 2012;36(2):85-89.
14. Sayhan S, Guvencer M, Özer E, Arda MN. Morphometric evaluation of parasagittal venous anatomy for intracranial approaches: a cadaveric study. *Turk Neurosurg*. 2012;22(5): 540-546.
15. Sampei T, Yasui N, Okudera T, Fukasawa H. Anatomic study of anterior frontal cortical bridging veins with special reference to the frontopolar vein. *Neurosurgery*. 1996;38(5):971-975.
16. Di Chiro G. Angiographic patterns of cerebral convexity veins and superficial dural sinuses. *Am J Roentgenol Radium Ther Nucl Med*. 1962;87:308-321.
17. Han H, Tao W, Zhang M. The dural entrance of cerebral bridging veins into the superior sagittal sinus: an anatomical comparison between cadavers and digital subtraction angiography. *Neuroradiology*. 2007;49(2):169-175.
18. Clemente C. *Gray's Anatomy*. 13th ed. Lea & Fiebinger; 1985:809.
19. Tubbs RS, Loukas M, Shoja MM, Apaydin N, Ardalan MR, Oakes WJ. Lateral lakes of Trolard: anatomy, quantitation, and surgical landmarks. Laboratory investigation. *J Neurosurg*. 2008;108(5):1005-1009.
20. Woodburne RT. *Essentials of Human Anatomy*. Oxford University Press; 1978:275.

Disclosures

The authors report no conflict of interest concerning the materials or methods used in this study or the findings specified in this paper.

Author Contributions

Conception and design: Baskaya, Martínez Santos, Avci. Acquisition of data: Uygur, Kurtoglu Olgunus. Analysis and interpretation of data: Karatas, Martínez Santos, Dagtekin, Avci. Drafting the article: Martínez Santos, Uygur, Dagtekin. Critically revising the article: Baskaya, Martínez Santos, Avci. Reviewed submitted version of manuscript: Baskaya, Karatas, Martínez Santos, Kurtoglu Olgunus. Approved the final version of the manuscript on behalf of all authors: Baskaya. Statistical analysis: Karatas, Dagtekin. Administrative/technical/material support: Karatas, Uygur, Dagtekin, Kurtoglu Olgunus. Study supervision: Baskaya, Kurtoglu Olgunus, Avci.

Correspondence

Mustafa K. Baskaya: University of Wisconsin School of Medicine & Public Health, Madison, WI. baskaya@neurosurgery.wisc.edu.