Article published online: 2023-01-13

A Rare Case of Migration of Hyaluronic Acid Gluteal Injection to the Medial Thigh Presenting as a Soft Lump

Ahmed Saad[1] Karthikeyan P. Iyengar[1,2] A. Mark Davies[3] Rajesh Botchu[3]

[1] Department of Orthopedics, Royal Orthopaedic Hospital NHS Foundation Trust, Birmingham, United Kingdom
[2] Deprtment of Orthopedics, Southport and Ormskirk Hospital NHS Trust, Southport, United Kingdom
[3] Department of Musculoskeletal Radiology, University Hospitals of Leicester, Leicester, United Kingdom

Address for correspondence Rajesh Botchu, MBBS, MS(Orth), MRCSEd, FRCR, Department of Musculoskeletal Radiology, Royal Orthopedic Hospital, Bristol Road South, Northfield, Birmingham, United Kingdom (e-mail: drbrajesh@yahoo.com).

Indian J Radiol Imaging 2023;33:253–256.

Abstract

Introduction Hyaluronic acid (HA) is a widely accepted agent most commonly used as a dermal filler in facial aesthetic/cosmetic medicine. More recently, HA has been utilized for gluteal augmentation. The common side effects of HA injection are often minor and self-limiting. HA migration is a very rare complication.

Case Report We describe a rare case of HA buttock injection migration in a transgender patient, appearing as a superficial lump on right thigh representing a diagnostic dilemma. We highlight the need of a clinical suspicion and discuss the appropriate investigations for guided management of such patients.

Conclusion It is essential for reporting radiologist to be aware of the commonly used injectable fillers, their complications, and imaging findings to avoid misdiagnosis and guide optimal patient management.

Keywords
- Hyaluronic acid
- gluteal augmentation
- filler injections
- magnetic resonance imaging

Introduction

Hyaluronic acid (HA) is a widely accepted agent most commonly used as a dermal filler in facial aesthetic/cosmetic medicine.[1,2] Its main benefits include maintaining a youthful appearance, through facial rejuvenation and volume restoration secondary to aging or even post-traumatic facial disfiguration.[1–3] More recently, and as HA products continue to develop, attention has turned to the use of HA for body contouring and more specifically gluteal augmentation.[4] The common side effects of HA injection (HAI) are often minor and self-limiting.[5,6] HA migration is a rare complication, and there is lack of literature about HA migration following gluteal augmentation.

We report a rare case of HA buttock injection (HAI) migration in a transgender patient. The aim is to create awareness among radiologists to allow early detection and management of such unusual radiological imaging findings.

Case Report

A 41-year-old man undergoing gender change to female of South-East Asian ethnicity was referred to our department for an ultrasound scan (USS) following a 6-week history of an unprovoked progressively enlarging palpable painless mass on the medial aspect of her right thigh. She was otherwise asymptomatic, fit, and well, without any significant past medical history. She did, however, mention that she had

article published online
January 13, 2023

DOI https://doi.org/10.1055/s-0042-1760364.
ISSN 0971-3026.

© 2023. Indian Radiological Association. All rights reserved.
This is an open access article published by Thieme under the terms of the Creative Commons Attribution-NonDerivative-NonCommercial-License, permitting copying and reproduction so long as the original work is given appropriate credit. Contents may not be used for commercial purposes, or adapted, remixed, transformed or built upon. (https://creativecommons.org/licenses/by-nc-nd/4.0/)
Thieme Medical and Scientific Publishers Pvt. Ltd., A-12, 2nd Floor, Sector 2, Noida-201301 UP, India

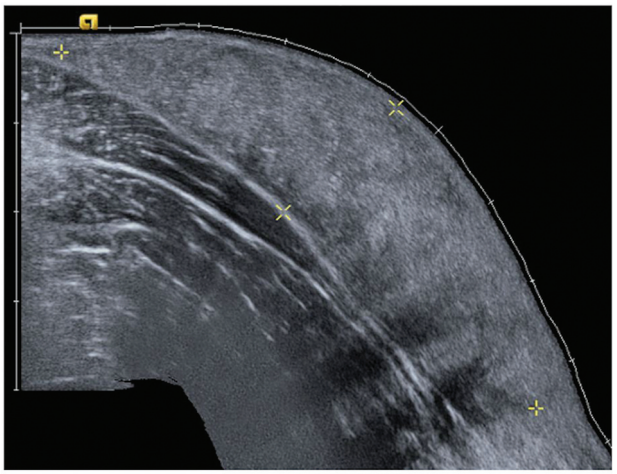

Fig. 1 Ultrasound scan. Longitudinal view of mass in medial right thigh within the subcutaneous compartment and superficial to the deep fascia. The mass is homogeneously isoechoic relative to the surrounding subcutaneous fat. No vascularity was demonstrated on Doppler imaging.

undergone a recent gluteal augmentation procedure as a part of her transgender transition, in a private clinic. The gluteal augmentation was performed using HA gel fillers; however, the patient was not entirely sure about the specific HA agent utilized.

On examination, the patient had a painless fluctuant mass on the medial aspect of her right thigh, with no associated erythema or any other signs suggestive of an infection. The mass was mobile and measured 6.6 by 1.7cm.

The patient had an USS of the mass that demonstrated a subcutaneous homogeneously hyperechoic lesion with no vascularity of Doppler imaging (►**Fig. 1**). The sonographic features were similar to that of fat and hence an initial diagnosis of subcutaneous lipoma was made.

Given the nonspecific findings, a magnetic resonance imaging (MRI) of the pelvis and thigh was performed. On MRI, the mass was found to be continuous with smaller foci of identical signal in the posterior and lateral aspect of the thigh. These lesions demonstrated relatively homogeneous signal that were isointense to slightly hyperintense on T1-weighted and markedly hyperintense on T2-weighted scans, relative to skeletal muscle. The foci of the similar signal intensities were also demonstrated within the subcutaneous tissues of left buttock and gluteus maximus muscle. However, here they appeared nodular and had a feathered pattern (►**Fig. 2**).

The patient was recalled for wide field of view images of the entire pelvis, including axial T2-weighted fat-saturated and coronal short-tau inversion recovery. This confirmed the findings of the prior MRIs. Moreover, these abnormal signal foci were bilateral and largely symmetrical. Again, the subcutaneous nodular pattern and intramuscular feathered pattern were noted. These features were consistent with a diagnosis of migration of the HA gel agent from the buttock onto the medial aspect of right thigh (►**Figs. 3** and **4**).

In the absence of pain, the patient was managed with outpatient monitoring and observation. Reassurance was given.

Discussion

HA is a naturally occurring polysaccharide found distributed within healthy connective tissues across various parts of the body.[3] Its function is to stabilize the extracellular matrix by attracting water and creating volume for extrastructural tissue support. Through this concept, HA gel injection fillers (HAI) have been developed and approved for use in aesthetic medicine. HAI preparations are most commonly used in facial aesthetic practice.[7,8] Common sites include the lips, chin, facial lines, nasolabial, and melolabial folds. HAI of the buttocks is not as common, but gradually increasing in popularity, especially with the increase in transgender transitions.[4]

The side effects of HAI are uncommon, and are often localized, comprising hematoma formation, infection, localized erythema, or allergic reactions. Late complications may include foreign body granulomas, chronic deep infections, and cross-link reactions between different fillers (oedema,

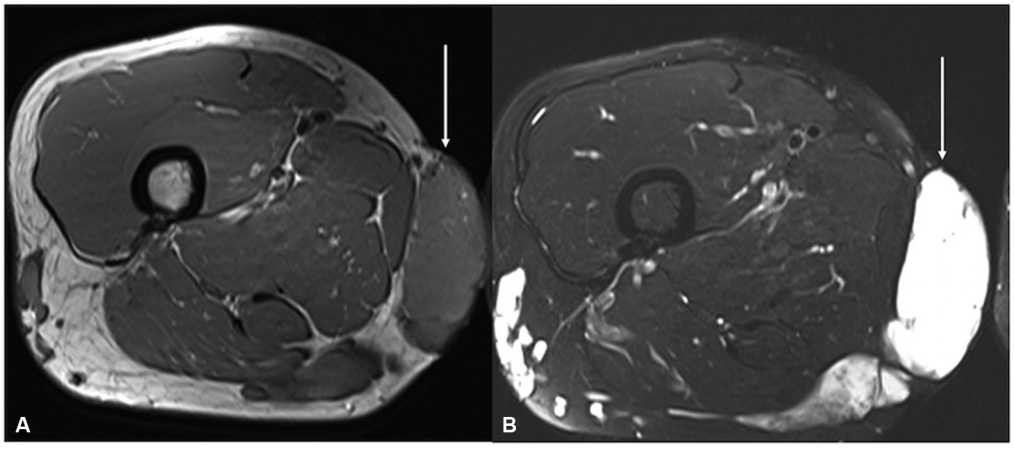

Fig. 2 Axial T1-weighted (**A**) and T2-weighted fat-saturated (**B**) magnetic resonance imagings of the right thigh. On serial axial images, the medial subcutaneous thigh mass (arrow) was shown to be continuous with smaller foci of identical signal in the posterior and lateral thigh. These demonstrated relatively homogeneous signal that was isointense to slightly hyperintense on T1-weighted (**A**) and markedly hyperintense on T2-weighted scans, relative to skeletal muscle.

 © 2023. Indian Radiological Association. All rights reserved.

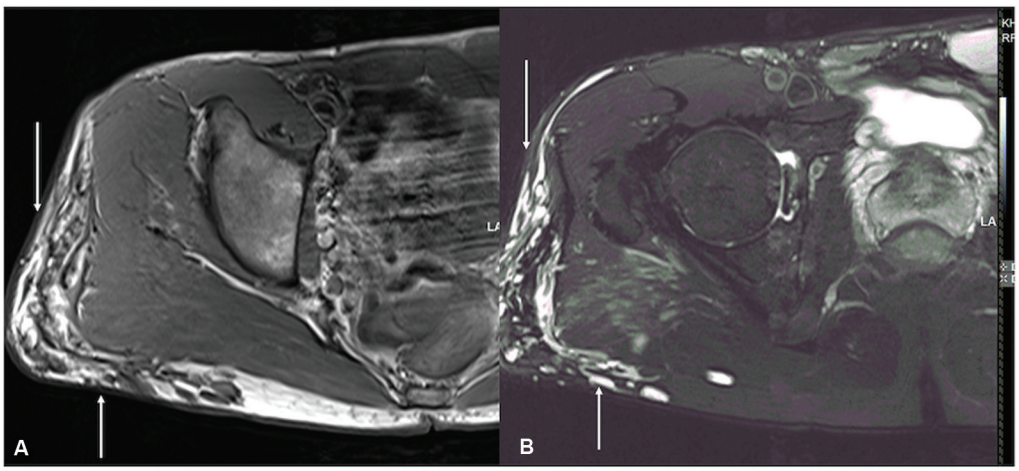

Fig. 3 Axial T1-weighted (**A**) and T2-weighted fat-saturated (**B**) magnetic resonance imagings of the right buttock. Foci of the same signal intensities as demonstrated in Fig. 2 are demonstrated in the subcutaneous fat, where they have a nodular pattern (arrow) and within the gluteus maximus muscle, where they have a feathered pattern. Also, despite the patient being listed as female on the RIS, a prostate gland is noted within the pelvis. RIS, Radiology information System.

discoloration, nodules, ulcers).[5,6] HAI filler migration is a very rare complication, and according to the authors knowledge, has rarely been described in the literature.[9–13] Moreover, HAI migration is often difficult to diagnose as reactions may occur months after injection and lumps formed distant to the site of filler injections would not routinely be considered a HAI filler complication. The phenomenon behind this migration is not well understood; however, it is thought to occur due to its hydrophilic nature and the diffusion permeability of the fibrous septae found between subcutaneous tissue layers.[5,12] Given the rarity of this complication, imaging often plays a critical role in diagnosis. Hence, it is necessary for radiologists to understand complications of HAI, progression and be able to delineate imaging features to avoid misinterpretation of MRI and USS as well as expedite therapeutic solutions in indistinct cases.

The imaging features of HAI can be somewhat misleading and nonspecific. Radiological features can mimic a neoplasm. USS is usually the initial investigation for any superficial lump and many studies have shown its efficacy in localizing commonly used fillers as well as detect filler-related complications. US of HAI are usually hypoechoic; however, in our

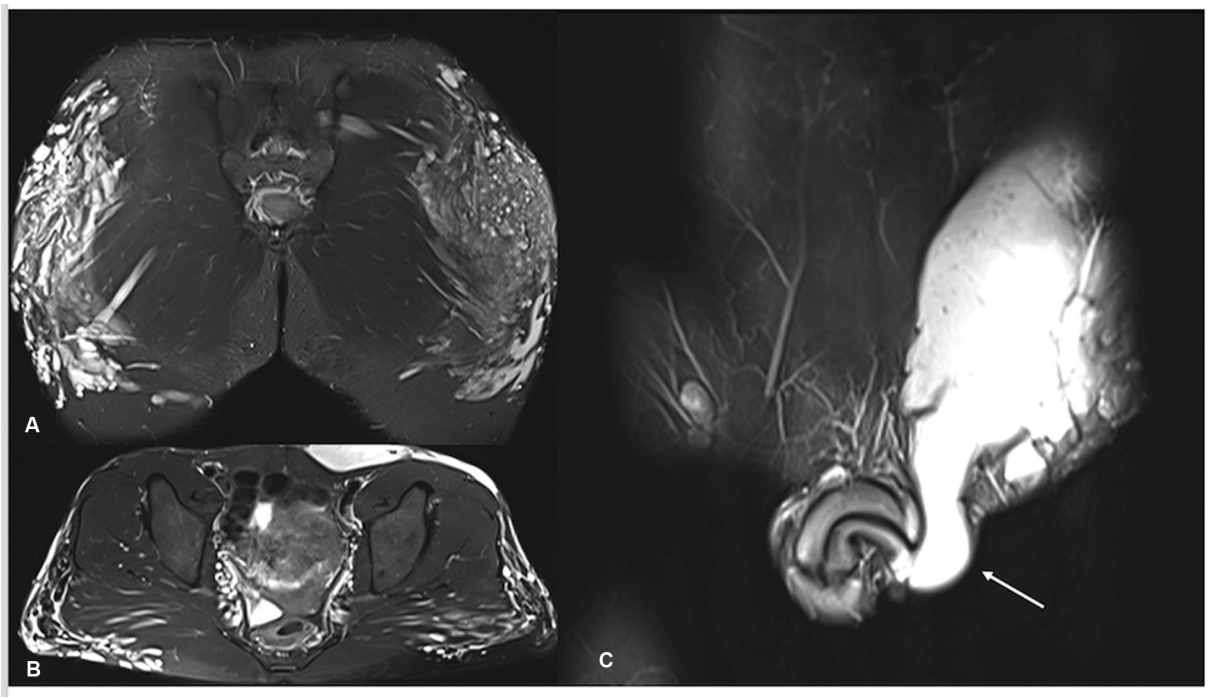

Fig. 4 The patient was recalled for wide-field of view images of the entire pelvis, including axial T2-weighted fat-saturated (**B**) and coronal short-tau inversion recovery (**A** and **C**). Again, the subcutaneous nodular pattern and intramuscular feathered pattern are noted. On the left, the abnormal signal extends into the subcutaneous tissue of the left scrotum, external to the inguinal canal (arrow). Despite the patient being listed as female on the RIS, a penis and scrotum are noted.

 © 2023. Indian Radiological Association. All rights reserved.

case this was hyperechoic that could be due to leakage into the subcutaneous tissues distant from initial site of injection. USS also plays a role in identifying the differentials of other soft tissue lesions. However, USS imaging of filler-related lumps is affected by the site and the time elapsed from injection, often complicating the diagnosis.[14] MRI is thought to be the best imaging modality to classify HAI lesions and has the advantage of accurately evaluating the volumetric and temporal changes of HA fillers.[15] HA filler lumps are best seen on fluid-sensitive fat saturated sequences. They possess appearances similar to that of water, with a faint peripheral enhancement at the early stages of injection and show progressive dissolution by 1 year on serial MRI.

Vascular malformation can be considered in the differential diagnosis of such lesions, if there is no relevant history. However, the fact that this was bilateral symmetrical and absence of increased signal on Doppler imaging are against this. These findings are contrary to features of a sinister lesion.

The treatment of migrated HA filler lesions is usually dependent on symptoms. This can involve aspiration or surgical drainage in symptomatic cases. To minimize the risk of migration, certain theories have been described in the literature. These include using low-pressure filler injections, limiting physical activity in the immediate post-injection period, and having more than one treatment session.[12,16]

Learning Points

1. The use of HA filler injections is becoming increasingly popular within current aesthetic practice.
2. Although HA filler migration is infrequent, it is imperative to ensure appropriate history is undertaken to narrow down the differential diagnosis.
3. Moreover, it is essential that radiologist is aware of the commonly used injectable fillers, their complications, and imaging findings to avoid misdiagnosis and unnecessary management.

Note
Consent was obtained from patient for this study.

Funding
None.

Conflict of Interest
None declared.

References

1 Salsberg J, Andriessen A, Abdulla S, et al. A review of protection against exposome factors impacting facial skin barrier function with 89% mineralizing thermal water. J Cosmet Dermatol 2019; 18(03):815–820
2 Alharbi M. Review of sterility of reused stored dermal filler. J Cosmet Dermatol 2019. Doi: 10.1111/jocd.12932
3 Walker K, Basehore BM, Goyal A, et al. Hyaluronic Acid. [Updated 2022 Jul 4]. In: StatPearls [Internet]. Treasure Island (FL): StatPearls Publishing; 2022. Accessed December 17, 2022 at: https://www.ncbi.nlm.nih.gov/books/NBK482440/
4 De Meyere B, Mir-Mir S, Peñas J, Camenisch CC, Hedén P. Stabilized hyaluronic acid gel for volume restoration and contouring of the buttocks: 24-month efficacy and safety. Aesthetic Plast Surg 2014;38(02):404–412
5 Becker M, Balagué N, Montet X, Calmy A, Salomon D, Toutous-Trellu LLIPO and Metabolism Group. Hyaluronic acid filler in HIV-associated facial lipoatrophy: evaluation of tissue distribution and morphology with MRI. Dermatology 2015;230(04):367–374
6 Lin DJ, Wong TT, Ciavarra GA, Kazam JK. Adventures and misadventures in plastic surgery and soft-tissue implants. Radiographics 2017;37(07):2145–2163
7 Gold MH. Use of hyaluronic acid fillers for the treatment of the aging face. Clin Interv Aging 2007;2(03):369–376
8 International Society of Aesthetic Plastic Surgeons IAPAS international survey on aesthetic/cosmetic procedures in 2017; 2018. Accessed December 17, 2022 at: www.isaps.org
9 Chae SY, Lee KC, Jang YH, Lee SJ, Kim DW, Lee WJ. A case of the migration of hyaluronic acid filler from nose to forehead occurring as two sequential soft lumps. Ann Dermatol 2016;28(05): 645–647
10 Mosleh R, Mukari A, Krausz J, Hartstein ME, Azzam SH. Orbit mass secondary to migration of dermal hyaluronic acid filler. JAAD Case Rep 2019;5(06):488–490
11 Almukhtar R, Fitzgerald R, Cotofana S, Fabi S. Migration of hyaluronic acid-based soft tissue filler from the temples to the cheeks-an anatomic explanation. Dermatol Surg 2021;47(11): 1526–1527
12 Jordan DR, Stoica B. Filler migration: a number of mechanisms to consider. Ophthal Plast Reconstr Surg 2015;31(04):257–262
13 Chang JR, Baharestani S, Salek SS, Piluek WJ, Eberhart CG, McCulley TJ. Delayed superficial migration of retained hyaluronic acid years following periocular injection. Ophthal Plast Reconstr Surg 2017;33(3S, Suppl 1):S116–S118
14 Urdiales-Gálvez F, De Cabo-Francés FM, Bové I. Ultrasound patterns of different dermal filler materials used in aesthetics. J Cosmet Dermatol 2021;20(05):1541–1548
15 Mundada P, Kohler R, Boudabbous S, Toutous Trellu L, Platon A, Becker M. Injectable facial fillers: imaging features, complications, and diagnostic pitfalls at MRI and PET CT. Insights Imaging 2017;8(06):557–572
16 Beer KR. Radiesse nodule of the lips from a distant injection site: report of a case and consideration of etiology and management. J Drugs Dermatol 2007;6(08):846–847

 © 2023. Indian Radiological Association. All rights reserved.