diagnostic deliberations. I ultimately excluded HES for the reasons stated in the discussion.

With the marrow findings in hand, HES is excluded by definition. In their classic review on the subject, Chusid and co-workers stipulated that there be no other demonstrable cause of eosinophilia if one is to make the "diagnosis" of HES. When the patient was first seen at Oregon Health Sciences University, the marrow was diagnostic of acute leukemia with 30 percent blast cells as well as an increase in eosinophils. The morphologic and histochemical characteristics of the blast cells were consistent with a lymphoid origin. One could argue that it is more typical in acute lymphoblastic leukemia (ALL) to find the bone marrow "packed" with blasts, but this certainly is not a prerequisite for the diagnosis. Of note in this regard is the fact that in 7 of the 15 reported cases of ALL associated with eosinophilia the initial bone marrow examination showed less than 50 percent blast cells (see reference 2, table 5 for references). Although karyotypic abnormalities have been found in patients with HES, this finding also supports the diagnosis of acute leukemia.

The reported absence of leukemic cells in the bone marrow at autopsy casts considerable doubt on the antemortem diagnosis. However, Dr Markwell was kind enough to forward the autopsy material to me and to my eye the postmortem marrow is hypercellular and contains a mixed infiltrate of eosinophils and abnormal mononuclear cells.

Drs Markwell and Wilson seem to be particularly impressed by the finding of endomyocardial fibrosis at autopsy and imply that this lesion could not have resulted from reactive eosinophilia. However, in their monograph on the eosinophil, Beeson and Bass cite numerous reports of endomyocardial fibrosis occurring in patients with eosinophilia secondary to parasitic infections, asthma, tropical eosinophilia, solid tumors and leukemia, as well as in patients with HES, and conclude "the clinical circumstances seem to provide indisputable evidence that high and prolonged eosinophilia from any cause can produce this unique kind of cardiac damage."[3] Furthermore, in the 15 reported cases of eosinophilia secondary to ALL,[2] 4 of the 5 patients in whom autopsies were done were found to have endomyocardial fibrosis at postmortem examination and the fifth had numerous infarcts and mural thrombi.

Shungaard and co-workers[4] have recently shed light on the mechanism by which eosinophils produce endocardial damage. They studied a patient with early endocardial damage and eosinophilia secondary to a highly anaplastic lung cancer. They found deposition of major basic protein (MBP), cytotoxic specific constituent of eosinophil granules, in areas of endocardial fibrosis but not in unaffected heart chambers. Delamination of endocardium from basement membranes was noted in areas of heavy MBP deposition. Moreover, treatment of cultured endothelial cells with MBP induced detachment of adherent monolayers from the culture dishes.

In summary, the postmortem findings in this case are nonspecific and could have resulted from eosinophilia of any cause. The comments of Drs Markwell and Wilson suggest that the intrepid CPC discussant, heart pounding with anticipation, should not breathe easy when the pathologist stands up and says "You got it right." Still, for the reasons stated, I think I did.

JOHN H. FITCHEN, MD
Associate Professor of Medicine
The Oregon Health Sciences University
Portland

REFERENCES

1. Chusid MJ, Dale DC, West BC, et al: The hypereosinophilic syndrome: Analysis of fourteen cases with review of the literature. Medicine (Baltimore) 1975; 54:1-27
2. Bachhuber R, Fitchen JH, Harty-Golder B: Rash and eosinophilia in a 23-year-old man. West J Med 1982 Sep; 137:221-227
3. Beeson PB, Bass DA: Major Problems in Internal Medicine, Vol 14: The Eosinophil. Philadelphia, WB Saunders, 1977
4. Shungaard A, Gleich G, Jacob HS: A mechanism of hypereosinophilic endocardial fibrosis: The delamination of endocardium by exocytosed eosinophil major basic protein. Blood 1982; 60(Suppl 1):68a

Possible Therapy for Snoring

TO THE EDITOR: Snoring is a very disturbing disorder for which no adequate pharmacotherapy has been recommended. There have been numerous mechanical aids devised, but all of these seem to be rather uncomfortable.

Since protriptylene has been reported effective in sleep apnea, perhaps by improving airway coordination,[1] I have been prescribing a small dose of about 10 mg at bedtime to snoring patients whose spouses or families complained that the noise levels were unbearable. It is well known also that snoring is a frequent concomitant of obstructive sleep apnea.

Most families thus far have reported a diminution or cessation of snoring after protriptylene therapy was instituted. I have not done a double-blind study on this problem, but such a benign intervention appears worthy of further trials.

JAY A. GOLDSTEIN, MD
Anaheim Hills, California

REFERENCE

1. Cloaker LA, Quan SF: Diagnosis and treatment of sleep apnea syndrome in adults (Seminars in Continuing Education). Ariz Med 1981 Jun; 38:446-550

Hospital Charges in Rural Utah

TO THE EDITOR: The expansion in the number of rural hospitals over the past 30 years has provided many rural communities with a financial challenge. Low "front end" costs for these hospitals, many in part subsidized by Hill-Burton funds, have been affected by advances in technology, changing physician practice patterns, increasing employee salaries, shifts in the demographic characteristics of the population served, and the costs associated with meeting governmental and accreditation standards.[1] Closure of marginally surviving rural hospitals has been suggested as a means of reducing health care costs.[2] However, given the substantial emotional

TABLE 1.—*Charges for Daily Semiprivate Room Rate in Each Hospital for Time Period Two Years Before Affiliation to Two Years After Affiliation**

Group & Hospital	−2 Year Dollars	−2 Year (percent)	−1 Year Dollars	−1 Year (percent)	+1 Year Dollars	+1 Year (percent)	+2 Year Dollars	+2 Year (percent)
A1	$86.00		$95.00	(10.5)	$135.00	(42.1)	$140.00	(3.7)
A2	67.00		85.00	(26.9)	140.00	(64.7)	140.00	(0.0)
B1	-NA-		75.00		90.00	(20.0)	115.00	(27.7)
B2	78.00	(20.0)	90.00	(15.4)	112.00	(24.4)	125.00	(11.6)
B3	68.00		74.00	(8.8)	86.00	(16.2)	103.00	(19.7)
C1	63.00		72.00	(14.3)	87.00	(20.8)	96.00	(10.3)
C2	64.00		72.00	(12.5)	92.00	(27.7)	105.00	(14.1)

*Groups A and B represent for-profit affiliation. Group C represents nonprofit affiliation. Percent increase from the preceding year is shown in parentheses.

and monetary investment in many of these hospitals, this is usually only considered as a "last resort."

One option for solving financial problems has been the shift in ownership or management of these hospitals from communities to regional or national nonprofit or for-profit corporations. Chain, for-profit hospitals may be less costly than nonprofit hospitals.[3] However, the study on which this observation was based may have over-sampled urban hospitals. To more clearly understand this phenomenon in rural areas, we evaluated the impact of a change in hospital ownership or administration upon hospital charges in rural Utah.

In the last seven years 19 of 25 rural hospitals in Utah have undergone hospital chain management or ownership affiliation. Of these, seven allowed us to review charge information for a period extending two years before to two years after affiliation. Each belonged to one of three groups: two for-profit chains and one nonprofit chain. Each is located in a rural community of 25,000 people or less and contains fewer than 80 beds. We collected charge information on a number of services, including semiprivate room rate, nursery room rate, electrocardiograms and complete blood counts. These services were chosen based upon the assumption that they did not vary as a function of either diagnosis or hospital case mix. To verify and supplement data collected at each hospital, records of the State Medicaid Management System were also reviewed.

Because of the small sample and short period of the review, we felt that substantial analysis of the data would not be meaningful. Assessment of the trend of charges is interesting, nonetheless. For example, Table 1 presents daily room charges during each year for each hospital. Charges increased substantially more in the year immediately following affiliation than they did in the year before. The magnitude of the marginal increase in percentage for the first affiliation year ranged from 1.4 percent to 37.8 percent, with an average marginal increase of 17.9 percent. A similar trend existed for nursery room rates. For the five hospitals for which these data are available, rates in four increased more in the year following affiliation than they did in the year before (range, 5 percent to 102 percent), with the average marginal increase being 33.6 percent.

Comparing the hospitals with respect to for-profit and nonprofit status, group C, the nonprofit corporation, had, as a rule, lower percentage increases upon affiliation. Group C also had lower total increases in charges over the first two years of affiliation than the other two for-profit corporations. For example, group A hospitals showed a 57.8 percent average increase in semiprivate room rates over the first two years of affiliation and group B showed a 39.8 percent increase. Group C hospitals, on the other hand, showed only a 28.5 percent average increase. However, group A hospitals did average lower percentage increases in nursery room rates (66.4 percent) than group B (93.1 percent) and group C (84.6 percent).

For the less costly services (such as electrocardiograms and complete blood counts) a pattern was seen with group A increases being larger than those for group B, which are larger than found in group C.

Small hospitals have several options in adapting to increasing financial burdens. They may increase charges on their own, pass an often unpopular bond issue, associate with other rural or urban hospitals, contract for the services provided, or close. Eliminating unprofitable services is possible. However, unless a hospital maintains modern equipment and the widest possible range of services, patients may opt for care in facilities that they perceive to be more modern.[1] Also, without modern facilities, hospitals often cannot attract physicians.[4] Although increased charges may reflect a "catch up" phenomenon necessary to attain financial solvency, given previously reported information on the potential cost-effectiveness of merging rural hospitals,[5] several questions remain unanswered: Is there a true need in each community for a hospital? Is the relationship among charge for service, services offered and overall cost of operation influenced by the nonprofit or for-profit nature of the affiliating corporation? What impact do such affiliations have on the overall cost of health

care? And finally, what impact upon quality of care and health status can be expected from such changes?

MICHAEL H. BOURNE, BA
Third-Year Medical Student

KEVIN PATRICK, MD, MSCM
Assistant Professor
Department of Family and Community Medicine

F. ROSS WOOLLEY, PhD
Associate Professor
Department of Family and Community Medicine
University of Utah School of Medicine
Salt Lake City

REFERENCES

1. Christianson JB, Falkner L: The contribution of rural hospitals to local economies. Inquiry 1981 Spring; 18:46-60
2. McClure W: Reducing excess hospital capacity. Springfield, VA, National Technical Information Service, Bureau of Health Planning and Resources Development, DHEW Report HRP-0015194, 1976, pp 35-38
3. Bays CW: Cost comparisons of for-profit and nonprofit hospitals. Soc Sci Med 1979 Dec; 13:219-225
4. Kane WJ: Rural health care. JAMA 1978 Dec 8; 240:2647-2650
5. Treat TF: The performance of merging hospitals. Med Care 1976 March; 14:199-209

Pneumothorax: A Complication of 'Skin Popping'

TO THE EDITOR: The hazards of subcutaneous drug abuse in the cervicothoracic region have not been well documented in the recent literature. We wish to report a case of direct drug injection into the lateral thorax, resulting in a pneumothorax.

Report of a Case

A 29-year-old woman with a history of chronic intravenous and subcutaneous drug abuse was admitted with a chief complaint of severe right-sided pleuritic chest pain. The onset of her symptom began after a mixture of methylphenidate hydrochloride (Ritalin) and codeine was injected into the lateral right side of her chest. She said that there was no "charge" from this "skin popping" attempt, but shortly thereafter chest pain developed on the right side, originating from the site of the injection and radiating anteriorly and posteriorly. She noted no other symptoms.

On physical examination, the patient was well developed and in no acute distress. She had multiple skin lesions secondary to her drug injections on all extremities and thorax that ranged in appearance from scarred and sclerotic to erythematous, abscessed lesions. Her most recent site of injection was located at approximately the fifth intercostal space, anterior axillary line. On auscultation there were decreased breath sounds on the right. The findings on the remainder of the examination were unremarkable.

An x-ray film of the chest showed a small right-sided pneumothorax (Figure 1). Another film two days later showed partial resolution of the pneumothorax. The patient's symptoms lessened and she was discharged with warnings regarding the dangers of continued drug injection.

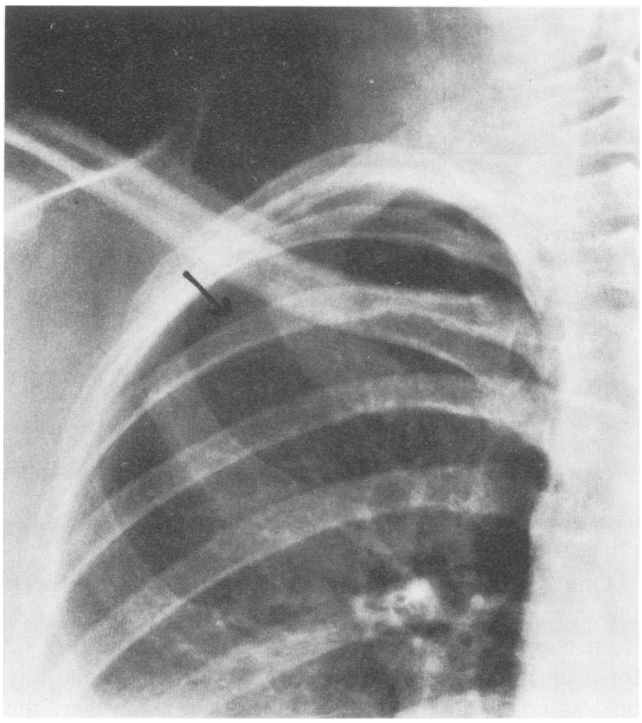

Figure 1.—An x-ray study showing small pneumothorax **(arrow)** on right side of patient's chest.

Comment

Chronic intravenous and subcutaneous drug abuse often leads to the injection of drugs in more unusual and dangerous sites after the more commonly accessible sites become sclerosed and unavailable.[1] These other sites are the neck, supraclavicular region and the thorax. As in the case presented, the possibility of a pneumothorax should be considered in a patient who has recently injected drugs and presents with chest pain.

LUCY SHIH, BA
Fourth-Year Medical Student

OM P. SHARMA, MD
Associate Professor of Medicine

KEVIN BARNETT, MD
Medical Resident

Pulmonary Diseases Division
Los Angeles County-University of Southern California Medical Center
Los Angeles

REFERENCE

1. Lewis JW Jr, Groux N, Elliott JP Jr, et al: Complications of attempted central venous injections performed by drug abusers. Chest 1980; 78:613-617