cant depression of the C1q level should prompt further evaluation for lymphoma and other conditions associated with the acquired inhibitor deficiency.

REFERENCES

1. Caldwell JR, Ruddy S, Schu PH, et al: Acquired C1 inhibitor deficiency in lymphosarcoma. Clin Immunol Immunopathol 1972 Oct; 1:39-52
2. Gelfand JA, Boss GR, Conley CL, et al: Acquired C1 esterase inhibitor deficiency and angioedema: A review. Medicine (Baltimore) 1979 Jul; 58:321-328
3. Cohen SH, Koethe SS, Kozin F, et al: Acquired angioedema associated with rectal carcinoma and its response to danazol therapy—Acquired angioedema treated with danazol. J Allergy Clin Immunol 1978 Oct; 62:217-221
4. Mann RB, Jaffe ES, Berard, CW: Malignant lymphomas: A conceptual understanding of morphologic diversity—A review. Am J Pathol 1979 Jan; 94:105-192
5. Rosenfeld SI, Staples PJ, Leddy JP: Angioedema and hypocomplementemia: Unusual features of lymphoma. J Allergy Clin Immunol 1975 Feb; 55-104
6. Schreiber AD, Zweiman B, Atkins P, et al: Acquired angioedema with lymphoproliferative disorder: Association of C1 inhibitor deficiency with cellular abnormality. Blood 1976 Oct; 48:567-580
7. Hauptmann G, Mayer S: Treatment of acquired C1-inhibitor deficiency with danazol. Ann Intern Med 1977 Nov; 87:577-578
8. Gelfand JA, Sherins RJ, Frank MM, et al: Treatment of hereditary angioedema with danazol. N Engl J Med 1976 May; 195:1444-1448
9. Frank MM, Gelfand JA, Atkinson JP: Hereditary angioedema: The clinical syndrome and its management. Ann Intern Med 1976 Dec 23; 84:580-593

Fulminant Neonatal Hepatic Necrosis Associated With Echovirus Type 11 Infection

NORMAN GITLIN, MD, MRCP, MRCPE
NADARASA VISVESHWARA, MB
STEPHEN H. KASSEL, MD
IRA ROBERT BYOCK, MD
KRISHNAKUMAR B. RAJANI, MD, MRCP
HORST M. WEINBERG, MD
Fresno, California

NEONATAL HEPATIC NECROSIS is fortunately rare.[1] Although a variety of enteroviruses have been recognized to infect fetuses and neonates,[2-4] the cause of most cases of fulminant neonatal hepatic necrosis is unknown.[1] Occasionally cytomegalovirus,[5] rubella[6] and echovirus types 3,[7] 6,[8] 9,[9] 11,[8,10,11] 14[12] and 19[13] have been directly associated with fatal hepatic necrosis during the neonatal period.

We report four cases of neonatal hepatic necrosis associated with echovirus type 11. These cases occurred sporadically during one year and each patient came from a different geographic area; thus at no time was an epidemic of echovirus type 11 suspected.

The perinatal histories were negative for viral illness as manifested by fever, vomiting, diarrhea or upper respiratory tract infections.

Refer to: Gitlin N, Visveshwara N, Kassel SH, et al: Fulminant neonatal hepatic necrosis associated with echovirus type 11 infection. West J Med 1983 Feb; 138:260-263.

From the Departments of Medicine (Dr Gitlin), Pediatrics (Drs Visveshwara and Weinberg) and Pathology (Dr Kassel), University of California, San Francisco, Fresno-Central San Joaquin Valley Medical Education Program, the Veterans Administration Medical Center, Fresno (Dr Gitlin), Valley Children's Hospital, Fresno (Drs Visveshwara, Kassel, Rajani and Weinberg) and Valley Medical Center, Fresno (Dr Byock).

Submitted, revised, November 24, 1981.

Postmortem studies in case 4 were done by Zrino Bezmalinovic, MD.

Reprint requests to Norman Gitlin, MD, Department of Medicine, Veterans Administration Medical Center, 2615 East Clinton Avenue, Fresno, CA 93703.

TABLE 1.—*Summary of Clinical Features and Results of Laboratory Investigations*

Data	*Case 1*	*Case 2*	*Case 3*	*Case 4*
Birth weight (grams)	3,856	3,359	3,154	2,765
Admission weight (grams)	3,000	2,934	3,000	2,540
Gestation (weeks)	37	38	38	38
First symptoms	Jaundice	Jaundice	Jaundice	Jaundice
Age	5 days	6 days	6 days	5 days
Bilirubin (mg/dl) (normal 1-12)	10.1	10.3	11.3	14.1
Platelet count (per cu mm)	39,000	46,000	10,000	31,000
Fibrinogen (mg/dl) (normal 200-300)	...	12	40	40
Fibrin-split products (μg/dl) (normal 0-3)	40	40	40	40
AST (IU) (normal 11-40)*	5,530	7,480	1,182	1,029
ALT (IU) (normal 11-40)†	1,370	2,040	227	197
AST/ALT ratio	4.0	3.6	5.2	5.2
Prothrombin time (sec)	45.0	33.5	28.9	28.6
Blood ammonia (μg/dl) (normal 11-35)	NP	158	108	NP
Viral cultures (Echovirus II)				
Liver	+	+	+	+
Lung	+	+	+	+
Parents	NP	NP	NP	NP

NP = not performed; + = positive.

*Aspartate aminotransferase, formerly SGOT.
†Alanine aminotransferase, formerly SGPT.

Reports of Cases

CASE 1. This infant was delivered by cesarean section to a 26-year-old primigravid woman. The mother was treated throughout her pregnancy with phenytoin sodium and phenobarbital for the control of a seizure disorder. Birth weight was 3,856 grams. The infant was discharged home at 3 days of age after an unremarkable hospital course.

The parents noted that the infant at 5 days of age was jaundiced, lethargic and had mottling of the lower extremities; he was readmitted to hospital. Examination showed that the abdomen was distended and tender with the liver edge palpable 8 cm below the right costal margin. Pertinent laboratory data are summarized in Table 1. Despite exchange transfusion with packed cells reconstituted with fresh frozen plasma, the infant's condition steadily deteriorated until his death the next day. The parents and a 15-month-old sibling were asymptomatic throughout the neonate's illness.

CASE 2. This infant was delivered by cesarean section because of cephalopelvic disproportion. The perinatal history was unremarkable except for a vaginal yeast infection two weeks before delivery. The Apgar score was listed as 9 at one and at five minutes. Birth weight was 3,359 grams. The infant had an unremarkable hospital course and was discharged home on the third day.

On the sixth day of life, a temperature of 39°C (102°F) developed and he was found to be jaundiced, with a serum bilirubin level of 10.7 mg per dl. A workup for sepsis was done, including a lumbar puncture, but proved negative. He became more lethargic and jaundiced and had some respiratory distress. The liver

was palpated 2 cm below the right costal margin. Laboratory data are summarized in Table 1.

Soon after admission, the infant had a generalized tonic-clonic seizure, following which his pupils became dilated and nonreactive to light. A bleeding diathesis then developed, characterized by an oozing from all puncture sites and a bloody endotracheal tube aspirate. Double-volume exchange transfusion with fresh whole blood was done to correct the disseminated intravascular coagulation and to replenish some of the coagulation factors. The infant's clinical condition deteriorated, however, and he died 24 hours after admission.

CASE 3. This infant was the product of a normal spontaneous vaginal delivery to a 25-year-old gravida 2, para 1 woman. Antenatal history and perinatal history were unremarkable. The Apgar score was listed as 9 at both one and five minutes. Birth weight was 3,154 grams. The infant had an unremarkable course in the first four days of life.

On the fifth day he was observed to be jaundiced, with a serum bilirubin level of 11.3 mg per dl. On the sixth day the infant became irritable and was feeding poorly. He was then admitted to hospital where pertinent physical signs included lethargy and poor response to stimuli; the abdomen was distended and tender and the liver edge was palpable 4 cm below the right costal margin. Biochemistry findings are summarized in Table 1.

Soon after admission the infant's blood pressure suddenly rose, followed by the sudden onset of apnea and bradycardia with poor response to stimuli. At lumbar puncture the fluid was found to be grossly bloody. An exchange transfusion with fresh whole blood was carried out. A computerized tomographic scan done thereafter showed massive intraventricular and intracerebral hemorrhage. The infant's clinical condition deteriorated and he died shortly thereafter.

CASE 4. The child was a male infant born to a 20-year-old gravida 3, para 3 mother by repeat cesarean section. The maternal history was significant for epilepsy, well controlled by phenobarbital therapy. Ten days before the birth premature labor occurred, felt to be due to asymptomatic bacteremia. Management included administration of ampicillin and parenteral terbutaline sulfate tocolysis. Oral administration of terbutaline was continued until term. Birth weight was 2,765 grams. Apgar score was listed as 9 and 10 at one and five minutes, respectively. The course in the nursery was unremarkable.

On day 5, while at home, the child was noted to feed poorly at the breast and to be lethargic and jaundiced.

The infant was admitted to hospital. Findings on general examination were remarkable only for icterus; the liver was palpable 1 cm below the right costal margin. Hematologic and biochemical studies showed a severe hepatitis with disseminated intravascular coagulation (Table 1).

Fresh frozen plasma and platelets were administered and an exchange transfusion with whole blood carried out. Despite these efforts, the disseminated intravascular coagulation progressed and evidence of hemorrhage emerged, progressing to circulatory collapse and death.

Determination of creatine kinase and serum aldolase levels was not done. Neither viral cultures nor titers from cord blood or parents were available. Viral cultures were done at postmortem examination on specimens from the liver and lungs and were positive for echovirus type 11 in all four cases.

Virology Studies

Specimens were taken from the lungs and liver at postmortem examination while the organs were in situ and before opening the bowel. The specimens were inoculated into human fetal diploid lung and primary monkey kidney tissue, which was incubated for 14 days. A daily check for cytopathic effect of cells was undertaken. From this cytopathic effect, a diagnosis of enterovirus was made and the culture was subpassaged to increase the viral concentration. Then, using the tube neutralization test (the Lim and Benyesh-Melnick schema[14]) the subspecies was identified. The identification was done at the Fresno County Laboratory using the standard method of the California State Health Department. Echovirus type 11 was isolated from the liver and lungs in all four cases that were evaluated.

Discussion

The enteric cytopathic human orphan (ECHO) group of enteroviruses is known to be capable of producing a wide spectrum of human diseases, including asymptomatic infection.[15,16] The infection occurs primarily in children and in young adults. The incubation ranges from 2 to 20 days, but is usually 5 to 10 days.[15] The most common symptoms are fever, headache, nausea and vomiting, sore throat, rhinitis, myalgia, rash and a cough accompanied by chest pain. These symptoms may reflect aseptic meningitis, carditis, encephalitis, gastroenteritis or pleurodynia. A familial incidence is common and there is a tendency for the condition to relapse or run a biphasic course. Infections due to echoviruses are seldom associated with serious residual effects.[15]

There are scant data implicating echoviruses in liver disease. Mild disturbances in liver function or hepatomegaly (or both) have occasionally been noted during outbreaks of echoviruses 1, 4, 6, 7, 8, 9 and 12.[17] Isolated cases of fulminant neonatal hepatic necrosis associated with echoviruses 3, 6, 9, 14 and 19 have been reported.[7,13] These reports described an illness with a rapid, fatal course of three to four days. Necropsy findings showed severe liver parenchyma loss but an intact reticular network, a surviving collar of hepatocytes around the portal areas and minimal mononuclear cell infiltration. Rarely, giant cells, iron deposition or calcification was noted. The destroyed hepatocytes were replaced by a pool of blood—mostly erythrocytes.

The cases described in this report are interesting because of the findings that appear peculiar to echovirus type 11 infection. The identification of echovirus type

11 at postmortem studies of specimens from the liver and lungs of all four infants is strong evidence that this virus represents the causal agent.[18] There was no evidence of coincidental infection or contamination. All the cases had features suggestive of disseminated intravascular coagulation, which could be a nonspecific phenomenon of severe acute hepatic failure. All the infants, however, also showed a unique and constant elevation of serum aspartate aminotransferase (AST, formerly SGOT)-to-serum alanine aminotransferase (ALT, formerly SGPT) ratio between 3.6 and 5.2. The AST-to-ALT ratio has been investigated as a diagnostic tool in many forms of liver diseases. Cohen and Kaplan[19] in a recent report concluded that a ratio of greater than 2 was highly suggestive of alcoholic hepatitis and cirrhosis. In only 4 percent of their patients with viral hepatitis was the ratio higher than 2. The highest ratio in viral hepatitis was marginally greater than 2. They also noted that in alcoholic liver disease, the serum ALT level was less than 300 IU in 98 percent of patients; thus, the increased ratio was accounted for by a disproportionate elevation of AST. In our patients, despite an AST-to-ALT ratio of 3.6 to 5.2, the serum ALT values ranged from 197 to 2,040 with a mean of 1,150 IU. The AST and ALT determinations were done on the same blood specimen and they were measured in the hospital chemistry laboratory on the DuPont ACA.[20,21] Where serial aminotransferase determinations were available, the ratio of every set was noted and every patient maintained a constant ratio of AST-to-ALT that was unique to that given infant (see Table 1 and Figure 1).

The high AST-to-ALT ratio in fulminant hepatic necrosis may be explained by the fact that in a normal liver, the *liver* AST-to-ALT ratio is 3.2,[22] and the serum ratio of 3.6 to 5.2 merely reflects an acute massive hepatic release of these enzymes. One doubts whether this is a specific feature of echoviral hepatitis.

In a recent report[23] of an echovirus type 11 epidemic in Japan affecting 102 patients, the authors noted that echovirus type 11 infections were less serious in neonates as compared with children of an older age. They also reported no remarkable gastrointestinal symptoms in any of their 42 neonates infected with echovirus type 11. A British study[24] of an outbreak of echovirus in a

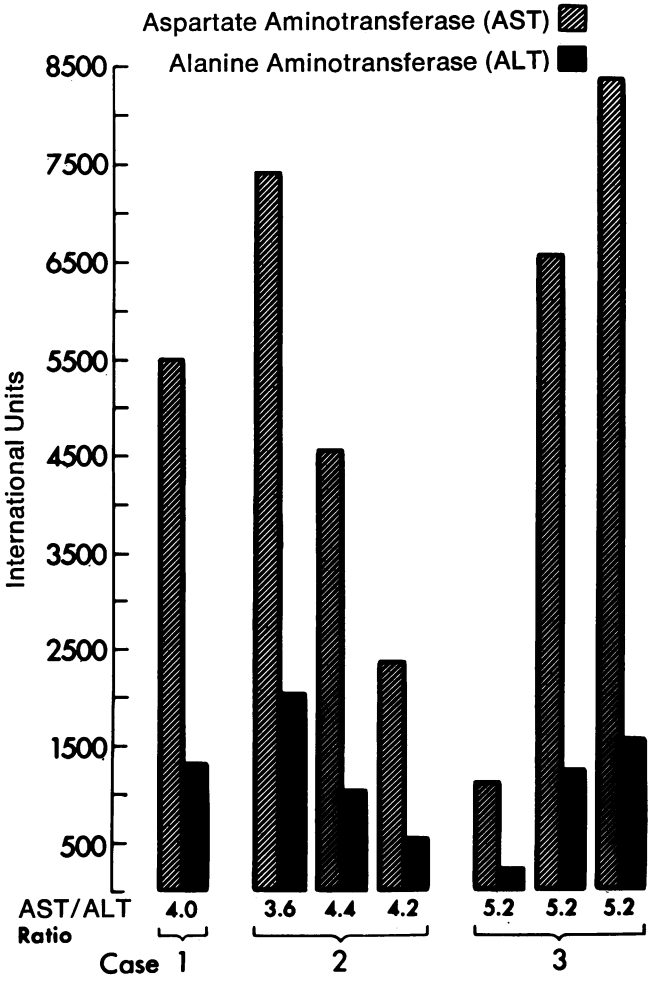

Figure 1.—The AST/ALT ratios of cases 1 through 3.

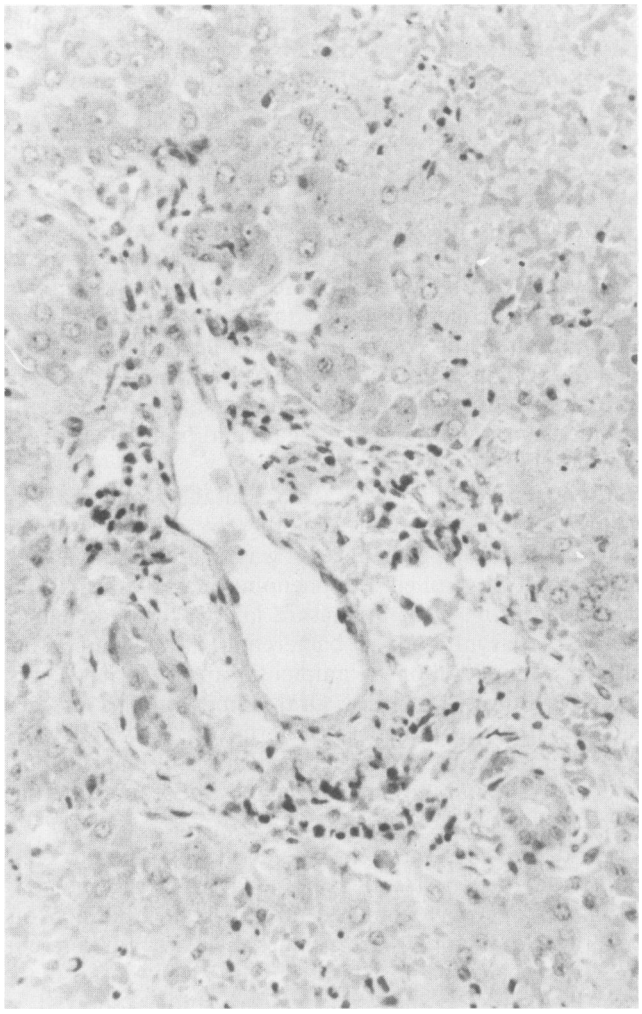

Figure 2.—Postmortem histologic examination of specimen of liver from case 4 showing massive hepatic necrosis with some intact periportal hepatocytes. Pronounced sinusoidal congestion is present in the necrotic areas. The portal triad is unremarkable. (Hematoxylin and eosin stain, reduced from magnification × 66.)

neonatal unit from which 9 to 24 became infected reports three infant deaths. In the three fatal cases there were renal and gastrointestinal lesions but no histologic abnormality in the liver. Six other patients, all of whom recovered, had predominantly an aseptic meningitis with apneic attacks or appeared "off color." All other fatal cases of echovirus type 11 infection reported in neonates have been due to disseminated intravascular coagulation. In each of these cases, the infants presented with a rapidly developing septicemic condition and died within 24 hours after the appearance of symptoms.[25,26]

This report expands the recently reported association between echovirus type 11 and fulminant neonatal hepatic necrosis.[8,10,11] Massive hepatic failure with extensive hemorrhage due to hepatic disease and disseminated intravascular coagulation have been the predominant clinical features in the previous six cases of echovirus type 11 fulminant neonatal necrosis. Previous isolated reports of neonatal hepatic necrosis have involved echoviruses 3, 9, 11, 14 and 19 and they describe a similar clinical picture. Liver histology in our infants showed almost complete necrosis of hepatocytes, with a collar of surviving hepatocytes around the portal tracts. These portal tracts and the hepatic lobular architecture appeared essentially intact. No hemosiderosis, calcium or giant cells were noted; no inflammatory infiltrate was evident, but there was extensive hemorrhage into the liver tissue (Figure 2).

The clinical course of our infants and the subsequent postmortem pathology appear similar to the five cases of neonatal hepatic necrosis described by Ruebner and colleagues,[1] except for the absence of hemosiderin deposition and hepatocytic giant cells in our cases. No cause was identified in the report of Ruebner and associates and most of these infants had massive adrenal hemorrhage as was encountered in our series. In both series, the infants were not premature and there was a rapid, fatal course reflecting disseminated intravascular coagulation, profound hemorrhagic diathesis, hypoglycemia and encephalopathy but only moderate serum bilirubin elevation. It is possible that the echovirus type 11 was the cause in both series or, more probably, neonates' livers have a limited response to severe damage regardless of the origin.

The epidemiology of the infection in our cases is obscure. The patients became ill on the fifth or sixth day of life, thus they could have acquired their infection either in utero[11,27] or after birth. No sources of contact for infection were identified when sought and the cases occurred over a wide geographic area and at a scattered time interval, thus eliminating the likelihood of an epidemic. The cardinal pathologic findings, apart from those already described in the liver, were disseminated intravascular coagulation and extensive adrenal hemorrhage.

Thus, in the light of our findings, echovirus type 11 expands the growing list of viral agents capable of causing fulminant hepatic necrosis. Severe echovirus infections appear to occur mostly in neonates and infants. The same viruses produce a much milder, self-limiting disease in older children and adults and are more likely to affect the respiratory and neurological systems in the older age groups.

A possible explanation for this is that transplacental passage of neutralizing echovirus type 11 antibody does not occur if the maternal infection occurs in the immediate antenatal period. Decreased immune response in a newborn would aggravate this unprotected state, thus predisposing to an overwhelming viremia. Recently, Modlin and associates[11,28] have shown that any passive immunity acquired from the mother prevents severe neonatal systemic echovirus disease. However, they showed that this does not prevent mucosal infection of the respiratory or gastrointestinal tract. Hence we conclude that infants of mothers with perinatal echovirus type 11 infection should be closely observed for the occurrence of liver disease. This would be especially important when the maternal infection occurs immediately antepartum.

REFERENCES

1. Ruebner BH, Bhagavan BS, Greenfield AJ, et al: Neonatal hepatic necrosis. Pediatrics 1969 Jun; 43:963-970
2. Nogen AG, Lepow ML: Enteroviral meningitis in very young infants. Pediatrics 1967 Oct; 40:617-626
3. Berkovich S, Pangan J: Recoveries of virus from premature infants during outbreaks of respiratory disease: The relation of ECHO virus type 22 to disease of the upper and lower respiratory tract in the premature infant. Bull NY Acad Med 1968 Apr; 44:377-387
4. Sanders DY, Cramblett HG: Viral infections in hospitalized neonates. Am J Dis Child 1968 Sep; 116:251-256
5. Weller TH, Macauley JC, Craig JM, et al: Isolation of intranuclear inclusion producing agents from infants with illness resembling cytomegalic inclusion disease. Proc Soc Exp Biol Med 1957 Jan 12; 94:4-7
6. Esterley JR, Slusser RJ, Ruebner BH: Hepatic lesions in the congenital rubella syndrome. J Pediatr 1967 Nov; 71:676-685
7. Haynes RE, Cramblett HG, Hilty MD, et al: ECHO virus type 3 infections in children: Clinical and laboratory studies. J Pediatr 1972 Apr; 80:589-595
8. Krous HF, Dietzman D, Ray CG: Fatal infections with echovirus types 6 and 11 in early infancy. Am J Dis Child 1973 Dec; 126:842-846
9. Rawls WE, Shorter RG, Herrmann EC: Fatal neonatal illness associated with ECHO 9 (Coxsackie A-23) virus. Pediatrics 1964 Feb; 33: 278-280
10. Longworth-Krafft J, Morgan-Capner P: Renal medullary haemorrhage and echovirus infection (Letter). Lancet 1980 Jan 26; 1:200
11. Modlin JF: Fatal echovirus 11 disease in premature neonates. Pediatrics 1980 Nov; 66:775-780
12. Hughes JR, Wilfert CM, Moore M, et al: Echovirus 14 infection associated with fatal neonatal hepatic necrosis. Am J Dis Child 1972 Jan; 123:61-67
13. Philip AGS, Larson EJ: Overwhelming neonatal infection with ECHO 19 virus. J Pediatr 1973 Mar; 82:391-397
14. Lim KA, Benyesh-Melnick M: Typing of viruses by combinations of antiserum pools—Application to typing of enterovirus. J Immunol 1960; 84:309-317
15. Sanford JP, Sulkin SE: The clinical spectrum of ECHO-virus infection. N Engl J Med 1959 Nov 26; 261:1113-1122
16. Davies JE, McDermott A, Swevers D: Epidemic virus meningitis due to ECHO 9 virus in Newfoundland. Can Med Assoc J 1958 Aug 1; 79:162-167
17. Hersey DF, Shaw ED: Viral agents in hepatitis—A review. Lab Invest 1968 Nov; 19:558-572
18. Lennette EH, Schmidt NJ (Eds): Diagnostic Procedures—Vol 1, Diagnostic Procedures for Viral, Rickettsial and Chlamydial Infections. Washington, DC, American Public Health Association 1979
19. Cohen JA, Kaplan MM: The SGOT-SGPT ratio—An indicator of alcoholic liver disease. Dig Dis Sci 1979 Nov; 24:835-838
20. Westgard JO, Lahmeyer BL: Comparison of results from DuPont "ACA" and Technicon "SMA 12-60." Clin Chem 1972 Apr; 18:340-348
21. Bergmeyer HU, Bernt E: Methods of Enzymatic Analysis. New York, Academic Press, 1965, p 846
22. Matloff DS, Selinger J, Kaplan MM: Hepatic transaminase activity in alcoholic liver disease. Gastroenterology 1980 Jun; 78:1389-1392
23. Suzuki N, Ishikawa K, Horiuchi T, et al: Age-related symptomatology of ECHO 11 virus infection in children. Pediatrics 1980 Feb; 65:284-286
24. Nagington J, Wreghitt TE, Gandy G, et al: Fatal echovirus 11 infections in outbreak in special-care baby unit. Lancet 1978 Sep 30; 2:725-728
25. Hercik L, Huml M, Mimra JB, et al: Epidemien der Respirationstrakterkrankungen bei Neugeborenen durch ECHO 11-Virus. Zentralbl Bakteriol 1970; 213:18-27 (Ger)
26. Davis DP, Hughes CA, MacVicar J, et al: Echovirus 11 infection in a special care baby unit (Letter). Lancet 1979 Jan; 1:96
27. Jones MJ, Kolb M, Votara HJ, et al: Intrauterine echovirus type 11 infection—Case report. Mayo Clin Proc 1980 Aug; 55:509-512
28. Modlin JF, Polk BF, Horton P, et al: Perinatal echovirus infection: Risk of transmission during a community outbreak. N Engl J Med 1981; 305:368-371