Sexual Medicine, 2023, **11**, 1–4
https://doi.org/10.1093/sexmed/qfac011
Case Report

Penile metastasis from prostate cancer misdiagnosed as Peyronie disease: a case report

Yu Dai, Bao-Lei Shi, Jie Zhang, Shuang-Ning Liu, Ya-Tao Jia*

Department of Urology, Baoji People's Hospital, Baoji, Shaanxi, 721000

*Corresponding author: Department of Urology, Baoji People's Hospital, 24 Xinhua Lane, Jinger Road, Weibin District, Baoji City, Shaanxi Province, 721000. Email: 3036565766@qq.com

Abstract

Introduction: Penile metastases from prostate cancer are rare, and patients' prognosis and survival rates are low. Conservative treatment is usually recommended for such patients with an emphasis on improving their quality of life.

Aims: The aims were to raise awareness of penile metastasis from prostate cancer and Peyronie disease among physicians and other health care professionals, as well as to provide a useful experience for future diagnosis and treatment.

Methods: The current case report is based on patient self-report and a literature review. Written informed consent was obtained from the patient.

Results: We report the case of a 68-year-old man who was admitted with a complaint of urinary retention. Preoperative examination and ancillary tests showed a 2.0-cm-long hard nodule palpable on the dorsal aspect of the penile root, which was misdiagnosed as Peyronie disease. However, a biopsy of the penile scleroma was performed, and the final pathology finding confirmed the diagnosis of penile metastasis from prostate cancer. The patient opted for continuous androgen deprivation therapy (abiraterone) and systemic chemotherapy (docetaxel and cisplatin). He was treated for 2 cycles and had no specific discomfort during chemotherapy, except for significant gastrointestinal reactions, hypocellularity, and hair loss symptoms.

Conclusion: This report describes a rare case of penile metastasis from prostate cancer, which was initially misdiagnosed as Peyronie disease, indicating that clinicians need to improve their understanding and discrimination of this disease.

Keywords: penile metastasis; prostate cancer; Peyronie disease; case report.

Introduction

Prostate cancer, the second-most common type of cancer worldwide, is frequently observed in men aged >50 years. With current medical advances and improved screening methods, the detection rate of prostate cancer has become significantly higher than before. However, most patients are asymptomatic. The common sites of metastasis from prostate cancer are the lymph nodes and bones, less frequently the lungs, and very rarely the penis. Peyronie disease, also known as fibrous cavernositis of the penis or nodular cavernositis, is a benign chronic lesion in which the connective tissue of the penis fibroses into fibrous scars, plates, or calcifications and therefore loses its elasticity. The age of onset is approximately 55 to 60 years. Early clinical signs include penile sclerosis, painful erection, and penile deformity during erection, whereas late presentation often includes penile sclerosis, stable penile sclerosis during erection, and dysfunction during erection. We report a relatively rare case of prostate adenocarcinoma with penile metastasis that was misdiagnosed as penile cavernous sclerosis. The patient provided informed consent for publication of this case.

Case Presentation

A 68-year-old man was admitted to our hospital with a complaint of acute urinary retention and a hard node of approximately 2.0 cm in length that was palpable on the dorsal side of the penile root. He had no relevant medical history. Rectal examination showed that the prostate was enlarged, which we classified as degree II, and was tough in texture. No obvious nodules were palpable. The patient's prostate-specific antigen (PSA) level was 2 ng/mL. His urologic ultrasound suggested prostatic hyperplasia, sized approximately $4 \times 4.5 \times 5.5$ cm, and a residual bladder urine volume of 100 mL after urination. Penile ultrasonography revealed a high possibility of cavernous sclerosis. Other tests did not reveal any significant abnormalities. He was diagnosed with prostatic hyperplasia and Peyronie disease prior to surgery. The patient was scheduled to undergo a transurethral prostate resection.

Postoperative pathologic examination suggested prostate cancer with a Gleason score of 9 (4 + 5). Immunohistochemical results were as follows: high molecular weight cytokeratin (basal cell –), P63 (basal cell –), P504S (+), PSA (partial +), GATA3 (−), and Ki-67 (hot zone + approximately 30%). Because of the patient's previous good health and lack of contraindications to surgery and after full communication with the patient and his family, he was advised to return to the hospital within 2 to 3 months for radical prostate cancer surgery.

The patient was hospitalized again 2 months later with a complaint of progressive difficulty in passing urine and

Received: October 25, 2022. **Revised:** November 13, 2022. **Accepted:** November 15, 2022
© The Author(s) 2023. Published by Oxford University Press on behalf of The International Society of Sexual Medicine.
This is an Open Access article distributed under the terms of the Creative Commons Attribution Non-Commercial License (http://creativecommons.org/licenses/by-nc/4.0/), which permits non-commercial re-use, distribution, and reproduction in any medium, provided the original work is properly cited. For commercial re-use, please contact journals.permissions@oup.com

was scheduled to undergo radical prostate cancer surgery. On admission, the patient had a significantly larger dorsal penile nodule than that before admission. Adjunctive examinations were as follows. Lung computed tomography (CT) (128-slice spiral CT; GE) suggested multiple metastases in both lungs, and bone scan indicated possible bone metastases, mainly involving the eighth thoracic vertebrae and left sciatic bone. Repeat penile ultrasonography (Figure 1, A and B) (S2000; Siemens) suggested the possibility of Peyronie disease and did not detect penile metastasis of prostate cancer. Prostate magnetic resonance imaging (MRI) (3.0 T; GE) indicated locally advanced disease involving the seminal vesicles and neurovascular plexus bilaterally. However, the boundary of the posterior bladder wall was unclear, revealing possible metastatic invasion of the posterior bladder wall, left sciatic bone, multiple small lymph nodes in the bilateral inguinal region, and corpus cavernosum tubercles (Figure 1C).

After deliberation, we decided to perform a penile sclerosis puncture biopsy with 4 stitches. Biopsy pathology results suggested adenocarcinoma tissue infiltration in the fibrous tissue sample (Figure 1D), and the morphology, combined with the medical history and immunohistochemical results, was consistent with prostate adenocarcinoma metastasis. The final diagnosis was penile metastasis from prostate cancer. Immunohistochemical results were as follows (Figure 1, E and F): PSA (focal +), prostatic-specific acid phosphatase (+), Villin (−), CDX-2 (−), GATA3 (−), Ki-67 (+60%), and P63 (−).

In the context of prostate adenocarcinoma combined with penile, lung, and bone metastases, this patient was informed about treatments such as palliative sequential androgen deprivation therapy (ADT), penectomy, brachytherapy, or systemic chemotherapy. He opted for continuous ADT (abiraterone) and systemic chemotherapy (docetaxel and cisplatin). He was treated for 2 cycles with satisfactory results (multiple nodules in both lungs and hard nodes in the penis were significantly reduced), but the treatment was accompanied by chemotherapy side effects such as significant gastrointestinal reactions, leukopenia, and hair loss.

Discussion

Metastasis from prostate cancer to the penis is rare, with an incidence of approximately 0.3% to 0.5%.[1] To date, <500 cases have been reported in the literature. Eberth first described a case of penile metastasis in 1870.[2] Studies have shown that penile metastases may be a late manifestation of the natural course of metastatic prostate cancer and are usually associated with an extremely poor prognosis. The average survival of patients with penile metastases from prostate cancer is 9 months.[3] The longest survival reported in the literature is 5 years 2 months.[4] The clinical presentation of this group of patients often includes painless nodules (including the corpus cavernosum or glans), penile skin changes, abnormal penile erection, urinary retention, pelvic and perineal pain, dyspareunia, and hematuria.[5-7] In our case, the main presentation was limited to a recently presented painless nodule in the corpus cavernosum of the penis. Preoperative examination and ancillary tests did not reveal any signs of prostate cancer, and the patient was easily misdiagnosed with penile sclerosis. A local biopsy is a strong basis for the differential diagnosis of these 2 diseases. Prostate cancer progression and metastasis to other parts of the body without elevated PSA levels are rare phenomena but may occur,[8] as observed in our patient. One of the reasons for this may be neuroendocrine differentiation of adenocarcinoma. Neuroendocrine differentiation of prostate cancer is usually more aggressive and malignant and has a poor prognosis. In these cases, metastases to distal organs can occur early,[9] which poses some difficulties for diagnosis. We must carefully conduct physical examination and improve relevant radiologic imaging. Possible mechanisms of penile metastasis from prostate cancer are as follows[2,10,11]: direct invasion, implantation of previous devices, retrograde venous flow, and arterial or lymphatic dissemination. The most likely route of dissemination is thought to be retrograde venous blood flow because of the presence of significant traffic between the pelvic venous plexus and the deep dorsal penile veins. CT is important for the detection and diagnosis of secondary penile lesions.[2] Because of its high contrast with soft tissue, MRI allows for a more reliable assessment of leukocoria, cavernous and urethral invasion, differential diagnosis, and accurate staging of penile lesions. However, MRI did not play a role in this study; we could detect only the presence of cavernous nodules in the penis and did not consider metastasis. The current ultrasound detection results are not satisfactory. No metastasis was found on penile ultrasound before or after surgery. Therefore, the patient was misdiagnosed with cavernous sclerosis. This may be related to the experience of ultrasound physicians. In conclusion, ultrasound has no significant advantage in the characterization of penile tumors. Positron emission tomography–CT imaging is currently recommended as a noninvasive imaging technique for the detection of penile metastases.[12] As mentioned by Fan et al,[11] prostate-specific membrane antigen positron emission tomography–CT can detect penile metastases from prostate cancer at an early stage. The differential diagnosis should include primary penile tumors, sclerosing chancres, tuberculosis, and nonspecific inflammatory lesions.[2] Current treatment options include local excision, partial or total penile excision, bilateral orchiectomy, hormonal therapy, radiotherapy, and chemotherapy.[12] Partial or total penile excision is generally not preferred because of its negative psychological impact on the patient, but it may be considered when the patient has uncontrollable erections or pain.[13]

The main treatment for metastatic prostate cancer is ADT. Radiation therapy is also an effective treatment for improving local tumor control and relieving patients' local symptoms, thus improving the prognosis and quality of life. Similar to a study by Martz et al,[1] the patient chose ablative high-dose brachytherapy for penile metastases from prostate cancer, and he tolerated the overall treatment well, with rapid normalization of urinary function. Complete remission of penile tumors without any inguinal lymph node involvement and with almost no significant side effects was observed at the 6-month follow-up. Yet, radiotherapy has reportedly more side effects and can lead to glans ulceration and urethral stricture.[14] When fatal castration-resistant prostate cancer develops, new hormonal therapies (abiraterone and enzalutamide) and chemotherapies (docetaxel, cabazitaxel, etc) have a greater advantage in improving the survival of these patients.[2] Pal and Stein[15] reported similar results in a 73-year-old man with penile metastases from prostate cancer who underwent 24 cycles of cabazitaxel chemotherapy. However, chemotherapy regimens based on vincristine, cyclophosphamide, estramustine, gemcitabine, mitomycin,

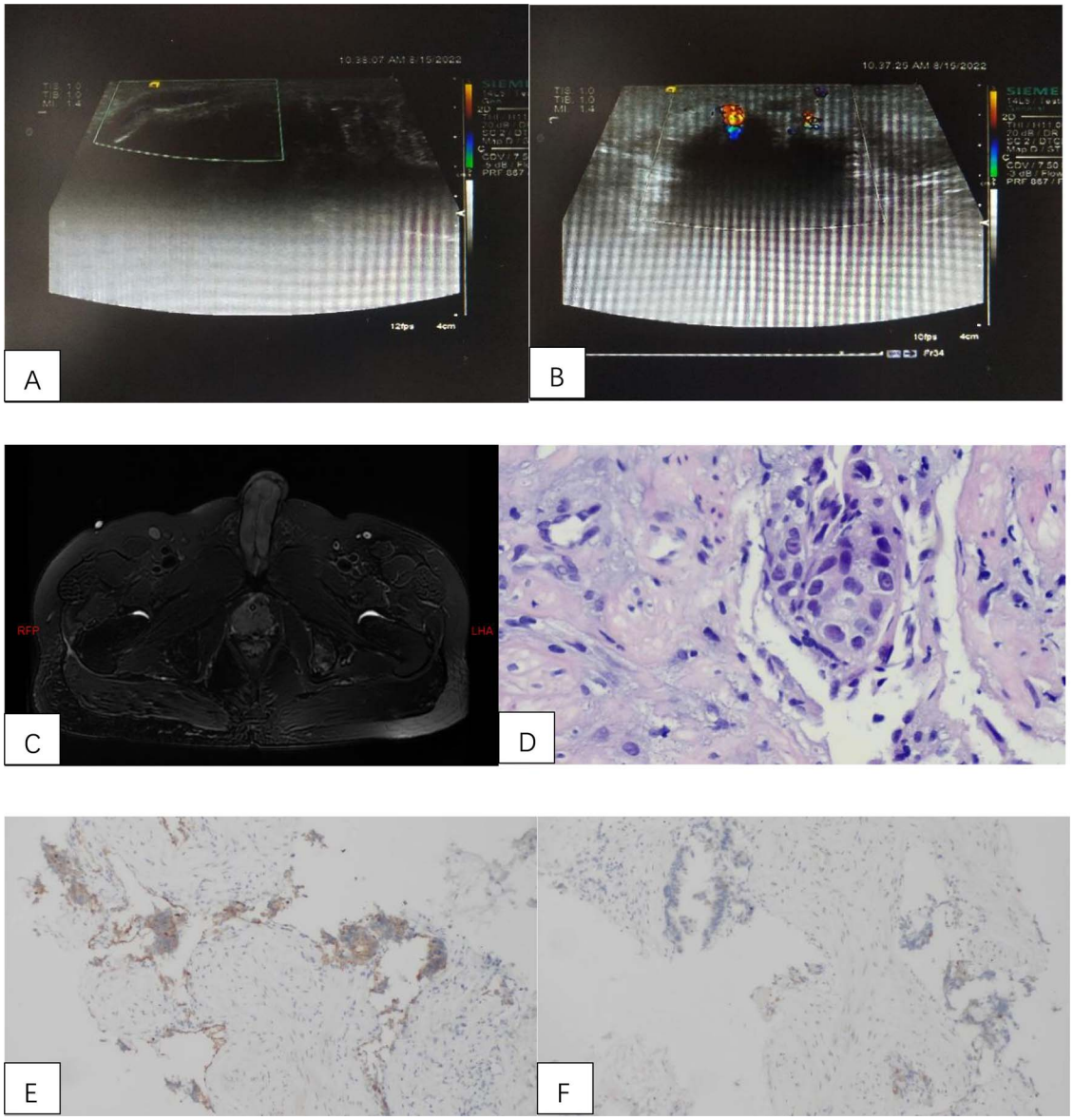

Figure 1. Ultrasound image of the penis: (A) there was thickening of the subcutaneous soft tissue at the base of the penis, and (B) fascicular blood flow signals were seen inside. (C) Prostate magnetic resonance imaging: 9 × 20–mm slightly long T2 signal nodule in the penile corpus cavernosum. Pathologic and immunohistochemical results of penile biopsy: (D) high magnification (×400), (E) prostatic-specific acid phosphatase (+), and (F) prostate-specific antigen (partial +).

and carboplatin have reportedly limited therapeutic efficacy and benefit for patients with prostate cancer.[16]

Funding

None declared.

Conflicts of interest: None declared.

References

1. Martz N, Benziane-Ouaritini N, Gautier M, et al. Brachytherapy for oligometastatic prostate cancer to the penis. *J Contemp Brachytherapy*. 2021;**13**(5):593-597.
2. Fiaschetti V, Liberto V, Claroni G, et al. Relevance of computed tomography and magnetic resonance imaging for penile metastasis after prostatectomy: uncommon case report and brief review of the literature. *Radiol Case Rep*. 2016;**11**(3):255–259.
3. Kamaleshwaran KK, BKP B, Jose R, Shinto AS. Penile metastasis from prostate cancer presenting as malignant priapism detected using gallium-68 prostate-specific membrane antigen positron emission tomography/computed tomography. *Indian J Nucl Med*. 2018;**33**(1):57–58.
4. Fujita N, Kurokawa R, Kaneshima R, et al. Patient with penile metastasis from prostate cancer and survival over 5 years: a case report with longitudinal evaluation using computed tomography and magnetic resonance imaging. *Radiol Case Rep*. 2021;**16**(6):1255–1258.
5. Center MM, Jemal A, Lortet-Tieulent J, et al. International variation in prostate cancer incidence and mortality rates. *Eur Urol*. 2012;**61**(6):1079–1092.
6. Messeguer F, Nagore-Enguidanos E, Requena C, Guillen-Barona C. An unusual presentation of penile metastasis from prostatic adenocarcinoma. *Int J Dermatol*. 2012;**51**(9):1133–1134.

7. Tatkovic A, McBean R, Schoeman J, Wong D. Prostate penile metastasis: incidence and imaging pattern on (68) Ga-PSMA PET/CT. *J Med Imaging Radiat Oncol*. 2020;**64**(4): 499–504.
8. Mohamadzadeh Rezaei M, Mostafa S, Ghoreifi A, et al. Penile metastasis originating from prostate adenocarcinoma: an unusual presentation with penile curvature. *Nephrourol Mon*. 2016;**9**(1):e41866.
9. Vamsi Parimi RG, Poropatich K, Yang XJ. Neuroendocrine differentiation of prostate cancer: a review. *Am J Clin Exp Urol*. 2014;**2**(4):273–285.
10. Anchal B, Neelam G, Neetu B, Rashi G. Metastatis to the glans penis from prostate adenocarcinoma—a rare presentation. *Int J Curr Res*. 2020;**12**(1):9335–9337.
11. Fan J, Liang H, Zhang X, et al. Case report: (18)F-PSMA PET/CT may improve the clinical management of penile metastases from prostate cancer. *Front Oncol*. 2021;**11**: 683343.
12. Elif Atag HSS, Kazaz SN. Response to cabazitaxel beyond 20 cycles in a patient with penile metastasis of prostate cancer: a case report. *Urol J*. 2016;**14**(1):2985–2988.
13. Kotake Y, Gohji K, Suzuki T, et al. Metastases to the penis from carcinoma of the prostate. *Int J Urol*. 2001;**8**(2):83–86.
14. Cante D, Franco P, Sciacero P, et al. Penile metastasis from prostate cancer: a case report. *Tumori*. 2014;**100**:14–16.
15. Pal SK, Stein CA. Prolonged therapy with cabazitaxel in an octogenarian with metastatic castration-resistant prostate cancer. *Clin Genitourin Cancer*. 2012;**10**(4):274–276.
16. Spinapolice EG, Fuccio C, Rubino B, et al. Penile metastases from bladder and prostate cancer detected by PET/CT: a report of 3 cases and a review of literature. *Clin Genitourin Cancer*. 2014;**12**:e155–e159.