hypothesis and one is examining its preventive effect for all cancers.

The CARET study reported here evolved from successful pilot programs. It is unique in that its participant group consists of both smokers and asbestos-exposed workers and also that its regimen is a combination of β-carotene and vitamin A. It includes women as well as men.

Experience with prevention trials has shown some important differences in design and conduct from treatment studies. These differences include the problems of recruiting large numbers of participants from populations not experiencing current illness and maintaining them on the study treatment for long periods of time while monitoring to protect them against side effects. In addition, there are management problems because of the scale of the operation. Participants in prevention trials are partners in research; they are not patients.

We expect CARET, combined with the results of the other two major trials, to determine by the end of the decade whether or not vitamin A and β-carotene can be recommended to occupationally defined high-risk groups and to the public as chemopreventive agents against lung cancer.

REFERENCES

1. Boring CC, Squires TS, Tong T: Cancer statistics, 1991. CA 1991; 41:19-36

2. Cancer Goals for Year 2000. Bethesda, Md, National Cancer Institute, 1986

3. Hammond EC, Selikoff IJ, Seidman H: Asbestos exposure, cigarette smoking, and death rates. Ann NY Acad Sci 1979; 330:473-490

4. Doll R, Peto J: Effects on health of exposure to asbestos. Health and Safety Committee Report. London, Her Majesty's Stationery Office, 1985

5. Berry G, Newhouse ML, Antonis P: Combined effect of asbestos and smoking on mortality from lung cancer and mesothelioma in factory workers. Br J Ind Med 1985; 42:12-18

6. Havlik RJ: Determinants of health—Cardiovascular risk factors. *In* Health Statistics on Older Persons. Washington, DC, US Department of Health and Human Services publication No. (PHS) 87-1409, 1986

7. Lubin JH, Blot WJ, Berrino F, et al: Modifying risk of developing lung cancer by changing habits of cigarette smoking. Br Med J 1984; 288:1953-1956

8. Omenn GS, Merchant J, Boatman E, et al: Contribution of environmental fibers to respiratory cancer. Environ Health Perspect 1986; 70:51-56

9. Nicholson WJ, Perkel G, Selikoff IJ: Occupational exposure to asbestos: Population at risk and projected mortality. Am J Ind Med 1982; 3:259-311

10. Wattenberg LW: Chemoprevention of cancer. Cancer Res 1985; 45:1-8

11. Bertram JS, Kolonel LN, Meyskens F: Rationale and strategies for chemoprevention of cancer in humans. Cancer Res 1987; 47:3012-3031

12. Meyskens FL Jr: Future strategies for cancer prevention trials. *In* Moon TE, Micozzi M (Eds): Nutrition and Cancer Prevention: Investigating the Role of Micronutrients. New York, NY, Marcel Dekker, 1989, pp 569-575

13. Omenn GS, Goodman G, Grizzle J, et al: CARET, the β-Carotene and Retinol Efficacy Trial to prevent lung cancer in asbestos-exposed workers and in smokers. Anticancer Drugs 1991; 2:79-86

14. Omenn GS: A double-blind randomized trial with β-carotene and retinol in persons at high risk of lung cancer due to occupational asbestos exposure and/or cigarette smoking. Public Health Rev 1988; 16:99-125

15. Grizzle J, Omenn G, Goodman G, et al: Design of the β-Carotene and Retinol Efficacy Trial (CARET) for chemoprevention of cancer in populations at high risk: Heavy smokers and asbestos-exposed workers. *In* Pastorino U, Hong WK (Eds): Chemoimmuno Prevention of Cancer. New York, Stuttgart, Thiemes Medical Publishers, 1991, pp 167-176

16. Peto R, Doll R, Buckley JD, Sporn MB: Can dietary β-carotene materially reduce human cancer rates? Nature 1981; 290:201-209

17. Goodman DS: Vitamin A and retinoids in health and disease. N Engl J Med 1984; 310:1023-1031

18. Lotan R, Lippman SM, Hong WK: Retinoid modulation of squamous cell differentiation and carcinogenesis. MD Anderson Cancer Bull 1991; 43:490-498

19. Weiss W, Boucot KR, Seidman H: The Philadelphia Pulmonary Neoplasms Research Project. Clin Chest Med 1982; 3:243-256

20. Fontana RS, Taylor WF: Screening for lung cancer: The Mayo Lung Cancer Project. *In* Mizel M, Correa P (Eds): Lung Cancer: Causes and Prevention. Deerfield Beach, Fla, Verlag Chemie International, 1985, pp 161-174

21. Gaziano JM, Manson JE, Ridker PM, et al: β-Carotene therapy for chronic stable angina. Circulation 1990; 82:S201

22. National Heart, Lung, and Blood Institute: Report of NHLBI Workshop on Role of Oxidized Lipoproteins in Atherogenesis. Circulation, in press

Sarcoidosis Presenting With an Unusual Erythematous Rash and Persistent Hypercalcemia

BRET L. BARNEY, MD
Portland, Oregon

SARCOIDOSIS HAS been defined as a multisystem granulomatous disorder of unknown etiology that most commonly affects young adults and most frequently manifests initially with bilateral hilar lymphadenopathy, pulmonary infiltration, and skin or eye lesions.[1]

I describe the case of a patient who had an unusual erythematous annular rash and persistent hypercalcemia as the first signs of the disease. This case illustrates the wide variety of clinical manifestations of this fascinating disease.

Report of a Case

The patient was a previously healthy 61-year-old man who five months before admission had acute iritis, which was treated with topical corticosteroids. Subsequently, intermittent low-grade fevers, drenching night sweats, fatigue, loss of appetite, and an 11-kg (25-lb) weight loss developed.

Three months before admission, laboratory evaluation by another physician yielded the following results: serum calcium 3.12 mmol per liter (12.5 mg per dl), albumin 32 grams per liter (3.2 grams per dl), urea nitrogen 12.85 mmol per liter (36 mg per dl), creatinine 159 μmol per liter (1.8 mg per dl), and a nonreactive rapid plasma reagin test. The erythrocyte sedimentation rate and results of thyroid function tests were within normal limits. The chest roentgenogram showed a small calcified granuloma in the left mid-lung and minimal change from a film obtained 12 years before. Results of renal function studies and serum calcium measurements were within normal limits three years earlier.

Six weeks before admission, a nonpruritic erythematous rash developed on the patient's back and spread to the chest and extremities. Ultrasound studies revealed hepatosplenomegaly, cholelithiasis, and a small right kidney. Laboratory results were as follows: serum calcium 2.82 mmol per liter (11.3 mg per dl), albumin 27 grams per liter (2.7 grams per dl), urea nitrogen 11.42 mmol per liter (32 mg per dl), and creatinine 184 μmol per liter (2.2 mg per dl). Flexible sigmoidoscopy, barium enema, esophagogastroduodenoscopy, and bone scan showed no evidence of malignancy. Tests for carcinoembryonic antigen, prostate-specific antigen, and serum protein electrophoresis revealed no abnormalities.

The patient had a history of hypertension that was well controlled with the use of atenolol, abdominal aortic aneurysm repair five years previously, and persistent edema of both wrists and hands for five years. He had a 70-pack-year history of cigarette smoking.

On admission to hospital the patient appeared chronically ill and cachectic. Physical examination revealed extensive skin lesions and bilateral nonpitting edema of the hands. No ophthalmologic abnormalities were detected. Many annular,

(Barney BL: Sarcoidosis presenting with an unusual erythematous rash and persistent hypercalcemia. West J Med 1992 May; 156:544-547)

From the Department of Medicine, St Vincent Hospital and Medical Center, Portland, Oregon.

Reprint requests to Bret L. Barney, MD, 2891 S 2000 E, Salt Lake City, UT 84109.

polycyclic, and dermally infiltrative lesions, 2 cm to 6 cm in diameter, were scattered over the back, chest, upper arms, and thighs (Figure 1). They were erythematous and minimally elevated, with palpable areas of central clearing. Older lesions appeared to have a hyperpigmented edge with mild superficial desquamation. The mucosa was not involved.

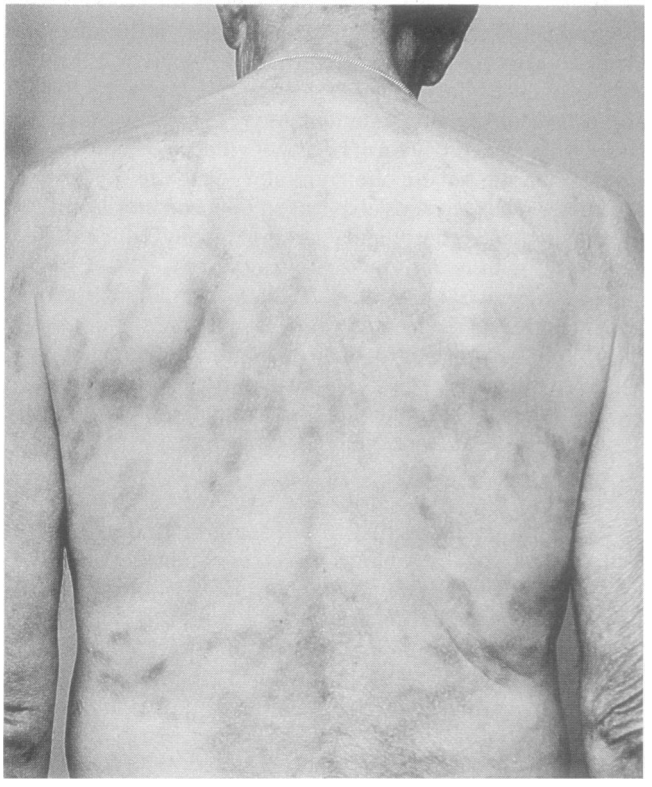

Figure 1.—Widespread erythematous annular lesions with central clearing are clearly visible.

Abnormal laboratory data were as follows: serum urea nitrogen 16.07 mmol per liter (45 mg per dl), creatinine 282 μmol per liter (3.2 mg per dl), calcium 3.49 mmol per liter (14.0 mg per dl), phosphorus 1.81 mmol per liter (5.6 mg per dl), albumin 31 grams per liter (3.1 grams per dl), aspartate aminotransferase 1.35 μkat per liter (81 IU per liter), and alkaline phosphatase 1.92 μkat per liter (115 IU per liter). Urinalysis showed 1+ calcium oxalate crystals and no protein, bacteria, or cellular elements. The electrocardiogram revealed no serious abnormalities and a normal QT interval.

The chest roentgenogram showed mild bilateral diffuse perihilar interstitial infiltrates in a reticular pattern without adenopathy. Computed tomography of the chest and abdomen revealed minimal bullous disease in the apex of the right lung, a small calcified granuloma in the left upper lobe of the lung, a few scattered calcified splenic granulomas in the spleen, and atrophy of the right kidney.

Therapy was begun with vigorous intravenous saline hydration and furosemide diuresis. Prednisone, 20 mg per day orally, and a three-day course of etidronate sodium, 325 mg per day intravenously, were then added to the regimen.

Additional laboratory results were as follows: intact parathyroid hormone level determined by immunoradiometric assay was less than 0.2 pmol per liter (normal < 1.5), parathyroid hormone-related peptide was undetectable, human immunodeficiency virus antibody test was negative, serum angiotensin-converting enzyme level was 158 U per liter (normal range 8 to 52), and 1,25-dihydroxyvitamin D level was 130 pmol per liter (normal range, 36 to 120). Purified protein derivative and control tests were nonreactive.

A skin biopsy showed many noncaseating granulomas in the dermis and subcutaneous tissue (Figure 2). Special stains for fungal and acid-fast organisms were negative. A bone marrow biopsy showed no abnormalities.

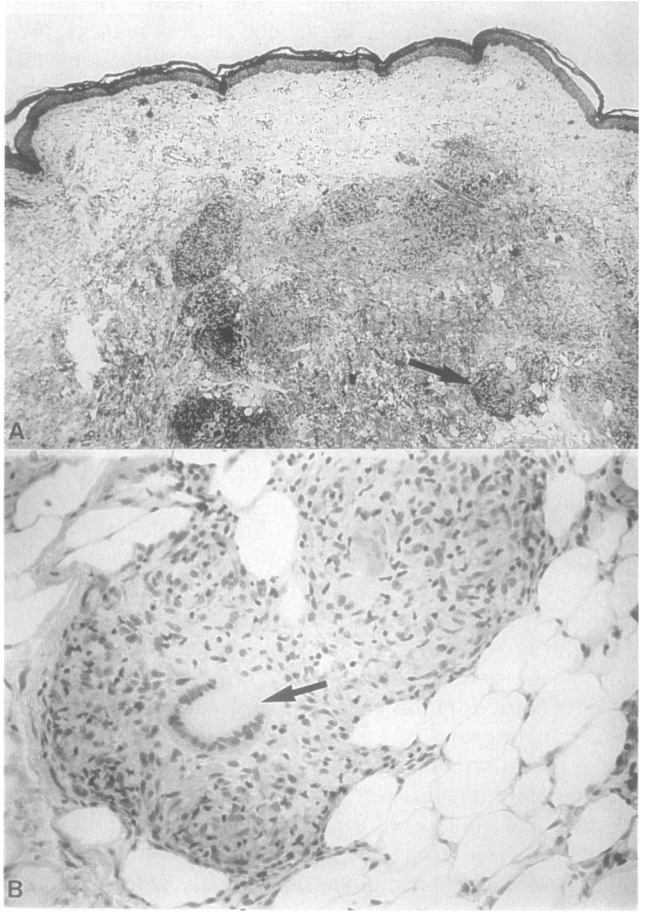

Figure 2.—**A,** Photomicrograph of the skin biopsy specimen shows many noncaseating granulomas **(arrow)** throughout the dermis consistent with sarcoid (original magnification × 100). **B,** Magnified view shows a sarcoid granuloma with multinucleated giant cells **(arrow),** epithelioid histiocytes, and admixed lymphocytes (original magnification × 400).

The patient remained afebrile and had increased strength and return of appetite. Serum calcium and creatinine levels decreased to 2.67 mmol per liter (10.7 mg per dl) and 185 μmol per liter (2.1 mg per dl), respectively. The patient was discharged from the hospital on a regimen of prednisone, 40 mg per day orally, and etidronate, 1 gram per day orally. A diagnosis of sarcoidosis was considered probable.

Three weeks later, the patient had regained 4.5 kg (10 lb) and there was generalized clearing of the skin lesions, particularly on the back. Serum calcium, creatinine, and 1,25-dihydroxyvitamin D levels were within normal limits. Etidronate therapy was discontinued, and gradual withdrawal from prednisone was begun.

Discussion

Sarcoidosis may involve any organ but commonly affects the lungs, eyes, mucous membranes, skin, liver, spleen,

musculoskeletal system, and heart. The diagnosis is established by compatible clinicoradiographic findings supported by histologic evidence of widespread epithelioid cell granulomas, preferably in more than one organ.

In a worldwide review of 3,676 patients with sarcoidosis, 68% of patients were under 40 years of age when first seen, and 80% had evidence of hilar lymphadenopathy.[2] Constitutional symptoms may occur in more than a third of patients; weight loss, fatigue, and fever are the most common.[3]

As many as a third of patients with sarcoidosis have ocular inflammatory disease, and the sudden onset of redness, photophobia, and blurred vision are often the presenting features.[4] In a university-based population, 5.5% of patients with uveitis had associated systemic sarcoidosis.[5] The most frequent manifestation is anterior uveitis, but patients may rarely have isolated posterior uveitis, optic nerve inflammation, or orbital disease.[4] Vigorous therapy with topical or systemic corticosteroids should be initiated to prevent the complications of glaucoma and blindness.

Persistent hypercalcemia is observed in only 2% of patients with sarcoidosis and is usually associated with severe and widespread disease.[6] It represents one of the firm indications for steroid therapy because of the risk of renal impairment, nephrocalcinosis, and nephrolithiasis.[7] Renal dysfunction resulting solely from granulomatous infiltration is rare. Hypercalcemia can depress the glomerular filtration rate directly.[8]

The presumed mechanism of hypercalcemia is the extrarenal conversion of 25-hydroxyvitamin D to 1,25-dihydroxyvitamin D by macrophages in sarcoid granulomas.[9-11] This results in the overproduction of 1,25-dihydroxyvitamin D, which augments calcium absorption by the gastrointestinal tract.[12] Administration of low doses of corticosteroids generally causes prompt reduction of the circulating level of 1,25-dihydroxyvitamin D and return of the serum level of calcium to the normal range.[13]

Therefore, the level of 1,25-dihydroxyvitamin D is often elevated and the level of parathyroid hormone is almost always suppressed in patients with sarcoid-related hypercalcemia. This is in contrast to the substantially reduced level of 1,25-dihydroxyvitamin D in patients with hypercalcemia resulting from malignancy.[14]

Cutaneous manifestations of sarcoidosis vary widely.[15-18] The lesions are usually asymptomatic but may rarely be pruritic.[19] The presence of cutaneous manifestations is often important because a skin biopsy may establish the diagnosis in unsuspected cases.

Nonspecific lesions represent hypersensitivity reactions without granulomas. The most common is erythema nodosum, found in 17% of sarcoid patients worldwide.[2] Erythema multiforme is rarely seen.

Specific lesions, found in 9% of sarcoid patients worldwide,[2] have characteristic histologic findings with noncaseating granulomas. Common lesions include lupus pernio, persistent plaques, papules, subcutaneous nodules, scar infiltrates, and mucous membrane lesions.

Lupus pernio consists of violaceous and often large and disfiguring plaques or thickenings that can involve the nose, cheeks, earlobes, fingers, and knees. Persistent plaques are usually large, purplish brown, dark, and nontender lesions. They are commonly located on the limbs, buttocks, and abdomen and can have irregular, annular, or serpiginous shapes. Papules may erupt suddenly and appear in crops scattered over the face and limbs. Mucous membrane lesions are small and involve the mouth and conjunctivae.

Other uncommon or rare variants include skin ulcerations,[20] nonscarring alopecia,[21] and erythema multiforme-like target lesions.[22] Hypopigmented macules, ichthyosiform, and psoriasiform lesions are also uncommon and usually present in African-American patients.[23]

Erythrodermic or widespread erythematous lesions have rarely been described; most are minimally infiltrative and coalesce into sheets of dermatitis.[21,24] The lesions in this patient clinically resembled a deep gyrate erythema, which are deep dermal nongranulomatous lesions of unknown cause.[25] They also can form rings with indurated borders and central clearing but are often migratory with rapidly advancing edges. These lesions also lacked the characteristic wood grain appearance of erythema gyratum repens, which is often associated with underlying malignancy.

The differential diagnosis of annular sarcoidosis should also include tuberculoid leprosy, granuloma annulare, tertiary syphilis, lupus erythematosus, and lymphoma cutis.[18]

My patient's lesions were unusual in that they cleared so rapidly in response to therapy. Sarcoid plaques are typically slow to resolve and are often resistant to therapy.[15-18]

Summary

Sarcoidosis is a multisystem disease that often presents with constitutional symptoms and ocular and skin manifestations. The chest roentgenogram may show no abnormalities or only diffuse interstitial disease. The serum calcium level is uncommonly persistently elevated and responds rapidly to low-dose corticosteroid therapy. The level of 1,25-dihydroxyvitamin D is often elevated, and the level of parathyroid hormone is almost always suppressed. Skin manifestations vary considerably and may appear in an unusual fashion. A skin biopsy may often be essential in the diagnosis of sarcoidosis.

REFERENCES

1. James DG, Turiaf J, Hosoda Y, et al: Description of sarcoidosis: Report of the subcommittee on classification and definition. Ann NY Acad Sci 1976; 278:742

2. James DG, Turiaf J, Hosoda Y, et al: A worldwide review of sarcoidosis. Ann NY Acad Sci 1976; 278:321-333

3. Mayock RL, Bertrand P, Morrison CE, Scott JH: Manifestations of sarcoidosis—Analysis of 145 patients, with a review of nine series selected from the literature. Am J Med 1963; 35:67-89

4. Obenauf CD, Shaw HE, Sydnor CF, Klintworth GK: Sarcoidosis and its ophthalmic manifestations. Am J Ophthalmol 1978; 86:648-655

5. Rosenbaum JT: Uveitis—An internist's view. Arch Intern Med 1989; 149:1173-1176

6. Goldstein RA, Israel HL, Becker KL, Moore CF: The infrequency of hypercalcemia in sarcoidosis. Am J Med 1971; 51:21-30

7. Muther RS, McCarron DA, Bennett WM: Renal manifestations of sarcoidosis. Arch Intern Med 1981; 141:643-645

8. Benabe JE, Martinez-Maldonado M: Hypercalcemic nephropathy. Arch Intern Med 1978; 138:777-779

9. Mason RS, Frankel T, Chan Y, Lissner D, Posen S: Vitamin D conversion by sarcoid lymph node homogenate. Ann Intern Med 1984; 100:59-61

10. Barbour GL, Coburn JW, Slatopolsky E, Norman AW, Horst RL: Hypercalcemia in an anephric patient with sarcoidosis: Evidence for extrarenal generation of 1,25-dihydroxyvitamin D. N Engl J Med 1981; 305:440-443

11. Adams JS, Gacad MA: Characterization of 1 alpha-hydroxylation of vitamin D_3 by cultured alveolar macrophages from patients with sarcoidosis. J Exp Med 1985; 161:755-765

12. Insogna KL, Dreyer BE, Mitnick M, Ellison AF, Broadus AE: Enhanced production rate of 1,25-dihydroxyvitamin D in sarcoidosis. J Clin Endocrinol Metab 1988; 66:72-75

13. Sandler LM, Winearls CG, Fraher LJ, Clemens TL, Smith R, O'Riordan JLH: Studies of the hypercalcaemia of sarcoidosis: Effect of steroids and exogenous vitamin D_3 on the circulating concentrations of 1,25-dihydroxy vitamin D_3. Q J Med 1984; 53:165-180

14. Stewart AF, Horst R, Deftos LJ, Cadman EC, Lang R, Broadus AE: Biochemical evaluation of patients with cancer-associated hypercalcemia. N Engl J Med 1980; 303:1377-1383

15. James DG: Dermatologic aspects of sarcoidosis. Q J Med 1959; 28:109-124
16. Elgart ML: Cutaneous lesions of sarcoidosis. Prim Care 1978; 5:249-262
17. Sharma OP: Cutaneous sarcoidosis: Clinical features and management. Chest 1972; 61:320-325
18. Moschella SL: Diseases of the mononuclear phagocytic system (the so-called reticuloendothelial system)—Sarcoidosis, chap 16, *In* Moschella SL, Hurley HJ (Eds): Dermatology—Vol 1, 2nd Ed. Philadelphia, Pa, WB Saunders, 1985, pp 910-919
19. Fong YW, Sharma OP: Pruritic maculopapular skin lesions in sarcoidosis. Arch Dermatol 1975; 111:362-364
20. Gupta AK, Haberman HF, From GLA, Lipa M: Sarcoidosis with extensive cutaneous ulcerations—Unusual clinical presentation. Dermatologica 1987; 174:135-139
21. Greer KE, Harman LE, Kayne AL: Unusual cutaneous manifestations of sarcoidosis. South Med J 1977; 70:666-668
22. Beacham BE, Schuldenfrei J, Julka SS: Sarcoidosis presenting with erythema multiforme-like cutaneous lesions. Cutis 1984; 33:461-463
23. Minus HR, Grimes PE: Cutaneous manifestations of sarcoidosis in blacks. Cutis 1983; 32:361-363, 372
24. Wigley JEM, Musso LA: A case of sarcoidosis with erythrodermic lesions—Treatment with calciferol. Br J Dermatol 1951; 63:398-407
25. Burgdorf WHC, Goltz RW: Figurate erythemas, chap 88, *In* Fitzpatrick TB, Eisen AZ, Wolff K, Freedberg IM, Austen KF (Eds): Dermatology in General Medicine—Vol 1, 3rd Ed. New York, NY, McGraw-Hill, 1987, pp 1010-1018

Primary Biliary Cirrhosis and Adult Celiac Disease

PATRICK GINN, MD
RONALD D. WORKMAN, MD
Fresno, California

OVERLAPPING SIGNS and symptoms of two relatively rare disorders, celiac disease and primary biliary cirrhosis (PBC), may result in delays in establishing the diagnosis of both conditions. In a patient with diagnosed celiac disease, persistently abnormal results of liver function tests after symptomatic improvement on a gluten-free diet should arouse suspicion of primary liver disease.

Report of a Case

The patient, a 59-year-old airline pilot, was seen in September 1988 because of persistently abnormal results of liver function tests dating to 1980 and with the chief complaint of intermittent diarrhea and weight loss of 18 months' duration. The patient had 8 to 20 pale, foul-smelling, nonbloody bowel movements daily associated with bloating after meals and borborygmi. On occasion the diarrhea occurred during the night and had not been associated with abdominal discomfort. Despite what the patient perceived as an adequate dietary intake, he had lost about 9 kg (20 lb) during the first six months of his diarrhea. His weight had been relatively stable for a year since then. There had been no fevers, pruritus, or abdominal pain. He did not use laxatives, and he had not traveled outside of the country. He had not had exposure to water suspected of harboring *Giardia* species, nor had he received antibiotics in the past several years.

His medical history was unremarkable other than having persistently abnormal liver function for six years. He had not had previous abdominal operations or radiation exposure. He took no medications other than occasional vitamins, and there was no notable history of alcohol use. He had been a ten pack-year smoker. There was no family history of gastrointestinal diseases. There were no symptoms suggestive of extraintestinal manifestations of inflammatory bowel disease.

On physical examination, he was afebrile, weighed 79 kg (174 lb), was 177 cm (5 ft 10 in) tall, and had no skin stigmata of end-stage liver disease. His abdomen was nontender, and there was no evidence of organomegaly. His stool was pale, grossly fatty, and negative for occult blood. A sigmoidoscopic examination was unremarkable, as was histologic evaluation of rectosigmoid mucosal biopsies. Stool culture and ova and parasite studies were negative. The hemoglobin level was 132 grams per liter (13.2 grams per dl).

Laboratory data since 1982 were reviewed. His alkaline phosphatase, aspartate aminotransferase (AST), and alanine aminotransferase (ALT) levels had been elevated during that time, minimally at first and gradually rising thereafter (Table 1). The serum bilirubin value was normal. An upper gastrointestinal x-ray study with small bowel follow-through revealed coarsening of duodenal folds, some narrowing of the descending duodenum, and dilatation of the small bowel with a mucosal pattern compatible with sprue. Upper gut endoscopy was then done. Excellent-quality biopsy specimens of small intestine were obtained, revealing total villous atrophy with glandular crypt hyperplasia and intraepithelial lymphocytes consistent with celiac disease (Figure 1). The patient was placed on a gluten-free diet, and his steatorrhea resolved shortly thereafter. His weight had increased 3.2 kg (7 lb), and his subjective feeling of strength was increased. Examination of his stool showed no evidence of fat.

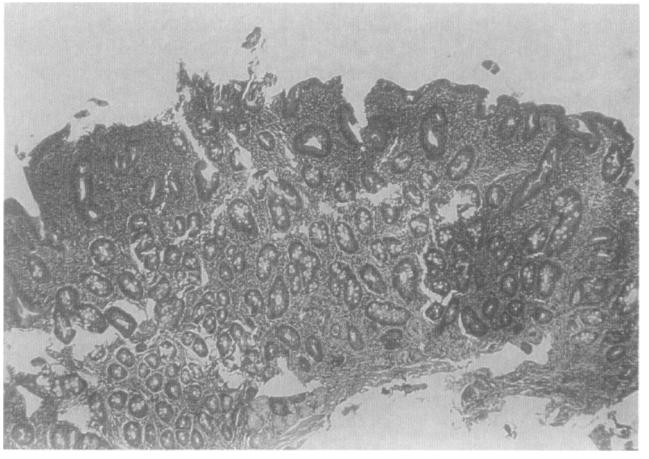

Figure 1.—The small intestine mucosal biopsy shows total villous atrophy. The mucosal glandular crypts have a hyperplastic appearance and are elongated. The lamina propria contains an increased amount of chronic inflammatory cells with an increased number of intraepithelial lymphocytes at the absorptive surface (hematoxylin and eosin stain; original magnification × 25).

The results of follow-up liver function tests initially were nearly normal in 1989 as well. Despite the resolution of his steatorrhea and gradually increasing body weight, however, liver function test levels began to rise thereafter. In January 1990 his alkaline phosphatase level was 442 units per liter. An antimitochondrial antibody test was positive at a dilution of 1:4,096 (normal <1:40). His antismooth muscle antibody test was trace positive at a dilution of 1:64 (normal <1:40). A needle liver biopsy was done a month later that showed findings of primary biliary cirrhosis (Figure 2) and precirrhotic bridging fibrosis (Figure 3). The liver biopsy showed no evidence of sclerosing cholangitis. At that time

(Ginn P, Workman RD: Primary biliary cirrhosis and adult celiac disease. West J Med 1992 May; 156:547-549)

From the Community Hospitals of Central California, Fresno, California.
Reprint requests to Ronald D. Workman, MD, Department of Pathology, Clinical Laboratories, PO Box 1232, Fresno, CA 93715.