

## **Case report**

# **Acquired sideroblastic anaemia after aplastic anaemia caused by D-penicillamine therapy for rheumatoid arthritis**

A C P RAMSELAAR, A W DEKKER, O HUBER-BRUNING, AND  
J W J BIJLSMA

*From the Departments of Rheumatology and Haematology, University Hospital Utrecht, The Netherlands*

**SUMMARY** A 68 year old man with rheumatoid arthritis developed marrow aplasia during D-penicillamine treatment. Recovery of granulopoiesis and erythropoiesis was ineffective with features of a secondary sideroblastic anaemia. Absence of megakaryopoiesis persisted. Therapeutic measures failed, and the patient finally died. These events illustrate a haematopoietic stem cell injury induced by D-penicillamine.

**Key words:** marrow aplasia, haematopoietic stem cell injury.

D-Penicillamine was introduced in the treatment of rheumatoid arthritis by Jaffe in 1964.<sup>1</sup> Nowadays, the efficacy of D-penicillamine has been established,<sup>2,3</sup> though its use is limited by the occurrence of adverse effects, some of which are potentially hazardous.<sup>4</sup> Haematological toxicity is the most serious of the untoward effects which may be produced.<sup>2,5</sup> Fatal reactions are associated predominantly with bone marrow aplasia. Of the 18 deaths associated with D-penicillamine treatment reported to the Committee on Safety of Medicines in the UK between January 1964 and December 1977, 14 were due to blood dyscrasias, half of them marrow aplasia.<sup>5</sup>

As far as sideroblastic anaemia is concerned no case reports have so far been published about this effect during the use of D-penicillamine in the treatment of rheumatoid arthritis. In the treatment of primary biliary cirrhosis with 1000 mg D-penicillamine daily for one year, however, sideroblastic anaemia has been noted.<sup>6</sup>

We report a case of acquired sideroblastic anaemia which evolved after a phase of bone

marrow aplasia induced by D-penicillamine treatment for rheumatoid arthritis.

## **Case report**

A 68 year old Indonesian man had a five year history of seropositive erosive rheumatoid arthritis. He was treated with a variety of non-steroidal anti-inflammatory drugs and from May 1982 with indomethacin. Treatment with antimalarials was not successful. Because of active polyarthritis with progressive erosive changes he was started on D-penicillamine 250 mg a day in August 1983. His rheumatoid arthritis responded well to this treatment and after six months there was no active synovitis.

In April 1984 leucopenia with agranulocytosis and thrombocytopenia was noted (Fig. 1). Physical examination showed petechiae and purpura on his legs. The drugs (D-penicillamine and indomethacin) were stopped immediately. There was no lymphadenopathy, nor splenomegaly. The erythrocyte sedimentation rate was 107 mm/1st h, haemoglobin 8.8 g/100 ml (88 g/l); mean cell volume 85 fl; mean cell haemoglobin 32 pg; mean cell haemoglobin concentration 37 g/100 ml (370 g/l); reticulocytes 3%, leucocytes 1500/mm<sup>3</sup> ( $1.5 \times 10^9/l$ ); 1% bands and 8% segmented neutrophils, 86% lymphocytes,

Accepted for publication 24 June 1986.

Correspondence to Dr J W J Bijlsma, Department of Rheumatology, University Hospital Utrecht, Catharijnesingel 101, 3511 GV Utrecht, The Netherlands.

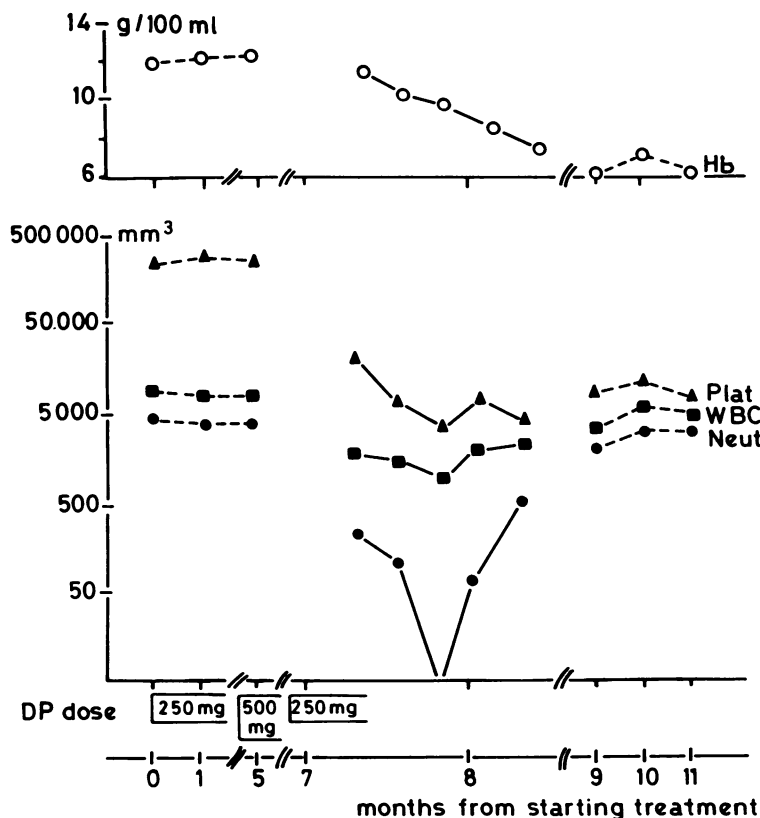


Fig. 1 Marrow depression developing in the seventh month of treatment with D-penicillamine, followed by partial recovery with persisting thrombocytopenia and anaemia. SI conversion:  $\text{cells/mm}^3 \times 10^9 = \text{cells/l}$ . Hb=haemoglobin; Plat=platelets; WBC=white blood cells; Neut=neutrophils; DP=D-penicillamine.

and 5% monocytes. In the peripheral blood smear no abnormalities were found. The platelet count was  $5000/\text{mm}^3$  ( $5 \times 10^9/\text{l}$ ). Serum creatinine, potassium, and proteins were normal, as were his liver function tests. Serum iron was  $27 \mu\text{mol/l}$ , latent iron binding capacity  $7 \mu\text{mol/l}$ , and saturation 79%. Bone marrow aspiration and biopsy showed aplasia with 80% fat tissue with only scarce erythropoietic and granulopoietic cells, absence of megakaryocytes, and a relative increase of lymphocytes, plasma cells, and mast cells.

A diagnosis of aplastic anaemia was made. Supportive care was given, including red blood cell transfusions and platelet transfusions when necessary. No signs of infection were observed. There was a flare of his rheumatoid arthritis, for which analgesics (paracetamol) were required. The leucopenia resolved after two months, but severe anaemia and thrombocytopenia persisted. The following findings were noted: haemoglobin  $7.2 \text{ g/100 ml}$  ( $72 \text{ g/l}$ ); reticulocytes 8%; white cells  $5300/\text{mm}^3$  ( $5.3 \times 10^9/\text{l}$ ) with 66% neutrophils, 20% band forms, 22% lymphocytes, and 8% monocytes; platelets

$12\,000/\text{mm}^3$  ( $12 \times 10^9/\text{l}$ ). Repeated bone marrow examination showed hypercellularity with active erythropoiesis and granulopoiesis, but no recovery of the megakaryocytes. Ring sideroblasts accounted for more than 30% of all nucleated red cells in the bone marrow. These features were suggestive of a myelodysplastic syndrome, specifically an acquired sideroblastic anaemia. No chromosomal abnormalities were found after cytogenetic examination of marrow and blood.

In October 1984 he was readmitted because of fever and rigors. Cultures from blood and urine yielded *Proteus mirabilis*. The source of origin was not found. Anaemia and thrombocytopenia persisted, for which frequent blood cell transfusions and platelet transfusions were necessary. The neutrophil count remained in the normal range. In December 1984 the aspirated bone marrow disclosed hyperplastic erythropoiesis with some degree of dyserythropoiesis; there was a moderately active toxic granulopoiesis with a left shift and sporadic blast cells. The number of sideroblasts was again increased with absence of megakaryocytes.

Because of persisting thrombocytopenia treatment with a short course of high dose prednisone was tried without any improvement. Consecutive treatment with high dose pyridoxine, folate, and oxymetholone was given, also without success.

A postmortem examination showed that the bone marrow was hypercellular with a relative plasmacytosis and the presence of many ring sideroblasts. Necropsy also disclosed diffuse bronchopneumonia and destruction of several lumbar vertebrae due to osteomyelitis, probably caused by the infection with *P. mirabilis*.

## Discussion

Thrombocytopenia, neutropenia, and proteinuria are frequently observed side effects of D-penicillamine, which require frequent surveillance with blood and urine checks. It is our policy to perform complete blood counts including platelet counts every two weeks for the first six months and monthly thereafter. Patients are alerted to the need for this surveillance but sometimes omit to visit the outpatient clinic.

This patient developed a bone marrow aplasia seven months after starting D-penicillamine treatment. The total dose of D-penicillamine at that time was 81 g (mean dose 360 mg/day). We consider this aplasia to have been induced by D-penicillamine since this drug has definitely been associated with aplastic anaemia.<sup>7</sup> The risk of haematological toxicity associated with indomethacin is very low.<sup>8</sup>

The subsequent partial recovery with development of a sideroblastic anaemia is a remarkable phenomenon. At that time the bone marrow was hypercellular with marked ring sideroblastic changes and persisting absence of megakaryocytopoiesis. These features indicate a stem cell injury which appeared to be induced by D-penicillamine. Apart from bone marrow depression sideroblastic anaemia

alone has been reported as a side effect of D-penicillamine treatment for primary biliary cirrhosis. Secondary sideroblastic anaemia has also been described in association with rheumatoid arthritis.<sup>9</sup> In these reports, however, there were no features of stem cell injury such as the preceding aplastic phase and persistent thrombocytopenia in our patient.

With regard to management treatment with D-penicillamine should be discontinued immediately when haematological abnormalities are detected. A trial of pyridoxine could be given in acquired sideroblastic anaemias, but responses are known to be sporadic. Treatment with androgenic steroids may be useful and could be tried in patients who are transfusion dependent. Both therapies failed in our patient.

This case again underscores the fact that myelotoxicity is a potentially hazardous side effect of D-penicillamine. Frequent haematological surveillance is mandatory because recovery of bone marrow function after prompt discontinuation of this drug is possible.<sup>7</sup>

## References

- 1 Jaffe I A. Rheumatoid arthritis with arteritis—a report of a case treated with penicillamine. *Ann Intern Med* 1964; **61**: 556–63.
- 2 Multicentre Trial Group. Controlled trial of D-penicillamine in severe rheumatoid arthritis. *Lancet* 1973; **i**: 275–80.
- 3 Baum J. The use of penicillamine in the treatment of rheumatoid arthritis and scleroderma. *Scand J Rheumatol [Suppl]* 1979; **28**: 65–70.
- 4 Hill W F H. Penicillamine in rheumatoid arthritis. Adverse effect. *Scand J Rheumatol [Suppl]* 1979; **28**: 94–9.
- 5 Kay A G L. Myelotoxicity of D-penicillamine. *Ann Rheum Dis* 1979; **38**: 232–6.
- 6 Sullivan A, Burakoff R, Weintraub I R. Sideroblastic anaemia associated with penicillamine therapy. *Arch Intern Med* 1981; **141**: 1713–4.
- 7 Heimpel H, Heit W. Drug-induced aplastic anaemia: clinical aspects. *Clin Haematol* 1980; **3**: 641–62.
- 8 Inman W H W. Fatal bone marrow depression with special reference to phenylbutazone and oxyphenbutazone. *Br Med J* 1977; **i**: 2500–5.
- 9 McGibbon B H, Mollin D H. Sideroblastic anaemia in man. *Br J Haematol* 1965; **1**: 59–69.