Since January 2020 Elsevier has created a COVID-19 resource centre with free information in English and Mandarin on the novel coronavirus COVID-19. The COVID-19 resource centre is hosted on Elsevier Connect, the company's public news and information website.

Elsevier hereby grants permission to make all its COVID-19-related research that is available on the COVID-19 resource centre - including this research content - immediately available in PubMed Central and other publicly funded repositories, such as the WHO COVID database with rights for unrestricted research re-use and analyses in any form or by any means with acknowledgement of the original source. These permissions are granted for free by Elsevier for as long as the COVID-19 resource centre remains active.

Clinical Imaging 81 (2022) 92–95

Contents lists available at ScienceDirect

Clinical Imaging

journal homepage: www.elsevier.com/locate/clinimag

Neuroradiology

Brain death in a vaccinated patient with COVID-19 infection

Jennifer M. Watchmaker *, Puneet B. Belani

Department of Diagnostic, Molecular and Interventional Radiology, Icahn School of Medicine at Mount Sinai, One Gustave L. Levy Pl, Box 1234, New York, NY 10029, USA

ARTICLE INFO

Keywords:
COVID-19
Neuroradiology
Brain death
Immunocompromised
Systemic lupus erythematosus

ABSTRACT

We present a case of brain death in a vaccinated, immunocompromised patient who presented with COVID-19 pneumonia. Imaging was characterized by diffuse cerebral edema, pseudo-subarachnoid hemorrhage, and no antegrade flow above the terminal internal carotid arteries. To our knowledge, this is the first case report with such findings in a vaccinated patient.

1. Introduction

It has become increasingly evident that COVID-19 is not just a respiratory illness, but is implicated in severe vascular disease that can affect many organ systems including the brain, heart, and kidneys. While the exact mechanism for increased stroke risk among hospitalized patient with COVID-19 is unknown, there is amassing data that shows this patient group as having a uniquely elevated stroke risk, even when compared to patients with similar infectious conditions such as influenza infection and sepsis [1–5]. In a study published earlier in the pandemic, which included 214 patients from Wuhan, China, 5.7% of patients with severe infection, as defined by the American Thoracic Society and Infectious Disease Society of America Criteria [6], suffered from acute cerebrovascular disease (CVD), and 14% from impaired consciousness including somnolence, stupor, and coma [7]. More recent data collected as part of the American Heart Association COVID-19 cardiovascular disease registry, which included data on over 20,000 hospitalized patients with COVID-19 across the United States, found that 1.4% of all hospitalized patients with COVID-19 had a stroke confirmed by diagnostic imaging, with 52.7% of the patients experiencing ischemic stroke, 2.5% with transient ischemic attack, and 45.2% with hemorrhagic or unspecified stroke type [8].

Neuroimaging plays a vital role in determining not only the diagnosis of patients with acute CVD, but also in the prognosis determination of patients with acute CVD. In the setting of suspected brain death, CT angiography demonstrating both arrest of contrast medium at the level of the internal carotid and vertebral arteries and associated absence of venous blood return is sufficient to pronounce brain death in certain countries [9–12]. Diagnostic imaging also has the benefit of simplicity and rapidity, unlike conventional clinical testing that often requires numerous reassessments conducted hours apart and aerosolizing procedures such as apnea testing [9,13–16].

In this report, we detail the clinical course and neuroimaging findings of a critically ill COVID-19 pneumonia patient, who ultimately suffered catastrophic intracranial events and imaging and clinical findings compatible with brain death.

2. Case description

A 60-year-old woman with medical history notable for type II diabetes, hypertension, atrial fibrillation on apixaban, and systemic lupus erythematosus, treated with a combination of steroids, rituximab, and methotrexate (25 mg per week, held upon hospital admission), presented on May 2, 2021 with a one-week history of fever (T_{max} 104 F) and productive cough. Notably, the patient had been vaccinated with an mRNA vaccine (Pfizer, New York, NY) receiving the second dose on February 18, 2021. She underwent routine COVID testing in anticipation of screening colonoscopy procedure and tested positive on April 1, 2021; she was asymptomatic at that time. She subsequently developed the aforementioned symptoms on April 24, 2021 prompting hospital presentation. PCR testing for COVID-19 on day of hospital presentation returned positive. The patient was negative for SARS-CoV-2 antibodies upon hospital admission on May 3, 2021. Blood cultures taken at admission and on hospital day 6, 9, 14, 18, 21, 23, 25, 27, 29 were all negative.

* Corresponding author at: Department of Diagnostic, Molecular and Interventional Radiology, Icahn School of Medicine at Mount Sinai, One Gustave L. Levy Place, New York 10029, NY, USA.

E-mail address: Jennifer.watchmaker@mountsinai.org (J.M. Watchmaker).

https://doi.org/10.1016/j.clinimag.2021.09.020
Received 1 September 2021; Accepted 29 September 2021
Available online 11 October 2021
0899-7071/© 2021 Elsevier Inc. All rights reserved.

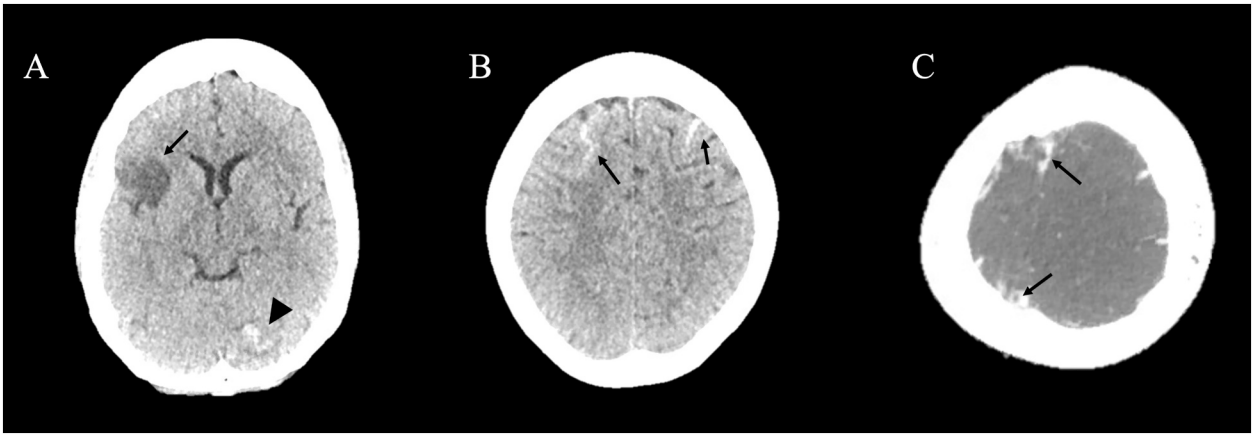

Fig. 1. Axial non contrast head CT demonstrates an acute to subacute infarct involving the right frontal operculum and insular region (A, arrow) and new parenchymal hemorrhages versus hemorrhagic infarcts involving the left parietal lobe (A, arrowhead) and multifocal acute subarachnoid hemorrhage (B, arrows). CT angiogram demonstrates multifocal irregularity within the superior sagittal sinus, with differential notable for prominent arachnoid granulations and/or sinus venous thrombosis (C, arrows).

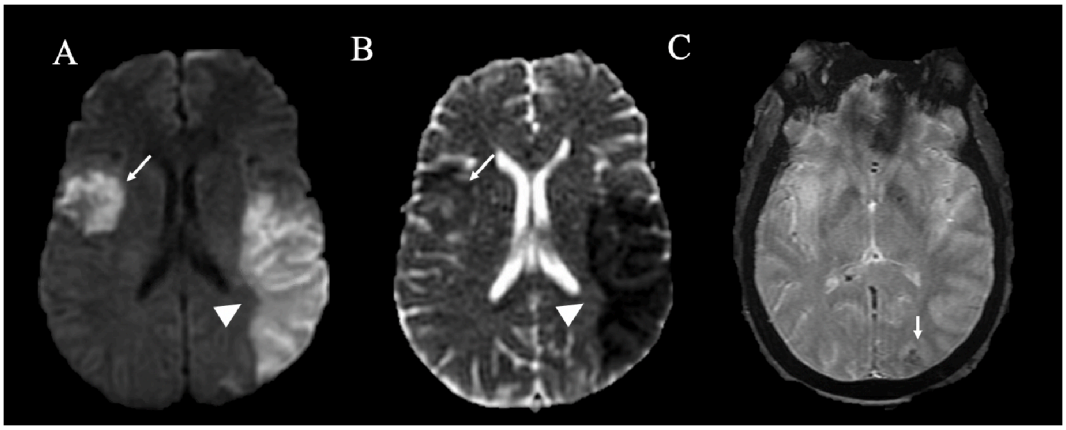

Fig. 2. Axial non contrast brain MRI demonstrates acute left middle cerebral artery territory infarct (A and B, arrowhead) and evolution of right frontal lobe infarcts on diffusion weight imaging (A and B, arrow) with apparent diffusion weight imaging correlates. Representative gradient-echo image redemonstrates parenchymal blood products in area of known hemorrhage (C, arrow).

The patient was admitted to the ICU due to acute hypoxic respiratory failure on May 9, 2021. She had a complex course which included treatment with broad spectrum antibiotics given her immunocompromised state, high dose steroids for concern for lupus flair, and remdesivir. Of note, the patient received her home dose of apixaban during the initial 5 days of hospitalization; this was subsequently stopped given development of disseminated intravascular coagulopathy (DIC) with platelet count dropping to a nadir of $20 \times 10^3/\mu L$ (platelet count on presentation $164 \times 10^3/\mu L$) on hospital day 8.

On hospital day 13, the patient reported headache, and altered mental status was observed. She was intubated at this time for airway protection. Subsequent head CT demonstrated a new acute to subacute infarct involving the right frontal operculum and insular region, new parenchymal hemorrhages versus hemorrhagic infarcts involving the left parietal lobe and left cerebellar hemisphere, and multifocal acute subarachnoid hemorrhage (Fig. 1A, B). CT angiogram of the head and neck performed later the same day demonstrated no definite evidence of an acute large vessel intracranial arterial occlusion or substantial arterial stenosis, however did demonstrate multifocal irregularity within the superior sagittal sinus, with differential notable for prominent arachnoid granulations and/or sinus venous thrombosis (Fig. 1C).

MRI of the brain performed the following day revealed acute left middle cerebral artery territory infarct, evolving right MCA territory infarcts, and redemonstration of previously seen parenchymal and subarachnoid blood products (Fig. 2). Contrast-enhanced MR venogram demonstrated non-occlusive superior sagittal sinus thrombosis (Fig. 3). After interdisciplinary discussion with hematology, neurosurgery and neurology a heparin drip was initiated following MR venogram confirmation of venous sinus thrombosis. On hospital day 19, head CT demonstrated continued expected evolution of infarcts with sulcal effacement surrounding the dominant left sided infarcts and trace rightward midline shift. Final head CT, performed on hospital day 35, demonstrated cessation of contrast opacification of the anterior and posterior intracranial arterial circulation as well as new cerebral edema with effacement of the gray-white matter borders, sulci, ventricles and cisterns, new hemorrhage in the right frontal and left frontoparietal lobes at the site of previous infarctions, and new hyperdensity in the sylvian fissures consistent with pseudo-subarachnoid hemorrhage (Fig. 4).

3. Discussion

In this unfortunate case, despite vaccination, this patient who notably was on immunosuppression for systemic lupus erythematosus, succumbed to SARS-CoV-2 infection. Hypoxic respiratory failure, complicated by DIC and acute CVD including ischemic, hemorrhagic and

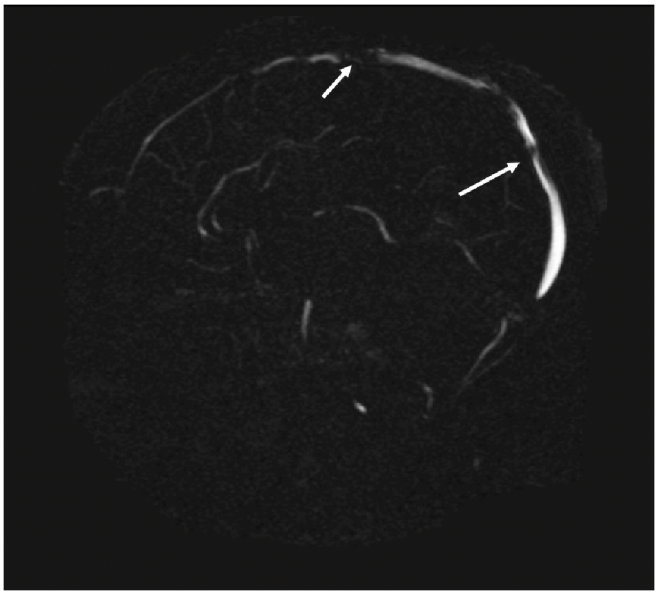

Fig. 3. Sagittal view from a contrast enhanced MR venogram of the head demonstrates multiple, non-occlusive, superior sagittal sinus thrombi. The transverse and sigmoid sinuses are patent bilaterally.

Fig. 4. Final axial head CT images demonstrate cerebral edema with effacement of the gray-white matter borders, sulci, ventricles and cisterns with new areas of hemorrhage and hemorrhage at site of prior infarctions (A, arrows). New hyperdensity is seen in the sylvian fissures consistent with pseudosubarachnoid hemorrhage (B, arrow). Coronal MIP CTA of the head and neck reveals opacification of the carotids (black arrows) in the neck but not in the intracranial circulation.

venous thrombotic events were contributory to this patient's death. This case not only is illustrative of classic imaging findings of brain death, but also highlights the vulnerably of immunocompromised patients despite vaccination.

While the mass vaccination efforts in some parts of the world have greatly ameliorated the burden of COVID-19, significant populations remain vulnerable even in areas that are approaching near-complete vaccination. Furthermore, the emergence of Delta and Lambda variants and increasing volume of severe breakthrough infections further substantiates the need to understand the varying degrees in which SARS-CoV-2 infection can afflict different patient populations.

Rituximab and methotrexate, both agents the patient presented in this report was receiving when vaccinated, until hospital admission, have been shown to reduce the humoral response to influenza and pneumococcal vaccines [17,18]. In a randomized clinical trial, Park et al found that in patients taking methotrexate for rheumatoid arthritis, a two-week methotrexate discontinuation prior to vaccination was shown to both improve efficacy of seasonal influenza vaccination compared to patients who continued their methotrexate (75.5% vs. 54.5%) and result in higher antibody titers against all four influenza antigens.

More limited data is available regarding the COVID-19 vaccines and immunosuppressed patients. In a small study that included 123 patients with rheumatic and musculoskeletal disease, of which 24 carried a diagnosis of systemic lupus erythematosus, 25% of this subgroup did not mount a detectable antibody response after the first dose of mRNA vaccine [19]. Additionally, reports have cited antibody responses as low as 17% after 1 dose and 39% after two doses for patients post-transplant patients receiving antimetabolite maintenance immunosuppression [20,21].

Overall, our report adds to the limited number of studies reporting on the disease course of COVID-19 infection in immunocompromised patients [22–24], and is the first to our knowledge that details neuroimaging findings. Our report is particularly timely given the Food and Drug Administration has now approved a third, booster, mRNA vaccine dose for immunocompromised patients given the mounting evidence that this patient population accounts for a large proportion of breakthrough infections, but also is a group capable of asymptomatic spreading [25,26]. While there are currently no guidelines for routine antibody testing to assure mounted vaccine response, extrapolation of what is known from prior vaccine studies may be warranted as we continue to study the outcomes of individuals at risk for severe infection despite vaccination.

References

1. Li Y, et al. Acute cerebrovascular disease following COVID-19: a single center, retrospective, observational study. Stroke Vasc Neurol 2020;5(3):279–84.

2. Szelenberger R, Saluk-Bijak J, Bijak M. Ischemic stroke among the symptoms caused by the COVID-19 infection. J Clin Med 2020;9(9).
3. Ntaios G, et al. Characteristics and outcomes in patients with COVID-19 and acute ischemic stroke: the global COVID-19 stroke registry. Stroke 2020;51(9):e254–8.
4. Belani P, et al. COVID-19 is an independent risk factor for acute ischemic stroke. AJNR Am J Neuroradiol 2020;41(8):1361–4.
5. Kihira S, et al. Fatal cerebral infarct in a child with COVID-19. Pediatr Radiol 2020; 50(10):1479–80.
6. Metlay JP, et al. Diagnosis and treatment of adults with community-acquired pneumonia. an official clinical practice guideline of the American Thoracic Society and Infectious Diseases Society of America. Am J Respir Crit Care Med 2019;200(7): e45–67.
7. Mao L. Neurologic manifestations of hospitalized patients with Coronavirus disease 2019 in Wuhan, China. JAMA Neurol 2020;77(6):683–90.
8. Shakil S, E.-B.S, Rutan C. Stroke among patients hospitalized with COVID-19 I the United States: results from the AHA COVID-19 Cardiovascular Disease Registry. In: International stroke conference 2021; 2021.
9. Frampas E, et al. CT angiography for brain death diagnosis. AJNR Am J Neuroradiol 2009;30(8):1566–70.
10. Escudero D, et al. Diagnosing brain death by CT perfusion and multislice CT angiography. Neurocrit Care 2009;11(2):261–71.
11. Quesnel C, et al. Limitations of computed tomographic angiography in the diagnosis of brain death. Intensive Care Med 2007;33(12):2129–35.
12. Dupas B, et al. Diagnosis of brain death using two-phase spiral CT. AJNR Am J Neuroradiol 1998;19(4):641–7.
13. Wijdicks EF, et al. Evidence-based guideline update: determining brain death in adults: report of the quality standards Subcommittee of the American Academy of neurology. Neurology 2010;74(23):1911–8.
14. Kapoor I, Prabhakar H, Mahajan C. COVID-19 and diagnosing brain death: an ambiguity. Turk J Anaesthesiol Reanim 2020;48(5):436.
15. Guan WJ, et al. Clinical characteristics of coronavirus disease 2019 in China. N Engl J Med 2020;382(18):1708–20.
16. Migdady I, Rae-Grant A, Greer DM. Brain death evaluation during the pandemic. Neurology 2020;95(15):693–4.
17. Bingham 3rd CO, et al. Immunization responses in rheumatoid arthritis patients treated with rituximab: results from a controlled clinical trial. Arthritis Rheum 2010; 62(1):64–74.
18. Park JK, et al. Impact of temporary methotrexate discontinuation for 2 weeks on immunogenicity of seasonal influenza vaccination in patients with rheumatoid arthritis: a randomised clinical trial. Ann Rheum Dis 2018;77(6):898–904.
19. Boyarsky BJ, et al. Antibody response to a single dose of SARS-CoV-2 mRNA vaccine in patients with rheumatic and musculoskeletal diseases. Ann Rheum Dis 2021. annrheumdis-2021-220289.
20. Boyarsky BJ, et al. Immunogenicity of a single dose of SARS-CoV-2 messenger RNA vaccine in solid organ transplant recipients. JAMA 2021;325(17):1784–6.
21. Boyarsky BJ, et al. Antibody response to 2-dose SARS-CoV-2 mRNA vaccine series in solid organ transplant recipients. JAMA 2021;325(21):2204–6.
22. Helleberg M, et al. Persistent COVID-19 in an immunocompromised patient temporarily responsive to two courses of remdesivir therapy. J Infect Dis 2020;222 (7):1103–7.
23. Clark SA, et al. SARS-CoV-2 evolution in an immunocompromised host reveals shared neutralization escape mechanisms. Cell 2021;184(10):2605–2617 e18.
24. Choi B, et al. Persistence and evolution of SARS-CoV-2 in an immunocompromised host. N Engl J Med 2020;383(23):2291–3.
25. Tarhini H, et al. Long-term severe acute respiratory syndrome coronavirus 2 (SARS-CoV-2) infectiousness among three immunocompromised patients: from prolonged viral shedding to SARS-CoV-2 superinfection. J Infect Dis 2021;223(9):1522–7.
26. Brosh-Nissimov T, et al. BNT162b2 vaccine breakthrough: clinical characteristics of 152 fully vaccinated hospitalized COVID-19 patients in Israel. Clin Microbiol Infect 2021. S1198-743X(21)00367-0.