Since January 2020 Elsevier has created a COVID-19 resource centre with free information in English and Mandarin on the novel coronavirus COVID-19. The COVID-19 resource centre is hosted on Elsevier Connect, the company's public news and information website.

Elsevier hereby grants permission to make all its COVID-19-related research that is available on the COVID-19 resource centre - including this research content - immediately available in PubMed Central and other publicly funded repositories, such as the WHO COVID database with rights for unrestricted research re-use and analyses in any form or by any means with acknowledgement of the original source. These permissions are granted for free by Elsevier for as long as the COVID-19 resource centre remains active.

Clinical Imaging 80 (2021) 202–204

Contents lists available at ScienceDirect

Clinical Imaging

journal homepage: www.elsevier.com/locate/clinimag

Breast Imaging

Mammographic and sonographic findings in the breast and axillary tail following a COVID-19 vaccine

Jasmine N. Locklin, Genevieve A. Woodard *

Mayo Clinic, Department of Breast Imaging and Intervention, Rochester, MN, United States of America

ARTICLE INFO

Keywords:
Focal asymmetry
Edema
COVID-19 vaccine

ABSTRACT

Axillary lymphadenopathy on breast imaging after recent coronavirus disease 2019 (COVID-19) vaccination has been reported in the literature as immunization has become more widespread. While muscle edema at the injection site has been observed on MRI secondary to an immune response, ipsilateral breast imaging observations of edema have not been reported to be seen with the COVID-19 vaccinations to date. Mammographic findings such as trabecular and skin thickening, along with increased echogenicity on ultrasound, can be seen with edema secondary to capillary leak or poor lymphatic drainage, and should be considered as a possible etiology for the observed breast edema following a recent COVID-19 vaccine. Inflammatory changes observed in the breast and axillary tail post vaccination described in this case series are transient, but clinically relevant for patients who experience swelling following injection. Similar to evaluations for suspected mastitis, a short interval imaging follow up to confirm resolution may be appropriate for patients with ipsilateral vaccination histories, and could potentially reduce the number of false positive examinations in this clinical scenario. However, inflammatory breast cancer can mimic inflammation and infection, therefore close follow up to resolution is critical as to not miss cancer.

1. Introduction

Axillary lymphadenopathy on breast imaging after recent coronavirus disease 2019 (COVID-19) vaccination has been reported in the literature as immunization has become more widespread [1]. While muscle edema at the injection site has been observed on MRI secondary to an immune response [2], ipsilateral breast imaging observations of edema have not been reported to be seen with the COVID-19 vaccinations to date. Mammographic findings such as trabecular and skin thickening, along with increased echogenicity on ultrasound, can be seen with edema secondary to capillary leak or poor lymphatic drainage, and should be considered as a possible etiology for the observed breast edema following a recent COVID-19 vaccine [3]. Inflammatory changes observed in the breast and axillary tail post vaccination described in this case series are transient, but clinically relevant for patients who experience swelling following injection. Similar to evaluations for suspected mastitis, a short interval imaging follow up to confirm resolution may be appropriate for patients with ipsilateral vaccination histories, and could potentially reduce the number of false positive examinations in this clinical scenario [4]. However, inflammatory breast cancer can mimic inflammation and infection, therefore close follow up to resolution is critical as to not miss cancer.

2. Case 1

An 83-year-old woman presented for diagnostic imaging for a screening detected right breast focal asymmetry. The screening mammogram on 3/25/2021 demonstrated a new focal asymmetry in the upper outer right breast posterior depth extending into the axilla with associated minimal skin thickening compared to the prior 10/2/2018 examination (Fig. 1). The right breast diagnostic mammogram on 3/29/2021 revealed complete interval resolution of the focal asymmetry (Fig. 2). A targeted breast ultrasound was performed and confirmed normal underlying fibroglandular tissue (images not shown). Additionally, the diagnostic mammogram demonstrated a partially visualized enlarged right axillary lymph node (Fig. 3A). Targeted right axillary ultrasound demonstrated a level I lymph node with a preserved fatty hilum and mild cortical thickening measuring up to 6 mm (Fig. 3B).

A chart review revealed the patient received the first COVID-19 vaccination in the right arm one day prior to obtaining her screening

* Corresponding author at: 200 1st Street SW, Rochester, MN 55905, United States of America.
E-mail address: woodard.genevieve@mayo.edu (G.A. Woodard).

https://doi.org/10.1016/j.clinimag.2021.07.015
Received 16 May 2021; Received in revised form 7 July 2021; Accepted 20 July 2021
Available online 26 July 2021
0899-7071/© 2021 The Authors. Published by Elsevier Inc. This is an open access article under the CC BY-NC-ND license (http://creativecommons.org/licenses/by-nc-nd/4.0/).

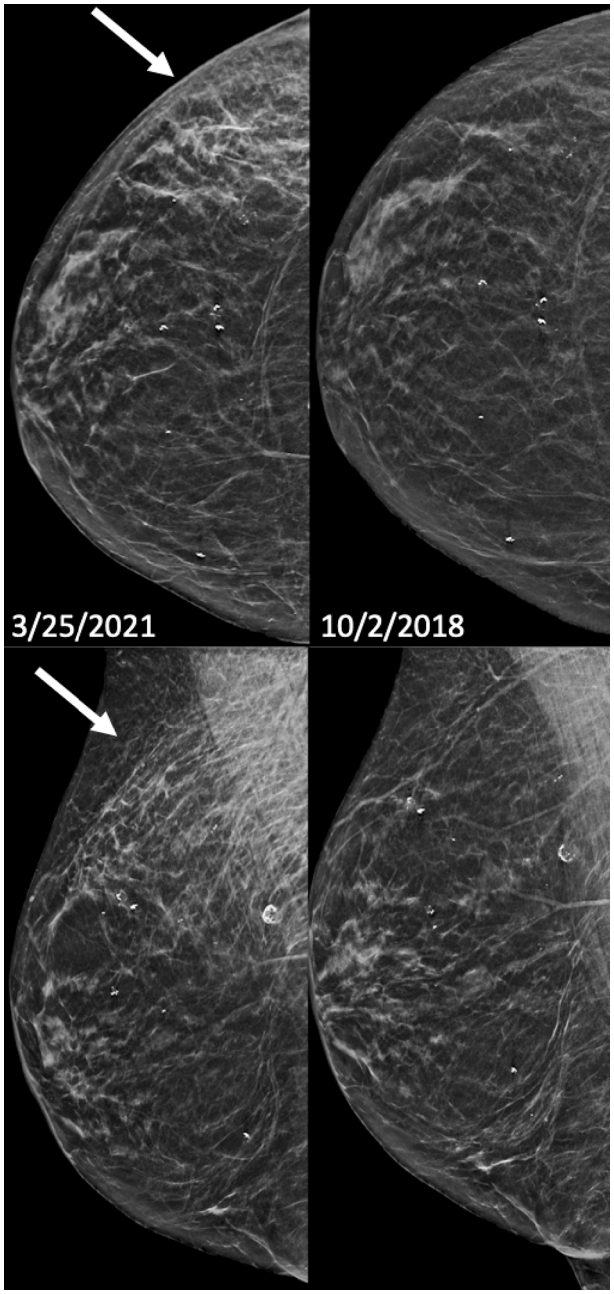

Fig. 1. Right CC view (top row) and MLO view (bottom row) from the screening mammogram on 3/25/2021 demonstrated a focal asymmetry manifested as trabecular thickening in the upper outer right breast posterior depth extending into the axilla with associated minimal skin thickening (white arrows), which was not present on the prior screening mammogram on 10/2/2018.

mammogram. The patient reported significant clinical swelling in her right arm extending into neck and face following the vaccination that resolved a few days later. The screening detected focal asymmetry in the upper outer right breast was likely related to edema associated with the recent vaccination given the ipsilateral presentation, known inflammatory response elicited by the vaccine, and the rapid resolution. The patient also had mild right axillary lymphadenopathy, which is known to be associated with COVID-19 vaccination, further supporting this clinical scenario.

Since the right axillary lymphadenopathy had a reasonable explanation of recent ipsilateral COVID-19 vaccination, a benign BI-RADS 2 assessment category was assigned [5,6]. Clinical follow up of the right

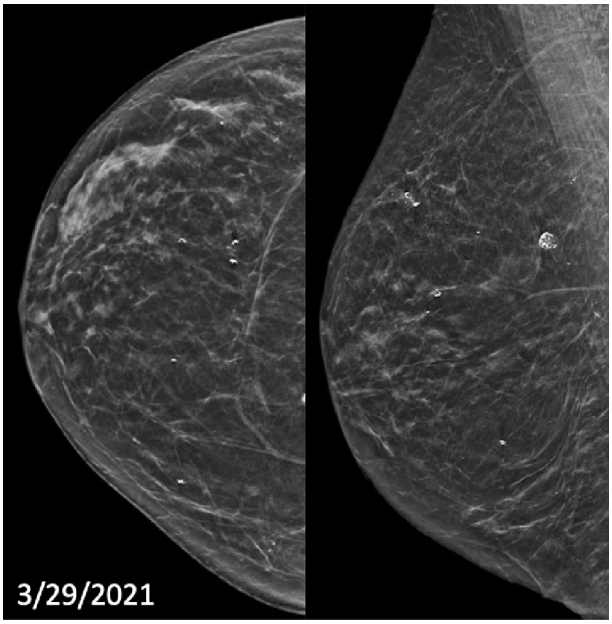

Fig. 2. Diagnostic right breast CC and MLO mammographic views on 3/29/20/21 demonstrated complete interval resolution of the previously seen focal asymmetry and associated skin thickening.

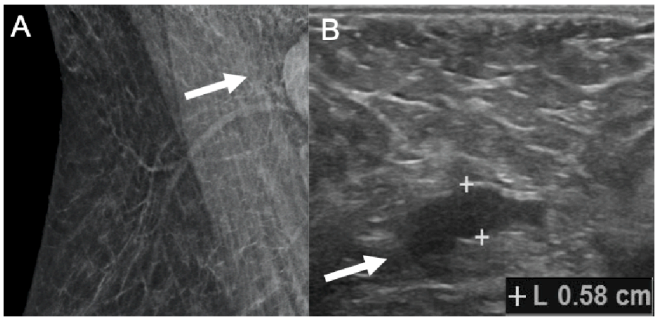

Fig. 3. Diagnostic right breast ML view mammogram demonstrates a partially visualized enlarged right axillary lymph node (white arrow, A). Targeted right axillary ultrasound demonstrated a corresponding right level I axillary lymph node (white arrow) with a preserved fatty hilum and mild cortical thickening of 6 mm (B).

axilla was recommended with additional targeted imaging if there was persistent clinical concern beyond the expected time frame for vaccine related lymphadenopathy. These recommendations align with the ACR BI-RADS Atlas 5th Edition management for unilateral adenopathy in the setting of a known inflammatory cause [7].

3. Case-2

A 36-year-old women presented with a palpable lump in the left axilla with associated erythema and warmth on 1/22/2021. The patient confirmed a COVID-19 vaccine in the left arm 11 days prior to presentation. Left breast diagnostic mammography revealed trabecular thickening of the right axillary tail (Fig. 4A and B) and an adjacent prominent axillary lymph node (Fig. 4C). Targeted ultrasound demonstrated corresponding subcutaneous edema (Fig. 5A) at the palpable lump and a single level I axillary lymph node with mild cortical thickening measuring 7 mm (Fig. 5B). The examination was given a probably benign assessment (BI-RADS 3), and the patient was instructed to return for short interval imaging follow up as her symptoms and imaging finding were likely inflammatory in etiology given her recent ipsilateral

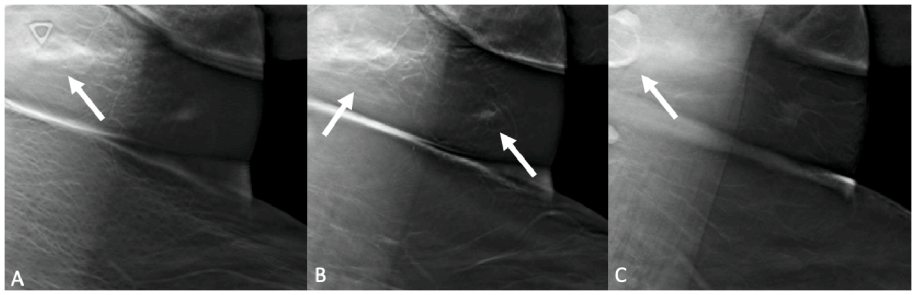

Fig. 4. Selected tomosynthesis slices from the diagnostic mammographic MLO view on 1/22/2021 show a triangular palpable marker (white arrow) overlying the left axillary tail at the site of clinical concern (A) with underlying trabecular thickening (white arrow, B) and an adjacent prominent level I axillary lymph node (white arrow, C).

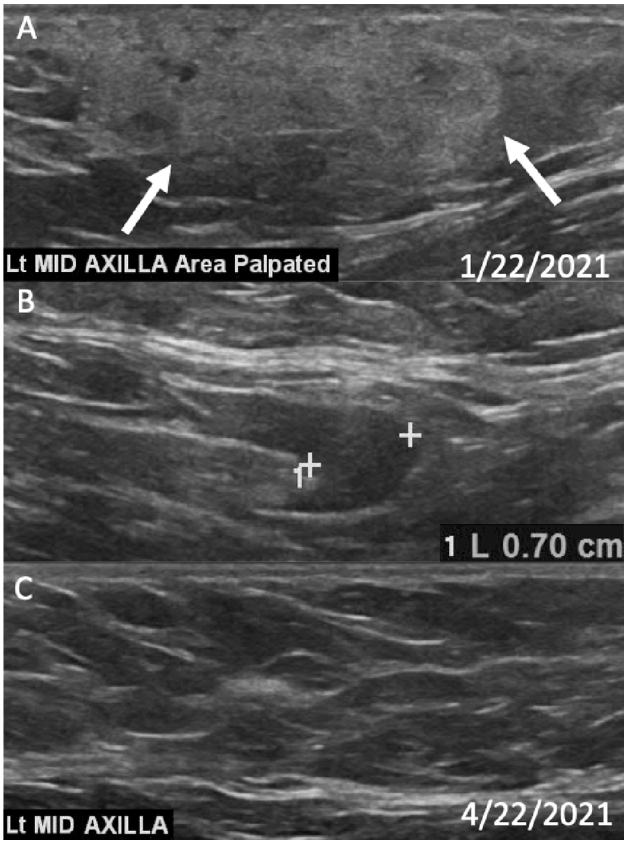

Fig. 5. Targeted left axillary tail ultrasound on 1/22/2021 shows increased subcutaneous echogenicity consistent with edema (A) at the palpable lump, corresponding to the trabecular thickening on mammography. An adjacent lymph node with a preserved fatty hilum and mild cortical thickening measuring 7 mm was identified. (B). Follow up targeted left axillary tail ultrasound on 4/22/2021 confirmed complete resolution of the previously seen edema (C).

vaccination. The patient indicated complete resolution of her clinical symptoms in less than four weeks, and repeat targeted ultrasound on 4/22/2021 confirmed no residual axillary tail edema (Fig. 5C) or lymphadenopathy (images not shown).

4. Case-3

A 60-year-old asymptomatic women with a remote history of bilateral breast reduction presented for screening mammography on 4/22/2021. A subtle focal asymmetry was noted in the upper outer left breast posterior depth, new since the prior 9/16/2019 examination (Fig. 6).

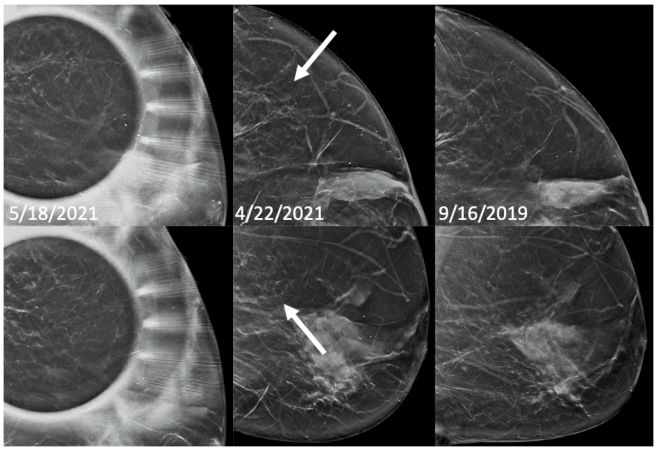

Fig. 6. Left CC view (top row) and MLO view (bottom row) from the screening mammogram on 4/22/2021 demonstrated a subtle focal asymmetry in the upper outer left breast posterior depth (white arrows), which was not present on the prior screening mammogram on 9/16/2019. Diagnostic spot compression CC view (top row) and MLO view (bottom row) performed on 5/18/21 showed resolution of the subtle focal increased trabecular thickening visualized on the screening mammogram.

Electronic chart review confirmed the patient received her COVID-19 vaccine in her left arm on 4/21/2021. The diagnostic mammogram performed on 5/18/2021 demonstrated complete resolution of the previously described focal asymmetry. Confirmatory targeted ultrasound noted no sonographic abnormality in the upper outer left breast, but prominent ipsilateral level I axillary lymph nodes with mild cortical thickening were identified and assessed as likely inflammatory in etiology (images not shown).

References

1. Tu W, Gierada DS, Joe BN. COVID-19 vaccination-related lymphadenopathy: what to be aware of radiology: imaging. Cancer 2021;(3):e210038.
2. Theodorou DJ, Drs Theodorou SJ, Axiotis A, Gianniki M, Tsifetaki N. COVID-19 vaccine-related myositis. QJM: An International Journal of Medicine 2021:1–2. https://doi.org/10.1093/qjmed/hcab043.
3. Cao MM, Hoyt AC, Bassett LW. Mammographic signs of systemic disease. Radiographics 2011;31(4):1085–100.
4. Woodard GA, Bhatt AA, Knavel EM, Hunt KN. Mastitis and more: a pictorial review of the red, swollen, and painful breast. J. Breast Imag. 2020;3(1):113–23.
5. Lehman CD, D'Alessandro HA, Mendoza DP, Succi MD, Kambadakone A, Lamb LR. Unilateral lymphadenopathy after COVID-19 vaccination: a practical management plan for radiologists across specialties. J Am Coll Radiol June 2021;18(6):843–52.
6. Mortazavi S. Coronavirus Disease (COVID-19) Vaccination Associated Axillary Adenopathy: Imaging Findings and Follow-Up Recommendations in 23 Women. Am J Roentgenol 2021 Feb 24 [published online]. Accepted manuscript, https://doi.org/10.2214/AJR.21.25651.
7. D'Orsi CJS, EA Mendelson EB, Morris EA, et al. ACR BI-RADS® Atlas, breast imaging reporting and data system. Reston, VA: American College of Radiology; 2013.