Since January 2020 Elsevier has created a COVID-19 resource centre with free information in English and Mandarin on the novel coronavirus COVID-19. The COVID-19 resource centre is hosted on Elsevier Connect, the company's public news and information website.

Elsevier hereby grants permission to make all its COVID-19-related research that is available on the COVID-19 resource centre - including this research content - immediately available in PubMed Central and other publicly funded repositories, such as the WHO COVID database with rights for unrestricted research re-use and analyses in any form or by any means with acknowledgement of the original source. These permissions are granted for free by Elsevier for as long as the COVID-19 resource centre remains active.

Environmental Research 201 (2021) 111643

Contents lists available at ScienceDirect

Environmental Research

journal homepage: www.elsevier.com/locate/envres

Mucormycosis: An opportunistic pathogen during COVID-19

Iyer Mahalaxmi [a,1], Kaavya Jayaramayya [b,1], Dhivya Venkatesan [b,1], Mohana Devi Subramaniam [c,1], Kaviyarasi Renu [d,1], Padmavathi Vijayakumar [b], Arul Narayanasamy [e], Abilash Valsala Gopalakrishnan [d], Nachimuthu Senthil Kumar [f], Palanisamy Sivaprakash [g], Krothapalli R.S. Sambasiva Rao [f], Balachandar Vellingiri [b,*]

[a] Livestock Farming and Bioresource Technology, Tamil Nadu, India
[b] Human Molecular Cytogenetics and Stem Cell Laboratory, Department of Human Genetics and Molecular Biology, Bharathiar University, Coimbatore, 641-046, India
[c] SN ONGC, Department of Genetics and Molecular Biology, Vision Research Foundation, Chennai, 600 006, Tamil Nadu, India
[d] Department of Biomedical Sciences, School of Biosciences and Technology, Vellore Institute of Technology, Vellore, 632 014, Tamil Nadu, India
[e] Disease Proteomics Laboratory, Department of Zoology, Bharathiar University, Coimbatore, 641046, Tamil Nadu, India
[f] Department of Biotechnology, Mizoram University (A Central University), Aizawl, 796 004, Mizoram, India
[g] Centre for Environmental Awareness, Dr. N.G.P. Institute of Technology, Coimbatore, 641048, Tamil Nadu, India

ARTICLE INFO

Keywords:
COVID-19
Mucormycosis
Organ damage
Diabetes
Immunosuppression
Steroids
Environmental pollution

ABSTRACT

The pandemic of coronavirus disease 2019 (COVID-19) still remains on an upsurge trend. The second wave of this disease has led to panic in many countries, including India and some parts of the world suffering from the third wave. As there are no proper treatment options or remedies available for this deadly infection, supportive care equipment's such as oxygen cylinders, ventilators and heavy use of steroids play a vital role in the management of COVID-19. In the midst of this pandemic, the COVID-19 patients are acquiring secondary infections such as mucormycosis also known as black fungus disease. Mucormycosis is a serious, but rare opportunistic fungal infection that spreads rapidly, and hence prompt diagnosis and treatment are necessary to avoid high rate of mortality and morbidity rates. Mucormycosis is caused by the inhalation of its filamentous (hyphal form) fungi especially in the patients who are immunosuppressed. Recent studies have documented alarming number of COVID-19 patients with mucormycosis infection. Most of these patients had diabetes and were administered steroids for Severe Acute Respiratory Syndrome Coronavirus 2 (SARS-CoV-2) infection and were consequently more prone to mucormycosis. Hence, the present review emphasizes mucormycosis and its related conditions, its mechanism in normal and COVID-19 affected individuals, influencing factors and challenges to overcome this black mold infection. Early identification and further investigation of this fungus will significantly reduce the severity of the disease and mortality rate in COVID-19 affected patients.

1. Introduction

Mucormycosis is a rare fungal infection caused by exposure to mucor mold commonly found in soil, manure, plants, decaying fruits and vegetables, air and even in the mucus of healthy people. It affects the sinus, brain and lungs and can be life-threatening in diabetic or severely immunocompromised individuals. The year 2020 was devastating for global health as an uncommon virus raced worldwide, emerging rapidly as one of the top killers laying bare the inadequacies of the health systems. Today, health services in all regions are struggling to tackle

Abbreviations: AML, Acute Myeloid Leukemia; $CD4^+$ T, cluster of differentiation 4 T-helper cells; CNS, Central Nervous System; CotH, Spore coat protein; COVID19, Coronavirus Disease 2019; CT, Computed Tomography; ICU, Intensive Care Unit; IFN-γ, Interferon-gamma; IL-10, Interleukin −10; IL-17, Interleukin −17; IL-4, Interleukin-4; LIFE, Leading International Fungal Education; NK cells, Natural Killer cells Normal T-cell Expressed and Secreted; PDGFRB, Platelet-Derived Growth Factor Receptor B; RANTES, Regulated upon Activation Normal T-cell Expressed and Secreted; ROCM, Rhino-Orbital Cerebral Mucormycosis; SARS-CoV-2, Severe acute respiratory syndrome coronavirus 2; SSTI, Skin and Soft Tissue Infection; WHO, World Health Organization.

* Corresponding author. Human Molecular Cytogenetics and Stem Cell Laboratory, Department of Human Genetics and Molecular Biology, Bharathiar University, Coimbatore, 641 046, Tamil Nadu, India.
E-mail addresses: geneticbala@buc.edu.in, geneticbala@yahoo.co.in (B. Vellingiri).
[1] Authors with Equal contribution.

https://doi.org/10.1016/j.envres.2021.111643
Received 21 May 2021; Received in revised form 1 July 2021; Accepted 1 July 2021
Available online 6 July 2021
0013-9351/© 2021 Elsevier Inc. All rights reserved.

COVID-19 and provide people with vital care. As the global COVID-19 pandemic enters the second year, countries around the world are racing to vaccinate their populations as novel variants emerge. The general population is relatively more complacent towards physical distancing, mask-wearing, and other public health interventions. India continued to maintain a downward trend in daily COVID-19 cases until the number of cases hovered above 3,00,000 in the deadly second wave of the infection. As of June 7, 2021, the country has recorded 28,252 cases of mucormycosis from 28 states. There are 24,370 cases with a history of COVID-19 and 17,601 cases with a history of diabetes. India had recorded its highest number (6329) of mucormycosis cases (Adil, 2021). The virus is spreading faster than ever before, in India, despite previous high infection rates in megacities, which should have conferred some protection. The pandemic is sweeping through India at a pace that has staggered scientists. Daily cases have exploded since early March 2021. Among the world, the European countries such as France and Germany, the Brazil and the United States are also currently experiencing large outbreaks, reporting high infection rates at around 70,000 a day. Hospitals are scrabbling for beds and oxygen in response to a deadly second surge in infections. India has reported for nearly half the COVID-19 cases worldwide recently and a quarter of the deaths (World Health Organization, 2021a). The number of COVID-19 cases globally remains at the highest levels since the beginning of the pandemic with over 175 million new weekly cases (World Health Organization, 2021b). At present, there are four variants of concern that WHO is tracking around the world. The B.1.1.7 was first identified in the United Kingdom, B.1.351, was first identified in South Africa, and the P.1 variant was first identified in Japan (World Health Organization, 2021c). Genomic surveillance data shows that the variant B.1.1.7, from the United Kingdom has become the dominant form of the virus in the Indian states. And a new and potential variant of concern, first identified in India late last year, known as B.1.617, has become dominant in the state of Maharashtra. B.1.617 has drawn attention because it contains two mutations linked to increased transmissibility and an ability to evade immune protection. It has now been detected in 20 other countries as well (Mallapaty, 2021). Physicians are documenting an alarming number of cases of mucormycosis among COVID-19 patients. Most of these patients had diabetes and are treated with steroids for SARS-CoV-2 infection and this combination might have made them more prone to fungal attack. People with a compromised immune system or bone marrow transplant with fewer neutrophils are more vulnerable to mucormycosis (Dantas et al., 2021; Sarvestani et al., 2013; Shariati et al., 2020; Suganya et al., 2019). COVID-19 patients are prescribed with heavy doses of steroids resulting in weakened immune system and are susceptible to mucormycosis. In addition, steroids can cause blood sugar levels to spike, which is challenging for patients with uncontrolled diabetes and the acidic environment due to this condition favors the fungal (Mucorales) growth. Inhalation of filamentous fungi by patients weakens the immune defense pathways. Mucormycosis has also been associated with various underlying conditions that predispose an individual to the infection. Hospitals around the country continue to report a growing trend of mucormycosis cases in COVID-19 patients and this disease has been declared as an epidemic. Hence, the aim of the present review emphasizes the history of mucormycosis, its related diseases, its process in normal individuals, immune-compromised and COVID-19 affected subjects, the various risk factors and its effect on multiple organs and challenges to overcome this infection. With increasing pressure on healthcare infrastructure during the COVID-19 pandemic, this review will provide a general evidence base for optimal treatment outcomes and prevention from this fungal infection.

2. Origin of mucormycosis

Mucormycosis (also called zygomycosis) is a serious but rare fungal infection caused by a group of molds called mucormycetes. Mucormycosis, or the deadly black fungus, is a life-threatening fungal infection caused by fungi that belongs to the subphylum Mucoromycotina and order Mucorales (Chegini et al., 2020; Chibucos et al., 2016). Mucorales fungi are the most common fungi found in hematological malignancies, hematopoietic stem cell transplantation and solid organ transplantation after Aspergillus (Jeong et al., 2019). Eleven genus and ~27 species under the order Mucorales cause mucormycosis (Gomes et al., 2011). Among the predominant genera that cause mucormycosis, Rhizopus is the most common followed by Mucor and Lichtheimia. Mucorales are generally found in soil, decaying food, manure and dust (Asghar et al., 2019; Chakrabarti et al, 2006, 2009bib_Chakrabarti_et_al_2009bib_Chakrabarti_et_al_2006; Chow et al., 2015; Reid et al., 2020). Mucormycosis was initially described in 1855, as this was the first authentic human case of this condition (Küchenmeister, 1855). In 1876, pulmonary mucormycosis was discovered by Furbringer in Germany in a cancer patient who presented with a hemorrhagic infarct in the right lung that consisted of fungal hyphae and spores (Furbringer, 1876). Mucormycosis was first seen in an autopsy in the year 1956 (Baker, 1956). The main mode of infection of mucormycosis is through the inhalation of spores, consumption of contaminated food and inoculation of the fungi into abrasions or cuts on the skin (Chibucos et al., 2016; Gomes et al., 2011; Jeong et al., 2019; Prakash and Chakrabarti, 2019; Reid et al., 2020). In addition, outbreaks of mucormycosis have also been linked to contamination of medical devices, ventilation systems and hospital disposables like bandages, hospital linen etc. (Rammaert et al., 2012). Mucormycosis mostly infects immunocompromised individuals whose immune system lacks the ability to mitigate the fungi. It is mainly diagnosed by laboratory analysis of the biopsy isolated from the site of infection. In addition, other imaging tests like CT are also beneficial for diagnosis (Prakash and Chakrabarti, 2019). This condition can be classified into six forms namely rhino-orbital cerebral mucormycosis (ROCM), pulmonary, cutaneous, gastrointestinal, disseminated and uncommon sites based on the location of their occurrence. Among them, ROCM is the most commonly occurring one. Among the species that cause mucormycosis, the Rhizopus species was linked with ROCM. At the same time Cunninghamella was found in the pulmonary or disseminated form, while Apophysomyces and Saksenaea were seen in the cutaneous type (Jeong et al., 2019). The most common sites of infection are sinuses (39%), lungs (24%), disseminated (23%); and skin and soft tissue infection (19%) (Reid et al., 2020). The fungi begin by invading the blood vessels, which results in thrombosis and infarction of the tissue. When the spores of the fungus, comes in contact with the endothelial cells, angioinvasion occurs. More interaction with the receptors of these cells results in cell damage and fungal spread (Spellberg et al., 2005). In healthy people, the fungi often get eradicated by the polymorphonuclear phagocytes. Hence fungal growth is usually present in individuals with defects in this mechanism. In addition, Mucorales are sometimes resistant to these mechanisms making them more virulent (Chamilos et al., 2008; Ibrahim and Kontoyiannis, 2013; Kontoyiannis and Lewis, 2006). Despite the increase in mucormycosis, the prevalence data is not completely compiled due to the lack of population-based studies (Skiada et al., 2020). In a study comprising of 600 articles, it was found that majority of mucormycosis occurred in Europe (34%), followed by Asia (31%), North or South America (28%), Africa (3%), Australia and New Zealand (3%) (Jeong et al., 2019). The Leading International Fungal Education (LIFE) estimates 10,000 cases globally, excluding India, and this number increased to 9,10,000 after including the data from India (Prakash and Chakrabarti, 2019). In India, the prevalence was 0.14 cases per 1000 population, astoundingly higher than in developed countries (Skiada et al., 2020). The estimation of mucormycosis in countries around the world is illustrated in Fig. 1. In most cases, unless surgery and antifungal therapy are administered promptly, the condition deteriorates rapidly leading to death. The mortality rate was 54% in this condition and vastly depends on the site of infection, underlying comorbidities and type of fungus. The mortality rate was the highest for individuals with disseminated mucormycosis (96%), followed by pulmonary (76%) and sinus (46%) infections (Roden

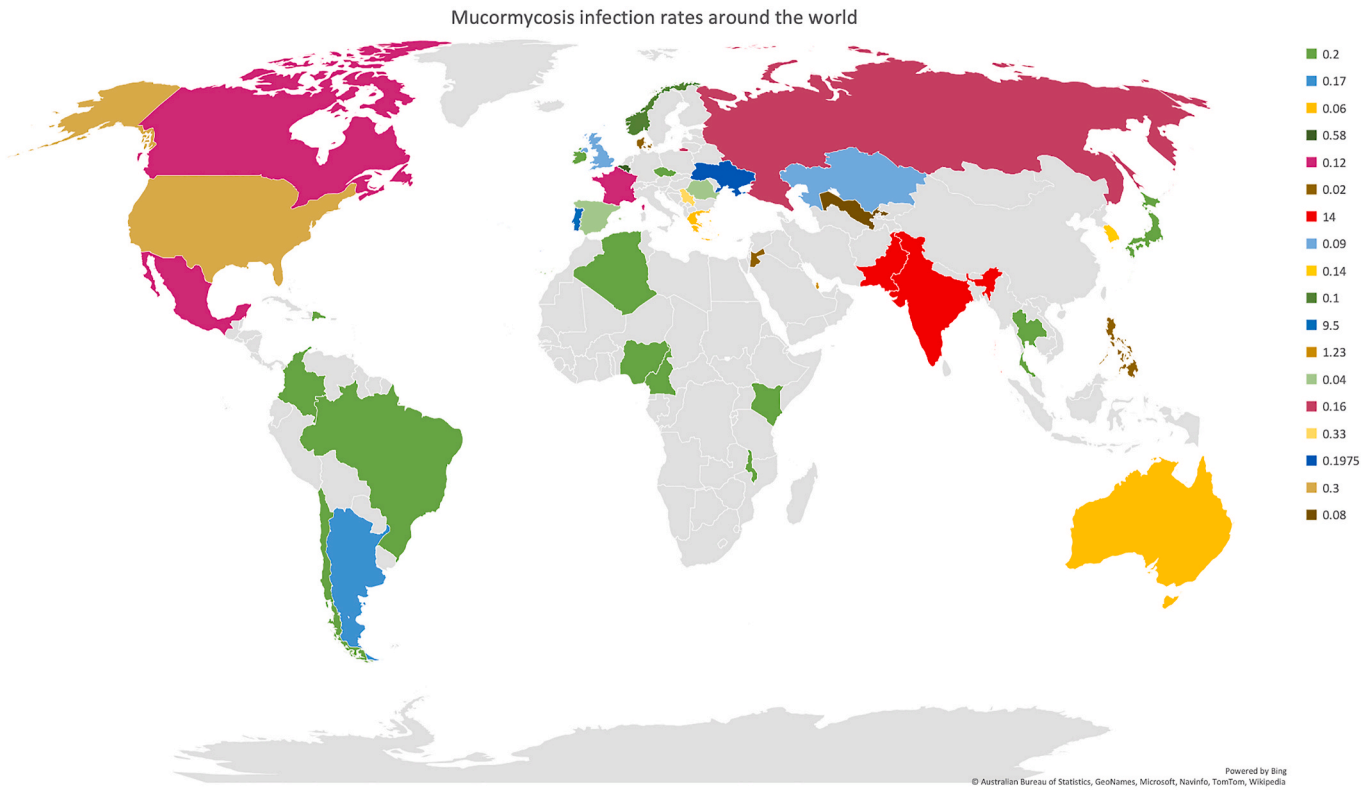

Fig. 1. Mucormycosis infections around the world: The estimated rates of mucormycosis infection per 100 K individuals around the world is illustrated in this figure. Among the countries, the mucormycosis burden is the highest in countries like India and Pakistan and followed by Portugal. This estimation was compiled by The Leading International Fungal Education (LIFE) portal.

et al., 2005). The extremely high mortality rate, negative effects of surgery and lack of therapeutic options makes it vital to develop early diagnostic and prevention strategies (Chibucos et al., 2016).

3. Underlying conditions associated with mucormycosis

Mucormycosis has been associated with various underlying conditions that predispose an individual to the infection. Some of these factors include diabetes, neutropenia, organ or stem cell transplantation, trauma and burns, hematological disorders, steroidal use, metabolic acidosis, intravenous drug usage, renal insufficiency, broad-spectrum antibiotics, increase in iron in the system, malnutrition, usage of voriconazole (Fig. 2) (Dantas et al., 2021; Sarvestani et al., 2013; Shariati et al., 2020; Suganya et al., 2019). A previous study from Europe (Skiada et al., 2011) showed that, the most significant underlying causes were hematological malignancies, while it was diabetes mellitus in India (Chakrabarti et al., 2009), Iran (Dolatabadi et al., 2018), Middle East, North Africa (Stemler et al., 2020) and Mexico (Corzo-León et al., 2018). Among the different forms of mucormycosis, ROCM has been concomitant with the presence of diabetes. The cutaneous form was more prominent in individuals with trauma, and organ transplant was related to the pulmonary, gastrointestinal and disseminated type. In addition, underlying hematological malignancies were present in disseminated type and neutropenia in the pulmonary form (Jeong et al., 2019). Mucormycosis occurs mainly in individuals with uncontrolled diabetes, and this is because the innate immunity in these individuals, impacts the polymorphonuclear phagocytes to destroy the fungi. In patients with diabetes, the sinus was the most affected area followed by the pulmonary areas (Rammaert et al., 2012). Individuals with hematological malignancies were also predisposed to mucormycosis during the neutropenia phase of the ailment. The presence of mucormycosis in hematological malignancies can be attributed to chemotherapy and the usage of voriconazole used in the treatment of aspergillosis (Shadrivova et al.,

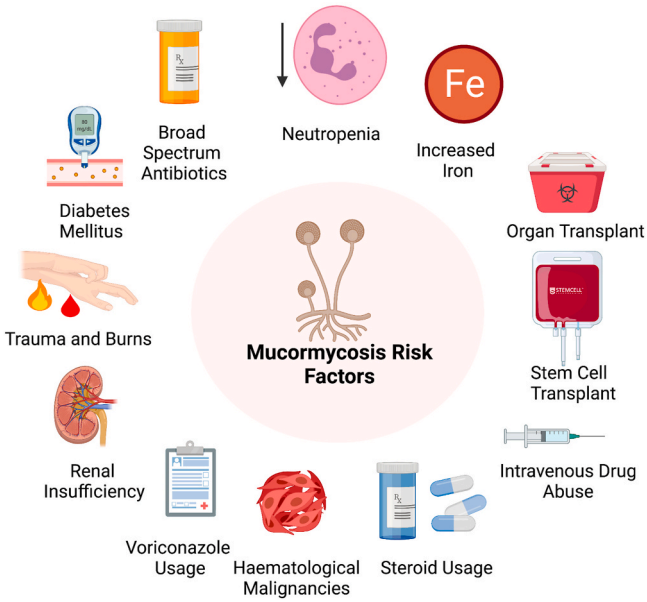

Fig. 2. Risk factors associated with the development of mucormycosis: Various factors that contribute to mucormycosis development; this includes the presence of underlying conditions like renal insufficiency, diabetes mellitus and hematological malignancies. Medications like voriconazole, broad-spectrum antibiotics and steroids are also known to predispose an individual to mucormycosis. In addition, an increase in iron levels in the circulation, neutropenia and immunosuppressant treatments like stem cell therapy and organ transplant make individuals more vulnerable to the condition. Exposure to spores through cuts and burns on the skin and intravenous drug usage are also risk factors for mucormycosis.

2019). Mucormycosis was also more common in patients with acute leukemia than other types of malignancies. The main modes of prevention of mucormycosis in patients with hematological malignancies include avoidance of environmental exposures and the treatment strategies were surgery, antifungal treatment and reversal of neutropenia (Pagano et al., 1997). Transplantation therapies have also been diagnosed as risk factors for mucormycosis. However, the incidence of the condition varies based on the type of organs that are being transplanted. Since recipients of transplantation therapies are administered immunosuppressants and high doses of steroids, it makes them more vulnerable to mucormycosis (Almyroudis et al., 2006). In addition, corticosteroids also suppress macrophages and neutrophils inhibiting the ability of the body to fight the infection (Mcnulty, 1982). Steroid administered individuals also fall under the high-risk category. Stem cell therapy patients are also treated with voriconazole which influences the occurrence of mucormycosis when used prophylactically (Lionakis et al., 2018). Another factor contributing to mucormycosis is iron overload and deferoxamine therapy, which is being used to treat patients with diabetic ketoacidosis, haemodialysis and renal failure. However, this deferoxamine therapy makes the patients more likely to develop mucormycosis. The iron that is removed by the drug is used by the fungi to grow making a favorable condition for its development (Boelaert et al., 1991). Interestingly, mucormycosis is not just observed in patients with comorbid conditions, and it can also be seen in individuals after surgery, probably after using contaminated products (Jeong et al., 2019). A detailed explanation regarding various studies related to mucormycosis and its clinical studies is provided in Table 1. Since invasive mucormycosis is also predominant in clinical settings, it is imperative to maintain a sterile environment that is safe for patients. In addition, care should be taken while assisting patients with chronic conditions in clinical settings to prevent the onset of mucormycosis.

4. Mucormycosis mode of action in normal individuals

Mucormycosis is caused by the inhalation of its filamentous (hyphal form) fungi, especially in patients who have undergone weakness in the arsenal of immune defense. The characteristic phenotype of this disease is the growth of hyphae in and around the blood vessels, leading to life-threatening scenarios in severely immunocompromised patients. Once the fungal spores invade the human system, the hyphae intrude on the blood vessels, resulting in tissue infarction, necrosis and thrombosis. Mucormycosis occurs in the host by two steps: 1) by evading the immune system and surviving inside the host cell, 2) perturbation of the immune system further damaging the host cell (Brunke et al., 2016). In immunocompromised patients, iron is abundantly released via sequestering proteins which creates a favorable environment for the growth of fungi inside the human body. Also, Mucorales fungi consume iron using high-affinity iron permease and transport iron to development inside the host cell (Artis et al., 1982). The virulence factors of the pathogen play a key role to accomplish the damage. Spore coat (CotH) protein which is present on the spore surface of the Mucorales is responsible for penetrating, disrupting and damaging the immune cells (Gebremariam et al., 2014). The epithelial cells are the first line of contact to fungal pathogens, especially the mucoralean fungi damaging the epithelial cell via increased signaling of platelet-derived growth factor receptor B (PDGFRB) provides the proper growth factors to the fungi. The neutrophils are the first line of defense against these fungi, as these are an important part of the innate immune system and regulate the adaptive immune system (Jaillon et al., 2013). In diabetic or steroid use patients due to ketoacidosis or hyperglycemic conditions, the chemotactic factors released by neutrophils decrease thereby increasing the fungal hyphae in human hosts (Roilides et al., 2012). The Mucorales, after entering the host cell produces Mucorales-specific T-cells which generates interleukins (IL-4, IL-10 and IL-17) and IFN-γ. These pro-inflammatory cytokines further stimulate $CD4^+$ T cells and damage the host cell (Castillo et al., 2018; Potenza et al., 2011). Also, the fungal hyphae reduce the release of various immunomodulatory molecules such as RANTES (regulated upon activation, normal T-cell expressed and secreted) and IFN-γ, which are secreted by NK cells which appears in the early stage of infection (Schmidt et al, 2013, 2016bib_Schmidt_et_al_2016bib_Schmidt_et_al_2013). These key findings explain the susceptibility of immunocompromised patients to mucormycosis and its possible mechanism of action inside the host cell (Fig. 3A).

5. COVID-19 and mucormycosis: a tangled relation

The advent of COVID-19 has sprung upon the world myriad of conditions and complications (Balachandar et al., 2020a; Iyer et al., 2020; Mahalaxmi et al., 2021). Mucormycosis is an another milestone added in COVID-19, that has emerged as a deadly complication associated with COVID-19. In March 2021, 41 cases of COVID-19 associated mucormycosis has been reported worldwide and 70% were from India. There is a surge in these cases amidst the second wave in India (Monica Slavin and Karin Thursky, 2021). There have been 2245 cases and 120 deaths from the infection in Maharashtra state (Barnagarwala, 2021). As of June 5, 2021, Rajasthan reported 2651 cases and 85 deaths (Mukherjee, 2021) and Telangana reports around 50 cases daily (Ali, 2021). In Tamil Nadu, till June 9, 2021, total mucormycosis reported being to be 1196 (Josephine, 2021). The mucormycosis stemming from COVID-19 patients has been more commonly observed in patients with a history of diabetes mellitus and 95% of individuals with severe or critical COVID-19 (Alekseyev et al., 2021; John et al., 2021). In addition to this, a two month old heart transplant patient developed mucormycosis three months after the COVID-19 diagnosis. This was of the cutaneous type as the old intravascular device location and despite aggressive treatment, the patient had died (Khatri et al., 2021). This evidence indicates that transplant patients need more vigilant care in the clinical setting while managing COVID-19 as these patients are already predisposed to mucormycosis (Fig. 4). Similarly, a patient with acute myeloid leukemia (AML) also suffered mucormycosis after the COVID-19 infection (Zurl et al., 2021). Although these factors such as diabetes, organ transplantation and hematological factors are commonly linked to mucormycosis, it is evident that COVID-19 infection also acts as a trigger in these situations. In addition, it has also been observed that people with no history of any underlying condition can also be diagnosed with mucormycosis post-COVID-19 infection (Maini et al., 2021). There are many plausible explanations for the occurrence of mucormycosis post-COVID-19 infection. COVID-19 patients exhibit a wide array of pulmonary changes (Subramaniam et al., 2020; Vishnupriya et al., 2021) which may be a focal point for fungal initiation. Moreover, COVID-19 is also associated with immune dysfunction (Renu et al., 2020) preventing the polymorphonuclear phagocytes from attacking the fungal spores upon entry (Jayaramayya et al., 2020). Patients with severe COVID-19 also require a prolonged hospital stay and mechanical ventilation (Balachandar et al., 2020b); the occurrence of fungal spores in this equipment could also contribute to mucormycosis in these individuals (Khatri et al., 2021). The immunosuppressants and corticosteroid medications that are warranted in COVID-19 can contribute significantly to the occurrence of mucormycosis (Khatri et al., 2021). Further, in addition to hyperglycemia, COVID-19 also contributes to changes in iron metabolism. High ferritin levels have been observed in COVID-19, the high iron concentrations release reactive oxygen species while damaging the nearby tissue. The cytokines released during COVID-19 further increases intracellular iron and leakage of iron into the circulation, posing as a risk factor for the development of mucormycosis (John et al., 2021). Although the diagnosis of mucormycosis is mainly made by observing fungus in biopsies and culturing the tissue (Johnson et al., 2021), waiting for the cultures in the dire COVID-19 situation may be impractical as the progression of mucormycosis is speedy (Dallalzadeh et al., 2021). Also, other therapeutic options besides reversal of underlying cause must be implemented as the reversal of these conditions may not be possible while treatment is ongoing for

Table 1
Predisposing conditions for mucormycosis.

Underlying Disease	Organ/region infected with fungus	Fungus/Disease 3. Disease entities in mucormycosis	Objective	No. Of patients	Country	Methodology	Results & Conclusion	Reference
ROCM and Stroke	Paranasal region and Brain	Mucormycosis	Administration of amphotericin B and its complications to stroke and vasculopathy	6 cases	Taiwan	Questionnaire survey	• Fatal infarctions, thrombotic occlusion, haemorrhage anmycotic aneurysm. • Combination of ocular exenteration, radical debridement parenteral and local administration of amphotericin B should be considered.	Thajeb et al. (2004)
Gerstmann syndrome	Brain	Rhizomucor	Clinical examination and discussion of a case with aggressive mucormycosis	A 60-year-old women	USA	• MRI • CTA • Immunostaining	• Hemorrahage with mucormycosis observed • Early detection and management of the infection is needed	Stretz et al. (2017)
Cerebral mucormycosis	Brain – basal ganglia	Rhizopus	Analysis of a case with mucormycosis along with multiple risk factors	A 28-year-old man	USA	• CT scan • MRI • CSF and serum testing • Histopathological examination	• CSF and serum testing were negative. Fungal outgrowths were observed. Neurological status declined. • Hemorraghic abscess was noticed in autopsy. • Early detection and therapy treats the disease.	Malik et al. (2014)
Cerebral Lymphoma, vision loss, cirrhosis, diabetes	Brain	Mucormycosis	Analysis of fungal infection in orbital and CNS inflammation	A 61-year-old man	USA	• MRI • Biopsy • CT	• CSF analysis showed fungal infection • This fungal infection should be investigated in vision loss and orbital cellulitis patients	Beketova et al. (2018)
Rhinocerebral mucormycosis	Paranasal sinus, orbital and intra-cranial	Mucormycosis	To analyse the infection in CT scan to determine paranasal sinus, orbital and intra-cranial involvement	17 cases	India	• CT scan • Cadaveric dissections	• Ethmoidal sinus involved with infection then spread to orbital region and finally intra-cranial part. • If blood stained nasal discharge occurs, CT should be conducted along with amphotericin B treatment should be given.	Kulkarni et al. (2005)
Diabetes	Lungs	Pulmonary mucormycosis and tuberculosis	A diabetic case with fungal co-infection	A 56-year old female	Netherlands	• X-ray, CT scan • Biopsy • RT-PCR • lobectomy	• Treatment with TB and mycosis medications showed few adverse effects • Diabetic patients should undergo the examination of these co-infections	Jiménez-Zarazúa et al. (2019)
Chronic lymphocytic leukemia	Blood and bone marrow	Aspergillosis and Mucormycosis	Assessment of fungal infection in leukemia patient	A 79-year-old man	USA	• MRI • Immunoassay • NGS • CT • Autopsy	• No risk factors were associated other than corticosteroids. • More studies based on risk factors should be assessed	Tsikala-Vafea et al. (2020)
Septic shock	Intestine	Mucormycosis	Examination of fungal infection in immunocompetent individual	A 40-year-old male	Ethiopia	• CT scan • Colonoscopy	• Hepatomegaly, icterus sclera, intestinal infection • Investigation on mucormycosis should be carried out without traditional risk factors in immunocompetent patients	Wotiye et al. (2020)
Hypothyroidism	Throat	Aspergillosis and Mucormycosis	A case study treated with corticosteroids developed fungal infections	A 55-year-old female	Italy	• Electromyography • CT and MRI • CSF examination	• Hemiparesis and hypoesthesia observed. Low glucose level.	Mantero et al. (2019)

(*continued on next page*)

Table 1 (*continued*)

Underlying Disease	Organ/region infected with fungus	Fungus/Disease 3. Disease entities in mucormycosis	Objective	No. Of patients	Country	Methodology	Results & Conclusion	Reference
							Respiratory failure. Pulmonary empyema was observed. • Though corticosteroids taken for a short period led to low immune function	
Diabetes mellitus	Pansinusitis	Mucormycosis	Analysis of infection in a diabetic patient	A 56-year-old male	India	• MRI • MRA • Biopsy • GMS and PAS staining	• The fungal growth invaded sphenoid bone and to clivus and to basilar artery. • Early recognition and treatment is needed	Kumar, 2021
Diabetes mellitus	Eye	Mucormycosis	Optic nerve infarction due to mucormycosis in a diabetes case	A 51-year-old male	Texas	• MRI • Exenteration and sinus debridement	• Extensive infarction on the left optic nerve with ipsilateral cavernous sinus thrombosis and periorbital adnexal inflammation. • Mucormycosis confirmed on histopathology	Chaulk et al. (2021)
Optic neuropathy	Eye	Mucormycosis	A case with retrobulbar optic neuropathy linked with mucormycosis.	A 94-year-old women	Japan	• MRI • Histopathology	• Right eye with sphenoid sinus with mucormycosis • Clinicians should recommend invasive fungal sinusitis present as retrobulbar optic neuropathy	Sano et al. (2018)
Renal failure and diabetes mellitus	Eye	Mucormycosis	ROCM observed in a case with ophthalmic nerve infection.	A 34-year-old man	Taiwan	• Ophthalmic and neurological examination • CSF examination • MRI • Grams stain	• Black eschars observed in bilateral canthi extending to vascular region. It spreads to bilateral ophthalmic nerves and intracranial nerves. • Patients with neuro-ophthalmological signs should consider ROCM in immunocompromised patients	Lau et al. (2011)
Seizure	Brain	Rhizopus	Examination of the fungal infection in a case	A 49-year-old male	USA	• MRI and CT scan • CSF examination • Autopsy	• Cerebral mucormycosis with prominent vascular pathology and hemorrhagic necrosis was observed • Tissue diagnosis with surgical excision and antifungal therapy might rescue life from this condition	Verma et al. (2006)
Diabetic ketoacidosis with ophthalmoplegia	Nostril region	mucormycosis	Recovery from mucormycosis infection in a case	A 22-year-old women	USA	• CT scan • Nasoendoscopy • Biopsy	• Surgical removal of the right eye, paranasal sinuses maxilla and palate, suboccipitalcraniectomy and shunting for hydrocephalus. • Antifungal treatment for 18 months • Delivers the risk of infection with multiple surgeries	Zafar and Prabhu (2017)
Diabetes mellitus	Orbital region	*Rhizopusorzae*	Two cases treated with posaconazole and amphotericin B with sinus surgical debridement.	2 cases	China	• funduscopic examination • MRI • CT scan	• Orbital mucormycosis treated with antifungal medications. • This study highlights the unusual manifestations on orbital mucormycosis as well as antifungal treatment	Zhang et al. (2013)
Diplopia, otalgia and right side numbness. Autoimmune hepatitis	Cerebral region	Mucormycosis	Assessment of fungal infection in a 12 year old girl	A 12-year-old girl	USA	• MRI • Biopsy	• Infection observed with acute sinusitis and then developed to thrombosis and carotid artery. • Immediate surgical and antifungal therapy might control the infection.	Ibrahim et al. (2009)

(*continued on next page*)

Table 1 (*continued*)

Underlying Disease	Organ/region infected with fungus	Fungus/Disease 3. Disease entities in mucormycosis	Objective	No. Of patients	Country	Methodology	Results & Conclusion	Reference
Diabetes, kidney failure, myelodysplastic syndrome, acute leukemia,	Cerebral region	Mucormycosis	Retrospective study of 36 cases with mucormycosis.	36 cases	Mexico	• surgical debridement • CT scan • MRI	• Rhinocerebral and systemic mucormycosis. • The study recommended medical and surgical therapy	Rangel-Guerra et al. (1996)
HIV infection and diabetes	Cerebral region	Mucormycosis	Mucormycosis with vasculitis in a diabetic case	A 54-year-old woman	Brazil	• CSF analysis • CT scan • Histopathologic analysis and angiography with HR-VWI • Surgical debridements	• Vasculitis with inflammation • More studies required to examine the accuracy for mucormycosis.	de Moura Feitoza et al. (2019)
Diabetes mellitus	Cerebral region	Mucormycosis	Progressive ophthalmoplegia and blindness in infection	18-year-old woman	USA	• MRI • Lumbar puncture • Funduscopic examination • surgical debridement	• Fungal hyphae observed in ophthalmic artery and in the optic nerve perineurals heath without significant optic nerve inflammation. • The infection should be suspected in ophthalmoplegia and blindness in patients with diabetes	Hu et al. (2006)
Chronic lymphocytic leukemia	Cerebral region	*Rhizomucorpusillus*	A case study with mucormycosis in an immunocompromised host	61-year-old man	USA	• CT scan • GMS stain • Sequencing	• Histopathology revealed with mucormycosis. Amplification and sequencing of 28 S ribosomal RNA gene showed the fungal species • Early diagnosis and antifungal therapy along with surgery is recommended.	Farid et al. (2017)
Eye movement syndrome	Sphenoid sinus	Mucormycosis	Patient with the infection suffered simultaneous carotid artery occlusion with infarction and a contralateral horizontal gaze palsy.	54-year-old man	San Antonio	• CT scan	• Lesion observed in the cavernous sinus producing occlusion of the internal carotid artery. • Sensory symptoms were normal with the involvement of trigeminal nerve.	Carter and Rauch (1994)
Diabetes mellitus (three patients) and Chronic leukemia (one patient)	Cerebral region	Mucormycosis	Examination of fungal infection in 4 cases with underlying diseases	4 cases	Turkey (Abstract)	• CT scan • Otorhinolaryngologic examination	• Neurological abnormalities were observed. Two patients were dead. • Mucormycosis should be investigated in ophthalmoplegia and rapid diagnosis should be ensured.	Karakurum et al. (2005)
Diabetes mellitus with Cushing's syndrome	Cerebral region	Mucormycosis	Infection is associated with Cushing's syndrome and solid tumors	42-year-old women	Mexico	• CT scan • Autopsy	• Left temporal lobe infarction. Patient died and autopsy found out to be plurihormonal pituitary adenoma with extension to the sphenoid bone and sellar erosion. ACTH found in left lung. • The study correlated ACTH-producing ectopic pulmonary tumor, pituitary apoplexy and mucormycosis	Salinas-Lara et al. (2008)
Acute lymphoblastic leukemia	Cerebral region	Mucormycosis	A case of fatal invasive ROCM with thrombotic occlusion of the internal carotid arteries following hematopoietic stem	A 5-year-old boy	Switzerland	• MRI and angiography • Blood stem cell transplantation	• ROCM with bilateral thrombotic occlusion of the internal carotid arteries • Treatment should be initiated quickly for this type of case	Abela et al. (2013)

(*continued on next page*)

Table 1 (*continued*)

Underlying Disease	Organ/region infected with fungus	Fungus/Disease 3. Disease entities in mucormycosis	Objective	No. Of patients	Country	Methodology	Results & Conclusion	Reference
			cell transplantation for acute lymphoblastic leukemia.					
Stroke	Cerebral region	Mucormycosis	Outcome of stroke occurring in pregnancy and puerperium	36 patients	USA	• Questionnaire survey	• Stroke types revealed in varied pregnancy and the puerperium cases • Strokes are likely to occur in the third trimester and postpartum period and cluster in the first postpartum week	Skidmore et al. (2001)
Hodgkin's lymphoma	Cerebral region	Mucormycosis	Assessment of mucormycosis in lymphoma patient which ended in multiple stroke	A 56-year-old man	Spain	• MRI	• Multiple subcortical strokes with mucormycosis • Prognosis is poor and it is yet to be developed	Jiménez Caballero et al. (2012)
Diabetes mellitus and immunosuppression conditions	Cerebral region	Mucormycosis	Regional differences in the infection and its causes	–	Middle East and North Africa	• Data collection	• 310 cases with infection. Majority cases reported with diabetes and immunosuppressed conditions. • Effective treatment and preventive strategies should be implemented	Stemler et al. (2020)
Chronic lymphocytic leukemia	Cerebral region	Mucormycosis	A case of mucormycosis with cerebral involvement which ended in ischemic stroke	A 68-year-old man	Pennsylvania	• CT and MRI scans • Autopsy	• A left temporoparietal lesion with restricted diffusion and vasogenicedema. • CT scan suggested with ischemic stroke. • Autopsy showed greyish blue discoloration, and histological study revealed mucormycosis with vascular invasion and thrombosis • Consideration of angioinvasive organisms as the etiology of stroke might be necessary	Ermak et al. (2014)
Diabetes	Cerebral region	Mucormycosis	A case with diabetes infected with mucormycosis	Elder man	Victoria	• CT scan • Autopsy	• Thrombosis with infection in cerebral region • Early diagnosis is the key to effective therapy	Macdonell et al. (1987)
Diabetes mellitus with Garcin syndrome	Cerebral region	Mucormycosis	Analysis of infection and tuberculosis meningitis in a case with underlying disease.	–	China	• CT scan with X-ray	• Tuberculous meningitis developed to mucormycosis. • Diagnosis should be first in identifying the infection.	Yang and Wang (2016)
Diabetes mellitus	Cerebral region	Mucormycosis	To identify the prevalence and predisposing factors of mucormycosis in diabetes mellitus patients	162 patients	Iran	• Detailed history, and otorhinolaryngologic, ophthalmic • and neurologic examinations	• 30 people had diabetes (19 were women and 11 were men) • Diabetes may be predisposing factor for fungal infection	Sarvestani et al. (2013)
Acute lymphoblastic leukemia	Cerebral region	Mucormycosis	Treatment for leukemia resulted with infection and neuropathy	17-year-old-female	USA	• MRI • Thyroid hormone assessment	• Neuropathic pain developed with mucormycosis infection • Neuropathic pain is difficult to assess and can be a great source of pain suffering	Dworsky et al. (2017)
Leukemia	Cerebral region	Mucormycosis	Isavuconazole treatment risk assessment in leukemia patients	100 patients	Houston	• Questionnaire analysis	• 13 patients had the risk of isavuconazole in which had 4 cases with mucormycosis. • There is a lack of risk assessment in isavuconazole induced patients.	Rausch et al. (2018)

(*continued on next page*)

Table 1 (*continued*)

Underlying Disease	Organ/region infected with fungus	Fungus/Disease 3. Disease entities in mucormycosis	Objective	No. Of patients	Country	Methodology	Results & Conclusion	Reference
Acute leukemias	Cerebral region	*Rizopusspp*	Assess the risk factors of infection in children with leukemia	1136 subjects	Israel	• CT and MRI scan • GMS stain	• 39 children with mucormycosis. Fungal infection was highly associated with acute leukemia.	Elitzur et al. (2020)
Diabetes mellitus	Cerebral region	Mucormycosis	Identification of infection in diabetic patient with complications to acute infarction.	57-year-old man	Iran	• CT scan • Biopsy	• Subarachnoid haemorrhage with stroke. Biopsy showed mucormycosis infection. • Early interventions are necessary to avoid serious complications	Sasannejad et al. (2015)
Diabetes mellitus	Sinus region	*Rhizopusarrhizus*	To estimate the distribution of infection and its associated factors	208 cases	Iran	• Sequencing and data collection	• Increase in infection was observed from 2008 to 2014. • Monitoring and diagnosis of this infection is essential	Dolatabadi et al. (2018)
Multiple diseases	Cerebral region	*Rhizopusoryzae* and *Apophysomyceselegans*	Clinical course of mucormycosis	75 cases	India	• Data collection from hospital	• Diabetes with infection was common. Risk factors such as renal failure and chronic liver disease require attention • Surgical debridement needed for treatment	Chakrabarti et al. (2009)
CSS	Cerebral region	Mucormycosis	To assess the clinical and etiological profile of patients with CSS	73 patients	India	• hematological, biochemical and radiological examination	• Paranasal, bone erosion and internal carotid artery with infection • The patients can be diagnosed accurately	Bhatkar et al. (2017)
Diabetes mellitus and Hypothyroidism	Cerebral region	*Rhizopussps*	A progressive bilateral visual loss from mucormycosis due to bilateral optic nerve and retinal infarction in a patient with diabetes	62-year-old woman	New York	• MRI • Rhinosopic examination • Fundoscopic examination	• Progressive sinusitis, periorbitaledema and cellulitis, ophthalmoplegia, and unilateral visual loss • Pseudoephedrine use enhanced the *Rhizopus* growth	Merkler et al. (2016)
Parkinsonism	Cerebral region	Mucormycosis	Parkinsonism disease with mucormycosis infection	A 24-year-old man	USA	• CT and MRI scans	• Septate hypha was observed. Gradual improvement was observed followed by amphotericin B therapy • Infectious parkinsonism can result from fungal infections of the striatum.	Adler et al. (1989)
Hematologic malignancies or HCT recipients	–	Mucorales	Effect of isavuconazole in hematologic malignancies or HCT recipients	145 patients	Portland	• PCR • Radiograph assessment • Antifungal testing	• 12 patients showed fungal infections in which 2 had mucorales infection. • Increased rate of invasive fungal infection showed the need of primary prophylaxis.	Fontana et al. (2020)
Hematologic malignancies or HCT recipients	rhino-orbital-cerebral, pulmonary, disseminated, gastrointestinal and cutaneous	Mucormycosis	Antifungal treatment for hematologic malignancies or HCT recipients who were affected with mucormycosis.	64 patients	USA	• Data collection • Antifungal treatment	• Combinational treatment resulted with poor results. • More evidences need to be performed to confirm this observation.	Miller et al. (2021)
Lymphoid cancers	Cerebral region	Mucorales	Assessment of children with lymphoid cancers who developed fungal abscesses.	8 children	India	• Fungal abscess examination • Data collection. • Antifungal therapy	• Prolong antifungal therapy can achieve treating the infections	Ramanathan et al. (2020)
Hematological diseases	Cerebral region	Mucorales		689 patients	South Korea	• Biochemical analysis • Sequencing	• 27 patients had mucorales infection. • More diagnostic efforts are needed	Lee et al. (2020)

(*continued on next page*)

Table 1 (*continued*)

Underlying Disease	Organ/region infected with fungus	Fungus/Disease 3. Disease entities in mucormycosis	Objective	No. Of patients	Country	Methodology	Results & Conclusion	Reference
			Patients with hematological diseases assessed for fungal infections			• Fungal infection assessment		
Diabetes and non-diabetic patients	rhino-orbito-cerebral	Mucorales	Compare the fungal infection in diabetic and non-diabetic patients	63 patients	Iran	• Ophthalmic investigation • Imaging studies • Biopsy	• Patients' survival was observed in 51% of diabetics and 70% of non-diabetics • Vision survival were not different in both the groups	Abdolalizadeh et al. (2020)
Diabetes mellitus, Malignancy, transplant	rhino-orbital	Rhizopus	Prospective observational study with mucormycosis across 12 centres in India	465 patients	India	• Questionnaire analysis	• Shorter duration of symptoms, shorter duration of antifungal therapy, and treatment with amphotericin B were independent risk factors of mortality. • Diabetes was the major predisposing factor	Patel et al. (2020)
Lymphoid cancers	Lungs, CNS, sinus, liver and orbital regions	Mucorales	Evaluation of mycotic infection in hematological malignancies	37 patients	Italy	• CT scan • Antifungal treatment	• 28 patients died due to infection and 9 patients were cured by antifungal therapy.	Pagano et al. (1997)
Renal transplant	Rhino-cerebral and pulmonary regions	Mucorales	Investigation of infection in renal transplant patients	25 patients	Iran	• Biopsy	• Pulmonary infection was seen more than rhino-cerebral infection. • Mucormycosis has poor prognosis after renal transplantation	Einollahi et al. (2011)
Acute lymphocytic leukemia	cerebral	Mucormycosis	A case with leukemia reported with mucormycosis	3-year-old girl	France	• MRI and CT scan • Microscopic examination • qPCR	• Isavuconazole therapy showed promising effects • Combinational administration of amphotericin B was also given • Isavuconazolecan be an alternative or adjunct to amphotericin B	Cornu et al. (2018)
Congenital neutropenia	–	Mucormycosis	Neutropenia patient with recurrent infections.	–	Iran	• Molecular study	• HAX1 mutation observed. • Mucormycosis observed in immunodeficient patients. • Early diagnosis and treatment is essential.	Fahimzad et al. (2008)

ROCM: rhino-orbito-cerebral mucormycosis; MRI: Magnetic resonance imaging; CT: computed tomography; CTA: computed tomography angiography; GMS: Grocott–Gomorimethenamine silver stain; PAS: periodic acid–Schiff; HR-VWI: high-resolution vessel wall imaging; ACTH: adrenal corticotropic hormone; CSS: cavernous sinus syndrome; HIV: human immunodeficiency virus; CSF: cerebrospinal fluid; RT-PCR: reverse transcription polymerase chain reaction; NGS: next-generation sequencing; HCT: hematopoietic cell transplant; PCR: polymerase chain reaction; qPCR: quantitative polymerase chain reaction; HAX1: HCLS1 Associated Protein X-1.

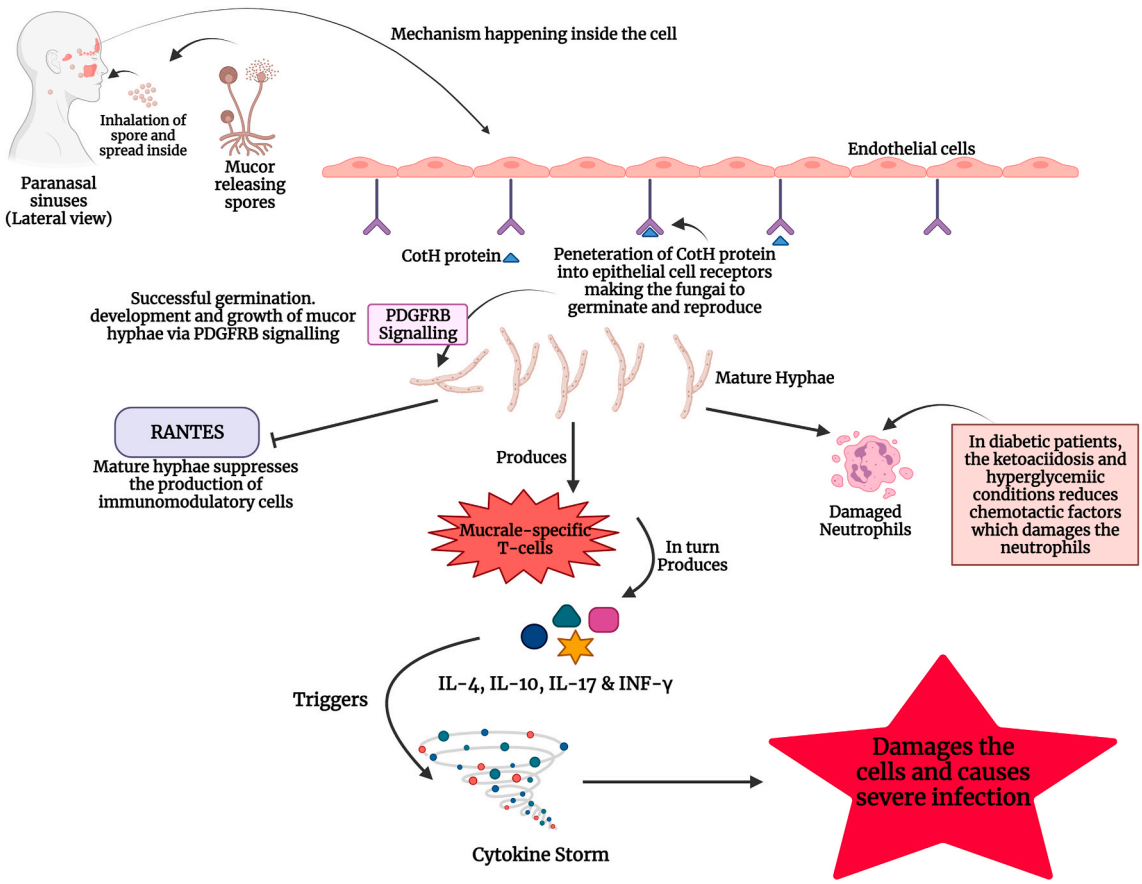

Fig. 3. (A): Mechanism of mucormycosis in healthy individuals: When the Mucorales enters an immune-compromised patient through inhalation, or through wounds, it is initially gets attached to the epithelial cells receptor using its CotH receptors. Further, the PDGFRB signaling pathways provides essentials for the proper development and growth of the fungal hyphae. Also, if the patients have diabetes, ketoacidosis and hyperglycaemia damage the neutrophils, making it easy for the fungi spread. Once the fungi are developed it starts to produce Mucorales-specific T cells which has various pro-inflammatory cells such as IL-4, IL-10, IL-17, IFN-γ, which triggers the cytokine storm resulting into cellular damages. **(B): Possible mechanism of mucormycosis in COVID-19 infected patients:** Mucormycosis is becoming common among COVID-19 patients, especially due to physiological stressors such as high body temperature osmolarity, hypoxia which are common conditions when affected with SARS-CoV-2. Also, these patients undergo heavy intake of steroids, use oxygen masks and ventilators to combat SARS-CoV-2 infection, which turns as an entry pass to the body for the Mucorales fungus. Further, this fungal infection could impact the COVID-19 in two-way scenario: 1) when the COVID-19 patients who have diabetes as co-morbidity, create an acidic environment that enables a unique environment for these fungi to grow. Also, due to hyperglycaemia, there is a decrease production of T-cells and immunosuppression, resulting in a cytokine storms. 2) heavy intake of steroids also release a huge amount of sugar which helps in the rapid multiplication and growth of fungal hyphae. Also, steroids tend to inflammation the immune cells leading to cytokine storm and damage to cellular organs.

COVID-19. This is especially true due to the need to use high doses of steroids for the treatment of COVID-19 (Moorthy et al., 2021; Sharma et al., 2021). In this condition, it is evident that the use of antibiotics and steroids may be dangerous for some patients as they may trigger the onset of these life-threatening fungal infections. It is extremely important for the doctors treating patients with COVID-19 to be mindful of patients with underlying illnesses and prescribed steroids or immunosuppressants (Sarkar et al., 2021). Despite the tremendous burden on the healthcare system due to the overwhelming increase in cases, more vigilance is required in utilizing preventive measures for this condition (Kanwar et al., 2021). Also, it is important to periodically check the air in the hospital wards and the oxygen therapy machinery for spores (Suryanarayanan and Shaanker, 2021). In addition, recovered patients should also be advised to stay indoors for few weeks to build up their immunity and follow-up studies to prevent any adverse complications. Since it's important that care should be taken in disposal of solid waste of COVID-19 patients, similar measures must be undertaken for individuals with the infection (Iyer et al., 2021). Moreover, there is an urgent need to develop prompt diagnostic measures to manage mucormycosis in time (Veisi et al., 2021). The proper management of mucormycosis must be prioritized to prevent more COVID-19 related deaths.

6. Possible role of action of mucormycosis among COVID-19 patients

The symptoms of COVID-19 includes a rise in body temperature, osmolarity, hypoxia and breathlessness (Balachandar et al., 2020a). The COVID-19 recovered patients of late have been distressed with a new infection called mucormycosis disease. This fungal disease could easily invade the sinus and lungs, making its way to intra-orbital and intra-cranial regions of the body (Sundaram et al., 2014). The main symptoms of COVID-19 create a perfect environment for the growth and development of Mucorales inside the human body. Hosts susceptible to mucormycosis include diabetics, those on systemic corticosteroid use, patients with neutropenia and hematologic malignancies, stem cell transplant patients and immunocompromised individuals (Binder et al., 2014). Reports suggest that diabetic patients are more prone to acquire COVID-19 accompanied by mucormycosis infection (Mehta and Pandey, 2020; Mekonnen et al., 2021; Ahmadikia et al., 2021; Alekseyev et al.,

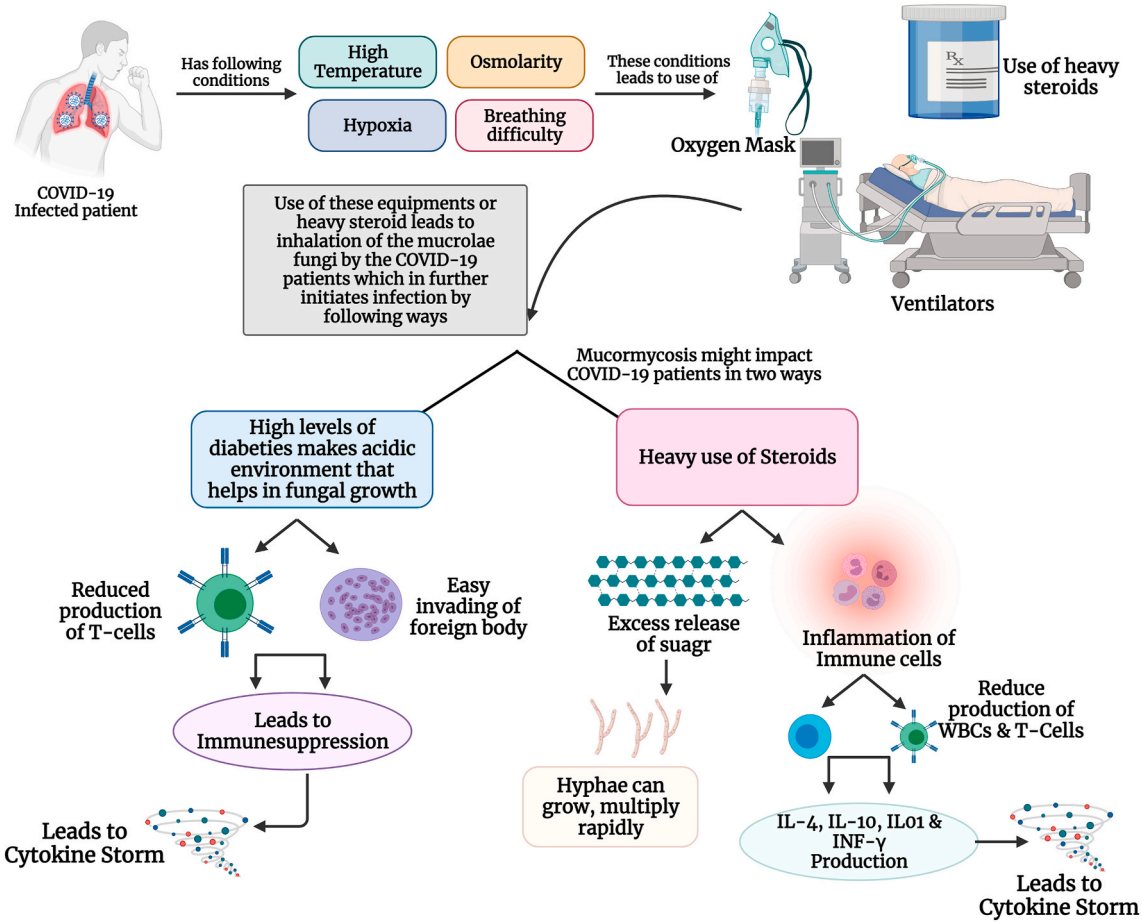

Fig. 3. (*continued*).

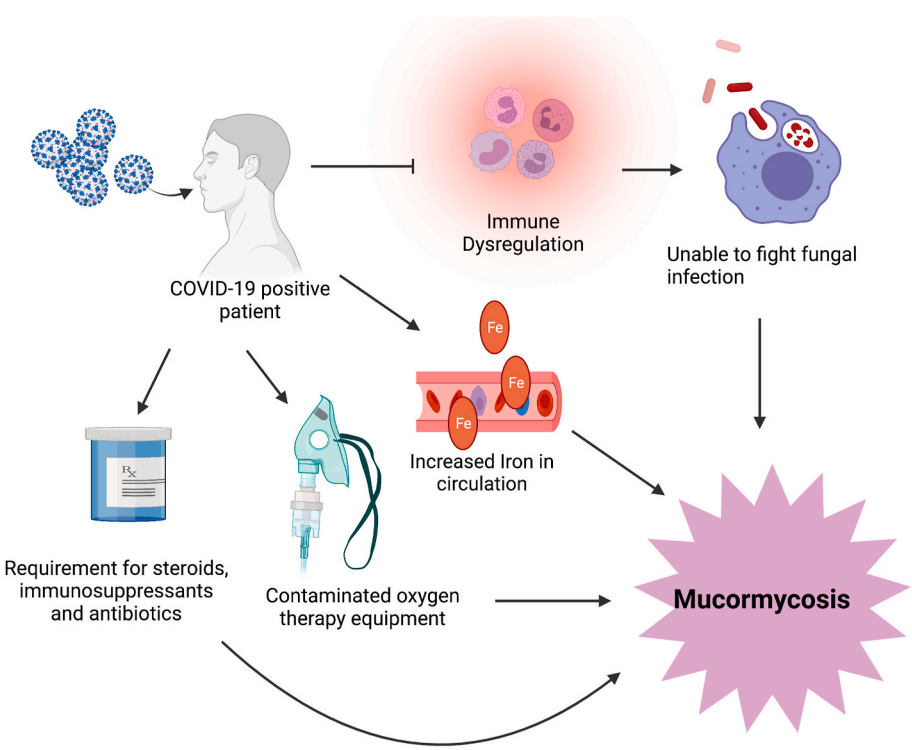

Fig. 4. COVID-19 and mucormycosis: A COVID-19 infected patient may be more susceptible to mucormycosis because, of a dysregulated immune system and may receive immune suppressant drugs that prevent the phagocytic cells in the body from attacking the fungus at an optimum level. COVID-19 also increases iron in the circulation and the fungus uses this iron to grow and proliferate and making the individual more vulnerable to infection. COVID-19 infected individuals are often given oxygen therapy. Contamination in these devices can serve as points of mucormycosis infection. The steroid therapy offered to COVID-19 patients places them at further risk for this condition.

2021; Garg et al., 2021; Ravani et al., 2021). The potential mechanism by which diabetes increases COVID-19 morbidity, and mortality is a) reduced viral clearance, b) decrease in T-cell function, c) high cytokine storm, d) immune-suppression (Balachandar et al., 2020b). Hyperglycemia worsens the cytokine storm by disrupting endothelial cells leading to multi-organ damage in COVID-19 patients. During diabetic ketoacidosis, the acidic environment and increase in the levels of free ferric ions support the growth of Mucorales. These circumstances support the invasion and successful attachment of the hyphae from the Mucorales inside the body. Individuals with chronic diabetes accompanied with foot ulcers are prone to this infection as any injured skin tissue is an easy entry route for this fungus. Further, treatment for COVID-19 is still preliminary (Kar et al., 2020; Kinoshita et al., 2021), and to combat the effect of SARS-CoV-2 infection, patients are given heavy doses of steroids (corticosteroids), as it reduces the inflammation in the lungs and might also curb the damages that had happened in the body due to the cytokine storm. Meanwhile patients affected with this new strain of COVID-19 are mostly treated with heavy steroids, extreme use of oxygen masks and ventilators which makes these patients more susceptible to mucormycosis. Steroids reduce both inflammation and the activity of the immune system, where the production of white blood cells (WBCs) and T-helper cells are decreased, making it easy for any foreign substances to invade and completely corrode the immune system in the host cell. Also, these steroids could trigger the uncontrolled release of sugar, which also enables the Mucorales to grow, multiply and invade at a rapid rate ("What patients with diabetes, cancer and kidney disorders need to know about black fungus," 2021). Only a few case reports have been published regarding the impact of mucormycosis on COVID-19 affected patients (Table 2). Hence, these possible mechanisms have been listed based on the points and suggestions provided by various doctors and researchers (Fig. 3B), where the above-explained reasons may be potential factors for the occurrence of mucormycosis among COVID-19 recovered or infected patients.

7. Unravelling the factors supporting mucormycosis in COVID-19

Mucormycosis is an invasive infection caused by naturally occurring fungus in the soil and human beings get infected by inhaling the spores floating in the air. These spores get lodged in the nasal passages and sinuses and cause the disease. Black Fungus is a rare fungal infection and is primarily contracted in the Intensive Care Unit (ICU) of a hospital and can be fatal, causing loss of vision and even death. Earlier symptoms include greyish-black pigmentation in the nose or oral cavity and blockage of the nasal cavity. Spores of fungus near the eyes leads to ocular swelling, and a few patients may get lesions over the cheeks. At a later stage, this fungus can make its way to the brain. It is quite severe, and the fatality rate can go up to 50%. Treatments include antifungal drugs like amphotericin-B that are given intravenously and supportive therapy. Healthcare workers and ICU technicians should be educated to change flow meters frequently and to sterilize oxygen tubing. Besides alveolar damage with severe inflammatory exudation, COVID-19 patients always have immunosuppression with decreased CD4 + T and CD8 + T cells (Yang et al., 2020a, 2020b). Critically ill patients, especially the patients admitted to the ICU with mechanical ventilation or who had a longer duration of hospital stay, are more likely to develop fungal co-infections (Yang et al., 2020a, 2020b). The symptoms of mucormycosis includes infection that can vary from person to person, these symptoms include headache, fever, facial, nasal pain, blackish nasal discharge, loss of vision, toothache (Loss of teeth, swelling in the upper jaw) and paralysis. Unless treated, this infection can cross the central nervous system (CNS) and become a life-threatening disease. Early diagnosis can be lifesaving, but the infections can be extremely challenging to treat, even at an early stage. These patients are treated with amphotericin-B injections, but these drugs can induce substantial side effects, including kidney damage. In less severe cases, endoscopy has been inserted into the nasal cavity to remove the fungus. In the severe spread of infections, the surgeon will remove the infected part. Earlier identifications of fungal co-infections can significantly reduce the mortality rate.

8. Depletion of organs due to mucormycosis

Mucormycosis can frequently infect the sinuses, brain or lungs but it has been said that it can also the impact on oral cavity, gastrointestinal tract, skin and other organs. The infection of mucormycosis could result in the following outcomes in different organs 1) when infected in the sinusitis, it blocks the nasal cavity leading to blackish or bloody discharge; 2) Face-local pain on cheekbone, one-sided facial pain or numbness; 3) Oral cavity-loosening of teeth or jaw; 4) Eye-blurred/double vision, vision loss; 5) Skin-thrombosis or necrotic skin lesion; 6) Lungs-chest pain, worsening of respiratory symptoms. However, in COVID-19 affected patients, mostly it affects the eye, oral region and brain.

8.1. Eye

The mucormycosis infection classically starts its journey inside the human body in the nasal or maxillary sinus and spreads to sphenoid or ethmoid sinus. After which it intrudes the orbit via ethmoid foramina or nasolacrimal duct or by splitting lamina papyracea (Sundaram et al., 2014; Teixeira et al., 2013). The lesion in the eye occurs due to the angioinvasion of the germinated hyphae resulting in dry gangrene. Whereas when the angioinvasion occurs via cavernous sinus thrombosis/internal carotid artery results in cerebral infarction, mycotic abscesses or aneurysms and hematogenous dissemination (Ochiai et al., 1993; Sundaram et al., 2014). When the blood vessel necrosis occurs in the ophthalmic artery it might lead to blindness, cranial nerve palsies and other motor and sensory deficits.

8.2. Mouth

Mucormycosis occurs in the oral cavity mainly due to spread of spores through inhalation, open oral wounds, ulceration or an extraction socket in the mouth, particularly in the patients who are immune-compromised (Rajashri et al., 2020). Diagnosis can be made based on the appearance of necrotic lesions in the form of pressure sores in the orbital-nasal region, the palate or the floor of the mouth. The infection of mucormycosis especially in the maxillofacial regions spreads to regions such as the oral cavity, maxilla, palate, nose, paranasal sinuses and finally into CNS (Bakathir, 2006). Angioinvasion of Mucorales and its spores into the blood vessels leads to the thrombus formation, which causes progressive necrosis of associated hard and soft tissues.

8.3. Brain

The manifestation of mucormycosis in the CNS mainly questions the survival rate and proper functioning of the organs in the infected individual. After the entry of the fungus, the invasion occurs either via hematogenous spread or by direct cranial dispersion from the paranasal sinuses. Patients who have diabetes mellitus as a major co-morbidity for mucormycosis, the CNS becomes the third most common site of infection (Bannykh et al., 2018; Higo et al., 2015). The fungal hypha develops in the internal elastic lamina and spreads to the arterial lumen, eradicating intravascular thrombosis. Vascular occlusion leading to cerebral infarction and hemorrhagic necrosis, even before hyphal invasion in brain tissue (Economides et al., 2017). Hyphal invasion of the necrotic brain parenchyma occurs in advanced CNS mucormycosis and might lead to death (Malik et al., 2014). Hence, the growing piece of evidence shows that it is important to have options open to diagnose this disease in different dimensions. It has several sites of infection mainly attacking the immune system and causing infection in individuals.

Table 2
Recent studies on COVID-19 cases with Mucormycosis.

Age of COVID-19 case	Symptoms	Clinical History	Clinical examination	Treatment	Study Findings and Conclusion	Reference
60-year-old male	severe breathlessness, pyrexia, tachypnea, and generalized malaise	diabetic (>10 years) pulse rate was 80/minute, blood pressure was 150/90 mmHg, Patient was afebrile on admission, respiratory rate was 26/minute, with a specific oxygen saturation of 86% on oxygen supplementation (10 L/min) bilateral crepts at the lung non-healing ulcer with the diabetic peripheral vascular disease was observed on right foot	• RT-PCR • CT scan • MRI	oral anti hypoglycemic tablets intravenous meropenem, oral oseltamivir with intravenous methylprednisolone and dexamethasone subcutaneous enoxaparin (40mg/0.4 ml) twice daily	• Acute respiratory distress syndrome deteriorated. • Ophthalmic examination observed with conjunctival edema and signs of exposure keratitis. MRI observed with mucormycosis. • COVID-19 associated with secondary infections due to immune dysregulation	Mehta and Pandey, (2020)
33-year-old Somali female	hypertension and asthma with altered mental status	patient began with symptoms of vomiting, cough, and shortness of breath 2 days prior to presentation. Signs of mild tachycardia, hypertension, and tachypnea. Afebrile and normal oxygen saturation. Left eye ptosis with 1 cm proptosis	• Chest X-ray • CT scan • MRI scan	Vancomycin and piperacillin-tazobactam, Amphotericin B	• Multifocal signal abnormality with edema, and evidence of ischemia and infarction. Cerebral edema had evolved into multiple encapsulated complex fluid. Mucormycosis was observed on sinusitis region • The patient's severe immunocompromised state from untreated diabetes, and ultimately diabetic ketoacidosis is what made her vulnerable to contract both mucormycosis and COVID-19.	Werthman-Ehrenreich (2021)
60-year-old man	diabetes, asthma, hypertension, hyperlipidemia and recent travel with dyspnea and hypoxia	Reported COVID-19 negative, and was discharged and later noticed with elevated level of glucose with oxygen demand. Was tested COVID-19 with ARDS	• CTA • Sinus histopathology • MRI • Fundus examination	Intravenous vancomycin and cefepime, antifungal coverage with liposomal amphotericin B, and strict glucose management. Dexamethasone 6 mg daily and a single dose of convalescent plasma as a treatment for COVID-19	• Partial opacification of the right sphenoid sinus and erosions of the lamina papyracea was observed. • Clinical and radiographic findings noticed with fungal rhinosinusitis. The right eye had mild proptosis with erythema and edema of the eyelids and conjunctival chemosis • Co-infection COVID-19 and *Rhizopus*. These diseases share risk factors, have high mortality rates, but presently have contradictory management principles.	Mekonnen et al, (2021)
9 patients	COVID-19 infection	Post-mortem examination conducted.	• Histochemical analysis • Immunohistochemical analysis • Histopathological analysis • RT-PCR	–	• Thrombotic features were observed. Lymphocyte depletion. Acute tubular injury was observed in all patients. Acute pancreatitis, adrenal	Hanley et al. (2020)

(*continued on next page*)

Table 2 (*continued*)

Age of COVID-19 case	Symptoms	Clinical History	Clinical examination	Treatment	Study Findings and Conclusion	Reference
					micro-infarction, pericarditis, disseminated mucormycosis, aortic dissection and marantic endocarditis were the major findings. Viral genomes were detected outside of the respiratory tract in four of five patients. • Additional examination of secondary infection should be considered to understand the role of COVID-19	
86-year-old male	arterial hypertension with acute diarrhea, cough, dyspnea, and fever	Throat swab confirmed COVID-19	• CT scan • EGD • GMS	ceftriaxone, azithromycin, oseltamivir, and hydrocortisone was provided.	• Pathologucal examination confirmed mucormycosis. Two giant gastric ulcers with dirty debris and a deep hemorrhagic base without active bleeding located in the greater and lesser curvature • Mucormycosis should be considered if atypical gastric ulcer in observed in COVID-19 patients	do Monte Junior et al. (2020)
44-year-old women	Diabetes mellitus observed. Fever, malaise, myalgia, dry cough and partial dyspnoea was noticed.	Positive for influenze and negative for COVID-19	• RT-PCR • CT scan • H&E stain • MRI	amphotericin B and posaconazole was administered.	• Abundant aseptate hyphae was observed in sinusitis region • COVID-19 associated mucormycosis is highly risky than influenza causing infection. More studies required to explore prognostic factors	Ahmadikia et al. (2021)
41-year-old man	Diabetes mellitus with loss of taste and cough.	Deep pain in the nose which radiated to throat. Oral cavity noted with black eschar	• Chest X-ray • CT scan • RT-PCR • MRI	Cefepime and IV abelcet, which is amphotericin B complexed with two phospholipids	• Bilateral lung infiltrates and chronic sinusitis was observed. RT-PCR reported to be positive for COVID-19. Sinuses and intracranial abscess in the infratemporal fossa with cavernous sinus enhancement • The severity of infection is due to uncontrollable diabetes with COVID-19	Alekseyev et al. (2021)
31 patients	Diabetes, COVID-19	Vision diminution and ophthalmoplegia	• Ophthalmic examination • Imaging studies	amphotericin B	• Orbital cellulitis and pansinusitis was observed with mucormycosis. 28 patients recovered. • Rhino-orbital mucormycosis significant during COVID-19	Ravani et al. (2021)
6 patients	COVID-19	ptosis and ophthalmoplegia, edema, ptosis and proptosis, conjunctival congestion, and severe chemosis	• Histopathologic examination • Cytopathologic examination • Microscopic evalaution	Corticosteroids, posaconazole was initiated	• Infection with mucor was observed • High index of suspicion, early diagnosis, and suitable management is recommended	Sen et al. (2021)
55-year-old man	diabetes mellitus,	Respiratory rate was 26 breaths/	• Chest X-ray • RT-PCR	examethasone and remdesivir	• Bilateral diffuse infiltrates and	Garg et al. (2021)

(*continued on next page*)

Table 2 (*continued*)

Age of COVID-19 case	Symptoms	Clinical History	Clinical examination	Treatment	Study Findings and Conclusion	Reference
	hypertension, and ischemic cardiomyopathy presented with fever, dry cough, and progressive breathlessness	minute, blood pressure 110/80 mmHg, and heart rate of 90 beats/minute. The oxygen saturation was 84%	• CT scan • LCB mount		cardiomegaly. Aseptate hyphae with nodal rhizoids and short sporangiophores with terminal spherical sporangia filled with brownish sporangiospores was observed on mounting. • *Rhizopus microsporus* observed to be a serious infection in COVID-19 patients. Early diagnosis and treatment is essential in pulmonary mucormycosis.	
66-year-old male	COVID-19 positive	Deterioration of oxygen.	• CT scan • LCB mount	hydroxychloroquine and lopinavir-ritonavir	• Buried cavitary lesions in the left lung and cranial CT showed corpuscular material in the left maxillary sinus. Mounting showed aseptate broad hyphae, sporangia and sporangiospores • COVID-19 impairs immune response and expose patients to opportunistic infections.	Pasero et al. (2020)
38-year-old male	COVID-19 positive.	high grade fever, body ache, cough and shortness of breath	• RT-PCR • MRI • Lactofuchsin staining	Methylprednisolone, Dexamethasone. Intravenous Fluconazole and Amphotericin B	• Malaise, proptosis, chemosis, periorbital cellulitis and restricted medial gaze was observed. Partial opthalmoplegia and no nasal discharge were seen. Aseptate, branching broad based fungal hyphae, areas of necrosis with granulomas were seen. • *Rhizopus oryzae* was noticed in COVID-19 patients hence better prevention and management is required	Maini et al. (2021)
32 year old women	Diabetes with ptosis and left facial pain		• CT scan • Nasal endoscopy • MRI	–	• Opacification of the left ethmoid, maxillary and frontal sinus indicative of fungal sinusitis. Subperiosteal lesion in the superomedial extraconal of the left orbit • Orbital apex syndrome with mucormycosis in COVID-19 patients requires emergency diagnosis and treatment strategies.	Saldanha et al. (2021)
Middle aged women	Diabetes mellitus with ptosis	Sinuses on the left side	• MRI • CT scan • Chest X-ray	Amphotericin B and aspirin. Antifungal treatment	• Opacification of the left ethmoid, maxillary and frontal sinuses. Inflammation of internal carotid artery and acute infarct of the parieto-occipital lobe. Ethmoid sinusitis impinging on the lamina papyracea. • Imaging studies are recommended in	Revannavar et al. (2021)

(*continued on next page*)

Table 2 (*continued*)

Age of COVID-19 case	Symptoms	Clinical History	Clinical examination	Treatment	Study Findings and Conclusion	Reference
					COVID-19 patients with fungal co-infection.	
40-year old woman and a 54-year old man	COVID-19	–	• Histopathology • Nasal endoscopic examination • Radiologic findings	corticosteroid therapy and amphotericin B	• Bilateral visual loss, ophthalmoplegia proptosis and orbital inflammation. Mucormycosis in both the patients • Steroidal treatment might have caused fungal infection in COVID-19 patients	Veisi et al. (2021)
79-year old male	diabetes mellitus and hypertension	fevers, rigors, dry cough, and worsening shortness of breath	• RT-PCR • Chest X-ray • CT scan • BAL culture	Ceftriaxone, azithromycin, remdesivir, dexamethasone, voriconazole	• COVID-19 positive with septate hyphae and characteristic conidial heads by *Rhizopus arrhizus* and *Aspergillus fumigatus* fungus. • Pulmonary aspergillosis and mucormycosis in COVID-19 patients as secondary infections	Johnson et al. (2021)
68-year old male	Hyperglycemia and acute renal failure	non-productive cough with non-bloody diarrhea, fever	• CT scan	Prednisone, mycophenolate mofetil, tacrolimus, atovaquone, nystatin, valganciclovir, hydroxychloroquine	• Purplish skin discoloration with fluctuant swelling • Evaluation for invasive fungal infections in patients with COVID-19 infection should be recommended	Khatri et al. (2021)
2 cases (Abstract)	diabetes mellitus and ketoacidosis	–	–	corticosteroids	• Fungal infection with rhino-orbital-cerebral mucormycosis • Early diagnosis is important in COVID-19 patients	Dallalzadeh et al. (2021)
24-year-old female	Obesity	COVID-19 with respiratory failure and oxygen saturation	• CT scan • RT-PCR • Fungal culture	–	• Swelling of the left inferior turbinate and thickening of the mucosa of the maxillary, ethmoid, and sphenoid sinuses on the ipsilateral side. Rhino-orbital mucormycosis • The study recommends mycotic infection in COVID-19 patients with diabetes	Waizel-Haiat et al. (2021)
49-year-old male	–	fever, cough, and shortness of breath	• Chest X-ray • RT-PCR	ceftriaxone and azithromycin, enoxaparin, remdesivir	• COVID-19 infection and necrotic empyema with mucormycosis • Immunocompromised condition developed with fungal infection	Placik et al. (2020)
53-year old male	acute myeloid leukemia, myelodysplastic syndrome, obesity and depression	sore throat, parageusia, dysosmia and fever	• RT-PCR • Chest X-ray • BAL and PAS	Corticosteroids and antibacterial therapy	• COVID-19 positive • BAL showed mixed nonpathogenic flora. Lungs observed with Rhizopus microsporus • COVID-19 ARDS with acute myeloid leukemia was observed with mucormycosis in postmortem	Zurl et al. (2021)
66-year-old male	Diabetes mellitus	–	• KOH mount	–	• COVID-19 with ophthalmoplegia. Rhino-orbital cellulitis with ischemia • This was the first study with orbital infarction	Rao et al. (2021)

(*continued on next page*)

Table 2 (*continued*)

Age of COVID-19 case	Symptoms	Clinical History	Clinical examination	Treatment	Study Findings and Conclusion	Reference
					syndrome in COVID-19 patient	
56-year-old man	Renal disease	fatigue and shortness of breath	• Chest X-ray • RT-PCR • GMS and pleural fluid culture • CT scan • MALDI-TOF	methylprednisolone and tocilizumab	• COVID-19 with mucormycosis • Higher mortality rate in COVID-19 with mucormycosis	Kanwar et al. (2021)
31 patients	Different diseases	COVID-19 symptoms	• Pathological examination	–	• Mucormycosis found in 1 patient • Reconstruction of head and neck during COVID-19 pandemic	Rashid et al. (2021)
18 patients	16 patients were diabetic	facial cellulitis, maxillary sinusitis, headache, necrosis of palatal bone/mucosa or acute loss of vision	• MRI and CT scans • KOH mount	voriconazole, posaconazole	• Maxillofacial and rhino-cerebro-orbital fungal infections • Significant increase of angioinvasive maxillofacial fungal infections in diabetic patients with COVID-19	Moorthy et al. (2021)
55-year-old man	follicular lymphoma	Inflammatory response	• RT-PCR • BAL	amphotericin B	• COVID-19 infection with fungal growth of A. fumigatus and Rhizopus microsporus • Fungal infection with immunocompromised COVID-19 patients is a rare one	Bellanger et al. (2021)
23 patients	Diabetes mellitus, renal failure and hypertension	COVID-19 positive cases	• MRI and CT scan	Steroids	• Mucormycosis in the paransal sinuses • Uncontrolled diabetes and usage of steroids aggravates the fungal infection.	Sharma et al. (2021)

ARDS: acute respiratory distress syndrome; EGD: Esophagogastroduodenoscopy; GMS: Grocott's methenamine staining; H&E: haematoxylin and eosin; LCB: Lactophenol cotton blue; BAL: bronchoalveolar lavage; PAS: periodic acid–Schiff; KOH: potassium hydroxide; MALDI-TOF: Matrix-assisted laser desorption ionization time-of-flight; MRI: magnetic resonance imaging, CT: computed tomography; COVID-19: coronavirus disease 2019; RT-PCR: reverse transcription polymerase chain reaction.

9. Challenges faced due to mucormycosis

Mucormycosis is a fungal infection with a high mortality rate of 50 percent. An increasing number of COVID-19 patients have been developing this infection while still at the hospital or after discharge. Patients hospitalized for COVID-19 and particularly those who require oxygen therapy during COVID-19 illness are at a much higher risk of mucormycosis. Inhalation of Mucor spores by patients with a compromised immune system will lead to colonization of the fungus, invasion of the host and development of mucormycosis. Individuals with uncontrolled diabetes are at a higher risk of mucormycosis because the high blood sugar levels make it easier for the fungi to grow and survive. Their weaker immune systems offers less protection against the infection. Hot and humid conditions, oxygen, humidifiers and oxygen delivery masks may contribute to the spread of infection. Delay in diagnosis and treatment can make the impact of this fungal infection deadlier.

10. Conclusion

COVID-19 has put the entire world in turmoil situation, and an exact cure for this deadly infection has not been found yet. Its an infection, the consequential immunosuppression, former co-morbidities and its medications have made the patients susceptible to secondary fungal infections such as Mucormycosis. This is an opportunistic fungal infection that is caused due to mucor hyphae that are commonly available in soil, plants, dungs, rotting fruits and vegetables. The COVID-19 affected patients who are more susceptible to these infections are immunocompromised, have diabetes, and are prescribed heavy steroids. As mucormycosis is angioinvasive, once inhaled, its spores begin to grow, and the fungal hyphae invade the blood vessels, further contributing to tissue infarction, necrosis and thrombosis. This fungal infection is life-threatening as it occurs among those who have immunosuppression accompanied with diabetic ketoacidosis, neutropenia, increased serum levels of iron, excess release of sugar due to overtake of steroids which finally results in a decrease in levels of WBCs, T-cells and other immunomodulatory cells and triggers the cytokine storm that damages the cellular organs. Therefore, researchers and healthcare professionals should promptly control this mucormycosis infection by understanding its influence and range of severity, especially on COVID-19 patients. A multidisciplinary approach should include prompt diagnosis, treatment with antifungals, any appropriate surgical consultation and treatment, which may reverse the underlying condition. Additional research in this area is recommended to investigate the mucormycosis in COVID-19 infected and recovered patients. Hence vigorous investigations to emphasize the root cause of mucormycosis, specifically in COVID-19, should be under the scope of research. A diagnostic study for this opportunistic pathogen should not be ignored in case the patient is COVID-19 positive and immunosuppressed.

Funding

This work was supported by the Project funded by MHRD-RUSA 2.0 – BEICH (Dr.VB).

Credit author statement

Conceptualization: BV; IM; KJ; MDS. Data curation: IM; KJ; MDS; DV; KR; PV. Project administration: BV; AN; AVG; PS; MDS; NSK; KRSSR. Supervision: BV; MDS; NSK; KRSSR. Validation: IM; KJ; MDS; DV; KR. Roles/Writing - original draft: IM; KJ; MDS; DV; BV. Writing - review & editing: IM; KJ; MDS; DV; AN; AVG; PS; MDS; NSK; KRSSR; BV.

Declaration of competing interest

The authors declare that they have no known competing financial interests or personal relationships that could have appeared to influence the work reported in this paper.

Acknowledgements

The author Dr. VB would like to thank Bharathiar University and Mizoram University (DBT- Advanced State Biotech Hub)for providing the necessary infrastructure facility and the RUSA 2.0 BEICH Project (Bharathiar University) for providing necessary help in carrying out this review process of the manuscript.

References

Abdolalizadeh, P., Kashkouli, M.B., Khademi, B., Karimi, N., Hamami, P., Es' haghi, A., 2020. Diabetic versus non-diabetic rhino-orbito-cerebral mucormycosis. Mycoses 63, 573–578.

Abela, L., Toelle, S.P., Hackenberg, A., Scheer, I., Güngör, T., Plecko, B., 2013. Fatal outcome of rhino-orbital-cerebral mucormycosis due to bilateral internal carotid occlusion in a child after hematopoietic stem cell transplantation. Pediatr. Infect. Dis. J. 32, 1149–1150.

Adil, A., 2021. Over 28,200 'black Fungus' Cases Recorded in India. Anadolu Agency, 2021. https://www.aa.com.tr/en/asia-pacific/over-28-200-black-fungus-cases-recorded-in-india/2266396. accessed 6.21.21.

Adler, C.H., Stem, M.B., Brooks, T.L., 1989. Parkinsonism secondary to bilateral striatal fungal abscesses. Mov. Disord.: Off. J. Movement Disord. Soc. 4, 333–337.

Ahmadikia, K., Hashemi, S.J., Khodavaisy, S., Getso, M.I., Alijani, N., Badali, H., Mirhendi, H., Salehi, M., Tabari, A., MohammadiArdehali, M., 2021. The double-edged sword of systemic corticosteroid therapy in viral pneumonia: a case report and comparative review of influenza-associated mucormycosis versus COVID-19 associated mucormycosis. Mycoses. https://doi.org/10.1111/myc.13256.

Alekseyev, K., Didenko, L., Chaudhry, B., 2021. Rhinocerebral mucormycosis and COVID-19 pneumonia. J. Med. Cases 12, 85. https://doi.org/10.14740/jmc3637.

Ali, M., 2021. Telangana: Black Fungus Patients Losing Sight. The Hans India. https://www.thehansindia.com/news/cities/hyderabad/telangana-black-fungus-patients-losing-sight-689329. accessed 6.21.21.

Almyroudis, N., Sutton, D., Linden, P., Rinaldi, M., Fung, J., Kusne, S., 2006. Zygomycosis in solid organ transplant recipients in a tertiary transplant center and review of the literature. Am. J. Transplant. 6, 2365–2374. https://doi.org/10.1111/j.1600-6143.2006.01496.x.

Artis, W.M., Fountain, J.A., Delcher, H.K., Jones, H.E., 1982. A mechanism of susceptibility to mucormycosis in diabetic ketoacidosis: transferrin and iron availability. Diabetes 31, 1109–1114. https://doi.org/10.2337/diacare.31.12.1109.

Asghar, S.A., Majid, Z., Tahir, F., Qadar, L.T., Mir, S., 2019. Rhino-oculo cerebral mucormycosis resistant to amphotericin B in a Young patient with diabetic ketoacidosis. Cureus 11. https://doi.org/10.7759/cureus.4295.

Bakathir, A.A., 2006. Mucormycosis of the jaw after dental extractions: two case reports. Sultan Qaboos Univ. Med. J. 6, 77–82.

Baker, R.D., 1956. Pulmonary mucormycosis. Am. J. Pathol. 32, 287.

Balachandar, V., Kaavya, J., Mahalaxmi, I., Arul, N., Vivekanandhan, G., Bupesh, G., Singaravelu, G., Anila, V., Dhivya, V., Harsha, G., 2020a. COVID-19: a promising cure for the global panic. Sci. Total Environ. 725, 138277 https://doi.org/10.1016/j.scitotenv.2020.138277.

Balachandar, V., Mahalaxmi, I., Devi, S.M., Kaavya, J., Kumar, N.S., Laldinmawii, G., Arul, N., Reddy, S.J.K., Sivaprakash, P., Kanchana, S., 2020b. Follow-up studies in COVID-19 recovered patients-is it mandatory? Sci. Total Environ. 139021.

Bannykh, S.I., Hunt, B., Moser, F., 2018. Intra-arterial spread of *Mucormycetes* mediates early ischemic necrosis of brain and suggests new venues for prophylactic therapy: arterial occlusion in mucormycosis. Neuropathology 38, 539–541. https://doi.org/10.1111/neup.12501.

Barnagarwala, T., 2021. Mucormycosis: 2,245 Cases So Far in Maharashtra, 30 Dead in Last Six Days. Indian Express. https://indianexpress.com/article/cities/mumbai/mucormycosis-2245-cases-so-far-in-maharashtra-30-dead-in-last-six-days-7330313/. accessed 6.21.21.

Beketova, T.R., Bailey, L., Crowell, E.L., Supsupin, E.P., Adesina, O.O., 2018. Orbitocerebral mucormycosis in a patient with central Nervous system lymphoma. Ophthalmic Plast. Reconstr. Surg. 34, e197–e201. https://doi.org/10.1097/IOP.0000000000001243.

Bhatkar, S., Goyal, M., Takkar, A., Mukherjee, K., Singh, P., Singh, R., Lal, V., 2017. Cavernous sinus syndrome: a prospective study of 73 cases at a tertiary care centre in Northern India. Clin. Neurol. Neurosurg. 155, 63–69. https://doi.org/10.1016/j.clineuro.2017.02.017.

Binder, U., Maurer, E., Lass-Flörl, C., 2014. Mucormycosis–from the pathogens to the disease. Clin. Microbiol. Infect. 20, 60–66. https://doi.org/10.1111/1469-0691.12566.

Boelaert, J.R., Fenves, A.Z., Coburn, J.W., 1991. Deferoxamine therapy and mucormycosis in dialysis patients: report of an international registry. Am. J. Kidney Dis. 18, 660–667. https://doi.org/10.1016/s0272-6386(12)80606-8.

Bellanger, A.-P., Navellou, J.-C., Lepiller, Q., Brion, A., Brunel, A.-S., Millon, L., Berceanu, A., 2017. Mixed mold infection with Aspergillus fumigatus and Rhizopus microsporus in a Severe Acute Respiratory syndrome Coronavirus 2 (SARS-CoV-2) patient. Infect. Dis. Now. https://doi.org/10.1016/j.idnow.2021.01.010. S2666-9919(21)00030-0.

Brunke, S., Mogavero, S., Kasper, L., Hube, B., 2016. Virulence factors in fungal pathogens of man. Curr. Opin. Microbiol. 32, 89–95. https://doi.org/10.1016/j.mib.2016.05.010.

Carter, J.E., Rauch, R.A., 1994. One-and-a-half syndrome, type II. Arch. Neurol. 51, 87–89. https://doi.org/10.1001/archneur.1994.00540130121020.

Castillo, P., Wright, K.E., Kontoyiannis, D.P., Walsh, T., Patel, S., Chorvinsky, E., Bose, S., Hazrat, Y., Omer, B., Albert, N., Leen, A.M., Rooney, C.M., Bollard, C.M., Cruz, C.R. Y., 2018. A new method for reactivating and expanding T cells specific for Rhizopus oryzae. Mol. Ther. - Methods Clin. Dev. 9, 305–312. https://doi.org/10.1016/j.omtm.2018.03.003.

Chakrabarti, A., Das, A., Mandal, J., Shivaprakash, M., George, V.K., Tarai, B., Rao, P., Panda, N., Verma, S.C., Sakhuja, V., 2006. The rising trend of invasive zygomycosis in patients with uncontrolled diabetes mellitus. Sabouraudia 44, 335–342. https://doi.org/10.1080/13693780500464930.

Chakrabarti, A., Chatterjee, S., Das, A., Panda, N., Shivaprakash, M., Kaur, A., Varma, S., Singhi, S., Bhansali, A., Sakhuja, V., 2009. Invasive zygomycosis in India: experience in a tertiary care hospital. Postgrad. Med. 85, 573–581.

Chamilos, G., Lewis, R., Lamaris, G., Walsh, T., Kontoyiannis, D., 2008. Zygomycetes hyphae trigger an early, robust proinflammatory response in human polymorphonuclear neutrophils through toll-like receptor 2 induction but display relative resistance to oxidative damage. Antimicrob. Agents Chemother. 52, 722–724. https://doi.org/10.1128/AAC.01136-07.

Chaulk, A.L., Do, T.H., Supsupin, E.P., Bhattacharjee, M.B., Richani, K., Adesina, O., 2021. A unique radiologic case of optic nerve Infarction in a patient with mucormycosis. J. Neuro Ophthalmol. Off. J. North Am. Neuro Ophthalmol. Soc. https://doi.org/10.1097/WNO.0000000000001179.

Chegini, Z., Didehdar, M., Khoshbayan, A., Rajaeih, S., Salehi, M., Shariati, A., 2020. Epidemiology, clinical features, diagnosis and treatment of cerebral mucormycosis in diabetic patients: a systematic review of case reports and case series. Mycoses 63, 1264–1282. https://doi.org/10.1111/myc.13187.

Chibucos, M.C., Soliman, S., Gebremariam, T., Lee, H., Daugherty, S., Orvis, J., Shetty, A. C., Crabtree, J., Hazen, T.H., Etienne, K.A., 2016. An integrated genomic and transcriptomic survey of mucormycosis-causing fungi. Nat. Commun. 7, 1–11. https://doi.org/10.1038/ncomms12218.

Chow, V., Khan, S., Balogun, A., Mitchell, D., Mühlschlegel, F.A., 2015. Invasive rhino-orbito-cerebral mucormycosis in a diabetic patient–the need for prompt treatment. Med. Mycol. Case Rep. 8, 5–9. https://doi.org/10.1016/j.mmcr.2014.12.002.

Cornu, M., Bruno, B., Loridant, S., Navarin, P., François, N., Lanternier, F., Amzallag-Bellenger, E., Dubos, F., Mazingue, F., Sendid, B., 2018. Successful outcome of disseminated mucormycosis in a 3-year-old child suffering from acute leukaemia: the role of isavuconazole? a case report. BMC Pharmacol. Toxicol. 19, 81. https://doi.org/10.1186/s40360-018-0273-7.

Corzo-León, D.E., Chora-Hernández, L.D., Rodríguez-Zulueta, A.P., Walsh, T.J., 2018. Diabetes mellitus as the major risk factor for mucormycosis in Mexico: epidemiology, diagnosis, and outcomes of reported cases. Med. Mycol. 56, 29–43 https://doi.org/0.1093/mmy/myx017.

Dallalzadeh, L.O., Ozzello, D.J., Liu, C.Y., Kikkawa, D.O., Korn, B.S., 2021. Secondary Infection with Rhino-Orbital Cerebral Mucormycosis Associated with COVID-19. Orbit, pp. 1–4. https://doi.org/10.1080/01676830.2021.

Dantas, K.C., Mauad, T., de André, C.D.S., Bierrenbach, A.L., Saldiva, P.H.N., 2021. A single-centre, retrospective study of the incidence of invasive fungal infections during 85 years of autopsy service in Brazil. Sci. Rep. 11, 1–10. https://doi.org/10.1038/s41598-021-83587-1.

de Moura Feitoza, L., Altemani, A., da Silva, N.A., Reis, F., 2019. Teaching neuroimages: mucormycosis-associated vasculitis: a new sequence to show an old invasive infection. Neurology 92, e1796–e1797. https://doi.org/10.1212/WNL.0000000000007275.

do Monte Junior, E.S., Dos Santos, M.E.L., Ribeiro, I.B., de Oliveira Luz, G., Baba, E.R., Hirsch, B.S., Funari, M.P., De Moura, E.G.H., 2020. Rare and fatal gastrointestinal mucormycosis (Zygomycosis) in a COVID-19 patient: a case report. Clin. Endosc. 53, 746–749. https://doi.org/10.5946/ce.2020.180.

Dolatabadi, S., Ahmadi, B., Rezaei-Matehkolaei, A., Zarrinfar, H., Skiada, A., Mirhendi, H., Nashibi, R., Niknejad, F., Nazeri, M., Rafiei, A., 2018. Mucormycosis in Iran: a six-year retrospective experience. J. Mycol. Medicale 28, 269–273. https://doi.org/10.1016/j.mycmed.2018.02.014.

Dworsky, Z.D., Bennett, R., Kim, J.M, Kuo, D.J, 2017. Severe medication-induced peripheral neuropathy treated with topical doxepin cream in a paediatric patient with leukaemia. Case Rep. https://doi.org/10.1136/bcr-2017-219900 bcr2017219900.

Economides, M.P., Ballester, L.Y., Kumar, V.A., Jiang, Y., Tarrand, J., Prieto, V., Torres, H.A., Kontoyiannis, D.P., 2017. Invasive mold infections of the central

nervous system in patients with hematologic cancer or stem cell transplantation (2000–2016): uncommon, with improved survival but still deadly often. J. Infect. 75, 572–580. https://doi.org/10.1016/j.jinf.2017.09.011.
Einollahi, B., Lessan-Pezeshki, M., Aslani, J., Nemati, E., Rostami, Z., Hosseini, M.J., Ghadiani, M.H., Ahmadpour, P., Shahbazian, H., Pour-Reza-Gholi, F., 2011. Two decades of experience in mucormycosis after kidney transplantation. Ann. Transplant. 16, 44–48. https://doi.org/10.12659/aot.881994.
Elitzur, S., Arad-Cohen, N., Barg, A., Litichever, N., Bielorai, B., Elhasid, R., Fischer, S., Fruchtman, Y., Gilad, G., Kapelushnik, J., 2020. Mucormycosis in children with haematological malignancies is a salvageable disease: a report from the Israeli study group of childhood leukemia. Br. J. Haematol. 189, 339–350. https://doi.org/10.1111/bjh.16329.
Ermak, D., Kanekar, S., Specht, C.S., Wojnar, M., Lowden, M., 2014. Looks like a stroke, acts like a stroke, but it's more than a stroke: a case of cerebral mucormycosis. J. Stroke Cerebrovasc. Dis. 23, e403–e404. https://doi.org/10.1016/j.jstrokecerebrovasdis.2014.02.024.
Fahimzad, A., Chavoshzadeh, Z., Abdollahpour, H., Klein, C., Rezaei, N., 2008. Necrosis of nasal cartilage due to mucormycosis in a patient with severe congenital neutropenia due to HAX1 deficiency. J. Investig. Allergol. Clin. Immunol. 18, 469–472.
Farid, S., AbuSaleh, O., Liesman, R., Sohail, M.R., 2017. Isolated cerebral mucormycosis caused by Rhizomucor pusillus. Case Rep. https://doi.org/10.1136/bcr-2017-221473 bcr-2017.
Fontana, L., Perlin, D.S., Zhao, Y., Noble, B.N., Lewis, J.S., Strasfeld, L., Hakki, M., 2020. Isavuconazole prophylaxis in patients with hematologic malignancies and hematopoietic cell transplant recipients. Clin. Infect. Dis. 70, 723–730. https://doi.org/10.1093/cid/ciz282.
Furbringer, M., 1876. Zur vergleichenden anatomie der Schultermuskeln. Morphol. Jahrb. 1, 636–816.
Garg, D., Muthu, V., Sehgal, I.S., Ramachandran, R., Kaur, H., Bhalla, A., Puri, G.D., Chakrabarti, A., Agarwal, R., 2021. Coronavirus disease (Covid-19) associated mucormycosis (CAM): case report and systematic review of literature. Mycopathologia 186, 289–298. https://doi.org/10.1007/s11046-021-00528-2.
Gebremariam, T., Liu, M., Luo, G., Bruno, V., Phan, Q.T., Waring, A.J., Edwards, J.E., Filler, S.G., Yeaman, M.R., Ibrahim, A.S., 2014. CotH3 mediates fungal invasion of host cells during mucormycosis. J. Clin. Invest. 124, 237–250. https://doi.org/10.1172/JCI71349.
Gomes, M.Z., Lewis, R.E., Kontoyiannis, D.P., 2011. Mucormycosis caused by unusual mucormycetes, non-Rhizopus,-Mucor, and-Lichtheimia species. Clin. Microbiol. Rev. 24, 411–445. https://doi.org/10.1128/CMR.00056-10.
Hanley, B., Naresh, K.N., Roufosse, C., Nicholson, A.G., Weir, J., Cooke, G.S., Thursz, M., Manousou, P., Corbett, R., Goldin, R., 2020. Histopathological findings and viral tropism in UK patients with severe fatal COVID-19: a post-mortem study. Lancet Microbe 1, e245–e253. https://doi.org/10.1016/S2666-5247(20)30115-4.
Higo, T., Kobayashi, T., Yamazaki, S., Ando, S., Gonoi, W., Ishida, M., Okuma, H., Nakamura, F., Ushiku, T., Ohtomo, K., Fukayama, M., Kurokawa, M., 2015. Cerebral embolism through hematogenous dissemination of pulmonary mucormycosis complicating relapsed leukemia. Int. J. Clin. Exp. Pathol. 8, 13639–13642.
Hu, W.T., Leavitt, J.A., Moore, E.J., Noseworthy, J.H., 2006. MRI findings of rapidly progressive ophthalmoplegia and blindness in mucormycosis. Neurology 66, E40. https://doi.org/10.1212/01.wnl.0000204231.85308.7e.
Ibrahim, M., Chitnis, S., Fallon, K., Roberts, T., 2009. Rhinocerebral mucormycosis in a 12-year-old girl. Arch. Neurol. 66, 272–273. https://doi.org/10.1001/archneurol.2008.546.
Ibrahim, A.S., Kontoyiannis, D.P., 2013. Update on mucormycosis pathogenesis. Curr. Opin. Infect. Dis. 26, 508. https://doi.org/10.1097/QCO.0000000000000008.
Iyer, M., Jayaramayya, K., Subramaniam, M.D., Lee, S.B., Dayem, A.A., Cho, S.-G., Vellingiri, B., 2020. COVID-19: an update on diagnostic and therapeutic approaches. BMB Rep 53, 191. https://doi.org/10.5483/BMBRep.2020.53.4.080.
Iyer, M., Tiwari, S., Renu, K., Pasha, M.Y., Pandit, S., Singh, B., Raj, N., Saikrishna, K., Kwak, H.J., Balasubramanian, V., 2021. Environmental Survival of SARS-CoV-2–A solid waste perspective. Environ. Res. 111015 https://doi.org/10.1016/j.envres.2021.111015.
Jaillon, S., Galdiero, M.R., Del Prete, D., Cassatella, M.A., Garlanda, C., Mantovani, A., 2013. Neutrophils in innate and adaptive immunity. Semin. Immunopathol. 35, 377–394. https://doi.org/10.1007/s00281-013-0374-8.
Jayaramayya, K., Mahalaxmi, I., Subramaniam, M.D., Raj, N., Dayem, A.A., Lim, K.M., Kim, S.J., An, J.Y., Lee, Y., Choi, Y., 2020. Immunomodulatory effect of mesenchymal stem cells and mesenchymal stem-cell-derived exosomes for COVID-19 treatment. BMB Rep 53, 400. https://doi.org/10.5483/BMBRep.2020.53.8.121.
Jeong, W., Keighley, C., Wolfe, R., Lee, W., Slavin, M., Kong, D., Chen, S.-A., 2019. The epidemiology and clinical manifestations of mucormycosis: a systematic review and meta-analysis of case reports. Clin. Microbiol. Infect. 25, 26–34. https://doi.org/10.1016/j.cmi.2018.07.011.
Jiménez Caballero, P.E., Falcón García, A.M., Portilla Cuenca, J.C., Casado Naranjo, I., 2012. Multiple subcortical strokes caused by mucormycosis in a patient with lymphoma. Arquivos de neuro-psiquiatria 70, 69–70. https://doi.org/10.1590/s0004-282x2012000100014.
Jiménez-Zarazúa, O., Vélez-Ramírez, L., Alcocer-León, M., Utrilla-Álvarez, J., Martínez-Rivera, M., Flores-Saldaña, G., Mondragón, J., 2019. A case of concomitant pulmonary tuberculosis and mucormycosis in an insulin-dependent diabetic patient. J. Clin. Tubercul. Mycobact. Dis. 16, 100105. https://doi.org/10.1016/j.jctube.2019.100105.
John, T.M., Jacob, C.N., Kontoyiannis, D.P., 2021. When uncontrolled diabetes mellitus and severe COVID-19 converge: the perfect storm for mucormycosis. J. Fungi 7, 298. https://doi.org/10.3390/jof7040298.
Johnson, A.K., Ghazarian, Z., Cendrowski, K.D., Persichino, J.G., 2021. Pulmonary aspergillosis and mucormycosis in a patient with COVID-19. Med. Mycol. Case Rep. 32, 64–67. https://doi.org/10.1016/j.mmcr.2021.03.006.
Josephine, S.M., 2021. 1,196 Cases of Mucormycosis in T.N., More Drugs Required. The Hindu. https://www.thehindu.com/news/national/tamil-nadu/1196-cases-of-mucormycosis-in-tn-more-drugs-required/article34784997.ece. accessed 6.21.21.
Kanwar, A., Jordan, A., Olewiler, S., Wehberg, K., Cortes, M., Jackson, B.R., 2021. A fatal case of Rhizopus azygosporus pneumonia following COVID-19. J. Fungi 7, 174. https://doi.org/10.3390/jof7030174.
Kar, P., Kumar, V., Vellingiri, B., Sen, A., Jaishee, N., Anandraj, A., Malhotra, H., Bhattacharyya, S., Mukhopadhyay, S., Kinoshita, M., 2020. Anisotine and amarogentin as promising inhibitory candidates against SARS-CoV-2 proteins: a computational investigation. J. Biomol. Struct. Dyn. 1–11. https://doi.org/10.1080/07391102.2020.1860133.
Karakurum, B., Karatas, M., Cagici, A.C., Uncu, H., Yildirim, T., Hurcan, C., Karaca, S., Kizilkilic, E., Tan, M., 2005. Mucormycosis presenting with painful ophthalmoplegia. Acta Neurol. Belg. 105, 201–205.
Khatri, A., Chang, K.-M., Berlinrut, I., Wallach, F., 2021. Mucormycosis after Coronavirus disease 2019 infection in a heart transplant recipient–case report and review of literature. J. Med. Mycol. 101125 https://doi.org/10.1016/j.mycmed.2021.101125.
Kinoshita, M., Sato, K., Vellingiri, B., Green, S.J., Tanaka, M., 2021. Inverse association between hypertension treatment and COVID-19 prevalence in Japan. Int. J. Infect. Dis. https://doi.org/10.1016/j.ijid.2021.05.071.
Kontoyiannis, D.P., Lewis, R.E., 2006. Invasive zygomycosis: update on pathogenesis, clinical manifestations, and management. Infect. Dis. Clin. 20, 581–607. https://doi.org/10.1016/j.idc.2006.06.003.
Küchenmeister, F., 1855. Die in und an dem körper des lebenden menschen vorkommenden parasiten: Ein lehr-und handbuch der diagnose und behandlung der thierischen und pflanzlichen parasiten des menschen. GB Teubner.
Kulkarni, NS., Bhide, A.R., Wadia, R.S., 2005. Rhinocerebral mucormycosis: an analysis of probable mode of spread and its implication in an early diagnosis and treatment. Indian J. Otolaryngol. Head Neck Surg. 57, 121–124. https://doi.org/10.1007/BF02907665.
Kumar, P., 2021. Centre Asks States to Notify "Black Fungus" under Epidemic Diseases Act. NDTV.
Lau, C.-I., Wang, H.-C., Yeh, H.-L., Li, C.-H., 2011. Isolated orbito-cerebral mucormycosis. Neurologist 17, 151–153. https://doi.org/10.1097/NRL.0b013e3182173395.
Lee, H., Cho, S., Lee, D., Park, C., Chun, H., Park, Y., 2020. Characteristics and risk factors for mortality of invasive non-Aspergillus mould infections in patients with haematologic diseases: a single-centre 7-year cohort study. Mycoses 63, 257–264. https://doi.org/10.1111/myc.13038.
Lionakis, M.S., Lewis, R.E., Kontoyiannis, D.P., 2018. Breakthrough invasive mold infections in the hematology patient: current concepts and future directions. Clin. Infect. Dis. 67, 1621–1630. https://doi.org/10.1093/cid/ciy473.
Macdonell, R.A., Donnan, G.A., Kalnins, R.M., Richards, M.J., Bladin, P.F., 1987. Otocerebral mucormycosis–a case report. Clin. Exp. Neurol. 23, 225–232.
Mahalaxmi, I., Kaavya, J., Mohana Devi, S., Balachandar, V., 2021. COVID-19 and olfactory dysfunction: a possible associative approach towards neurodegenerative diseases. J. Cell. Physiol. 236, 763–770. https://doi.org/10.1002/jcp.29937.
Maini, A., Tomar, G., Khanna, D., Kini, Y., Mehta, H., Bhagyasree, V., 2021. Sino-orbital mucormycosis in a COVID-19 patient: a case report. Int. J. Surg. Case Rep. 105957. https://doi.org/10.1016/j.ijscr.2021.105957.
Malik, A.N., Bi, W.L., McCray, B., Abedalthagafi, M., Vaitkevicius, H., Dunn, I.F., 2014. Isolated cerebral mucormycosis of the basal ganglia. Clin. Neurol. Neurosurg. 124, 102.
Mallapaty, S., 2021. India's massive COVID surge puzzles scientists. Nature 592, 667–668. https://doi.org/10.1038/d41586-021-01059-y.
Mantero, V., Basilico, P., Pozzetti, U., Tonolo, S., Rossi, G., Spena, G., Rigamonti, A., Salmaggi, A., 2019. Concomitant cerebral aspergillosis and mucormycosis in an immunocompetent woman treated with corticosteroids. J. Neurovirol. 26, 277–280. https://doi.org/10.1007/s13365-019-00804-4.
Mcnulty, J.S., 1982. Rhinocerebral mucormycosis: predisposing factors. Laryngoscope 92, 1140–1143.
Mekonnen, Z.K., Ashraf, D.C., Jankowski, T., Grob, S.R., Vagefi, M.R., Kersten, R.C., Simko, J.P., Winn, B.J., 2021. Acute invasive rhino-orbital mucormycosis in a patient with COVID-19-associated acute respiratory distress syndrome. Ophthalmic Plast. Reconstr. Surg. 37, e40–e80. https://doi.org/10.1097/IOP.0000000000001889.
Merkler, A.E., Duggal, I., Kaunzner, U., Maciel, C.B., Miller, A.M., Scognamiglio, T., Dinkin, M.J., 2016. Rapidly progressive bilateral optic nerve and retinal infarctions due to rhinocerebral mucormycosis and pseudoephedrine use. Neurol. Clin. Pract. 6, 549–552. https://doi.org/10.1212/CPJ.0000000000000253.
Mehta, S., Pandey, A., 2020. Rhino-orbital mucormycosis associated with COVID-19. Cureus 12. https://doi.org/10.7759/cureus.10726. S2666- 9919(21)00030-0.
Moorthy, A., Gaikwad, R., Krishna, S., Hegde, R., Tripathi, K., Kale, P.G., Rao, P.S., Haldipur, D., Bonanthaya, K., 2021. SARS-CoV-2, uncontrolled diabetes and corticosteroids—an unholy trinity in invasive fungal infections of the maxillofacial region? A retrospective, multi-centric analysis. J. Maxillofac. Oral Surg. 1–8 https://doi.org/10.1007/s12663-021-01532-1.
Mukherjee, M., 2021. Inside Black Fungus Wards in Rajasthan: amid Injection Shortage, Increasing Patients, Many End up Losing Vision. Indian Express. https://indianexpress.com/article/india/in-black-fungus-wards-in-rajasthan-many-end-up-losing-vision-amid-injection-shortage-rising-patient-numbers-7345983/. accessed 6.21.21.
Miller, M.A., Molina, K.C., Gutman, J.A., Scherger, S., Lum, J.M, Mossad, S.B, Burgess, M, Cheng, M.P, Chuang, S.T., Jacobs, S.E., 2017. Mucormycosis in

hematopoietic cell transplant recipients and in patients with hematological malignancies in the era of new antifungal agents. In: Presented at the Open Forum Infectious Diseases. Oxford University Press, US. https://doi.org/10.1093/ofid/ofaa646, 8, ofaa646.
Ochiai, H., Iseda, T., Miyahara, S., Goya, T., Wakisaka, S., 1993. Rhinocerebral mucormycosis —case report—. Neurol. Med.-Chir. 33, 373–376. https://doi.org/10.2176/nmc.33.373.
Pagano, L., Ricci, P., Tonso, A., Nosari, A., Cudillo, L., Montillo, M., Cenacchi, A., Pacilli, L., Fabbiano, F., Del Favero, A., 1997. Mucormycosis in patients with haematological malignancies: a retrospective clinical study of 37 cases. Br. J. Haematol. 99, 331–336. https://doi.org/10.1046/j.1365-2141.1997.3983214.x.
Pasero, D., Sanna, S., Liperi, C., Piredda, D., Branca, G.P., Casadio, L., Simeo, R., Buselli, A., Rizzo, D., Bussu, F., 2020. A challenging complication following SARS-CoV-2 infection: a case of pulmonary mucormycosis. Infection 1–6. https://doi.org/10.1007/s15010-020-01561-x.
Patel, A., Kaur, H., Xess, I., Michael, J., Savio, J., Rudramurthy, S., Singh, R., Shastri, P., Umabala, P., Sardana, R., 2020. A multicentre observational study on the epidemiology, risk factors, management and outcomes of mucormycosis in India. Clin. Microbiol. Infect. 26, 944.e9–944.e15. https://doi.org/10.1016/j.cmi.2019.11.021.
Placik, D.A., Taylor, W.L., Wnuk, N.M., 2020. Bronchopleural fistula development in the setting of novel therapies for acute respiratory distress syndrome in SARS-CoV-2 pneumonia. Radiol. Case Rep. 15, 2378–2381. https://doi.org/10.1016/j.radcr.2020.09.026.
Potenza, L., Vallerini, D., Barozzi, P., Riva, G., Forghieri, F., Zanetti, E., Quadrelli, C., Candoni, A., Maertens, J., Rossi, G., Morselli, M., Codeluppi, M., Paolini, A., Maccaferri, M., Del Giovane, C., D'Amico, R., Rumpianesi, F., Pecorari, M., Cavalleri, F., Marasca, R., Narni, F., Luppi, M., 2011. Mucorales-specific T cells emerge in the course of invasive mucormycosis and may be used as a surrogate diagnostic marker in high-risk patients. Blood 118, 5416–5419. https://doi.org/10.1182/blood-2011-07-366526.
Prakash, H., Chakrabarti, A., 2019. Global epidemiology of mucormycosis. J. Fungi 5, 26. https://doi.org/10.3390/jof5010026.
Rajashri, R., Muthusekhar, M.R., Kumar, S.P., 2020. Mucormycosis following tooth extraction in a diabetic patient: a case report. Cureus. https://doi.org/10.7759/cureus.9757.
Ramanathan, S., Kate, S., Kembhavi, S., Cheriyalinkal Parambil, B., KC, A., Bhat, V., Prasad, M., Moiyadi, A., Biswas, S., Narula, G., 2020. A retrospective analysis of Invasive Fungal Diseases (IFD) of the central nervous system in children with lymphoid malignancies. J. Pediatr. Hematol. Oncol. 42, e202–e206. https://doi.org/10.1097/MPH.0000000000001690.
Rammaert, B., Lanternier, F., Zahar, J.-R., Dannaoui, E., Bougnoux, M.-E., Lecuit, M., Lortholary, O., 2012. Healthcare-associated mucormycosis. Clin. Infect. Dis. 54, S44–S54. https://doi.org/10.1093/cid/cir867.
Rangel-Guerra, R.A., Martínez, H.R., Sáenz, C., Bosques-Padilla, F., Estrada-Bellmann, I., 1996. Rhinocerebral and systemic mucormycosis. Clinical experience with 36 cases. J. Neurol. Sci. 143, 19–30. https://doi.org/10.1016/s0022-510x(96)00148-7.
Rao, R., Shetty, A.P., Nagesh, C.P., 2021. Orbital infarction syndrome secondary to rhino-orbital mucormycosis in a case of COVID-19: clinico-radiological features. Indian J. Ophthalmol. 69, 1627–1630. https://doi.org/10.4103/ijo.IJO_1053.
Rashid, H.U., Rashid, M., Khan, N., Ansari, S.S., Bibi, N., 2021. Taking a step down on the reconstruction ladder for head and neck reconstruction during the COVID-19 pandemic. BMC Surg. 21, 120. https://doi.org/10.1186/s12893-021-01134-1.
Rausch, C.R., DiPippo, A.J., Bose, P., Kontoyiannis, D.P., 2018. Breakthrough fungal infections in patients with leukemia receiving isavuconazole. Clin. Infect. Dis. 67, 1610–1613. https://doi.org/10.1093/cid/ciy406.
Ravani, S.A., Agrawal, G.A., Leuva, P.A., Modi, P.H., Amin, K.D., 2021. Rise of the phoenix: mucormycosis in COVID-19 times. Indian J. Ophthalmol. 69, 1563–1568. https://doi.org/10.4103/ijo.IJO_310_21.
Reid, G., Lynch III, J.P., Fishbein, M.C., Clark, N.M., 2020. Mucormycosis. Presented at the Seminars in Respiratory and Critical Care Medicine. Thieme Medical Publishers, pp. 99–114. https://doi.org/10.1055/s-0039-3401992.
Renu, K., Subramaniam, M.D., Chakraborty, R., Haritha, M., Iyer, M., Bharathi, G., Kamalakannan, S., Balachandar, V., Abilash, V., 2020. The role of Interleukin-4 in COVID-19 associated male infertility–A hypothesis: running title: IL-4 and its role in COVID-19 associated male infertility. J. Reprod. Immunol. 103213 https://doi.org/10.1016/j.jri.2020.103213.
Revannavar, S.M., Supriya, P., Samaga, L., Vineeth, V., 2021. COVID-19 triggering mucormycosis in a susceptible patient: a new phenomenon in the developing world? BMJ Case Rep. 14, e241663 https://doi.org/10.1136/bcr-2021-241663.
Roden, M.M., Zaoutis, T.E., Buchanan, W.L., Knudsen, T.A., Sarkisova, T.A., Schaufele, R. L., Sein, M., Sein, T., Chiou, C.C., Chu, J.H., 2005. Epidemiology and outcome of zygomycosis: a review of 929 reported cases. Clin. Infect. Dis. 41, 634–653. https://doi.org/10.1086/432579.
Roilides, E., Kontoyiannis, D.P., Walsh, T.J., 2012. Host defenses against zygomycetes. Clin. Infect. Dis. 54, S61–S66. https://doi.org/10.1093/cid/cir869.
Saldanha, M., Reddy, R., Vincent, M.J., 2021. of the Article: Paranasal Mucormycosis in COVID-19 Patient. Indian J. Otolaryngol. Head Neck Surg. 1–4. https://doi.org/10.1007/s12070-021-02574-0.
Salinas-Lara, C., Rembao-Bojórquez, D., de la Cruz, E., Márquez, C., Portocarrero, L., Tena-Suck, M.L., 2008. Pituitary apoplexy due to mucormycosis infection in a patient with an ACTH producing pulmonary tumor. J. Clin. Neurosci. 15, 67–70. https://doi.org/10.1016/j.jocn.2006.01.023.
Sano, T., Kobayashi, Z., Takaoka, K., Ota, K., Onishi, I., Iizuka, M., Tomimitsu, H., Shintani, S., 2018. Retrobulbar optic neuropathy associated with sphenoid sinus mucormycosis. Neurol. Clin. Neurosci. 6, 146–147. https://doi.org/10.1111/ncn3.12216.
Sarkar, S., Gokhale, T., Choudhury, S.S., Deb, A.K., 2021. COVID-19 and orbital mucormycosis. Indian J. Ophthalmol. 69, 1002. https://doi.org/10.4103/ijo.IJO_3763_20.
Sarvestani, A.S., Pishdad, G., Bolandparvaz, S., 2013. Predisposing factors for mucormycosis in patients with diabetes mellitus; an experience of 21 years in southern Iran. Bull. Emerg. Trauma 1, 164.
Schmidt, S., Tramsen, L., Perkhofer, S., Lass-Flörl, C., Hanisch, M., Röger, F., Klingebiel, T., Koehl, U., Lehrnbecher, T., 2013. Rhizopus oryzae hyphae are damaged by human natural killer (NK) cells, but suppress NK cell mediated immunity. Immunobiology 218, 939–944. https://doi.org/10.1016/j.imbio.2012.10.013.
Sasannejad, P., Ghabeli-Juibary, A., Aminzadeh, S., Olfati, N., 2015. Cerebellar infarction and aneurysmal subarachnoid hemorrhage: an unusual presentation and rare complications of rhinocerebral mucormycosis. Iran. J. Child Neurol. 14, 222.
Schmidt, S., Schneider, A., Demir, A., Lass-Flörl, C., Lehrnbecher, T., 2016. Natural killer cell-mediated damage of clinical isolates of mucormycetes. Mycoses 59, 34–38. https://doi.org/10.1111/myc.12431.
Sen, M., Lahane, S., Lahane, T.P., Parekh, R., Honavar, S.G., 2021. Mucor in a Viral Land: a tale of two pathogens. Indian J. Ophthalmol. 69, 244–252. https://doi.org/10.4103/ijo.IJO_3774_20.
Shadrivova, O.V., Burygina, E.V., Klimko, N.N., 2019. Molecular diagnostics of mucormycosis in hematological patients: a literature review. J. Fungi 5, 112. https://doi.org/10.3390/jof5040112.
Shariati, A., Moradabadi, A., Chegini, Z., Khoshbayan, A., Didehdar, M., 2020. An overview of the management of the most important invasive fungal infections in patients with blood malignancies. Infect. Drug Resist. 13, 2329. https://doi.org/10.2147/IDR.S254478.
Sharma, S., Grover, M., Bhargava, S., Samdani, S., Kataria, T., 2021. Post coronavirus disease mucormycosis: a deadly addition to the pandemic spectrum. J. Laryngol. Otol. 1–6. https://doi.org/10.1017/S0022215121000992.
Skiada, A., Pagano, L., Groll, A., Zimmerli, S., Dupont, B., Lagrou, K., Lass-Florl, C., Bouza, E., Klimko, N., Gaustad, P., 2011. Zygomycosis in Europe: analysis of 230 cases accrued by the registry of the European confederation of medical mycology (ECMM) working group on zygomycosis between 2005 and 2007. Clin. Microbiol. Infect. 17, 1859–1867. https://doi.org/10.1111/j.1469-0691.2010.03456.x.
Skiada, A., Pavleas, I., Drogari-Apiranthitou, M., 2020. Epidemiology and diagnosis of mucormycosis: an update. J. Fungi 6, 265. https://doi.org/10.3390/jof6040265.
Skidmore, F.M., Williams, L.S., Fradkin, K.D., Alonso, R.J., Biller, J., 2001. Presentation, etiology, and outcome of stroke in pregnancy and puerperium. J. Stroke Cerebrovasc. Dis. 10, 1–10. https://doi.org/10.1053/jscd.2001.20977.
Slavin, Monica, Thursky, Karin, 2021. Mucormycosis: the Black Fungus Hitting Covid-19 Patients. BBC.
Spellberg, B., Edwards, J., Ibrahim, A., 2005. Novel perspectives on mucormycosis: pathophysiology, presentation, and management. Clin. Microbiol. Rev. 18, 556–569. https://doi.org/10.1128/CMR.18.3.556-569.2005.
Stemler, J., Hamed, K., Salmanton-García, J., Rezaei-Matehkolaei, A., Gräfe, S.K., Sal, E., Zarrouk, M., Seidel, D., Abdelaziz Khedr, R., Ben-Ami, R., 2020. Mucormycosis in the Middle East and North Africa: analysis of the FungiScope® registry and cases from the literature. Mycoses 63, 1060–1068. https://doi.org/10.1111/myc.13123.
Stretz, C., Mook, A., Modak, J.M., Rodriguez, J.M., Nouh, A.M., 2017. Gerstmann syndrome in a patient with aggressive mucormycosis. Neurohospitalist 7, 102–103. https://doi.org/10.1177/1941874416663282.
Subramaniam, M.D., Venkatesan, D., Iyer, M., Subbarayan, S., Govindasami, V., Roy, A., Narayanasamy, A., Kamalakannan, S., Gopalakrishnan, A.V., Thangarasu, R., 2020. Biosurfactants and anti-inflammatory activity: a potential new approach towards COVID-19. Curr. Opin. Environ. Sci. Health. https://doi.org/10.1016/j.coesh.2020.09.002.
Suganya, R., Malathi, N., Karthikeyan, V., Janagaraj, V.D., 2019. Mucormycosis: a brief review. J. Pure Appl. Microbiol. 13, 161–165. https://doi.org/10.22207/JPAM.13.1.16.
Sundaram, C., Sravani, T., Uppin, S., Uppin, M., 2014. Rhinocerebral mucormycosis: pathology revisited with emphasis on perineural spread. Neurol. India 62, 383. https://doi.org/10.4103/0028-3886.141252.
Suryanarayanan, T.S., Shaanker, U., 2021. COVID-19 and black fungus: what is mucormycosis? Health Sci.
Teixeira, C.A., Medeiros, P.B., Leushner, P., Almeida, F., 2013. Rhinocerebral mucormycosis: literature review apropos of a rare entity. BMJ Case Rep. https://doi.org/10.1136/bcr-2013-008552 bcr2012008552.
Thajeb, P., Thajeb, T., Dai, D., 2004. Fatal strokes in patients with rhino-orbito-cerebral mucormycosis and associated vasculopathy. Scand. J. Infect. Dis. 36, 643–648. https://doi.org/10.1080/00365540410020794.
Tsikala-Vafea, M., Cao, W., Olszewski, A.J., Donahue, J.E., Farmakiotis, D., 2020. Fatal mucormycosis and aspergillosis in an atypical host: what do we know about mixed invasive mold infections? Case Rep. Infect. Dis. 2020, 8812528. https://doi.org/10.1155/2020/8812528.
Veisi, A., Bagheri, A., Eshaghi, M., Rikhtehgar, M.H., Rezaei Kanavi, M., Farjad, R., 2021. Rhino-orbital mucormycosis during steroid therapy in COVID-19 patients: a case report. Eur. J. Ophthalmol. 11206721211009450.
Verma, A., Brozman, B., Petito, C.K., 2006. Isolated cerebral mucormycosis: report of a case and review of the literature. J. Neurol. Sci. 240, 65–69. https://doi.org/10.1016/j.jns.2005.09.010.
Vishnupriya, M., Naveenkumar, M., Manjima, K., Sooryasree, N., Saranya, T., Ramya, S., Winster, S.H., Paulpandi, M., Balachandar, V., Arul, N., 2021. Post-COVID pulmonary fibrosis: therapeutic efficacy using with mesenchymal stem cells–How

the lung heals. Eur. Rev. Med. Pharmacol. Sci. 25, 2748–2751. https://doi.org/10.26355/eurrev_202103_25438.
What Patients with Diabetes, Cancer and Kidney Disorders Need to Know about Black Fungus, 2021. Indian Express.
Waizel-Haiat, S., Guerrero-Paz, J.A., Sanchez-Hurtado, L., Calleja-Alarcon, S., Romero-Gutierrez, L., 2021. A case of fatal rhino-orbital mucormycosis associated with new onset diabetic ketoacidosis and COVID-19. Cureus 13, e13163. https://doi.org/10.7759/cureus.13163.
Werthman-Ehrenreich, A., 2021. Mucormycosis with orbital compartment syndrome in a patient with COVID-19. Am. J. Emerg. Med. 42, 264.e5–264.e8. https://doi.org/10.1016/j.ajem.2020.09.032.
World Health Organization, 2021a. Coronavirus Disease (COVID-19) Weekly Epidemiological Update and Weekly Operational Update. World Health Organization, 2021. https://www.who.int/emergencies/diseases/novel-coronavirus-2019/situation-reports. accessed 6.21.21.
World Health Organization, 2021b. Weekly Epidemiological Update on COVID-19 - 15 June 2021. World Health Organization, 2021. https://www.who.int/publications/m/item/weekly-epidemiological-update-on-covid-19—15-june-2021. accessed 6.21.21.
World Health Organization, 2021c. Episode #39 - Update on Virus Variants. World Health Organization, 2021. https://www.who.int/emergencies/diseases/novel-coronavirus-2019/media-resources/science-in-5/episode-39—update-on-virus-variants. accessed 6.21.21.
Wotiye, A.B., Poornachandra, K., Ayele, B.A., 2020. Invasive intestinal mucormycosis in a 40-year old immunocompetent patient-a rarely reported clinical phenomenon: a case report. BMC Gastroenterol. 20, 61. https://doi.org/10.1186/s12876-020-01202-5.
Yang, W., Cao, Q., Qin, L., Wang, X., Cheng, Z., Pan, A., Dai, J., Sun, Q., Zhao, F., Qu, J., Yan, F., 2020a. Clinical characteristics and imaging manifestations of the 2019 novel coronavirus disease (COVID-19):A multi-center study in Wenzhou city, Zhejiang, China. J. Infect. 80, 388–393. https://doi.org/10.1016/j.jinf.2020.02.016.
Yang, H., Wang, C., 2016. Looks like tuberculous meningitis, but not: a case of rhinocerebral mucormycosis with Garcin syndrome. Front. Neurol. 7, 181. https://doi.org/10.3389/fneur.2016.00181.
Yang, X., Yu, Y., Xu, J., Shu, H., Xia, J., Liu, H., Wu, Y., Zhang, L., Yu, Z., Fang, M., Yu, T., Wang, Y., Pan, S., Zou, X., Yuan, S., Shang, Y., 2020b. Clinical course and outcomes of critically ill patients with SARS-CoV-2 pneumonia in Wuhan, China: a single-centered, retrospective, observational study. Lancet Respir. Med. 8, 475–481. https://doi.org/10.1016/S2213-2600(20)30079-5.
Zafar, S., Prabhu, A., 2017. Rhino-orbito-cerebral mucormycosis: recovery against the odds. Practical. Neurol. 17, 485–488. https://doi.org/10.1136/practneurol-2017-001671.
Zhang, J., Kim, J.D., Beaver, H.A., Takashima, M., Lee, A.G., 2013. Rhino-orbital mucormycosis treated successfully with posaconazole without exenteration. Neuro Ophthalmol. 37, 198–203. https://doi.org/10.3109/01658107.2013.809463.
Zurl, C., Hoenigl, M., Schulz, E., Hatzl, S., Gorkiewicz, G., Krause, R., Eller, P., Prattes, J., 2021. Autopsy proven pulmonary mucormycosis due to Rhizopus microsporus in a critically ill COVID-19 patient with underlying hematological malignancy. J. Fungi 7, 88. https://doi.org/10.3390/jof7020088.