Since January 2020 Elsevier has created a COVID-19 resource centre with free information in English and Mandarin on the novel coronavirus COVID-19. The COVID-19 resource centre is hosted on Elsevier Connect, the company's public news and information website.

Elsevier hereby grants permission to make all its COVID-19-related research that is available on the COVID-19 resource centre - including this research content - immediately available in PubMed Central and other publicly funded repositories, such as the WHO COVID database with rights for unrestricted research re-use and analyses in any form or by any means with acknowledgement of the original source. These permissions are granted for free by Elsevier for as long as the COVID-19 resource centre remains active.

ARTICLE IN PRESS

Brain Hemorrhages xxx (xxxx) xxx

Contents lists available at ScienceDirect

Brain Hemorrhages

journal homepage: www.keaipublishing.com/en/journals/brain-hemorrhages/

Aphasia seven days after second dose of an mRNA-based SARS-CoV-2 vaccine

Josef Finsterer *, Maria Korn

Klinik Landstrasse, Messerli Institute, Vienna, Austria

ARTICLE INFO

Article history:
Received 9 June 2021
Received in revised form 19 June 2021
Accepted 19 June 2021
Available online xxxx

Keywords:
Intracerebral bleeding
SARS-CoV-2
COVID-19
Aphasia
Side effect
Adverse reaction
Vaccination

ABSTRACT

Objectives: Though rare, neurological side effects of SARS-CoV-2 vaccinations are increasingly reported. Even if the first dosage goes uncomplicated, the second dose may be complicated by severe adverse reactions as in the following case.

Case report: A 52yo male developed sudden-onset reading difficulty and aphasia 7d after the second dose of an mRNA-based SARS-CoV-2 vaccine. He had a previous history of myocardial infarction, arterial hypertension, hyperlipidemia, and nephrolithiasis. Blood pressure was slightly elevated on admission. Blood tests revealed mildly elevated D-dimer, pre-diabetes and hyperuricemia. Cerebral magnetic resonance imaging revealed an intracerebral bleeding (ICB) in the left temporal lobe. Aphasia resolved almost completely within a few days. Blood pressure values were normal throughout hospitalisation. Whether there was a causal relation between the ICB and the vaccination remains speculative but cannot be definitively excluded.

Conclusions: A second dose of a SARS-CoV-2 vaccination may be followed by ICB. Though the pathophysiology of ICB remains unexplained a causal relation between ICB and the vaccination cannot be excluded. Risk factors for ICB should be carefully monitored in patients undergoing SARS-CoV-2 vaccination.

© 2021 International Hemorrhagic Stroke Association. Publishing services by Elsevier B.V. on behalf of KeAi Communications Co. Ltd. This is an open access article under the CC BY-NC-ND license (http://creativecommons.org/licenses/by-nc-nd/4.0/).

Letter to the Editor

Though vaccination against SARS-CoV-2 is usually well tolerated, some patients experience side effects, including neurological adverse reactions.[1] Neurological adverse reactions to SARS-CoV-2 vaccinations include exacerbation or new onset neuroimmunologic disease, such as myasthenia, Guillain-Barre syndrome, immune encephalitis, or multiple sclerosis[2] but also ischemic stroke, or intra-cerebral bleeding (ICB). ICB may be due to hypocoagulability or immune-mediated thrombotic thrombocytopenia.[3,4] Even if patients do not experience side effects after the first dosage, they may develop severe neurological complications after the second dose, as in the following case.

The patient is a 52yo non-smoking, HIV-negative male, who experienced sudden-onset difficulties with reading and speaking seven days after the second dose of an mRNA-based SARS-CoV-2 vaccine. He did not experience any side effects immediately after the first or second vaccination. His previous history was positive for myocardial infarction four months earlier treated with stent implantation into the left anterior descending, ramus circumflexus, and right coronary artery, arterial hypertension, hyperlipidemia, and nephrolithiasis. Myocardial infarction was complicated by systolic dysfunction and non-sustained (persistent) ventricular tachycardias being treated with a temporary life west. His current medication comprised sacubitril/valsartan, atorvastatin, bisoprolol, and acetyl-salicylic acid. Neurologic exam one day later (hospital day (hd)-1) revealed motor aphasia with paraphasias and a spontaneous Babinski sign on the right side. Blood pressure was 170/98 mmHg on admission. Blood tests were unremarkable except for slightly elevated D-dimer, hyperuricemia, and a HbA1c value of 5.8 (n, 4.0–5.7). The glucose tolerance test was indicative of pre-diabetes. Other coagulation parameters and the thrombocyte count were within normal limits. Cerebral MRI revealed a lobar bleeding in the left temporal lobe (Fig. 1). Cerebral CT angiography was normal. Aphasia resolved almost completely within a few days. On hd4 he was transferred to the rehabilitation unit with a therapy of sacubtril/valsartan, atorvastatin, and bisoprolol.

The presented patient is interesting for ICB shortly after the second dose of an mRNA-based SARS-CoV-2 vaccine. Whether there was a causal relation between vaccination and the ICB remains

* Corresponding author.
E-mail address: fifigs1@yahoo.de (J. Finsterer).

https://doi.org/10.1016/j.hest.2021.06.001
2589-238X/© 2021 International Hemorrhagic Stroke Association. Publishing services by Elsevier B.V. on behalf of KeAi Communications Co. Ltd.
This is an open access article under the CC BY-NC-ND license (http://creativecommons.org/licenses/by-nc-nd/4.0/).

Please cite this article as: J. Finsterer and M. Korn, Aphasia seven days after second dose of an mRNA-based SARS-CoV-2 vaccine, Brain Hemorrhages, https://doi.org/10.1016/j.hest.2021.06.001

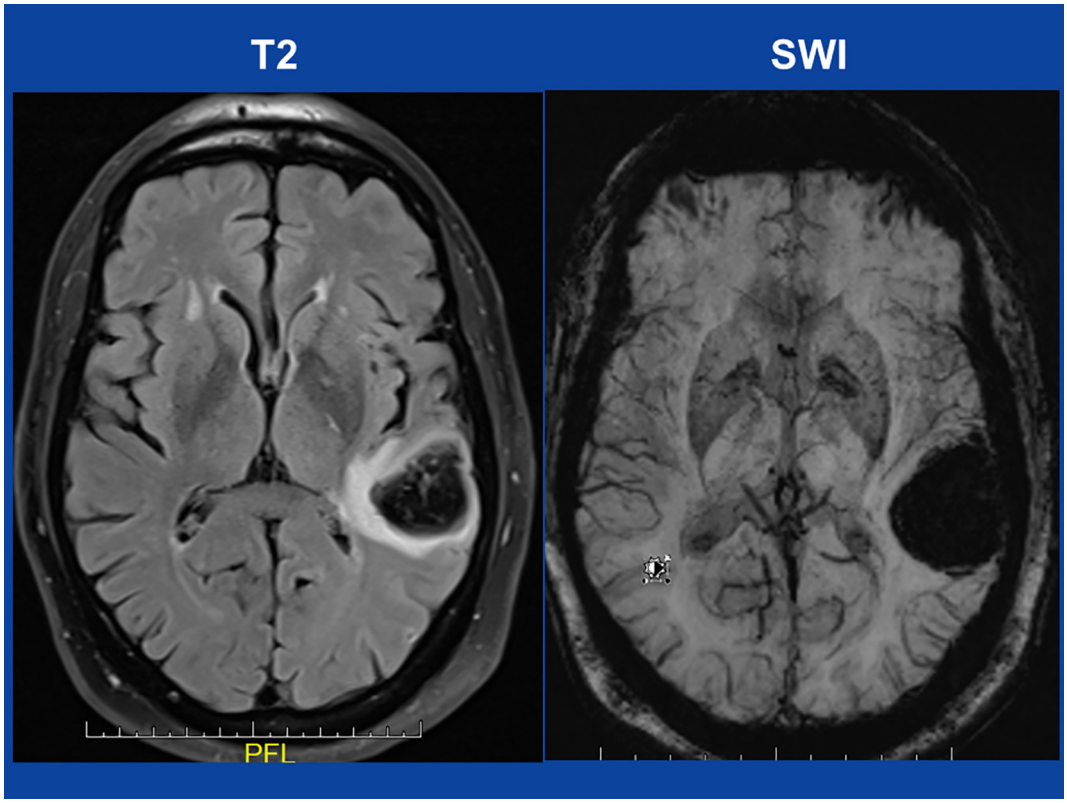

Fig. 1. cerebral MRI on admission showing an ICB in the left temporal lobe on T2-weighted images (left) and on susceptibility-weighted imaging (SWI) sequencies (right).

speculative. Arguments for a causal relation are that ICB has been reported as a complication of a SARS-CoV-2 vaccination,[5,6] that ICB occurred time-linked to the vaccination, and that arterial hypertension can be a complication of a SARS-CoV-2 vaccination.[7] A further argument in favour of a causal relation is that ICB has been repeatedly reported as a complication of infections with SARS-CoV-2.[8] Whether the slightly elevated D-dimer indicates hypercoagulability followed by compensatory hypocoagulability remains speculative. Pathophysiological mechanisms explaining SARS-CoV-2 associated ICB could be endothelial cell dysfunction due to direct invasion of the virus, vaccination induced thrombocytopenia, hypocoagulability due to disseminated intravascular coagulopathy or increased fibrinolysis,[9] or arterial hypertension due to affection of the autonomic innervation of the heart, Arguments against a causal relation are that the patient also had slightly elevated arterial hypertension on admission, that the latency between vaccination and ICB was 7 days, and that ICB after SARS-CoV2 vaccination has been only rarely reported. Possibly, the vaccination increased systolic blood pressure, or caused immune-mediated thrombocytopenia or hypocoagulability. The latency of 7 days argues against an immune mechanism as the T-cell response to the vaccination peaks not earlier than 14 days after vaccination.[10]

This case shows that the second dose of a mRNA-based SARS-CoV-2 vaccine may be followed by ICB. Though the pathophysiology of ICB remains unexplained a causal relation between ICB and the vaccination cannot be excluded. Infectiologists and neurologists should remain vigilant for complications of SARS-CoV-2 vaccination. Risk factors for ICB should be carefully monitored in patients undergoing SARS-CoV-2 vaccination

Funding

No funding was received for this study.

Ethical approval

All procedures performed in the studies involving human participants were in accordance with the ethical standards of the institutional and/or national research committee and with the 1964 Helsinki Declaration and its later amendments or comparable ethical standards.

Informed consent

Informed consent was obtained from all individual participants included in the study.

Declaration of Competing Interest

The authors declare that they have no known competing financial interests or personal relationships that could have appeared to influence the work reported in this paper.

References

1. Finsterer J, Scorza FA. SARS-CoV-2 vaccines are not free of neurological side effects. *Acta Neurol Scand*. 2021;144(1):109–110. https://doi.org/10.1111/ane.v144.110.1111/ane.13451.
2. Watad A, De Marco G, Mahajna H, et al. Immune-mediated disease flares or new-onset disease in 27 subjects following mRNA/DNA SARS-CoV-2 vaccination. *Vaccines (Basel)*. 2021;9(5):435. https://doi.org/10.3390/vaccines9050435.
3. Althaus K, Möller P, Uzun G, et al. Antibody-mediated procoagulant platelets in SARS-CoV-2-vaccination associated immune thrombotic thrombocytopenia. *Haematologica*. 2021. https://doi.org/10.3324/haematol.2021.279000.
4. Fueyo-Rodriguez O, Valente-Acosta B, Jimenez-Soto R, et al. Secondary immune thrombocytopenia supposedly attributable to COVID-19 vaccination. *BMJ Case Rep*. 2021;14(5):e242220. https://doi.org/10.1136/bcr-2021-242220.
5. Bjørnstad-Tuveng TH, Rudjord A, Anker P. Fatal cerebral haemorrhage after COVID-19 vaccine. *Tidsskr Nor Laegeforen*. 2021;29:141. https://doi.org/10.4045/tidsskr.21.0312.

6. Greinacher A, Thiele T, Warkentin TE, Weisser K, Kyrle PA, Eichinger S. Thrombotic thrombocytopenia after ChAdOx1 nCov-19 vaccination. *N Engl J Med*. 2021;384(22):2092–2101. https://doi.org/10.1056/NEJMoa2104840.
7. Meylan S, Livio F, Foerster M, Genoud PJ, Marguet F, Wuerzner G. CHUV COVID vaccination center. Stage III hypertension in patients after mRNA-based SARS-CoV-2 vaccination. *Hypertension*. 2021 Jun;77(6):e56–e57. https://doi.org/10.1161/HYPERTENSIONAHA.121.17316.
8. Leasure AC, Khan YM, Iyer R, et al. Intracerebral hemorrhage in patients with COVID-19: an analysis from the COVID-19 cardiovascular disease registry. Stroke 2021:STROKEAHA121034215. 10.1161/STROKEAHA.121.034215.
9. Bunch CM, Thomas AV, Stillson JE, et al. Thromboelastography-guided anticoagulant therapy for the double hazard of thrombohemorrhagic events in COVID-19: a report of 3 cases. *Am J Case Rep*. 2021;22. https://doi.org/10.12659/AJCR.931080.
10. Folegatti PM, Ewer KJ, Aley PK, et al. Oxford COVID Vaccine Trial Group. Safety and immunogenicity of the ChAdOx1 nCoV-19 vaccine against SARS-CoV-2: a preliminary report of a phase 1/2, single-blind, randomised controlled trial. *Lancet*. 2020;396(10249):467–478. https://doi.org/10.1016/S0140-6736(20)31604-4.