mAbs 1:6, 583-589; November/December 2009; © 2009 Landes Bioscience

Monoclonal antibodies and progressive multifocal leukoencephalopathy

Joseph R. Berger,[1,*] Sidney A. Houff[1] and Eugene O. Major[2]

[1]Department of Neurology; University of Kentucky College of Medicine; Lexington, Kentucky USA; [2]Laboratory of Molecular Medicine and Neuroscience; National Institute of Neurological Disorders and Stroke; National Institutes of Health; Bethesda, MD USA

Since their introduction, monoclonal antibodies have found an ever expanding role in the treatment of a wide number of disorders. However, the perturbation of the immune system that attends their use may also increase the risk for the development of disorders that arise in the setting of immunosuppressive conditions, such as, opportunistic infection and malignancy. In this paper, we address the association between some monoclonal antibodies and the development of a rare demyelinating disease of the brain, progressive multifocal leukoencephalopathy (PML). PML results from infection with a ubiquitous polyoma virus, JC virus, and typically occurs in the setting of impaired immunity, most commonly, AIDS. It was first recognized as a potential complication of monoclonal antibody therapy in patients with multiple sclerosis and Crohn disease being treated with natalizumab, an α4β1 and α4β7 integrin inhibitor. Subsequently, efalizumab, a monoclonal antibody used in the treatment of psoriasis, was also demonstrated to be associated with PML. An increased risk has been suggested for rituximab, although most of the patients developing PML with that monoclonal antibody have been treated for B-cell disorders that predispose to the development of PML. Based on our current understanding of the biology of JC virus and the pathogenesis of PML, we propose an explanation for the increased risk for PML that is observed with natalizumab and certain other monoclonal antibodies.

Key words: progressive multifocal leukoencephalopathy, JC virus, natalizumab, efalizumab, rituximab, alemtuzumab, multiple sclerosis, crohn disease

Submitted: 07/31/09

Accepted: 08/24/09

Previously published online: www.landesbioscience.com/journals/mabs/article/9884

*Correspondence to: Joseph R. Berger; Email: jrbneuro@uky.edu

Background

Progressive multifocal leukoencephalopathy (PML) was first described in 1958 by Astrom, Mancall and Richardson.[1] They reported three patients, all with an underlying lymphoproliferative disorder, who presented with neurologic deficits as a consequence of an otherwise unexplained progressive white matter disorder. At the time of their report, the etiology of this disorder had yet to be described. In 1965, ZuRhein suggested that a papovavirus was the cause of PML on the basis of intracellular paracrystalline inclusions observed on electron microscopic studies.[2] Subsequent studies in which viral replication was supported by human fetal glial cells glial confirmed that hypothesis.[3] The virus has been classified as a polyoma and referred to as JC virus from the initials of the individual from whom it was first isolated.

Seroepidemiologic studies have consistently reported a high incidence of antibody to JC viral capsid antigen, VP1, in the world's populations. Between the ages of 1 and 5 years, approximately 10% of children demonstrate antibody to JCV, and by age 10, it can be observed in 40–60% of the population. The acquisition of JC virus during childhood appears to occur slowly[4] and primary infection has yet to be correlated with identifiable clinical disorder. By adulthood, 70–80% of the population has been infected.[4,5] Seroconversion rates to JCV exceed 90% in some urban areas.[5] The mechanism of infection remains uncertain. Transient JC viral shedding in urine has been demonstrated in 30,[6] to more than 50% of immunologically normal individuals[7] and appears to increase with age.[8] Conversely, the virus is not detectable in the saliva or oropharyngeal washings of young healthy adults.[7] The virus has also been detected

worldwide in virtually every sample of sewage that has been examined.[9] Indeed, Bofilll-Mas and Girones have proposed contaminated food and water as potential sources of infection.[9]

PML was a rare disorder until the beginning of the AIDS pandemic in 1981. In the largest review of PML to that date in 1984, Brooks and Walker were able to identify only 230 cases that had been published in the English language or from their own experience.[10] Of these only 69 were pathologically confirmed and only 40 both virologically and pathologically confirmed.[10] Ninety-five percent of the patients in this series had a recognized underlying condition that predisposed them to PML. As in the seminal cases, nearly two thirds had an underlying lymphoproliferative disorder, chiefly, B-cell disorders. An underlying primary immunodeficiency disorder was evident in approximately 16%, but, at the time, there were only five cases of AIDS-associated PML in the literature.[11-13]

AIDS and PML

The onset of the AIDS pandemic was associated with a steep rise in the frequency with which PML was observed. In 1991, a surveillance study of patients diagnosed with AIDS in the San Francisco Bay area revealed a PML prevalence rate of 0.3%.[14] That same year, a study of vital statistics on patients with AIDS reported to the Centers for Disease Control revealed that 0.72% of death certificates listed PML among the diagnoses.[15] A study of hospitalized patients at a large, university-affiliated, public health trust hospital in Miami, Florida, revealed that nearly 4% of all hospitalized AIDS patients had PML.[16] An autopsy series of nearly 1,000 patients reported in 1991 similarly showed that 4% of HIV-infected individuals died with neuropathologically confirmed PML.[17] Repeated studies in the pre-highly active (HAART) or combined antiretroviral therapy (cART) era have demonstrated that approximately 1 in 20 HIV-infected persons will die with PML. In 1993, AIDS accounted for 87% of the underlying causes of immunosuppression predisposing to PML.[18] The effect of cART on PML incidence has been controversial with some studies demonstrating a decline in incidence[19,20] and others failing to document any change.[21,22] Regardless, PML remains one of the four most common HIV-associated CNS opportunistic infections[23] and PML occurs with HIV/AIDS ten times more commonly than with other underlying immunosuppressive disorders. Conversely, the occurrence of PML in otherwise immunological healthy individuals is extraordinarily rare.

Monoclonal Antibodies and PML

Treatment with monoclonal antibody products is a unique, newly identified predisposing factor for the development of PML. Among the monoclonal antibodies that increase the risk of PML are natalizumab (Tysabri®), an α4β1 and α4β7 antagonist, and efalizumab (Raptiva®), an anti-CD-11a antibody. Rituximab (Rituxan®), an anti-CD20 antibody, may also increase the risk of PML. Another monoclonal antibody, alemtuzumab (Campath®), an anti-CD52 antibody that depletes both T and B-cells, has not, as yet, been recognized to meaningfully increase the risk of PML.

Natalizumab has demonstrated efficacy in MS likely as a result of its ability to prevent activated lymphocytes from entering the brain. As a consequence, it is currently marketed for the treatment of relapsing-remitting multiple sclerosis as monotherapy. It was initially removed from the market on February 28th, 2005, as three patients had developed PML with the drug; two patients were in the Sentinel study for MS and had developed PML while on a combination of intramuscular interferon α1b (Avonex®) and natalizumab.[24,25] A third received natalizumab in a clinical trial of Crohn disease treatment.[26] Approximately 3,000 individuals had been treated with natalizumab at that time suggesting that as many as 1 in 1,000 treated individuals developed this illness in concert with treatment of natalizumab.[27] And subsequent estimates suggested that 1 in 1,000 persons would develop PML after 17.8 months of treatment.[28] Natalizumab returned to market in July 2006 and as of July 2009, 10 cases have been seen in this time frame[29] with an estimated PML risk of 1 in 1,133 for patients treated greater than 24 months. Importantly, prior to the use of natalizumab for MS and Crohn disease, neither disorder had been previously associated with PML.

Efalizumab is an anti-CD11a IgG1 antibody with demonstrated efficacy in moderate to severe plaque psoriasis.[30,31] It targets psoriasis pathogenesis at multiple levels, importantly by inhibiting the initial T-cell activation in lymph nodes, preventing binding of T-cells to endothelial cells and blocking trafficking of T-cells from the circulation into the psoriatic skin preventing their reactivation in the dermal and epidermal layer.[32] More than 6,000 patients had been treated with efalizumab before its removal from the European and U.S. markets in the spring of 2009; of these, only 166 patients had received more than three years of therapy. Four patients ranging in age from 47 to 73 years old treated with efalizumab for more than three years for psoriasis have developed PML. PML was confirmed in three cases and suspected in one. As with MS and Crohn disease, PML had not previously been observed complicating psoriasis.

Rituximab is an anti-CD20 that targets B-lymphocytes. It has been employed chiefly in the treatment of lymphoproliferative diseases, although it has found application in other autoimmune diseases including rheumatoid arthritis, systemic lupus erythematosus,[33] and even multiple sclerosis[34] and neuromyelitis optica.[35] From 1997 to 2008, 52 patients with lymphoproliferative disorders (generally B-cell malignancies), 2 with SLE, 1 with rheumatoid arthritis, and 1 with autoimmune pancytopenia have been reported with PML after rituximab therapy.[33] All had been treated with other immunosuppressive regimens, including hematopoietic stem cell transplantation in seven.[33] B-cell malignancies, after HIV/AIDS, are the second most common predisposing factor for PML, therefore, the occurrence of PML with these disorders is not uncommon. Garcia-Suarez and colleagues have even argued that the use of rituximab after high dose therapy and hematopoietic stem cell transplantation delays the onset of PML.[36] However, it is likely that the number of cases of PML reported with rituximab is an underestimate of the true incidence. There are at least 26 cases of PML that have been reported with SLE

and over 40% of cases have occurred with minimal immunosuppression, suggesting that SLE itself predisposes to PML.[37] PML has also been reported with rheumatoid arthritis in the absence of rituximab therapy.[10]

Barriers to the Development of PML

As 70–80% of the world's population is infected with JC virus, the barriers to the development of this disorder among immunologically healthy individuals must be extraordinary. Indeed, it is likely that there are multiple barriers to the development of the disease and an increased risk for its development requires that more than one is lowered. Mechanisms by which HIV infection may increase the risk for PML have been addressed in a prior publication.[38] Some parallels likely exist between those mechanisms and the ones that underlie the increased risk with some newer biological agents, including natalizumab, efalizumab and possibly, rituximab. Unfortunately, our understanding of PML remains incomplete in some measure because of the lack of animal models for the disorder; however, we will propose what we believe best explains this increased risk.

Development of PML proceeds is a stochastic sequence of events. The series of barriers that must be overcome in order to develop the disease can be divided into those that relate to the virus and those that result from an effective immune system. The proposed series of events that might lead to development of PML are outlined in **Table 1**.

Table 1. Proposed stages of PML development

Initial infection (typically <20 years)
Establishment of latent infection
Alteration in the non-coding regulatory region of JCV in latent sites converting the virus to a neurotropic strain
Failed immunosurveillance in the periphery
Periodic re-expression of JCV in PBMCs
Productive JCV infection of PBMC—dependent on B cell maturity and expression of transcriptional factors
Entry of JCV into brain
Establishment of productive oligodendrocyte infection
Failure of immunosurveillance in the brain

Note: JCV, JC virus; PBMC, peripheral blood mononuclear cells; PML, progressive multifocal leukoencephalopathy.

Viral Factors

Firstly, one must be infected with the JC virus. Although speculative, it is probable that the initial infection is with a form of the virus referred to as archetype virus. This virus is the one detected in the urine of infected individuals. It is not capable of replicating effectively in glial tissues and therefore, does not increase the risk of PML. Following infection, it is presumed that the virus establishes latency in most, if not all, individuals. Latent sites of infection include renal tubular epithelium, bone marrow, spleen, tonsils, lymph nodes and perhaps other sites.[39] Whether the virus establishes latency in the brain remains controversial. If the initial infection is with the archetype JCV, it must mutate with an expansion of the non-coding control region of the virus (**Fig. 1**) in order to be capable of growing efficiently in glial tissues. In the absence of this genetic modification, PML is not a serious threat. Gene rearrangement in the NCCR region permits it to bind to the NF-1X binding protein found in the nuclei of glial cells, a protein shared by B-cells.[40-43] How the gene rearrangement occurs is unclear, but its latent presence in somatic cells uniquely designed to rearrange the genome, namely, B-cells is intriguing. We propose that the machinery for gene arrangement utilized for immunoglobulin synthesis, specifically, the recombination activating gene and cytidine deaminase, in infected cells of B-cell lineage facilitates the development of a neurotropic strain of the virus.[44] This hypothesis fits with the observation of the presence of both archetype JC virus and that with a rearranged regulatory region in the bone marrow.[45] Genetic rearrangement in the promoter region may not be the only alteration that increases the neuropathogenecity of the virus. Amino acid substitutions in the VP1 capsid protein of the virus may also play a role in virulence.[46]

Although the possibility exists that initial infection with JC virus may result in PML, several convergent lines of evidence suggest that the disorder results from reactivated virus. Firstly, when immunoglobulin to JC virus is assayed in PML, it is IgG; IgM to JC virus is rarely observed.[47] Secondly, PML is a rare disorder in children.[48] Lastly, the JC virus genome obtained from brains of five patients with PML and from tissue specimens (lymph node, spleen, bone marrow) of the same individuals that had been banked up to four years earlier showed that the two isolates from each individual were virtually identical.[33]

Mutation to a neurotropic form is, by itself, insufficient to result in disease. The virus must be re-expressed and circulate in the peripheral blood, gaining access to the brain as either free virus or cell-associated virus. Failed immunosuppression likely leads to periodical expression of JC virus. The virus can be detected in both sera and peripheral blood mononuclear cells (PBMCs). Studies of normal healthy controls have demonstrated variable results from 0% to greater than 10%. The likelihood of detecting circulating JC virus in PML patients increases with immunosuppression as has been demonstrated in the AIDS population.[49,50] The appearance of JC virus in the blood prior to the development of PML has been reported in the number of instances.[26,51] Similarly, JC virus has been detected in the blood of MS patients treated with natalizumab prior to the diagnosis of PML, and in some MS patients without PML (Personal communication: Major EO, March 31, 2009, Lexington, Kentucky). This supports the hypothesis that the virus reaches the brain by hematogenous route as suggested by Houff et al.[40] In addition to being re-expressed, the risk of developing PML is likely enhanced when the virus is actively replicating. Studies employing

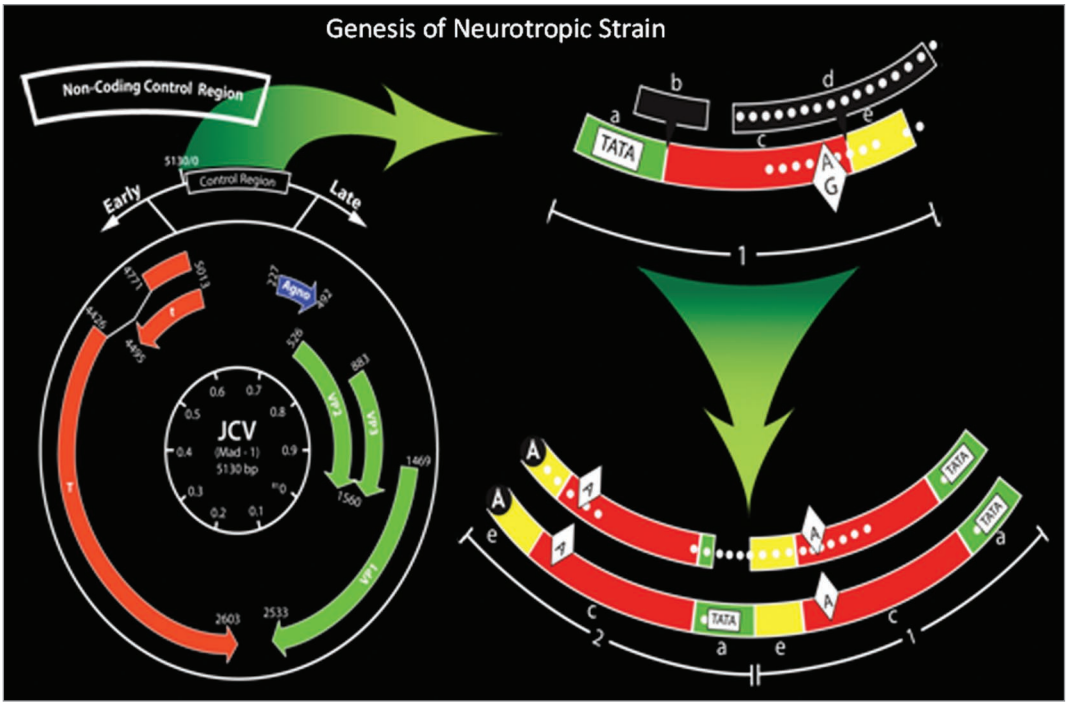

Figure 1. Genesis of the neurotropic Strain of JC Virus. (Adapted from Jensen and Major[85]). The JC virus genome is depicted on the left. The genes coding for its three structural proteins and three regulatory proteins (here) are highly conserved, but not the non-coding control region which dictates whether the virus can bind to a cells NF-1X DNA binding proteins. The archetype virus' non-coding control region is at the top; at the bottom, is the 98 bp tandem repeat sequence seen in the virus isolated from brains with PML. This is the mutation that must occur.

reverse transcriptase PCR in HIV-infected patients indicate that despite detection of the virus in PBMCs, active replication is a rare event.[52]

Immune Factors

As previously mentioned, immunosuppression increases the frequency with which JC virus is detected in the peripheral blood. However, perhaps more importantly, an effective CNS immunosurveillance can check the virus even after it has established glial infection. This has been amply demonstrated by development of immune reconstitution inflammatory syndrome (IRIS) in HIV-infected individuals with PML treated with highly active antiretroviral therapy. This observation is not limited to the HIV/AIDS population as immune recovery that attends other conditions associated with PML can also result in PML-IRIS. Prolonged survival (exceeding 12 months) with PML that was observed in only about 10% of individuals with HIV-associated PML prior to the introduction of HAART[53] increased substantially afterwards. Berenguer found that 63.6% of HIV-associated PML patients survived a median duration of 2.2 years with HAART and that one half of the survivors experience neurological improvement.[54] Correlates with survival include a higher CD4 lymphocyte counts,[55] the presence of JCV-specific cytotoxic T-lymphocytes,[56,57] contrast enhancement on MRI,[55] and probably pathologically demonstrated inflammatory response;[55,58] all indicative of the importance of the immune response in containing the infection once established in the brain.

Lowering the Barriers to Development of PML

The stochastic processes involved in development of PML are influenced by a number of factors, including co-infection with HIV, and treatment with natalizumab, efalizumab and rituximab. In effect, these factors appear to lower the barriers to development of the disease.

HIV/AIDS

In large part, the high incidence of PML in the HIV/AIDS population is likely a reflection of differences in the degree and duration of cellular immunosuppression and direct HIV-1 effects on JCV multiplication.[38] It appears the greater the degree of immunosuppression and the longer the duration of the HIV infection, the greater the likelihood of developing PML. The median CD4 cell counts at the time of diagnosis of PML from the two largest studies to date of AIDS-associated PML were 54,[53] and 60 cells/cu mm.[19] This results in the frequent re-expression of JCV in peripheral blood, as well as a failure to contain and eradicate the infection once established in the CNS. B-cell activation seen with HIV infection[59] may promote JCV transcriptional control region gene re-arrangement,[60] and also result in productive JCV infection of the PBMC due to an upregulation of the B-cell transcriptional factors. If JCV enters the CNS as a cell-associated virus, this entry is facilitated by the alteration of the blood-brain-barrier and the increased

expression of brain microvascular adhesion molecules that attend HIV infection.[38] Transactivation of the JCV within the brain may occur as a consequence of both HIV tat protein and the expression of a panoply of cytokines and chemokines elicited by HIV infection.[38]

Natalizumab

The explanation for the unexpected appearance of PML with natalizumab is also multifactorial because the product may facilitate the development of PML by affecting both the virus and the immune system. The binding of α4β1 integrin by natalizumab results in the release of lymphocytes from bone marrow stores. Natalizumab therapy for MS significantly elevates circulating CD19⁺ B-cells, particularly CD19⁺ CD10⁺pre-B-cells.[61] If these cells are latently infected with JCV, detectable virus may be observed in the peripheral blood. As the immature B-cells among them mature, transcriptional factors that are capable of transactivating JC virus are upregulated.[44,62] Additionally, other factors, including other infections that arise with natalizumab therapy, such as, HHV-6, may also transactivate the JC virus.[63] This increased expression of actively replicating virus occurs in the very cells that uniquely contain the necessary genetic machinery to rearrange the virus' transcriptional control region that may convert it to a neurotropic strain. Coupled with the likely increased expression of actively replicating virus in the blood is a failure of immunosurveillance. Firstly, natalizumab blocks CNS entry by lymphocytes, particularly important would be the blocking of JCV-specific cytotoxic lymphocytes. The latter, commonly found in normal individuals,[64] correlate very strongly with PML survival.[56,57] Dendritic cells have been demonstrated to be instrumental in the expansion of the JCV-CTL response.[65] In one patient with PML complicated by natalizumab therapy for MS, autopsy revealed a significant decrease in CD209⁺ dendritic cells in cerebral perivascular spaces; also, no CD4⁺ T-cells were detected in the brain tissue.[66] Therefore, there appear to be multiple insults to the immune system that predispose to the development of PML following natalizumab administration.

If this explanation for the increased incidence of PML with monoclonal antibodies that affect α4β1 integrin is correct, the occurrence of PML with α4β7 integrin inhibition by monoclonal antibodies would be unanticipated. The inhibition of α4β7 integrin is the proposed mechanism for the efficacy of natalizumab in Crohn disease[67] and monoclonal antibodies solely targeting α4β7 integrin are under investigation for the treatment of autoimmune gut disorders. Similarly, anti-tumor necrosis factor therapy, another form of therapy for inflammatory bowel disorders, would also not be anticipated to significantly increase the risk of PML and, to date, that has been the experience.

Efalizumab

There is insufficient data regarding the effects of efalizumab to comfortably comment on potential mechanisms by which it increases the risk of PML. However, efalizumab clearly affects the immune system in a fashion akin to natalizumab, and likely predisposes to PML by lowering immunological barriers. Efalizumab inhibits T-cell activation, migration and reactivation[68,69] and reduces the chemotactic properties of monocytes and neutrophils and downregulates VLA4.[70] Dendritic cells in the skin are significantly decreased after efalizumab treatment.[71] Whether the same pertains to brain tissue is unknown. Whether it affects viral mutation and replication remains unknown.

Rituximab

Rituximab is a monoclonal antibody directed against CD20 expressed by pre-B and B-cells, but not stem cells or plasma cells.[72] It results in profound B-cell depletion. PML has been described in more than 50 patients treated with rituximab; all of whom had received other immunosuppressive drugs and had, with rare exception, underlying disorders that predispose to PML.[33] PML was diagnosed a median of 5.5 months after the last rituximab dose.[33] With repopulation of the peripheral B-cells, immature B-cells predominate and certain cells such as memory cells are significantly delayed in their reappearance.[73] The rate of B-cell reconstitution varies from 6 months to up to 24 months depending on additional anti-lymphocyte treatments, especially stem cell transplantation.[74,75] Therefore, PML following rituximab therapy develops in conjunction with the reconstitution of the B-cell population. Additionally, rituximab also have reduced CD3 T-cells in the cerebrospinal fluid.[76] The temporal profile and functional consequences of a reduction in T-cells in patients treated with rituximab is unknown. Many of the mechanisms operant with natalizumab that predispose to PML also appear to be present with rituximab, for example, the migration of pre-B-cells into the peripheral circulation in response to B-cell depletion. However, despite the numbers of observed cases suggests that PML is less likely with rituximab than natalizumab.

Alemtuzumab

Alemtuzumab is a monoclonal antibody directed against CD52, an antigen expressed on more than 95% of B and T-cells.[77] It has been used most extensively in lymphoproliferative diseases,[78] but also in organ and stem cell transplantation and is under investigation in the treatment of MS.[79] Alemtuzumab depletes both B and T-cells with B-cells returning to levels greater than their baseline values at 27 ± 15 months after therapy.[80] CD4 T-cells remain depleted for an average of 61 months and CD8 cells for 30 months.[80] Alemtuzumab would therefore seem to be uniquely suited to predispose to the development of PML, yet only three cases have been reported to date; one patient developed PML three months after initiation of alemtuzumab for chronic lymphocytic leukemia,[81] another with a peripheral T-cell lymphoma who received alemtuzumab after eight cycles of cyclophosphamide, doxorubicin, vincristine and prednisone,[82] and a third in a lung transplant recipient who received steroids, anti-thymocyte globulin and alemtuzumab.[83] The target antigen of alemtuzumab is not expressed on hematopoietic progenitor cells,[84] and whether incidence rates of PML with alemtuzumab will increase with increased use in the future remains to be seen.

Future Directions

The pathogenesis of PML we have presented remains speculative. We believe that the only logical explanation for the rare appearance of PML in otherwise healthy individuals can only be explained by the lowering of multiple barriers to development of the disease, some of which are enormous. We provide plausible explanations for the high incidence of PML with HIV/AIDS and the unexpected occurrence of PML after treatment with natalizumab and rituximab based on what is currently known about the mechanism of action of these monoclonal antibodies.

Clearly, there are many unanswered questions. Is PML always the result of reactivated JCV infection? Once an individual is infected, does the virus always become latent? What are the sites of viral latency and what dictates reactivation from these sites? Is the presence of JCV in peripheral blood predicative of the development of PML? Could detection of JC virus through polymerase chain reaction (PCR) serve as a useful tool in risk reduction? If not, would demonstrating that the virus is actively replicating using quantitative PCR or demonstrating the presence of a neurotropic strain of virus in the blood be a better predictor? Does the risk of PML increase with prolonged exposure? Regarding the latter question, the appearance of PML only after three years of efalizumab therapy and the absence of PML in patients treated with natalizumab for less than 12 months and an increasing incidence after 18 months of therapy are certainly suggestive of this possibility.

Answering these and other questions will prove enormously helpful in addressing the risks for PML following treatment with the expanding array of newer immunomodulatory drugs. It will also provide possible strategies for prevention and treatment of PML.

References

1. Astrom KE, Mancall EL, Richardson EP Jr. Progressive multifocal leuko-encephalopathy; a hitherto unrecognized complication of chronic lymphatic leukaemia and Hodgkin's disease. Brain 1958; 81:93-111.
2. ZuRhein G, Chou S. Particles resembling papovavirions in human cerebral demyelinating disease. Science 1965; 148:1477-9.
3. Padgett BL, Walker DL, ZuRhein GM, Eckroade RJ, Dessel BH. Cultivation of papova-like virus from human brain with progressive multifocal leucoencephalopathy. Lancet 1971; 1:1257-60.
4. Stolt A, Sasnauskas K, Koskela P, Lehtinen M, Dillner J. Seroepidemiology of the human polyomaviruses. J Gen Virol 2003; 84:1499-504.
5. Walker D, Padgett B. The epidemiology of human polyomaviruses. In: Sever J, Madden D, eds. Polyomaviruses and human neurological disease. New York: Alan R. Liss, Inc 1983; 99-106.
6. Koralnik IJ, Boden D, Mai VX, Lord CI, Letvin NL. JC virus DNA load in patients with and without progressive multifocal leukoencephalopathy. Neurology 1999; 52:253-60.
7. Berger JR, Miller CS, Mootoor Y, Avdiushko SA, Kryscio RJ, Zhu H. JC virus detection in bodily fluids: Clues to transmission. Clin Infect Dis 2006; 43:9-12.
8. Chang H, Wang M, Tsai RT, Lin HS, Huan JS, Wang WC, et al. High incidence of JC viruria in JC-seropositive older individuals. J Neurovirol 2002; 8:447-51.
9. Bofill-Mas S, Girones R. Excretion and transmission of JCV in human populations. J Neurovirol 2001; 7:345-9.
10. Brooks BR, Walker DL. Progressive multifocal leukoencephalopathy. Neurol Clin 1984; 2:299-313.
11. Bernick C, Gregorios JB. Progressive multifocal leukoencephalopathy in a patient with acquired immune deficiency syndrome. Arch Neurol 1984; 41:780-2.
12. Miller JR, Barrett RE, Britton CB, Tapper ML, Bahr GS, Bruno PJ, et al. Progressive multifocal leukoencephalopathy in a male homosexual with T-cell immune deficiency. N Engl J Med 1982; 307:1436-8.
13. Snider WD, Simpson DM, Nielsen S, Gold JW, Metroka CE, Posner JB. Neurological complications of acquired immune deficiency syndrome: analysis of 50 patients. Ann Neurol 1983; 14:403-18.
14. Gillespie SM, Chang Y, Lemp G, Arthur R, Buchbinder S, Steimle A, et al. Progressive multifocal leukoencephalopathy in persons infected with human immunodeficiency virus, San Francisco, 1981–1989. Ann Neurol 1991; 30:597-604.
15. Holman RC, Torok TJ, Belay ED, Janssen RS, Schonberger LB. Progressive multifocal leukoencephalopathy in the United States, 1979–1994: increased mortality associated with HIV infection. Neuroepidemiology 1998; 17:303-9.
16. Berger JR, Kaszovitz B, Post MJ, Dickinson G. Progressive multifocal leukoencephalopathy associated with human immunodeficiency virus infection. A review of the literature with a report of sixteen cases. Ann Intern Med 1987; 107:78-87.
17. Kure K, Llena JF, Lyman WD, Soeiro R, Weidenheim KM, Hirano A, et al. Human immunodeficiency virus-1 infection of the nervous system: an autopsy study of 268 adult, pediatric, and fetal brains. Hum Pathol 1991; 22:700-10.
18. Selik RM, Karon JM, Ward JW. Effect of the human immunodeficiency virus epidemic on mortality from opportunistic infections in the United States in 1993. J Infect Dis 1997; 176:632-6.
19. Khanna N, Elzi L, Mueller NJ, Garzoni C, Cavassini M, Fux CA, et al. Incidence and outcome of progressive multifocal leukoencephalopathy over 20 years of the Swiss HIV Cohort Study. Clin Infect Dis 2009; 48:1459-66.
20. Sacktor N, Lyles RH, Skolasky R, Kleeberger C, Selnes OA, Miller EN, et al. HIV-associated neurologic disease incidence changes: Multicenter AIDS Cohort Study, 1990–1998. Neurology 2001; 56:257-60.
21. Gray F, Chretien F, Vallat-Decouvelaere AV, Scaravilli F. The changing pattern of HIV neuropathology in the HAART era. J Neuropathol Exp Neurol 2003; 62:429-40.
22. Yoritaka A, Ohta K, Kishida S. Prevalence of neurological complications in Japanese patients with AIDS after the introduction of HAART. Rinsho Shinkeigaku 2007; 47:491-6.
23. Collazos J. Opportunistic infections of the CNS in patients with AIDS: diagnosis and management. CNS Drugs 2003; 17:869-87.
24. Kleinschmidt-DeMasters BK, Tyler KL. Progressive multifocal leukoencephalopathy complicating treatment with natalizumab and interferon beta-1a for multiple sclerosis. N Engl J Med 2005; 353:369-74.
25. Langer-Gould A, Atlas SW, Green AJ, Bollen AW, Pelletier D. Progressive multifocal leukoencephalopathy in a patient treated with natalizumab. N Engl J Med 2005; 353:375-81.
26. Van Assche G, Van Ranst M, Sciot R, Dubois B, Vermeire S, Noman M, et al. Progressive multifocal leukoencephalopathy after natalizumab therapy for Crohn's disease. N Engl J Med 2005; 353:362-8.
27. Berger JR, Koralnik IJ. Progressive multifocal leukoencephalopathy and natalizumab—unforeseen consequences. N Engl J Med 2005; 353:414-6.
28. Yousry TA, Major EO, Ryschkewitsch C, Fahle G, Fischer S, Hou J, et al. Evaluation of patients treated with natalizumab for progressive multifocal leukoencephalopathy. N Engl J Med 2006; 354:924-33.
29. Tysabri Update. 2009. (Accessed 2009; at http://phx.corporate-ir.net/External.File?item=UGFyZW50SUQ9MTAwODZ8Q2hpbGRJRD0tMXxUeXBlPTM=&t = 1).
30. Leonardi CL. Current concepts and review of efalizumab in the treatment of psoriasis. Dermatol Clin 2004; 22:427-35.
31. Gordon KB, Papp KA, Hamilton TK, Walicke PA, Dummer W, Li N, et al. Efalizumab for patients with moderate to severe plaque psoriasis: a randomized controlled trial. JAMA 2003; 290:3073-80.
32. Lebwohl M, Tyring SK, Hamilton TK, Toth D, Glazer S, Tawfik NH, et al. A novel targeted T-cell modulator, efalizumab, for plaque psoriasis. N Engl J Med 2003; 349:2004-13.
33. Carson KR, Evens AM, Richey EA, Habermann TM, Focosi D, Seymour JF, et al. Progressive multifocal leukoencephalopathy after rituximab therapy in HIV-negative patients: a report of 57 cases from the Research on Adverse Drug Events and Reports project. Blood 2009; 113:4834-40.
34. Hauser SL, Waubant E, Arnold DL, Vollmer T, Antel J, Fox RJ, et al. B-cell depletion with rituximab in relapsing-remitting multiple sclerosis. N Engl J Med 2008; 358:676-88.
35. Cree BA, Lamb S, Morgan K, Chen A, Waubant E, Genain C. An open label study of the effects of rituximab in neuromyelitis optica. Neurology 2005; 64:1270-2.
36. Garcia-Suarez J, de Miguel D, Krsnik I, Banas H, Arribas I, Burgaleta C. Changes in the natural history of progressive multifocal leukoencephalopathy in HIV-negative lymphoproliferative disorders: impact of novel therapies. Am J Hematol 2005; 80:271-81.
37. Molloy ES, Calabrese LH. Progressive multifocal leukoencephalopathy in patients with rheumatic diseases: are patients with systemic lupus erythematosus at particular risk? Autoimmun Rev 2008; 8:144-6.
38. Berger JR. Progressive multifocal leukoencephalopathy in acquired immunodeficiency syndrome: explaining the high incidence and disproportionate frequency of the illness relative to other immunosuppressive conditions. J Neurovirol 2003; 9:38-41.
39. Caldarelli-Stefano R, Vago L, Omodeo-Zorini E, Mediati M, Losciale L, Nebuloni M, et al. Detection and typing of JC virus in autopsy brains and extraneural organs of AIDS patients and non-immunocompromised individuals. J Neurovirol 1999; 5:125-33.

40. Houff SA, Major EO, Katz DA, Kufta CV, Sever JL, Pittaluga S, et al. Involvement of JC virus-infected mononuclear cells from the bone marrow and spleen in the pathogenesis of progressive multifocal leukoencephalopathy. N Engl J Med 1988; 318:301-5.
41. Major EO, Amemiya K, Elder G, Houff SA. Glial cells of the human developing brain and B-cells of the immune system share a common DNA binding factor for recognition of the regulatory sequences of the human polyomavirus, JCV. J Neurosci Res 1990; 27:461-71.
42. Atwood W, Amemiya K, Traub R, Harms J, Major E. Interactions of the human polyomavirus, JCV, with human B lymphocytes. Virology 1992; 190:716-23.
43. Monaco MC, Atwood WJ, Gravell M, Tornatore CS, Major EO. JC virus infection of hematopoietic progenitor cells, primary B lymphocytes, and tonsillar stromal cells: implications for viral latency. J Virol 1996; 70:7004-12.
44. Houff SA, Berger JR. The bone marrow, B-cells and JC virus. J Neurovirol 2008; 14:341-3.
45. Marzocchetti A, Wuthrich C, Tan CS, Tompkins T, Bernal-Cano F, Bhargava P, et al. Rearrangement of the JC virus regulatory region sequence in the bone marrow of a patient with rheumatoid arthritis and progressive multifocal leukoencephalopathy. J Neurovirol 2008; 14:455-8.
46. Sunyaev SR, Lugovskoy A, Simon K, Gorelik L. Adaptive mutations in the JC virus protein capsid are associated with progressive multifocal leukoencephalopathy (PML). PLoS Genet 2009; 5:1000368.
47. Weber T, Weber F, Petry H, Luke W. Immune response in progressive multifocal leukoencephalopathy: an overview. J Neurovirol 2001; 7:311-7.
48. Berger JR, Scott G, Albrecht J, Belman AL, Tornatore C, Major EO. Progressive multifocal leukoencephalopathy in HIV-1-infected children. Aids 1992; 6:837-41.
49. Andréoletti L, Lescieux A, Lambert V, Si-Mohamed A, Matta M, Wattré P, et al. Semiquantitative detection of JCV-DNA in peripheral blood leukocytes from HIV-1-infected patients with or without progressive multifocal leukoencephalopathy. J Med Virol 2002; 66:1-7.
50. Tornatore C, Berger J, Winfield D, LaVoie L, Major E. Detection of JC viral genome in the lymphocytes of non-PML HIV positive patients: association with B-cell lymphopenia. Neurology 1992; 42:211.
51. Fedele CG, Ciardi MR, Delia S, Contreras G, Perez JL, De Oña M, et al. Identical rearranged forms of JC polyomavirus transcriptional control region in plasma and cerebrospinal fluid of acquired immunodeficiency syndrome patients with progressive multifocal leukoencephalopathy. J Neurovirol 2003; 9:551-8.
52. Andréoletti L, Dubois V, Lescieux A, Dewilde A, Bocket L, Fleury HJ, et al. Human polyomavirus JC latency and reactivation status in blood of HIV-1-positive immunocompromised patients with and without progressive multifocal leukoencephalopathy. Aids 1999; 13:1469-75.
53. Berger JR, Pall L, Lanska D, Whiteman M. Progressive multifocal leukoencephalopathy in patients with HIV infection. J Neurovirol 1998; 4:59-68.
54. Berenguer J, Miralles P, Arrizabalaga J, Ribera E, Dronda F, Baraia-Etxaburu J, et al. Clinical course and prognostic factors of progressive multifocal leukoencephalopathy in patients treated with highly active antiretroviral therapy. Clin Infect Dis 2003; 36:1047-52.
55. Berger JR, Tornatore C, Major EO, Bruce J, Shapshak P, Yoshioka M, et al. Relapsing and remitting human immunodeficiency virus-associated leukoencephalomyelopathy. Ann Neurol 1992; 31:34-8.
56. Du Pasquier RA, Clark KW, Smith PS, Joseph JT, Mazullo JM, De Girolami U, et al. JCV-specific cellular immune response correlates with a favorable clinical outcome in HIV-infected individuals with progressive multifocal leukoencephalopathy. J Neurovirol 2001; 7:318-22.
57. Du Pasquier RA, Kuroda MJ, Zheng Y, Jean-Jacques J, Letvin NL, Koralnik IJ. A prospective study demonstrates an association between JC virus-specific cytotoxic T lymphocytes and the early control of progressive multifocal leukoencephalopathy. Brain 2004; 127:1970-8.
58. Cinque P, Pierotti C, Viganò MG, Bestetti A, Fausti C, Bertelli D, et al. The good and evil of HAART in HIV-related progressive multifocal leukoencephalopathy. J Neurovirol 2001; 7:358-63.
59. Evans AS. Hypothesis: the pathogenesis of AIDS. Activation of the T- and B-cell cascades. Yale J Biol Med 1984; 57:317-27.
60. Epeldegui M, Widney DP, Martinez-Maza O. Pathogenesis of AIDS lymphoma: role of oncogenic viruses and B-cell activation-associated molecular lesions. Curr Opin Oncol 2006; 18:444-8.
61. Krumbholz M, Meinl I, Kumpfel T, Hohlfeld R, Meinl E. Natalizumab disproportionately increases circulating pre-B and B-cells in multiple sclerosis. Neurology 2008; 71:1350-4.
62. Lindberg RL, Achtnichts L, Hoffmann F, Kuhle J, Kappos L. Natalizumab alters transcriptional expression profiles of blood cell subpopulations of multiple sclerosis patients. J Neuroimmunol 2008; 194:153-64.
63. Yao K, Gagnon S, Akhyani N, Williams E, Fotheringham J, Frohman E, et al. Reactivation of human herpesvirus-6 in natalizumab treated multiple sclerosis patients. PLoS ONE 2008; 3:2028.
64. Du Pasquier RA, Schmitz JE, Jean-Jacques J, Zheng Y, Gordon J, Khalili K, et al. Detection of JC virus-specific cytotoxic T lymphocytes in healthy individuals. J Virol 2004; 78:10206-10.
65. Marzocchetti A, Lima M, Tompkins T, Kavanagh DG, Gandhi RT, O'Neill DW, et al. Efficient in vitro expansion of JC virus-specific CD8(+) T-cell responses by JCV peptide-stimulated dendritic cells from patients with progressive multifocal leukoencephalopathy. Virology 2009; 383:173-7.
66. del Pilar Martin M, Cravens PD, Winger R, Frohman EM, Racke MK, Eagar TN, et al. Decrease in the numbers of dendritic cells and $CD4^+$ T-cells in cerebral perivascular spaces due to natalizumab. Arch Neurol 2008; 65:1596-603.
67. Ko HH, Bressler B. Natalizumab: pharmacology, clinical efficacy and safety in the treatment of patients with Crohn's disease. Expert Rev Gastroenterol Hepatol 2007; 1:29-39.
68. Jullien D, Prinz JC, Langley RG, Caro I, Dummer W, Joshi A, et al. T-cell modulation for the treatment of chronic plaque psoriasis with efalizumab (Raptiva): mechanisms of action. Dermatology 2004; 208:297-306.
69. Papp KA. Efalizumab: Advancing psoriasis management with a novel, targeted T-cell modulator. Drugs Today (Barc) 2004; 40:889-99.
70. Capsoni F, Ongari AM, Frigerio E, Taglioni M, Altomare GF. Effect of Efalizumab on neutrophil and monocyte functions in patients with psoriasis. Int J Immunopathol Pharmacol 2008; 21:437-45.
71. Lowes MA, Chamian F, Abello MV, Fuentes-Duculan J, Lin SL, Nussbaum R, et al. Increase in TNFalpha and inducible nitric oxide synthase-expressing dendritic cells in psoriasis and reduction with efalizumab (anti-CD11a). Proc Natl Acad Sci USA 2005; 102:19057-62.
72. Cree B. Emerging monoclonal antibody therapies for multiple sclerosis. Neurologist 2006; 12:171-8.
73. Anolik JH, Friedberg JW, Zheng B, Barnard J, Owen T, Cushing E, et al. B-cell reconstitution after rituximab treatment of lymphoma recapitulates B-cell ontogeny. Clin Immunol 2007; 122:139-45.
74. Corti P, Peters C, Balduzzi A, Bertagnolio B, Biondi A, Bugarin C, et al. Reconstitution of lymphocyte subpopulations in children with inherited metabolic storage diseases after haematopoietic cell transplantation. Br J Haematol 2005; 130:249-55.
75. Leandro MJ, Cambridge G, Ehrenstein MR, Edwards JC. Reconstitution of peripheral blood B-cells after depletion with rituximab in patients with rheumatoid arthritis. Arthritis Rheum 2006; 54:613-20.
76. Cross AH, Stark JL, Lauber J, Ramsbottom MJ, Lyons JA. Rituximab reduces B-cells and T-cells in cerebrospinal fluid of multiple sclerosis patients. J Neuroimmunol 2006; 180:63-70.
77. Ginaldi L, De Martinis M, Matutes E, Farahat N, Morilla R, Catovsky D. Levels of expression of CD52 in normal and leukemic B and T-cells: correlation with in vivo therapeutic responses to Campath-1H. Leuk Res 1998; 22:185-91.
78. Castillo J, Winer E, Quesenberry P. Newer monoclonal antibodies for hematological malignancies. Exp Hematol 2008; 36:755-68.
79. Jones JL, Coles AJ. Campath-1H treatment of multiple sclerosis. Neurodegener Dis 2008; 5:27-31.
80. Coles A, Deans J, Compston A. Campath-1H treatment of multiple sclerosis: lessons from the bedside for the bench. Clin Neurol Neurosurg 2004; 106:270-4.
81. Martin SI, Marty FM, Fiumara K, Treon SP, Gribben JG, Baden LR. Infectious complications associated with alemtuzumab use for lymphoproliferative disorders. Clin Infect Dis 2006; 43:16-24.
82. Gallamini A, Zaja F, Patti C, et al. Alemtuzumab (Campath-1H) and CHOP chemotherapy as first-line treatment of peripheral T-cell lymphoma: results of a GITIL (Gruppo Italiano Terapie Innovative nei Linfomi) prospective multicenter trial. Blood 2007; 110:2316-23.
83. Waggoner J, Martinu T, Palmer SM. Progressive multifocal leukoencephalopathy following heightened immunosuppression after lung transplant. J Heart Lung Transplant 2009; 28:395-8.
84. Ravandi F, O'Brien S. Alemtuzumab in CLL and other lymphoid neoplasms. Cancer Invest 2006; 24:718-25.
85. Jensen PN, Major EO. A classification scheme for human polyomavirus JCV variants based on the nucleotide sequence of the noncoding regulatory region. J Neurovirol 2001; 7:280-7.