PRELIMINARY NOTE ON THE EXPERIMENTAL STUDY OF ENZOOTIC ENCEPHALO-MYELITIS (BORNA DISEASE).

S. NICOLAU, M.D., D.Sc.,

Pasteur Institute, Paris,

AND

I. A. GALLOWAY, B.Sc., M.R.C.V.S.

From the Department of Pathology and Bacteriology of the National Institute for Medical Research, Hampstead, London.

Received for publication July 19th, 1927.

ENCEPHALO-MYELITIS has long been recognized as a specific infection of the horse under the name of Borna disease, but the ætiology has remained undetermined until recent years. The work of Moussu (1924), Zwick and Seifried (1924, 1926), Beck and Frohböse (1926) and Ernst and Hahn (1927) shows that the ætiological factor belongs to the group of filterable viruses, and is transmissible in series by intracerebral inoculation of the horse, sheep, rabbit, guinea-pig, rat and fowl; in addition, Beck and Frohböse, Moussu, and Miessner (1926) demonstrate that enzootic encephalo-myelitis of the sheep is produced by a virus which is analogous. Finally, Ernst and Hahn have succeeded in isolating from cases of enzootic encephalo-myelitis of cattle and from malignant catarrhal fever of the same species strains of virus which are very closely related to, if not identical with, those isolated previously from cases of Borna disease in the horse. These last authors are of the opinion also that deer become spontaneously infected with the same virus. The question of the comparison of different strains will be discussed later in our complete memoir. It is sufficient to say at present that we are led to believe from certain experimental data that, contrary to the opinion of Arndt (1926), and of Zwick, Seifried and Witte, the virus isolated by Moussu in France in various epizootics among horses and sheep is a more virulent strain of the same virus as that studied by German workers.

In the present preliminary note, the results are given of experiments undertaken with a strain of virus isolated by Zwick and his collaborators from horses, and with another isolated by Miessner from sheep.

The animal which is, apparently, most susceptible to infection experimentally with the pathogenic agent is the rabbit.

I.—*Certain properties of the virus.*—(1) After centrifugalization for 5 or even 15 minutes at a speed of 5400 revs. per min. the superficial layers are still found to be virulent. (2) The virus is sensitive to the action of ultra-violet rays; after 5 minutes' exposure in quartz flasks the virus is rendered inactive.

II.—*Experimental study in the rabbit.*—(1) First of all it should be

mentioned that all our experiments up to the present go to prove that the two strains studied, *i. e.* the strain isolated from horses (Zwick) and the strain isolated from sheep (Miessner), are identical. *Cross-immunity* experiments show that a rabbit immunized by intracerebral inoculation against the first of these two strains resists some thousand infective doses of the second strain inoculated by the same route. (2) Over 200 rabbits have been infected during the course of our experiments. The symptomatology of the experimental disease in the rabbit is characteristic of an encephalo-myelitis, which may finally result in general paralysis.

The period of incubation and the duration of the disease varies according to the individual susceptibility. The weight, that is to say, the age of the animal, appears to be the sole factor, having a marked influence upon such variation in receptivity. The average time elapsing between the date of infection by inoculation intracerebrally and the subsequent death of the animal in the case of the strain of Zwick has been 28 days in rabbits weighing less than 1500 gm. (observations made on 25 rabbits), and 36 days in rabbits weighing more than 1500 gm. (observations made also on 25 rabbits).

In the case of the Miessner strain of virus in 12 rabbits infected by intracerebral inoculation, death supervened on an average in 30 days. A fuller description of the clinical symptoms as well as the table which furnished us with these figures will be given in detail in the complete memoir.

A feature of capital importance is the loss of weight which takes place in infected animals, which may be as much as half of the original weight of the animal inoculated.

The temperature of experimental animals is uninfluenced by infection with the virus, although it becomes subnormal during the period preceding death. The changes in the blood as demonstrated by counts are inconstant, but the leucocytic formula shows that the number of mononuclear lymphocytes is markedly increased during the course of the infection. (3) According to Zwick and Moussu, the introduction of a few drops of emulsion of virulent brain into the *sciatic nerve* fails to lead to successful infection of the rabbit. In our experiments we have succeeded, however, in producing the typical disease several times in animals infected by this route. The first symptom noticed was paralysis of the leg supplied by the nerve into which the virus had been introduced. Following upon this, the typical syndrome developed. Characteristic lesions were found in the brain, spinal cord, roots of the peripheral nerves, the spinal ganglia as well as in the nerve inoculated. The presence of the virus in the central nervous system of rabbits infected by intrasciatic inoculation was determined by inoculating fresh animals intracerebrally with emulsions of their brains and spinal cords. (4) *Intratesticular inoculation* gave results similar to those obtained by intrasciatic inoculation. It was shown also that the brain and spinal cord of animals so infected contained virus, since fresh animals inoculated intracerebrally with emulsions of the central nervous system (brain and spinal cord) died from encephalo-myelitis after showing the usual typical symptoms. (5) *Intra-ocular* inoculation (anterior chamber), *corneal* scarification and *intravenous* inoculation do not give constant results. (6) The introduction of a thick virulent emulsion into the *trachea* of rabbits gave negative results (6 animals in 2 series of experiments). (7) Animals infected

by scarification of the previously depilated and shaved *skin* did not develop the disease. However, when the precaution was taken of previously irritating the brain by inoculation of sterile saline intracerebrally, the virus, travelling probably by the intercostal nerves, reached the central nervous system and produced the characteristic disease.

Inoculation of saline into the spinal cord of rabbits previously infected by scarification of the skin did not lead to localization of the virus in the central nervous system.

III.—(1) Our findings with regard to the transmission of the disease to *guinea-pigs* are in accordance with the results obtained by the German school. The period of incubation in this species of animal is still more markedly variable than in the case of the rabbit after intracerebral inoculation. After infection by this route guinea-pigs died after showing typical symptoms in anything from 19 to 130 days (the longest period yet observed by us). With the object of having a more general idea of the susceptibility of guinea-pigs to the virus, we inoculated 45 guinea-pigs, which were divided into three lots of 15. The first lot received intracerebrally a virulent emulsion diluted 1/10, the second a dilution of 1/100, and the third a dilution of 1/1000. The results were paradoxical. During the first 110 days which followed infection, the animals inoculated with a dilution of 1/1000 furnished the largest number of positive takes, which suggests that the sensitiveness of the guinea-pigs to the virus of encephalo-myelitis is very variable. (2) Attempts at infecting guinea-pigs by intradermal inoculation of the virus into the metatarsal region, employing the technique used originally in foot and mouth disease by Waldmann and Pape, and in experimental herpes by Gildemeister and Herzberg, gave negative results.

IV.—The virus of Borna is definitely pathogenic for the *rat*. We have inoculated in all 28 rats intracerebrally. The period of incubation and the symptomatology are exactly as in the guinea-pig. A fact worthy of special note, however, is that *old rats are much more susceptible than young ones.* In general, small animals of this species have resisted infection in our experience, while old animals have developed the typical disease.

V.—Mice infected by intracerebral inoculation may present symptoms characteristic of the disease ending in death, but they are more resistant to infection than guinea-pigs and rats. In this case also the older animals appeared more sensitive to the pathogenic action of the virus. Death took place 37, 52, 81, 125 days after infection respectively in our experiments.

VI.—Virus passaged through guinea-pigs or rats still retained its virulence for the rabbit. This is in accordance with the findings of Zwick. A fact of special interest, however, is that our rabbits inoculated with virus after passage through rats or guinea-pigs developed the disease after a shorter period of incubation (death in 19 to 21 days). These rabbits exhibited lesions which were excessively intense and characteristic in type.

VII.—(1) We have succeeded in conferring enzootic encephalo-myelitis to *monkeys.* A *Macacus rhesus* weighing 3800 gm. was inoculated intracerebrally with a virus of rabbit passage. The first symptoms of the disease developed 57 days afterwards. Paresis and paralysis supervened, and the animal died 16 days after the onset of symptoms, *i. e.* 73 days after infection. The

symptomatology was that of a typical poliomyelitic infection with an ascending paralysis (type Landry).

Rabbits were inoculated intracerebrally with emulsions from the various organs of the monkey with the object of determining the absence or presence of virus. The virus could only be found in those organs derived from the *ectoderm* (cerebrum, medulla, spinal cord, adrenal* and parotid*).

(2) The virus can be transmitted from monkey to monkey by intracerebral inoculation.

(3) Cross-immunity experiments with the virus of poliomyelitis are being carried out.

VIII.—The *ferret* appears refractory to intracerebral infection with Borna virus.

IX.—*Pathological histology of experimental enzootic encephalo-myelitis.*—(1) *Rabbit.*—Up to the present the various authors have confined their attention strictly to the central nervous system (brain and spinal cord) in studying the pathological history of Borna.

The lesions described are mononuclear meningitis, perivascular and parenchymatous infiltration, always of a mononuclear type, with, in addition, the oxyphilic corpuscles in the large ganglion cells of the *cornu ammonis* described by Joest and Degen in the horse many years ago. We have studied minutely the alterations *throughout* the nervous system, and the conclusions resulting from our experiments, which will be published in full later, include the following :

In the rabbit, inoculation of the virus of Borna disease intracerebrally produces lesions of a typical encephalo-myelitis, to which are added profound changes of the spinal ganglia and peripheral nerves (*encephalo-myelitis, ganglio-radiculitis and a peripheral neuritis*). In the central nervous system as well as the spinal ganglia histological modifications are of two orders—*infiltrative* and *degenerative.*

The meningitis and the parenchymatous and perivascular infiltrations are produced always by mononuclear cells. A lesion which we have noted constantly is that termed by us "*satellitism*" of the neuron (surrounding of the neuron by neuroglial cells and infiltrating mononuclears). This last modification of the normal structure of the nerve-tissue is more marked in the medulla oblongata, mid-brain and the spinal ganglia, but may exist throughout the central nervous system.

Sometimes this "*satellitism*" may go so far as to constitute true *neuronophagia.*

Various stages and forms of *degeneration* of the nerve-cells are also met with—oxychromasia, chromatolysis, karyolysis, vacuolization of the cytoplasm which may show a denticulated border.

In the spinal cord, apart from the infiltrative lesions which predominate in the posterior horns, degenerative lesions of the nerve-cells may also be seen in the anterior horns. *Neuronophagia* is sometimes met with in the latter region.

In the *paravertebral ganglia* neuronophagia is much more frequent than in

* It is known that the medullary zone of the adrenal is derived from the ectoderm and that the parotid contains nerve-cells.

the central nervous system proper, and is comparable to that seen in experimental poliomyelitis of monkeys (disease of Heine-Medin).

The lesion of the *nerve-roots* and those of the *descending peripheral nerves* (sciatic nerve of animals inoculated into the brain) are produced by mononuclear cells, and present themselves as *interstitial* and *perivascular* infiltrations.

It is interesting to associate this peripheral neuritis obtained after central infection with the virus of Borna with the pathological process met with in zona zoster, "l'herpes recidivant," and perhaps also so-called "contagious sciatica," of which the ætiology is still unknown. It is possible that these latter conditions are external, secondary and descending manifestations of the respective viruses (which probably belong to the same group as the virus of Borna). The viruses concerned possibly descend from the central nervous system to the peripheral nerves centrifugally.

The possibility of centripetal ascending infection in these diseases must, however, not be excluded.

The corpuscles of Joest-Degen, intranuclear oxyphilic formations, appear to result from a condensation of the chromatin, which has become oxyphilic, possibly around the infectious agent. The cells which contain them present a marked rarification of the karyoplasm. It should be remarked that apart from this chromatic rarification, the cells with these corpuscles preserve their morphological and tinctorial integrity. Such corpuscles are never met with in degenerated cells or those undergoing degeneration. In rabies the same thing has been recorded. Negri bodies are seen only in cells which otherwise conserve their normal aspect.

We have found the corpuscles of Joest-Degen not only in the large ganglion cells of the *cornu ammonis*, but also in the pyramidal cells of the cerebrum, in the medulla oblongata, in the anterior horns of the spinal cord, and especially in the nerve-cells of the spinal ganglia.

It is perhaps worthy of note also that in the large ganglion cells of the *cornu ammonis* we have observed certain formations resembling so-called "cysts" in the cytoplasm in about 5% of cases. Their staining properties show that they are the degenerated nuclei of infiltrating mononuclear cells which have succeeded in penetrating the neuron.

(2) In the *guinea-pig* and the *rat* the alterations of the nervous system are on the whole comparable to those mentioned summarily in the case of the rabbit; the nerve-roots as well as the spinal ganglia show the same lesions as there described.

The sciatic nerve of infected guinea-pigs shows the same lesions as in the rabbit.

The corpuscles of the type described by Joest and Degen have been seen in the brain, spinal cord, and more especially in the spinal ganglia of infected guinea-pigs. These corpuscles also were found in the brain of rats.

(3) The lesions of the brain of the *mouse* infected by the intra-cerebral route have the same characters as in the aforementioned animals. Intranuclear corpuscles have also been demonstrated in the ganglion cells of the *cornu ammonis* of mice.

(4) In the *monkey* the whole nervous system is infected by lesions characteristic of an *encephalo-myelitis* with a *ganglio-radiculitis* and superadded *peripheral neuritis*.

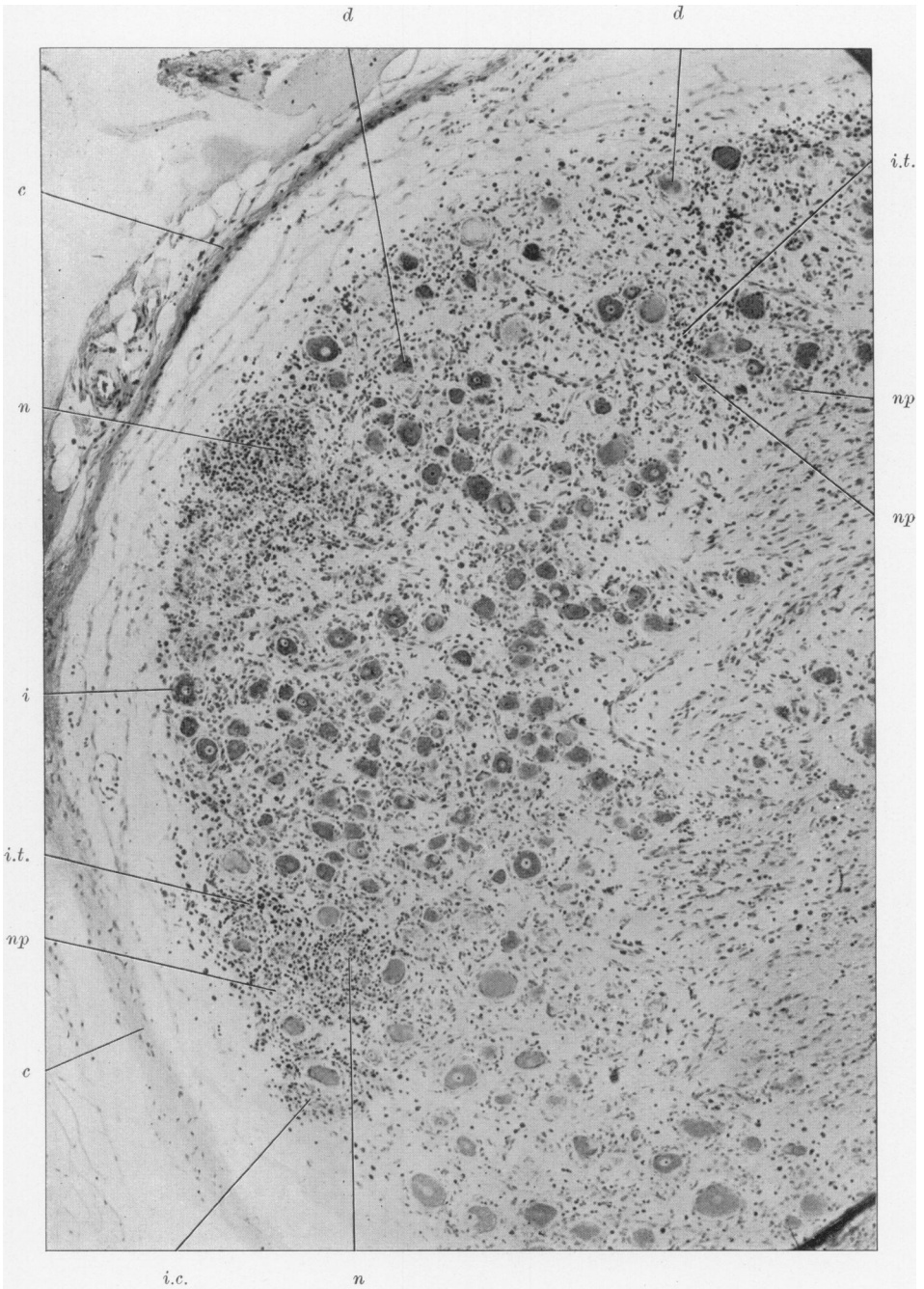

Fig. 4.

Nicolau and Galloway.

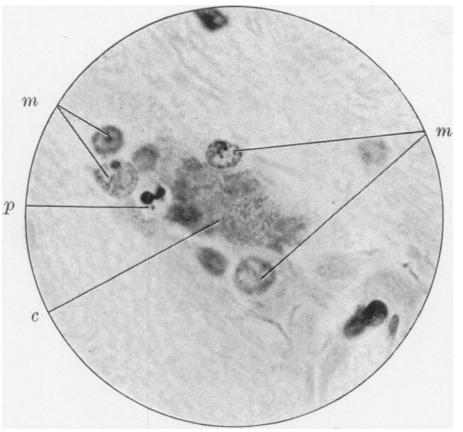

FIG. 2.

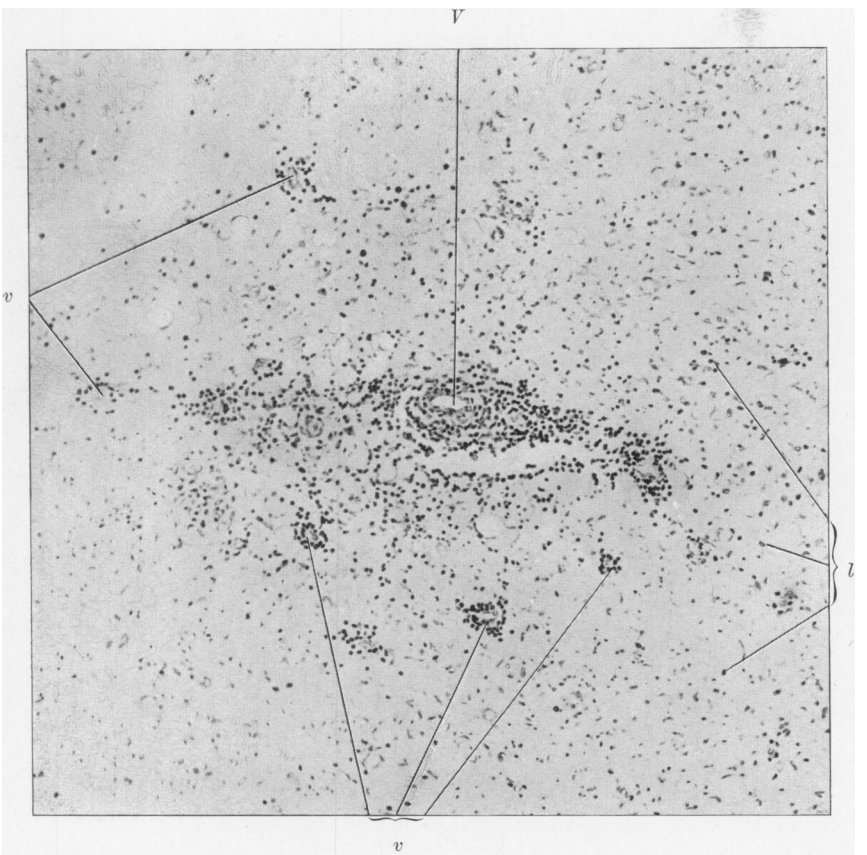

FIG. 3.

Nicolau and Galloway.

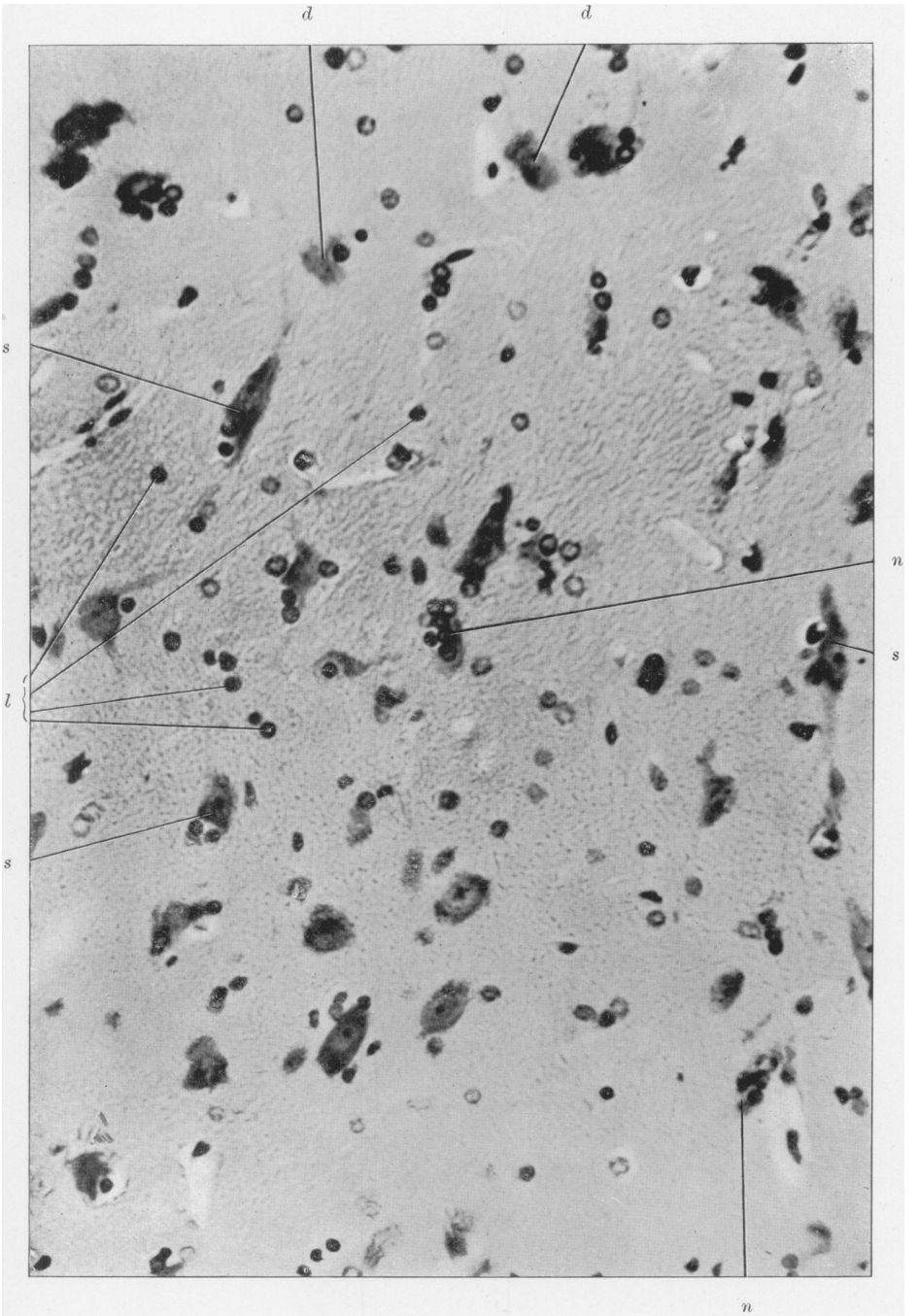

Fig. 1.

Nicolau and Galloway.

Neuronophagia is met with most frequently in the spinal ganglia. The details of all these lesions will be given in our monograph.

We have found typical oxyphilic corpuscles in nearly all sites of the nervous system (frontal, parietal and occipital lobes, hippocampus, optic thalamus, *cornu ammonis*, pons, medulla, cerebellum, cervical, thoracic and sacro-caudal parts of the spinal cord), but the finest and most frequent have been found in the spinal ganglia.

X.—(1) One can confer a durable immunity upon rabbits by intra-cerebral inoculation of a suitably attenuated virus. According to our experiments such immunity may last at least 160 days.

(2) The strain of encephalo-myelitis virus isolated from the horse infected with Borna (Zwick strain) suitably attenuated renders rabbits resistant to the intra-cerebral inoculation with the virus isolated from the brain of sheep (Miessner strain).

(3) Rabbits hyper-immunized against herpes by intra-cerebral inoculation are still susceptible to infection with the virus of Borna introduced by the same route.

We beg to thank the Medical Research Council for putting at our disposal all the material necessary for carrying out this research, and especially Capt. S. R. Douglas, Director of the Department of Pathology, for enabling us to bring this work to a successful conclusion. We also thank Prof. Zwick and Prof. Miessner, who kindly put their viruses at our disposal

REFERENCES.

ARNDT, H. J.—(1926) *Ztschr. f. Infektionsk. d. Haustiere*, **29**, 184.
BECK, A., AND FROHBÖSE H.—(1926) *Arch. f. wissensch. u. prakt. Tierhk.*, **54**, 84.
ERNST AND HAHN.—(1927) *München. tierärztl. Wchnschr.*, No. 6, February.
MIESSNER, H.—(1926) *Deutsche tierärztl. Wchnschr.*, **34**, 637.
MOUSSU, R.—(1924) Several notes published alone or in collaboration with L. Marchand. *Vide* "L'encéphalite enzootique des animaux domestiques." Paris (Vigot frères).
ZWICK, W., AND SEIFRIED, O.—(1924) *Berl. tierärztl. Wchnschr.*, **40**, 465.
ZWICK, W., SEIFRIED, O., AND WITTE, J.—(1926) *Ztschr. f. Infektionsk. d. Haustiere*, **30**, 42.

DESCRIPTION OF PLATES. (MICROPHOTOGRAPHS).

FIG. 1.—Rabbit infected by intra-cerebral inoculation. Section in the region of the pons showing—(*d*) degenerated nerve-cells; (*s*) "satellitism" with commencing neuronophagia; (*n*) neuronophagia; (*l*) lymphocytes in the parenchyma. × 230 (photo enlarged 2 diameters).

FIG. 2.—Rabbit infected by intra-cerebral inoculation. Nerve-cell showing neuronophagia in medulla oblongata. (*c*) Degenerated cytoplasm; (*p*) polynuclear penetrating neuron; (*m*) monocytes. × 1000.

FIG. 3.—Monkey infected by intra-cerebral inoculation. Transverse section from sciatic nerve after leaving obturator foramen. (*V*) Large vessel with perivascular infiltration; (*v*) small vessels showing same phenomena; (*l*) lymphocytes (interstitial infiltration). × 55 (photo enlarged 2½ diameters).

FIG. 4.—Monkey infected by intra-cerebral inoculation. Section of spinal ganglion in lumbar region of spinal cord showing the profound changes which predominate the peripheral parts of the nervous system. (*i*) Intra-nuclear corpuscle (Joest-Degen) with surrounding halo; (*n*) nodule of monocytes replacing destroyed neurons; (*d*) degenerated ganglion cells; (*np*) neuronophagia; (*i.c.*) Pericellular infiltration; (*i.t.*) interstitial infiltration; (*c*) capsule of ganglion. × 36 (photo enlarged 2½ diameters).