TURKISH JOURNAL OF EMERGENCY MEDICINE

Case Report

Access this article online
Quick Response Code:

Website: www.turkjemergmed.com

DOI: 10.4103/2452-2473.342809

Defective barcode sign – A newer sonographic sign in hydropneumothorax

Sasikumar Mahalingam*, Gunaseelan Rajendran, Anuusha Sadasivam, Manu Ayyan, Vivekanandan Muthu Pillai

Department of Emergency Medicine, Jawaharlal Institute of Postgraduate Medical Education and Research, Puducherry, India
**Corresponding author*

Abstract:

Effusive pneumothorax can be hemopneumothorax, pyopneumothorax, or hydropneumothorax depending on the type of fluid compartment within the pleural cavity. Hydropneumothorax is the abnormal collection of air and serous fluid within the pleural cavity. Here, we report a case of a 34-year-old male who presented to the emergency department with cough and breathlessness. We did bedside point-of-care ultrasound-assisted clinical evaluation as the patient was vitally unstable, which showed "hydro point" and "defective barcode sign," which suggested hydropneumothorax. We present these clinical evaluation details, imaging/sonographic findings, and patient management in this case report.

Keywords:

Defective barcode sign, diagnostic Ultrasound, hydro point, hydropneumothorax, point-of-care ultrasound

Introduction

Sonographic evaluation of various respiratory emergencies such as pneumothorax, pleural effusion, pneumonia, and pulmonary edema can be done at the bedside as they have clear diagnostic ultrasound findings. Hydropneumothorax may be an exception among them, as they lack sensitive and specific diagnostic ultrasound findings. The various causes of hydropneumothorax are tuberculosis, necrotizing bacterial pneumonia, bronchopleural fistula, esophagopleural fistula, prior lung surgery, iatrogenic causes, etc.[1] Hydropneumothorax is one of the common respiratory emergencies encountered in India due to the high prevalence of tuberculosis. Here, we discuss the newer sonographic signs of hydropneumothorax, namely hydro point and defective barcode sign which need further research studies to assess its diagnostic accuracy.

Case Report

A 34-year-old male came to our emergency department with a history of cough with expectoration for 2 months and breathlessness for 10 days. He also gave the history of right-sided chest pain, loss of weight, and loss of appetite. No other significant history was present. The patient's vitals were pulse rate of 110/min, blood pressure of 120/80mmhg, respiratory rate of 28/min, and oxygen saturation of 90% in room air. Respiratory examination showed absent right-sided air entry and crepitation in the left lung mammary area. Other systemic examinations were unremarkable.

Submitted: 22-10-2021
Revised: 21-12-2021
Accepted: 26-12-2021
Published: 11-04-2022

ORCID:
SM: 0000-0002-6681-8388
GR: 0000-0002-1280-209X
AS: 0000-0003-2766-7991
MA: 0000-0002-2541-5769
VMP: 0000-0002-7810-5369

Address for correspondence:
Dr. Sasikumar Mahalingam, No 9, Vaigai Street, Vallalar Nagar, Nainarmandabam, Pondicherry - 605 004, India.
E-mail: sasiempub@gmail.com

This is an open access journal, and articles are distributed under the terms of the Creative Commons Attribution-NonCommercial-ShareAlike 4.0 License, which allows others to remix, tweak, and build upon the work non-commercially, as long as appropriate credit is given and the new creations are licensed under the identical terms.

For reprints contact: WKHLRPMedknow_reprints@wolterskluwer.com

How to cite this article: Mahalingam S, Rajendran G, Sadasivam A, Ayyan M, Pillai VM. Defective barcode sign – A newer sonographic sign in hydropneumothorax. Turk J Emerg Med 2022;22:108-10.

© 2022 Turkish Journal of Emergency Medicine | Published by Wolters Kluwer - Medknow

Point-of-care ultrasound (POCUS) of the Right lung with high-frequency linear probe showed features of both pneumothorax and hydrothorax. When screened in caudocranial direction at the sitting position, the right lung showed a characteristic transition zone of hydrothorax to pneumothorax called "Hydro point" [Figure 1]. When M-mode was applied at this transition zone, it showed a peculiar sonographic pattern, which we named as "Defective barcode sign" [Figure 2]. Thus, "hydro point" and the newer "defective barcode sign" can help the treating physician confirm hydropneumothorax at the bedside in unstable patients. With oxygen support, the patient was symptomatically better, hence shifted for chest X-ray, which also confirmed hydropneumothorax [Figure 3]. The patient was treated with low-flow oxygen, empirical antibiotics, and a right intercostal drainage tube in the emergency department. The patient was transferred to the intensive care unit and started on antitubercular drugs, and targeted antibiotics based on sputum acid-fast bacilli smear and pleural fluid culture. Although the patient was improving initially, he succumbed due to severe sepsis. We obtained written informed consent from the patient's wife.

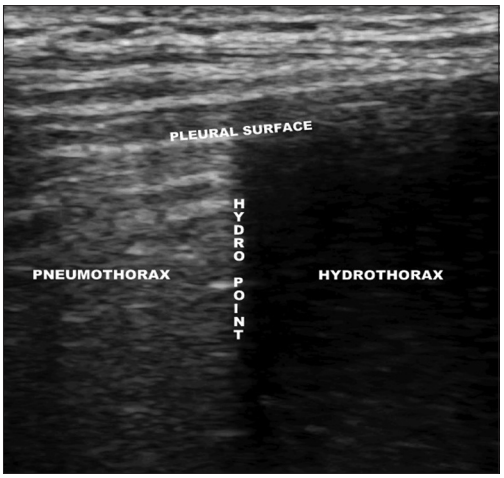

Figure 1: Hydro point in right-sided lung suggestive of hydropneumothorax

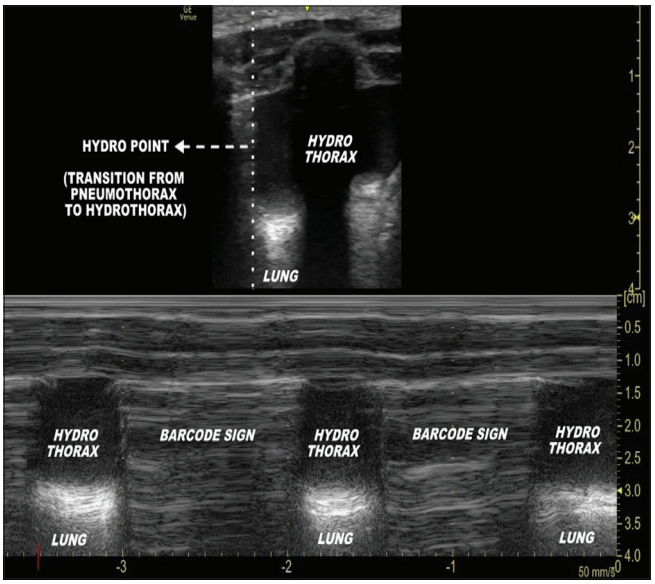

Figure 2: Defective barcode sign – M-mode feature of hydropneumothorax using the high-frequency linear probe in the right lung

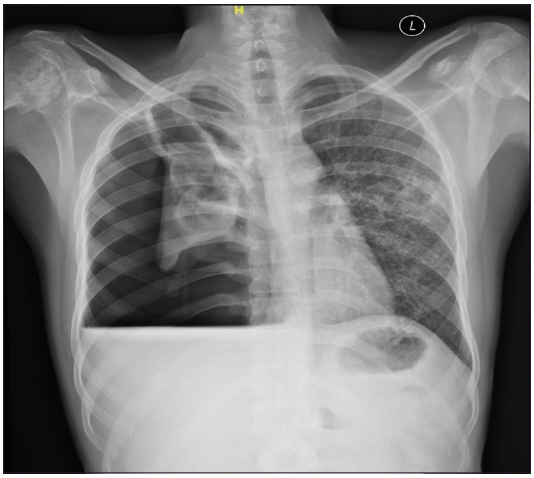

Figure 3: Chest X-ray showing the right-sided hydropneumothorax and left-sided mid-zone infiltrates

Discussion

Hydropneumothorax is one of the common respiratory emergencies encountered in the emergency department in India. Various causes of hydropneumothorax are tuberculosis, necrotizing pneumonia, malignancy, pleural fistula, iatrogenic causes, connective tissue disorders, cystic lung disease, etc., Diaphragmatic eventration, diaphragmatic hernia, and giant bronchogenic cyst have been reported to mimic hydropneumothorax.[2] Differentiating hydropneumothorax and pneumothorax is crucial as infections may be a contributing factor for hydropneumothorax. Differentiating these two in unstable patients may not be easy, as these patients cannot be shifted for a chest X-ray. POCUS plays a significant role in this situation for differentiating unstable hydropneumothorax from pneumothorax.

POCUS has become a popular game-changer in the field of emergency medicine and expanding exponentially beyond boundaries. Attention to the fluid characteristic in ultrasound can give a clue to the type of effusive pneumothorax. The echotexture of the fluid compartment can be anechoic, echogenic, or with multiple microbubbles, which may denote hydropneumothorax, hemopneumothorax, and pyopneumothorax, respectively. The sonographic accuracy of diagnosing pneumothorax and pleural effusion when occurring in isolation is very high. When hydrothorax and pneumothorax coincide within the pleural cavity, they produce a characteristic

air–fluid interface pattern called "hydro point."[3,4] The sonographic dynamicity of hydro point is called dynamic air–fluid interface sign.[5] The severity of hydropneumothorax can be assessed sonographically using hydro point location. When the lung is screened anteroposteriorly in the supine position, if the hydro point is more anterior, the effusion component is more than pneumothorax and vice versa.

Three sonographic components, namely barcode sign superior to the air–fluid interface in the nondependent zone, the hydro point at the air–fluid interface, and pleural effusion below the air–fluid interface in the dependent zone are seen in hydropneumothorax. This can be viewed by screening the lung from dependent zone to the nondependent zone using high-frequency linear probe. This sonographic sign of hydropneumothorax is called as "barcode – hydro point - effusion sign."[5]

Hydropneumothorax demonstrates air–fluid interface in chest radiography called as radiographic hydro point. A similar air–fluid interface can be seen in lung sonography called as "sonographic hydro point". These hydro points are basically the junction where the hydrothorax and pneumothorax meet. When M-mode is applied at this transition zone of hydro point, it produces a very characteristic novel M-mode pattern called "defective barcode sign". Defective barcode sign is a M-mode pattern with intermittent barcode sign (pneumothorax) and intermittent hypoechoic areas (hydrothorax) which occurs due to respirophasic motion of hydro point. This peculiar M-mode pattern of hydropneumothorax has not been reported till now in literature.

Another approach for sonographic confirmation of hydropneumothorax is sequential assessment of pneumothorax in each lung field (barcode sign), pleural effusion assessment in lower lung zones followed by their interface assessment (hydro point). Instead of checking these multiple sonographic components of hydropneumothorax, namely "barcode – hydro point - effusion sign," a simple M-mode along the hydro point can confirm the diagnosis of hydropneumothorax based on a "defective barcode sign." Thus, bedside POCUS can be used to confirm hydropneumothorax in unstable patients without the need for mobilizing the patient for chest X-rays. Hence, we felt reporting this newer sonographic finding can add value to the current literature.

Conclusion

"Defective barcode sign" is a newer M-mode sonographic sign of hydropneumothorax which has not been reported till now in literature. Acquiring "barcode – hydro point-effusion sign" in hydropneumothorax is often tedious and time consuming. Instead of checking these multiple sonographic components of hydropneumothorax, acquiring "hydro point" and a simple M-mode along the hydro point can confirm the diagnosis of hydropneumothorax based on "defective barcode sign". "Hydro point" and "Defective barcode sign" can help the treating physician confirm hydropneumothorax at the bedside in unstable patients without the need for mobilizing the patient for chest X-rays but requires further validation research studies.

Author contributions statement

CRediT author statement:

SM: Conceptualization, Resources, Visualization, Writing-original draft, Writing - Reviewing and Editing.

GR, AS: Resources, Writing, Reviewing.

MA, VMP: Writing – Extensive Review and Editing.

Conflicts of interest

None Declared.

Declaration of patient consent

Declaration of consent from patient's close relative: The authors certify that they have obtained all appropriate consent forms from the patient's wife. In the form, the patient's wife has given her consent for the images and other clinical information to be reported in the journal. The patient's wife understands that the patient's name and initials will not be published and due efforts will be made to conceal the identity, but anonymity cannot be guaranteed.

Funding

None.

References

1. Kasargod V, Awad NT. Clinical profile, etiology, and management of hydropneumothorax: An Indian experience. Lung India 2016;33:278-80.
2. Nations JA, Smith P, Parrish S, Browning R. Sonographic findings of hydropneumothorax. Ultrasound Q 2016;32:280-2.
3. Targhetta R, Bourgeois JM, Chavagneux R, Marty-Double C, Balmes P. Ultrasonographic approach to diagnosing hydropneumothorax. Chest 1992;101:931-4.
4. Volpicelli G, Boero E, Stefanone V, Storti E. Unusual new signs of pneumothorax at lung ultrasound. Crit Ultrasound J 2013;5:10.
5. Mahalingam S, Rajendran G, Nathan B, Kugan E, Sadasivam A. 'Hydro point' – The forgotten and unspoken entity in hydropneumothorax. Australas J Ultrasound Med 2021;24:246-8.