Since January 2020 Elsevier has created a COVID-19 resource centre with free information in English and Mandarin on the novel coronavirus COVID-19. The COVID-19 resource centre is hosted on Elsevier Connect, the company's public news and information website.

Elsevier hereby grants permission to make all its COVID-19-related research that is available on the COVID-19 resource centre - including this research content - immediately available in PubMed Central and other publicly funded repositories, such as the WHO COVID database with rights for unrestricted research re-use and analyses in any form or by any means with acknowledgement of the original source. These permissions are granted for free by Elsevier for as long as the COVID-19 resource centre remains active.

Travel Medicine and Infectious Disease 44 (2021) 102191

Contents lists available at ScienceDirect

Travel Medicine and Infectious Disease

journal homepage: www.elsevier.com/locate/tmaid

Ocular manifestations in COVID-19 patients: A systematic review and meta-analysis

Yueyang Zhong [1], Kai Wang [1], Yanan Zhu, Danni Lyu, Yinhui Yu, Su Li, Ke Yao *

Eye Center of the Second Affiliated Hospital, School of Medicine, Zhejiang University, Hangzhou, Zhejiang Province, China

ARTICLE INFO

Keywords:
COVID-19
SARS-CoV-2
Coronavirus
Ocular manifestation
Meta-analysis

ABSTRACT

Introduction: With the accumulating evidence of ocular manifestations of the 2019 novel coronavirus disease (COVID-19), the study aimed to systematically summarize the ocular manifestations in COVID-19 patients.
Methods: The PubMed, EMBASE, Web of Science databases were searched through June 2021. Studies that provided clinical characteristics and outcomes and reported on the ocular manifestations or conjunctival swab RT-PCR tests among COVID-19 patients were included.
Results: A total of 30 studies involving 5,717 patients were identified. Ocular manifestations including conjunctival hyperemia (7.6%, 95% confidence interval [CI] 1.8–8.9%), conjunctival discharge (4.8%, 95% CI 1.8–8.9%), epiphora (6.9%, 95% CI 2.8–12.8%), and foreign body sensation (6.9%, 95% CI 2.4–13.0%) were observed. The positive rate of conjunctival swab tests was 3.9% (95% CI 0.2–6.4%). Severe cases of COVID-19 were associated with an increased risk of developing ocular complications (odds ratio [OR] = 2.77, 95% CI 1.75–4.40).
Conclusions: Despite their relatively low incidence rate in COVID-19 patients, ocular manifestations may be non-specific and present as the initial symptoms of infection. The presence of SARS-CoV-2 in the conjunctival swabs implicates the eye as a potential source of infection. Early diagnosis and proper eye protection would help prevent viral transmission.

1. Introduction

The outbreak of the coronavirus disease 2019 (COVID-19) has rapidly spread and resulted in a global pandemic, defining a profound and enduring global health and social crisis of our time. As of July 2021, there have been a total of over 180 million confirmed cases of COVID-19 disease, causing deaths of over 3.9 million people [1]. Given the unprecedented impact of COVID-19, abundant studies have elucidated the etiology, pathogenesis, and mechanism of the COVID-19 disease, and virological studies on SARS-CoV-2's biological features were conducted, which shed light on the development of vaccines and effective treatment for the disease [2] [–] [4].

Respiratory viral infections are characterized by high transmissibility, worldwide distribution, and mucosal infection [5]. Previous clinical and experimental evidence have suggested that numerous respiratory viruses, of both human and zoonotic origins, utilized the ocular surface as a site of replication and dissemination [6]. Although ocular symptoms were not reported previously for the severe acute respiratory syndrome coronavirus (SARS-CoV), the virus was detected in tears and conjunctival samples, implicating the eye as a potential route for viral entry [6] [–] [8].

Recent research have demonstrated that the severe acute respiratory syndrome coronavirus 2 (SARS-CoV-2), like SARS-CoV, binds to the angiotensin-converting enzyme 2 (ACE2) cellular receptor and interact with the transmembrane protease serine 2 (TMPRSS2), which are known to be expressed in the human cornea, retina, and conjunctival epithelium [9] [–] [11]. Such findings offered the explanations for the ocular manifestations in some COVID-19 patients and the viability of the ocular transmission route. Guan et al. [12] first reported nine cases with ocular manifestations among 1,099 confirmed patients. In addition, several

Abbreviations: ACE2, angiotensin-converting enzyme 2; AHRQ, Agency for Healthcare Research and Quality; COVID-19, The coronavirus disease 2019; OR, odds ratio; PRISMA, Preferred Reporting Items for Systematic Reviews and Meta-Analyses; RT-PCR, reverse transcription polymerase chain reaction; SARS-CoV, severe acute respiratory syndrome coronavirus; SARS-CoV-2, severe acute respiratory syndrome coronavirus 2; TMPRSS2, transmembrane protease serine 2.

* Corresponding author. Eye Center, Second Affiliated Hospital, School of Medicine, Zhejiang University, No. 88 Jiefang Road, Hangzhou 310009, China.
E-mail address: xlren@zju.edu.cn (K. Yao).

[1] Yueyang Zhong and Kai Wang contributed equally to this work.

https://doi.org/10.1016/j.tmaid.2021.102191
Received 2 September 2020; Received in revised form 9 July 2021; Accepted 26 October 2021
Available online 8 November 2021
1477-8939/© 2021 Elsevier Ltd. All rights reserved.

COVID-19 cases presented with conjunctival hyperemia as the initial symptom, and SARS-CoV-2 could be detected in the patients' tears and conjunctival swabs, suggesting continuous replication and potential transmissibility [13,14]. To date, several studies have testified the potential transmission route of SARS-CoV-2 through ocular surface even in asymptomatic patients, providing important insights into the prevention of the disease [15,16].

Although some meta-analyses regarding ocular manifestations of COVID-19 patients have been published, they included a relatively small study size and the combination of proportion was marked with some methodological flaws [17] [–] [19]. Therefore, with the emerging evidence regarding the ocular involvements among COVID-19 patients, we sought to conduct a more comprehensive systematic review and meta-analysis to evaluate and summarize the ocular manifestations associated with the disease.

2. Material and methods

This meta-analysis was designed and performed based on the principles described in the Preferred Reporting Items for Systematic Reviews and Meta-Analyses (PRISMA) guidelines [20]. The protocol of our systematic review was registered with the International Prospective Register of Systematic Reviews (registration number CRD42020202218).

2.1. Eligibility criteria for considering studies for this review

Studies that satisfied the following criteria were included in our meta-analysis: (1) studies with clinical observations in humans; (2) studies providing clinical characteristics and outcomes of COVID-19 patients; and (3) studies reporting any ocular manifestations in COVID-19 patients. Filters were applied that only full-text studies presenting original data and published in English were eligible. Studies published as narrative reviews, meta-analyses, conference abstracts or studies that were not peer-reviewed were excluded. Besides, case reports of atypical ocular manifestations in COVID-19 patients were included and descriptive information were systematically summarized.

2.2. Search methods for identifying studies

The PubMed, EMBASE, Web of Science databases were systematically searched through 20 June 2021. The following keywords were used: ("COVID-19" OR "SARS-CoV-2" OR "2019-nCoV" OR "Novel Coronavirus" OR "coronavirus disease 2019") AND ("eye" OR "ocular" OR "conjunctival" OR "conjunctivitis" OR "conjunctiv*" OR "ophthalm*" OR "tear"). Reference lists of included articles and pertinent reviews were also searched.

2.3. Study selection

Two authors (Y.Z. and K.W.) independently screened all the titles and abstracts. Subsequently, full manuscripts of relevant articles were evaluated by two senior authors (Y.Z. and D.L.). Any discrepancies were resolved through group discussion.

2.4. Data collection and risk of bias assessment

The data of each eligible study were extracted using a standardized data collection form, which included the following baseline demographic and clinical data: first author, year of publication, study location, study design, number of COVID-19 cases, sample size, gender, age, time of sampling, laboratory test for COVID-19, and severity of COVID-19. The results of the nasopharyngeal swab and conjunctival swab reverse transcription polymerase chain reaction (RT-PCR) tests were recorded. Information of ocular manifestations, including conjunctival hyperemia, conjunctival discharge, epiphora, foreign body sensation, eye itching, conjunctival edema, ophthalmalgia, blurred vision, dry eye, and photophobia were also extracted.

Quality assessments for the included studies were performed using the Quality Assessment Forms for Cross-sectional/Prevalence Study recommended by the Agency for Healthcare Research and Quality (AHRQ) [21]. Briefly, each of the 11 items were scored for '1' if it was answered "YES", and scored for '0' if it was answered "NO" or "UNCLEAR". The overall quality was assessed by the total score as follows: low quality = 0–3; moderate quality = 4–7; high quality = 8–11 (Supplementary Method).

2.5. Data synthesis and analysis

Meta-analyses were performed to evaluate the proportion of the most frequently reported ocular manifestations among patients with confirmed COVID-19 and the proportion of conjunctival swab confirmation. Pooled estimates of proportions with corresponding 95% confidence intervals (95% CI) were calculated using the Freeman-Tukey double arcsine transformation to stabilize the variances within a random effect model framework [22,23]. Pooled odds ratio (OR) and 95% CI were calculated for the associations between the severity of COVID-19 and ocular manifestations across studies. A random-effects model (DerSimonian–Laird method) was applied to calculate the summarized OR and 95% CI [24].

Heterogeneity among the studies was estimated using the I^2 statistic and τ^2 test [25]. To explore the potential confounding factors, we performed subgroup analyses and meta-regression analyses, including location, sample size, and study design. Sensitivity analyses were performed by omitting one study at a time and calculating a pooled estimate for the remainder of the studies to evaluate whether the results were affected markedly by a single study. Publication bias was evaluated using contour-enhanced funnel plots, the Egger linear regression test, and the Begg rank correlation test, with significance set to $P < 0.10$ [26,27]. When a possible publication bias was identified, we used the trim and fill method for adjustment. All statistical analyses were performed using R version 3.6.2 (R Foundation for Statistical Computing, Vienna, Austria). Statistical significance was defined as $P < 0.05$.

3. Results

3.1. Search process

Of the 4,956 articles identified (2,421 from PubMed, 1,937 from Web of Science, 593 from EMBASE, and 5 from additional references screening), we excluded 4,289 duplicates and another 569 on the basis of their titles and abstracts not meeting our criteria (Fig. 1). Full-text assessment was performed on 98 articles, of which 68 were excluded for the following reasons: 32 were reviews, 20 were case reports, nine did not provide adequate information and seven were meta-analyses. Ultimately, 19 case series [28–46] and 11 cross-sectional studies [12,47–56] were included in the current meta-analysis. Additionally, 11 case reports of atypical ocular manifestations were included for descriptive analysis.

3.2. Study characteristics

Table 1 summarizes the descriptive characteristics and the quality assessment of each study. All studies were performed between December 2019 and September 2020. 11 studies were conducted in China, nine in other Asian countries, seven in Europe, and three in the United States. Overall, we recorded data from 5,717 patients (5,449 confirmed cases with positive nasopharyngeal swab test), consisting of 2,808 (58%) males and 2,042 (42%) females. The average quality score of the included studies was 8.4 points, with moderate to high quality (Table 1 and Table S1).

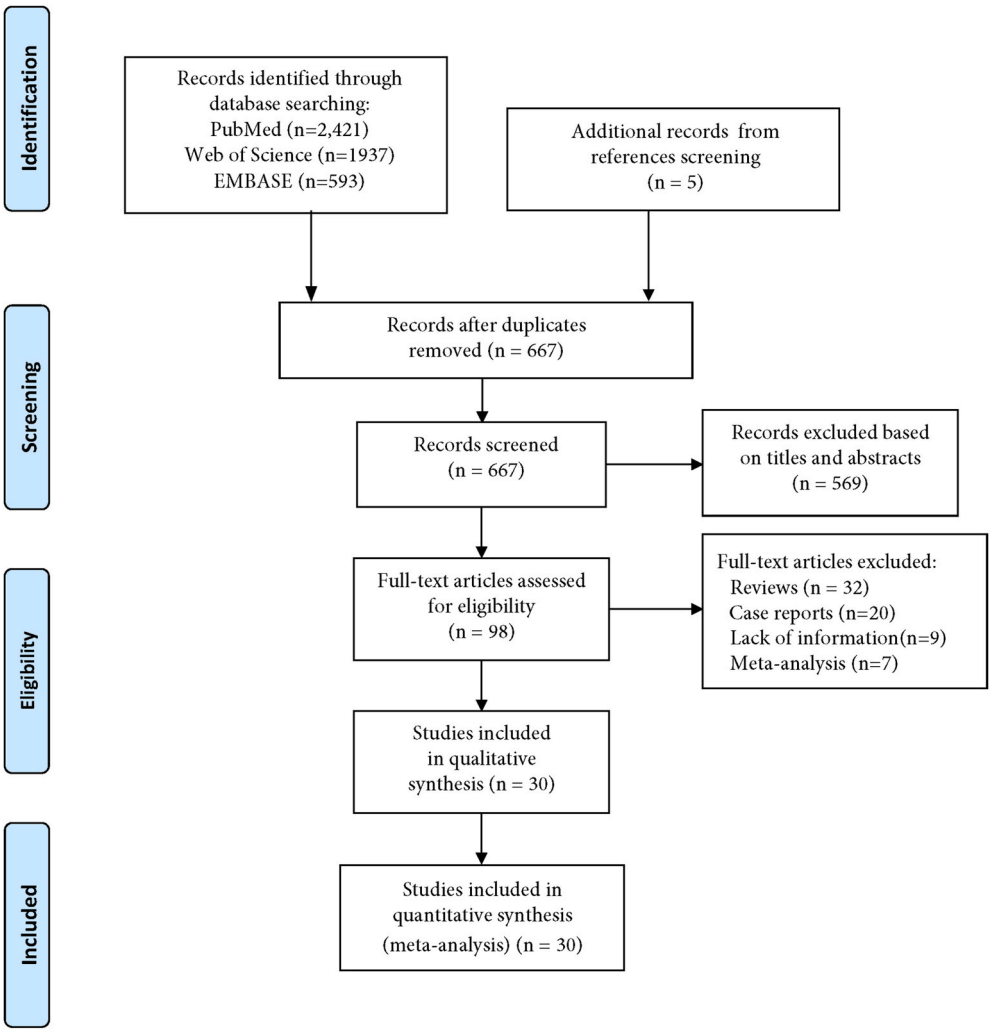

Fig. 1. PRISMA flowchart depicting selection of studies.

3.3. Ocular manifestations among COVID-19 patients

Overall, 29 studies provided detailed data of COVID-19 patients who reported any ocular manifestations (Table S2). Frequently reported ocular manifestations including conjunctival hyperemia, conjunctival discharge, epiphora, and foreign body sensation were pooled and analyzed (Fig. 2 and Fig. S1). Conjunctival hyperemia, which was the most common ocular manifestation in COVID-19 patients, was reported in 26 studies with a pooled proportion of 7.6% (95% CI 4.6–11.2%, $I^2 = 93.3\%$, $\tau^2 = 0.019$). 10 studies reported the symptom of conjunctival discharge, and the pooled proportion was 4.8% (95% CI 1.8–8.9%, $I^2 = 88.3\%$, $\tau^2 = 0.011$). For epiphora, the pooled results of nine studies revealed a proportion of 6.9% (95% CI 2.8–12.5%, $I^2 = 88.3\%$, $\tau^2 = 0.016$). In terms of foreign body sensation, the pooled proportion from nine studies was 6.9% (95% CI 2.4–13.0%, $I^2 = 90.1\%$, $\tau^2 = 0.018$).

3.4. Positive rate of conjunctival swab RT-PCR tests

Among the included studies, 14 of them provided information on conjunctival swab RT-PCR tests. Diagnostically, the SARS-CoV-2 detection rate in conjunctival swab samples was low (Fig. 3). Among 685 patients who were confirmed by nasopharyngeal swab RT-PCR and received further tests for conjunctival swab RT-PCR testing, the overall positive rate of conjunctival samples was 3.9% (95% CI 0.2–6.4%, $I^2 = 35.2\%$, $\tau^2 = 0.003$).

3.5. Risk of ocular manifestations in severe COVID-19 patients

11 studies stratified patients according to the severity of the COVID-19 disease. As presented in Fig. 4, COVID-19 patients who were defined as having severe disease had a higher risk of developing ocular manifestations (OR = 2.77, 95% CI 1.75–4.40, $I^2 = 0\%$, $\tau^2 = 0$).

3.6. Heterogeneity analysis and publication bias

In terms of the incidence rate of ocular manifestations, the studies were characterized by high between-study heterogeneity. To determine the possible source of heterogeneity, sensitivity analyses were conducted, which revealed that no individual study affected the pooled effect size, suggesting the stability of the results (Tables S3–6). In addition, subgroup analyses and meta-regression analyses were conducted to determine the source of heterogeneity (Table 2 and Table S7). Specifically, when stratified by sample size, the positive rate of conjunctival swab RT-PCR test were different between studies with sample size smaller than 100 (positive rate: 4.9%, 95% CI 2.4–7.9%) and larger than 100 (positive rate: 2.3%, 95% CI 0.6–4.9%; $P = 0.031$ for meta-regression). This may be attributed to the study by Hong *et al.* which only had conjunctival test on two patients and reported a positive rate of 50% [31]. Furthermore, it was found that the incidence rate of conjunctival discharge was modified by the location of studies ($P = 0.046$ for meta-regression; Table S7). Studies conducted in China exhibited a higher incidence rate of 7.5% (95% CI 1.6–16.5%) than in

Table 1
Characteristics of the studies included in the meta-analysis (n = 30).

Author	Location	Study type	Total case	Age (years)[a]	Sex (male/female)	Sampling time (days)[b]	Laboratory test for COVID-19	Quality score/grade[c]
Abrishami et al. [47]	Iran	Cross-sectional	142 (77 confirmed)	62.5 ± 15 (23–96)	77/65	5 (3–9)	nasopharyngeal swab RT-PCR	8/High
Argenziano et al. [28]	US	Retrospective case series	1000	61.7 ± 17.5 (50–75)	596/404	NA	nasopharyngeal swab RT-PCR	11/High
Arora et al. [48]	India	Cross-sectional	75	NA	41/34	NA	nasopharyngeal and conjunctival swab RT-PCR	10/High
Atum et al. [29]	Turkey	Prospective case series	40	41.4 ± 23.7 (1–82)	25/15	NA	nasopharyngeal swab RT-PCR	8/High
Cavalleri et al. [49]	Italy	Cross-sectional	172	64.2 ± 13.4	117/55	7.2 ± 4.3	nasopharyngeal and conjunctival swab RT-PCR	10/High
Chen et al. [50]	China	Cross-sectional	263 (Mobile cabin hospital)	40 (16–68)	134/129	NA	nasopharyngeal swab RT-PCR	10/High
			271 (Tongji hospital)	50 (18–65)	134/137			
Dolar-Szczasny et al. [30]	Poland	Prospective case series	74	21–89	46/28	<3	nasopharyngeal and conjunctival swab RT-PCR	8/High
Feng et al. [51]	US	Cross-sectional	400	61.7 ± 15.5	233/167	NA	nasopharyngeal swab RT-PCR	8/High
Gangaputra and Patel [52]	US	Cross-sectional	144	NA	NA	NA	nasopharyngeal swab RT-PCR	7/Moderate
Guan et al. [12]	China	Cross-sectional	1099	47 (35–58)	638/461	NA	nasopharyngeal swab RT-PCR	11/High
Güemes-Villahoz et al. [53]	Spain	Cross-sectional	689	NA	NA	NA	nasopharyngeal and conjunctival swab RT-PCR	8/High
Hong et al. [31]	China	Prospective case series	56	48 (24–68)	31/25	NA	nasopharyngeal swab RT-PCR	9/High
Karimi et al. [32]	Iran	Prospective case series	43	56 ± 13	29/14	3.3 (1–7)	nasopharyngeal and conjunctival swab RT-PCR	9/High
Kumar et al. [33]	India	Prospective case series	45	31.3 ± 12.8 (6–75)	35/10	NA	nasopharyngeal and conjunctival swab RT-PCR	7/Moderate
Lee et al. [34]	Korea	Retrospective case series	71	49 ± 18	15/56	NA	nasopharyngeal swab RT-PCR	7/Moderate
Li et al. [83]	China	Prospective case series	59	41.8 ± 19.3	35/24	19.3 (1–50)	nasopharyngeal and conjunctival swab RT-PCR	7/Moderate
Liu et al. [36]	China	Retrospective case series	67	49 (22–83)	36/31	6 (1–20)	nasopharyngeal swab RT-PCR	8/High
Meduri et al. [37]	Italy	Prospective case series	29	77.1 ± 12.6 (44–92)	15/14	NA	nasopharyngeal swab RT-PCR	7/Moderate
Pirraglia et al. [54]	Italy	Cross-sectional	43	70 (59–78)	25/18	21.5 (10–34)	nasopharyngeal and conjunctival swab RT-PCR	9/High
Seah et al. [38]	Singapore	Prospective case series	17	37 (20–75)	11/6	NA	nasopharyngeal and conjunctival swab RT-PCR	8/High
Shahriarirad et al. [39]	Iran	Retrospective case series	113	53.8 ± 16.6 (20–99)	71/42	5.6	nasopharyngeal swab RT-PCR	8/High
Shemer et al. [40]	Israel	Prospective case series	16	58.7 ± 24.0	7/9	NA	nasopharyngeal and conjunctival swab RT-PCR	7/Moderate
Sindhuja et al. [41]	India	Retrospective case series	127	38.8 (5–73)	113/14	14–21	nasopharyngeal and conjunctival swab RT-PCR	9/High
Valente et al. [42]	Italy	Prospective case series	27	7	20/7	7 (0–19)	nasopharyngeal and conjunctival swab RT-PCR	10/High
Wei et al. [43]	China	Retrospective case series	276	51 (41–58)	155/121	6 (4–7)	nasopharyngeal swab RT-PCR	9/High
Wu et al. [44]	China	Retrospective case series	38 (28 confirmed)	68 (53–76)	25/14	NA	nasopharyngeal and conjunctival swab RT-PCR	9/High
Xia et al. [45]	China	Prospective case series	30	54.5 ± 14.2	21/9	7.3 ± 3.8	nasopharyngeal and conjunctival swab RT-PCR	8/High
Xie et al. [46]	China	Retrospective case series	33	57.6 ± 14.0	22/11	7	nasopharyngeal and conjunctival swab RT-PCR	7/Moderate
Zhang et al. [55]	China	Cross-sectional	102 (72 confirmed)	57.6 ± 14.9	48/54	18.2 ± 7.6	nasopharyngeal and conjunctival swab RT-PCR	7/Moderate
Zhou et al. [56]	China	Cross-sectional	121	48 (22–89)	53/68	15.0 ± 8.8	nasopharyngeal and conjunctival swab RT-PCR	8/High

Abbreviations: NA: not available; RT-PCR: Real-time polymerase chain reaction.
[a] Age presented as mean ± SD and/or median (range).
[b] Sampling time presented as mean ± SD and/or median (range).
[c] Quality assessment using the Quality Assessment Forms for cross-sectional/prevalence study recommended by Agency for Healthcare Research and Quality (AHRQ) [21].

other locations but was subjected to substantial heterogeneity (I^2 = 87%), which might lead to the location-stratified results. Further subgroup analyses and meta-regression analyses stratified by location, sample size and study design did not present significant results.

Publication bias were tested using the Egger linear regression and Begg rank correlation tests [26,27]. We found evidence of publication bias with regards to the ocular manifestation of conjunctival hyperemia, conjunctival discharge, and positive rate of conjunctival swab RT-PCR

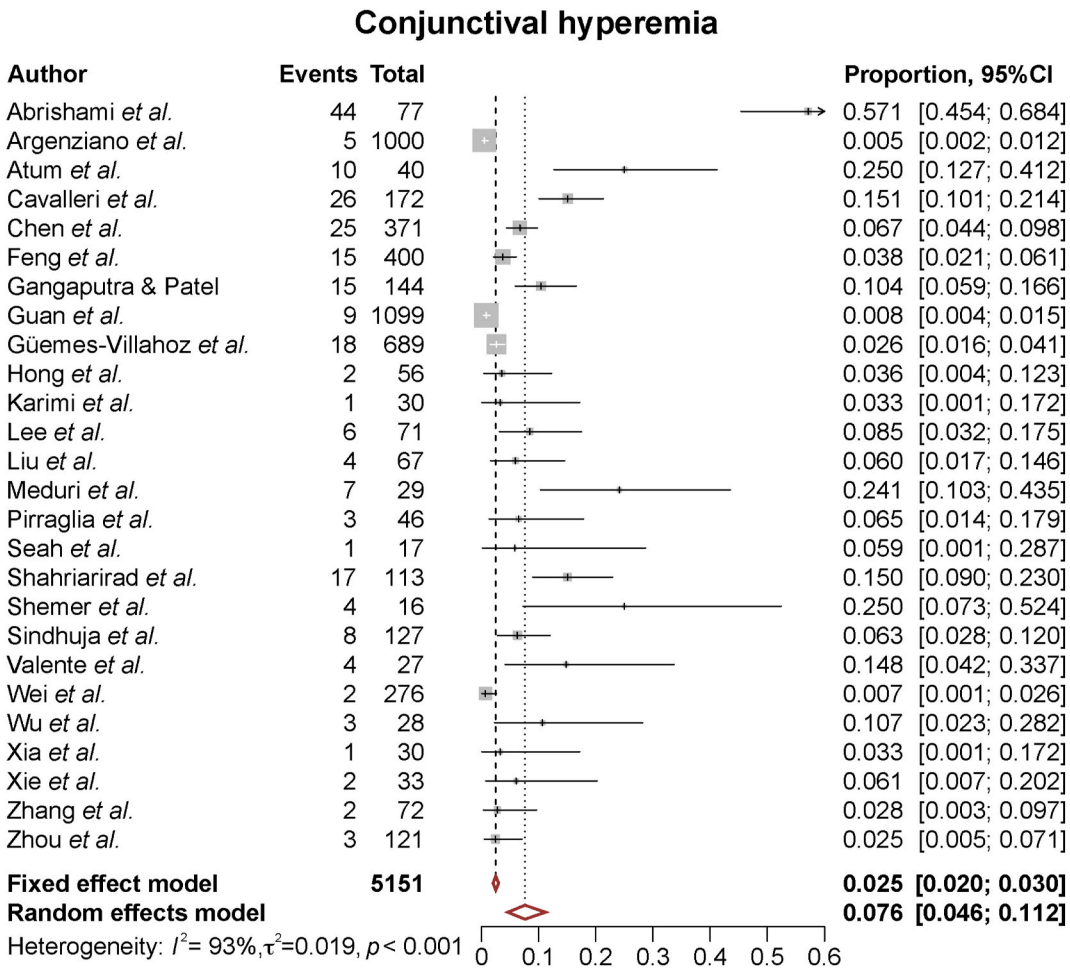

Fig. 2. Proportion of ocular manifestations of conjunctival hyperemia in COVID-19 patients.

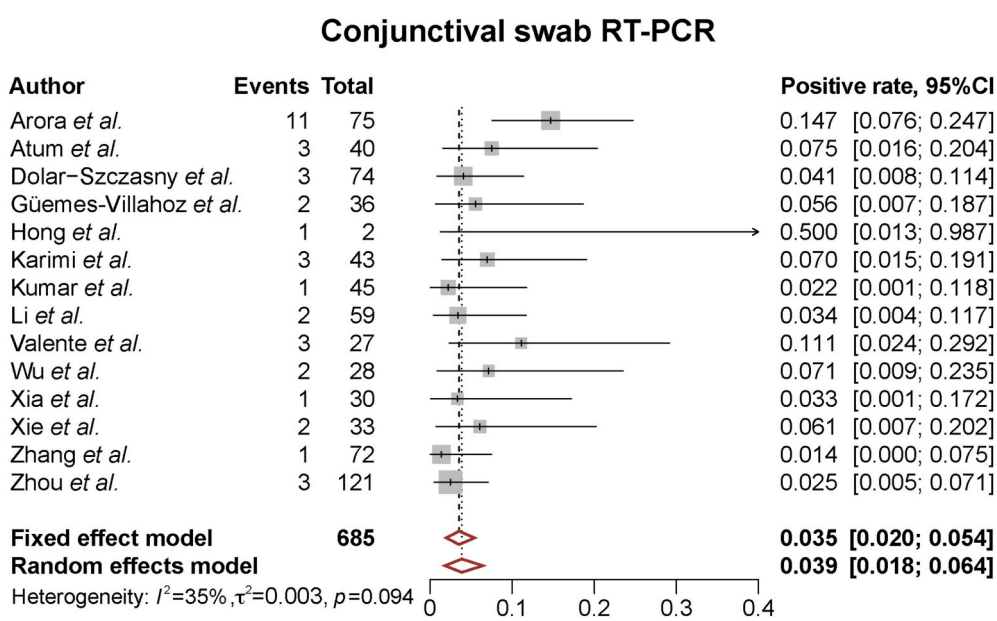

Fig. 3. Positive rate of conjunctival swab RT-PCR test in COVID-19 patients.

test (Table S8). Therefore, trim and fill method was adopted to recalculate the overall proportion. Publication bias was not detected in other comparisons, which was consistent with the funnel plots (Fig. S2).

3.7. Case reports of ocular manifestations

Despite the frequently reported ocular manifestations pooled in our

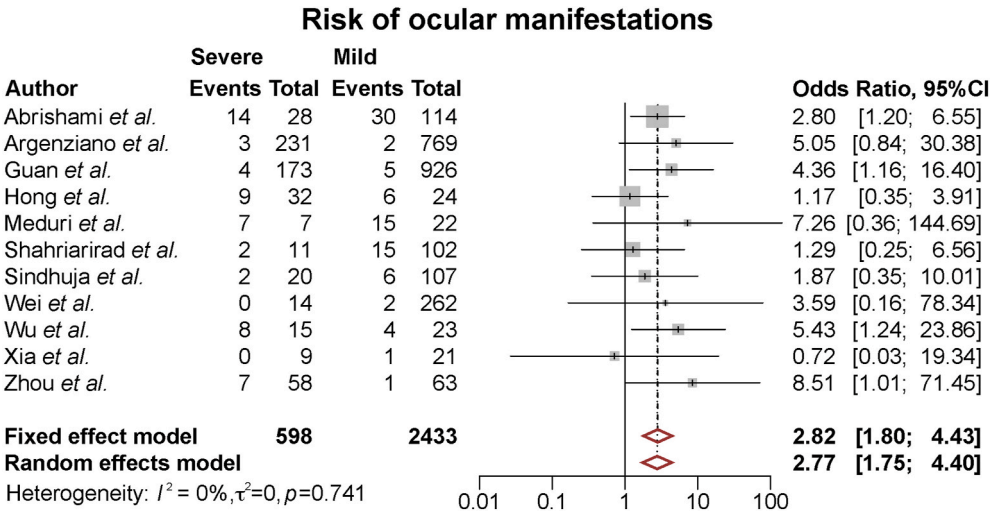

Fig. 4. Risk of ocular manifestations in severe COVID-19 patients.

Table 2
Subgroup analyses performed in conjunctival hyperemia, conjunctival swab RT-PCR and risk of ocular manifestations.

Subgroup	Conjunctival hyperemia				Conjunctival swab RT-PCR				Risk of ocular manifestations			
	N	Proportion (95%CI)	I^2	P^a	N	Proportion (95%CI)	I^2	P^a	N	OR (95%CI)	I^2	P^a
Location				0.427				0.199				0.689
China	10	0.032 (0.011, 0.059)	82		7	0.010 (0.001, 0.033)	10		6	2.93 (1.48, 5.82)	0	
Other Asian countries	7	0.151 (0.041, 0.306)	93		3	0.076 (0.018, 0.164)	65		3	2.28 (1.15, 4.53)	0	
Europe	6	0.127 (0.044, 0.242)	92		4	0.059 (0.026, 0.101)	0		1	7.26 (0.36, 144.69)	NA	
United States	3	0.037 (0.002, 0.105)	95		0	NA	NA		1	5.05 (0.84, 30.38)	NA	
Sample size				0.223				0.031				0.543
<100	13	0.092 (0.056, 0.135)	49		11	0.049 (0.024, 0.079)	20		4	2.30 (0.85, 6.20)	15	
≥100	13	0.065 (0.031, 0.109)	96		3	0.023 (0.006, 0.049)	0		7	3.04 (1.75, 5.26)	0	
Study design				0.811				0.709				0.490
Cross-sectional	11	0.077 (0.035, 0.132)	96		4	0.050 (0.008, 0.119)	77		4	3.22 (1.72, 6.04)	0	
Case series	15	0.078 (0.034, 0.136)	89		10	0.034 (0.014, 0.061)	0		7	2.32 (1.17, 4.60)	0	

Abbreviation: OR, odds ratio; 95% CI, 95 confidence intervals; N, study number; NA, not available.
a. *P* value for heterogeneity between subgroups with meta-regression analysis.

Table 3
Case reports of ocular manifestations with COVID-19 (n = 11).

Author	Location	Age (years), Sex	Exposure history	Ocular manifestations	Nasopharyngeal swab test	Conjunctival swab test
Cheema et al. [13]	US	29, M	1-month vacation in Philippines	Conjunctivitis, photophobia, clear watery discharge in the right eye as the initial presentations	Positive	Weakly positive on Day 5
Chen et al. [57]	China	30, M	Close contacts with patients	Conjunctival congestion, foreign body sensation, epiphora	Positive	Positive on Day 13, negative on Day 19
Colavita et al. [14]	Italy	65, F	History of travel to Wuhan	Severe conjunctival congestion, chemosis, epiphora	Positive	Positive on Day 3, negative on Day 5, positive again on Day 27
Dumitrascu et al. [58]	US	48, M	History of travel to Florida	Acute severe right eye vision loss, incomplete ophthalmic artery occlusion	Positive	NA
François et al. [59]	France	Late 50s, F	Contact with a fatal case	Severe ocular neuropathy and panuveitis	Positive	NA
Gascon et al. [60]	France	53, M	Close contacts with patients	Acute macular neuroretinopathy and paracentral acute middle maculopathy	Positive	Negative
Lani-Louzada et al. [61]	Brazil	3 cases	NA	Bilateral retinal microhemorrhages	Positive	NA
Marinho et al. [62]	Brazil	12 cases	NA	Cotton wool spot, retinal microhemorrhages, hyper-reflective lesions	Positive	NA
Murchison et al. [63]	US	50, M	NA	Central retinal artery occlusion as the initial presentation	Positive	NA
Navel et al. [64]	France	63, M	NA	Conjunctival congestion, secretion, petechias, tarsal hemorrhages, mucous filaments, pseudomembranous	Positive	Negative
Wu et al. [65]	China	2.8 (34 months), M	Familial patients contacts	Conjunctival congestion, eyelid dermatitis	Positive	NA

Abbreviations: M, male; F, female; NA: not available.

meta-analysis, we identified and summarized 11 case reports of atypical ocular manifestations of COVID-19 patients [13,14,57] [–] [65] (Table 3). Among them, four were reported in Europe, three were identified in the United States, two in China, and the other two in Brazil. Most cases had history of travelling to the affected areas or contacts with confirmed patients. All of the cases were tested positive for SARS-CoV-2 in nasopharyngeal swabs, while the virus load was relatively unstable in the conjunctival samples. Notably, Colavita *et al.* [14] reported a case of a woman with severe conjunctival congestion. Her conjunctival specimen was negative on day 3 of diagnosis but became positive again on day 27, suggesting continuous viral replication. The youngest patient was a 34-month-old boy who presented with conjunctival congestion and eyelid dermatitis as the only symptoms [65]. In addition, a case of pseudomembranous and hemorrhagic conjunctivitis was reported [64]. Despite conjunctival infection, Dumitrascu *et al.* [58] reported a case of ophthalmic artery occlusion, and Murchison *et al.* [63] later identified a case of central retinal artery occlusion as the initial presentation. Furthermore, Marinho *et al.* [62] first identified a case with retinal findings of cotton wool spot, retinal microhemorrhages, implying potential central nervous system manifestation. The retinal involvements were also reported by François *et al.* [59] and Lani-Louzada *et al.* [61], who found severe ocular neuropathy, panuveitis, and bilateral retinal microhemorrhages, respectively.

4. Discussion

Recent clinical evidence have demonstrated that COVID-19 patients could present with a wide range of systemic symptoms according to the severity of the disease [2]. Although the incidence rate of ocular manifestations is generally low, the early recognition of ocular signs may be helpful in identifying potential patients. In this meta-analysis, we identified 478 (8.8%) patients with ocular involvements from a population of 5,717 patients. Although ocular manifestations were generally less common than respiratory symptoms, they may be non-specific and present as the initial and the only symptoms of infection. Our meta-analysis analyzed the most frequently reported ocular symptoms included conjunctival hyperemia, conjunctival discharge, epiphora and foreign body sensation. The positive rate of SARS-CoV-2 detection in patients' conjunctiva is around 3.9%. Furthermore, severe COVID-19 cases were 2–3 times more likely to be accompanied with ocular manifestations than mild cases.

By the time of our search, some meta-analyses have been published on this topic. Aggarwal *et al.* reported a higher incidence rate of 31.2% for ocular pain, 19.2% for discharge, 10.8% for redness, and 7.7% for conjunctivitis than our results [18]. However, they included two studies consisting only healthcare workers, which might be a source of selection bias. Another study by Cao *et al.* also included a study consisting only children patients [19]. More importantly, due to the relatively small incidence rate of ocular manifestations, it is more accurate to use Freeman-Tukey double arcsine transformation methods to avoid bias and stabilize the variances when combining the proportions [22,66].

The conjunctiva, which serves as the barrier between lacrimal fluid, blood circulation, and the eye, is one of the first sites to be affected by exogenous pathogens. Conjunctivitis, or inflammation of the conjunctiva and eyelid, is the primary ocular complication reported in individuals with confirmed influenza virus infection [67]. As the most common overall cause of infectious conjunctivitis, acute viral conjunctivitis is usually a self-limiting condition that rarely causes permanent vision loss [68]. Typical conjunctivitis is characterized by dilation of conjunctival blood vessels, leading to hyperemia, edema and aqueous discharge [68]. Our results regarding COVID-19-related ocular symptoms are consistent with those reported for other respiratory viral infections [6]. However, the signs and symptoms at presentation are variable and non-specific. Other ocular manifestations including eye itching, ophthalmalgia, photophobia, blurred vision and dry eye were also recorded in some studies [50,69]. To our surprise, although evidence of other ocular findings is scarce, several severe cases of pseudomembranous hemorrhagic conjunctivitis, retinal-related manifestations, ophthalmic artery occlusion, and ocular neuropathy were also reported. Consequently, given the diverse clinical manifestation of COVID-19, utmost caution should be taken by medical workers in identifying potential infected patients.

Although most patients are considered mild cases, severe COVID-19 infection can lead to complications and higher mortality [70]. In our meta-analysis, severe cases had an approximately 3-fold higher risk of developing ocular symptoms. Patients with ocular abnormalities and positive conjunctival samples were more likely to be severe and/or critical cases [44,46,56]. Additionally, Wu *et al.* [44] evaluated 15 severe cases and reported an incidence rates of ocular manifestations as high as 25%. These findings should be considered with respect to the virus's systemic effect on the body. To our knowledge, SARS-CoV-2 can attack a wide range of organs and tissues in humans. Moreover, a severe infectious condition can impair immune responses, which might increase the possibility of the virus infection disseminating outside the respiratory tract. However, the mechanisms that underlie the development of complications and their association with severe COVID-19 cases are poorly understood and warrant further investigation.

Although SARS-CoV-2 is primarily transmitted through the respiratory tract, it can also be isolated from extra-pulmonary sites including the digestive tract, blood, tears and conjunctival specimens [42,71]. Nevertheless, whether SARS-CoV-2 can be transmitted through ocular surfaces remains controversial. It should also be noted that patients without any ocular symptoms can still yield positive conjunctival swab test [56]. Several established properties might render the eye as a potential conductive site for viral infection and subsequent dissemination. Anatomically, the eye is connected to the respiratory tract through the nasolacrimal system, which acts as a conduit for fluid exchange [6]. Several experimental and clinical studies have detected respiratory viruses in tears and the conjunctival surface, which is likely due to the direct spread via the nasolacrimal duct [67,72]. Despite the innate linkage, the mucous membranes of the mouth, eyes, and tears are potential sources of microbial transmission and detection. The conjunctival mucous membrane shares permissive receptors in common with the respiratory tract, which contributes to the ocular tropism of respiratory viruses [6]. Specifically, for coronaviruses, the cellular receptor ACE2 and the serine protease TMPRSS2, which are highly expressed in the epithelia of the lung and small intestine in humans, is also expressed in human corneal and conjunctival tissues [9]. Recent experimental studies have suggested SARS-CoV-2 binds ACE2 on host cells with significantly higher affinity than the 2013 SARS-CoV, providing more evidence of viral pathogenesis via this receptor [10,73]. Additionally, it has been proposed that SARS-CoV-2 exploited up-regulation of ACE2 and TMPRSS2 through inflammatory pathways to enhance infection in the ocular surface [74]. Therefore, direct contact with the ocular secretions of COVID-19 patients and aerosols produced by non-contact tonometry spraying, lid specula, and slit lamps might increases the risk of disease transmission.

With the existing evidence of medications of treating COVID-19, anti-malarial agents of chloroquine and hydroxychloroquine have been examined for their therapeutic role for the disease. Studies have confirmed their direct antiviral effects by inhibiting pH-linked steps of replication of retroviruses, flaviviruses, coronaviruses, and SARS-Cov-2. However, controversies still exist on whether the treatment of hydroxychloroquine could prevent the transmission or progression of the disease [75] [–] [77]. Furthermore, systemic application of chloroquine and hydroxychloroquine were associated with retinal toxicity which may lead to irreversible visual loss [78]. To date, most guidelines and trails have recommended relatively high doses of chloroquine and hydroxychloroquine than the maximum safety dose of related retinal toxicity [79]. According to the recommendation by the American Academy of Ophthalmology, high dose and long duration of over 5 years the are major risk factors for retinal toxicity [80]. Nevertheless,

considering the unproven therapeutic effect of chloroquine and hydroxychloroquine in the current pandemic situation, the risk of their irreversible retinal damage should not be overlooked. With respect to the ocular surface, topical application of chloroquine (0.03%) has shown effective results in the management of dry eye syndrome [81]. However, whether it is effective in preventing SARS-Cov-2 infection is still unknown.

Given the ocular-respiratory proximity and probability of conjunctival transmission, the use of respiratory protection solely does not fully protect against virus exposure and infection. Therefore, appropriate use of personal protective equipment including masks, goggles, gloves and face shields is necessary for health workers, especially for ophthalmologists [15,82]. Furthermore, as ocular involvements of COVID-19 may be diverse and non-specific, and may present as the initial symptoms, ophthalmologists should be vigilant in identifying potential COVID-19 patients.

Admittedly, several limitations of our study should be addressed. First, high heterogeneities were noticed among studies with regard to ocular manifestations. This might be due to the different measurement standards, sampling times, patients' medical conditions, and the relatively low incidence rate of ocular symptoms. However, sensitivity analyses have proven the stability of our results. Second, it is possible that the proportion of conjunctival hyperemia and positive rate of conjunctival swab RT-PCR test have been overstated due to the publication bias, particularly given that many studies have relatively small sample size. Third, the observational design of the included studies precluded the evidence of causality between COVID-19 and ocular manifestations. Instead, we can only provide description and explanation of the findings. Fourth, most of the included studies were carried out in China, which limits the generalizability of our findings.

5. Conclusions

In summary, our meta-analysis provided the updated and comprehensive evidence of ocular manifestations among COVID-19 patients. Although ocular involvements are relatively rare and nonspecific, conjunctivitis-related symptoms may occur prior to the onset of respiratory symptoms and could be the precursors for early diagnosis. The presence of SARS-CoV-2 in conjunctival specimens may represent a source of spread, especially for severe cases with higher viral loads. Therefore, utmost caution must be taken by healthcare workers to avoid cross-infection during patient examinations. Further research is warranted to elucidate the mechanisms of transmission and potential of prevention and treatment of SARS-CoV-2 via the ocular surfaces.

Funding

This research did not receive any specific grant from funding agencies in the public, commercial, or not-for-profit sectors.

Declaration of competing interest

The authors declare that there is no conflict of interest associated with this manuscript.

Acknowledgments

Author contributions are listed as follows: Y.Z. and K.Y. conceived and designed the study. K.W., Y.Z. and D.L. performed literature searches and data collection. K.W. and Y.Y. conducted statistical analysis. Y.Z. and S.L. wrote the manuscript and K.Y. revised it. All authors reviewed the manuscript.

Appendix B. Supplementary data

Supplementary data to this article can be found online at https://doi.org/10.1016/j.tmaid.2021.102191.

References

[1] WHO Coronavirus (COVID-19) Dashboard n.d. https://covid19.who.int (accessed July 7, 2021).
[2] Jutzeler CR, Bourguignon L, Weis CV, Tong B, Wong C, Rieck B, et al. Comorbidities, clinical signs and symptoms, laboratory findings, imaging features, treatment strategies, and outcomes in adult and pediatric patients with COVID-19: a systematic review and meta-analysis. Trav Med Infect Dis 2020;37:101825. https://doi.org/10.1016/j.tmaid.2020.101825.
[3] Barboza JJ, Chambergo-Michilot D, Velasquez-Sotomayor M, Silva-Rengifo C, Diaz-Arocutipa C, Caballero-Alvarado J, et al. Assessment and management of asymptomatic COVID-19 infection: a systematic review. Trav Med Infect Dis 2021; 41:102058. https://doi.org/10.1016/j.tmaid.2021.102058.
[4] Pang JK, Jones SP, Waite LL, Olson NA, Armstrong JW, Atmur RJ, et al. Probability and estimated risk of SARS-CoV-2 transmission in the air travel system. Trav Med Infect Dis 2021;43:102133. https://doi.org/10.1016/j.tmaid.2021.102133.
[5] de Wit E, van Doremalen N, Falzarano D, Munster VJ. SARS and MERS: recent insights into emerging coronaviruses. Nat Rev Microbiol 2016;14:523–34. https://doi.org/10.1038/nrmicro.2016.81.
[6] Belser JA, Rota PA, Tumpey TM. Ocular tropism of respiratory viruses. Microbiol Mol Biol Rev MMBR 2013;77:144–56. https://doi.org/10.1128/MMBR.00058-12.
[7] Bonn D. SARS virus in tears? Lancet Infect Dis 2004;4:480. https://doi.org/10.1016/S1473-3099(04)01093-X.
[8] Peiris JSM, Yuen KY, Osterhaus ADME, Stöhr K. The severe acute respiratory syndrome. N Engl J Med 2003;349:2431–41. https://doi.org/10.1056/NEJMra032498.
[9] HCA Lung Biological Network, Sungnak W, Huang N, Bécavin C, Berg M, Queen R, et al. SARS-CoV-2 entry factors are highly expressed in nasal epithelial cells together with innate immune genes. Nat Med 2020;26:681–7. https://doi.org/10.1038/s41591-020-0868-6.
[10] Ziegler CGK, Allon SJ, Nyquist SK, Mbano IM, Miao VN, Tzouanas CN, et al. SARS-CoV-2 receptor ACE2 is an interferon-stimulated gene in human airway epithelial cells and is detected in specific cell subsets across tissues. Cell 2020;181:1016–35. https://doi.org/10.1016/j.cell.2020.04.035. e19.
[11] Li W, Moore MJ, Vasilieva N, Sui J, Wong SK, Berne MA, et al. Angiotensin-converting enzyme 2 is a functional receptor for the SARS coronavirus. Nature 2003;426:450–4. https://doi.org/10.1038/nature02145.
[12] Guan W-J, Ni Z-Y, Hu Y, Liang W-H, Ou C-Q, He J-X, et al. Clinical characteristics of coronavirus disease 2019 in China. N Engl J Med 2020;382:1708–20. https://doi.org/10.1056/NEJMoa2002032.
[13] Cheema M, Aghazadeh H, Nazarali S, Ting A, Hodges J, McFarlane A, et al. Keratoconjunctivitis as the initial medical presentation of the novel coronavirus disease 2019 (COVID-19). Can J Ophthalmol J Can Ophtalmol 2020;55:e125–9. https://doi.org/10.1016/j.jcjo.2020.03.003.
[14] Colavita F, Lapa D, Carletti F, Lalle E, Bordi L, Marsella P, et al. SARS-CoV-2 isolation from ocular secretions of a patient with COVID-19 in Italy with prolonged viral RNA detection. Ann Intern Med 2020;173:242–3. https://doi.org/10.7326/M20-1176.
[15] Pandey N, Kumar S, Kesar SD, Dandu HR, Ankita, Maurya VK, et al. An Ophthalmological update for air-travellers during COVID-19. Trav Med Infect Dis 2021;39:101955. https://doi.org/10.1016/j.tmaid.2020.101955.
[16] Hui KPY, Cheung M-C, Perera RAPM, Ng K-C, Bui CHT, Ho JCW, et al. Tropism, replication competence, and innate immune responses of the coronavirus SARS-CoV-2 in human respiratory tract and conjunctiva: an analysis in ex-vivo and in-vitro cultures. Lancet Respir Med 2020;8:687–95. https://doi.org/10.1016/S2213-2600(20)30193-4.
[17] Inomata T, Kitazawa K, Kuno T, Sung J, Nakamura M, Iwagami M, et al. Clinical and prodromal ocular symptoms in coronavirus disease: a systematic review and meta-analysis. Invest Ophthalmol Vis Sci 2020;61:29. https://doi.org/10.1167/iovs.61.10.29.
[18] Aggarwal K, Agarwal A, Jaiswal N, Dahiya N, Ahuja A, Mahajan S, et al. Ocular surface manifestations of coronavirus disease 2019 (COVID-19): a systematic review and meta-analysis. PLoS One 2020;15:e0241661. https://doi.org/10.1371/journal.pone.0241661.
[19] Cao K, Kline B, Han Y, Ying G, Wang NL. Current evidence of 2019 novel coronavirus disease (COVID-19) ocular transmission: a systematic review and meta-analysis. BioMed Res Int 2020;2020:1–8. https://doi.org/10.1155/2020/7605453.
[20] Moher D, Liberati A, Tetzlaff J, Altman DG, PRISMA Group. Preferred reporting items for systematic reviews and meta-analyses: the PRISMA statement. PLoS Med 2009;6:e1000097. https://doi.org/10.1371/journal.pmed.1000097.
[21] Rostom A, Dubé C, Cranney A, Saloojee N, Sy R, Garritty C, et al. Appendix D. Quality assessment forms. Agency for Healthcare Research and Quality (US); 2004.
[22] Freeman MF, Tukey JW. Transformations related to the angular and the square root. Ann Math Stat 1950;21:607–11. https://doi.org/10.1214/aoms/1177729756.
[23] Miller JJ. The inverse of the freeman – Tukey double arcsine transformation. Am Statistician 1978;32. https://doi.org/10.1080/00031305.1978.10479283. 138–138.
[24] DerSimonian R, Kacker R. Random-effects model for meta-analysis of clinical trials: an update. Contemp Clin Trials 2007;28:105–14. https://doi.org/10.1016/j.cct.2006.04.004.

[25] Rücker G, Schwarzer G, Carpenter JR, Schumacher M. Undue reliance on I2 in assessing heterogeneity may mislead. BMC Med Res Methodol 2008;8:79. https://doi.org/10.1186/1471-2288-8-79.
[26] Begg CB, Mazumdar M. Operating characteristics of a rank correlation test for publication bias. Biometrics 1994;50:1088–101.
[27] Egger M, Davey Smith G, Schneider M, Minder C. Bias in meta-analysis detected by a simple, graphical test. BMJ 1997;315:629–34. https://doi.org/10.1136/bmj.315.7109.629.
[28] Argenziano MG, Bruce SL, Slater CL, Tiao JR, Baldwin MR, Barr RG, et al. Characterization and clinical course of 1000 patients with coronavirus disease 2019 in New York: retrospective case series. BMJ 2020;369:m1996. https://doi.org/10.1136/bmj.m1996.
[29] Atum M, Boz AAE, Çakır B, Karabay O, Köroğlu M, Öğütlü A, et al. Evaluation of conjunctival swab PCR results in patients with SARS-CoV-2 infection. Ocul Immunol Inflamm 2020;28:745–8. https://doi.org/10.1080/09273948.2020.1775261.
[30] Dolar-Szczasny J, Toro MD, Dworzańska A, Wójtowicz T, Korona-Glowniak I, Sawicki R, et al. Ocular involvement of SARS-CoV-2 in a polish cohort of COVID-19-positive patients. Int J Environ Res Publ Health 2021;18:2916. https://doi.org/10.3390/ijerph18062916.
[31] Hong N, Yu W, Xia J, Shen Y, Yap M, Han W. Evaluation of ocular symptoms and tropism of SARS-CoV-2 in patients confirmed with COVID-19. Acta Ophthalmol 2020;98. https://doi.org/10.1111/aos.14445.
[32] Karimi S, Arabi A, Shahraki T, Safi S. Detection of severe acute respiratory syndrome Coronavirus-2 in the tears of patients with Coronavirus disease 2019. Eye Lond Engl 2020;34:1220–3. https://doi.org/10.1038/s41433-020-0965-2.
[33] Kumar K, Prakash AA, Gangasagara SB, Rathod SBL, Ravi K, Rangaiah A, et al. Presence of viral RNA of SARS-CoV-2 in conjunctival swab specimens of COVID-19 patients. Indian J Ophthalmol 2020;68:1015–7. https://doi.org/10.4103/ijo.IJO_1287_20.
[34] Lee YH, Kim YC, Shin JP. Characteristics of ocular manifestations of patients with coronavirus disease 2019 in Daegu province, Korea. J Kor Med Sci 2020;35:e322. https://doi.org/10.3346/jkms.2020.35.e322.
[35] Li J-PO, Lam DSC, Chen Y, Ting DSW. Novel Coronavirus disease 2019 (COVID-19): the importance of recognising possible early ocular manifestation and using protective eyewear. Br J Ophthalmol 2020;104:297–8. https://doi.org/10.1136/bjophthalmol-2020-315994.
[36] Liu W-R, Zuo G-J, Qin Y. Clinical characteristics and outcomes of 2019-nCoV-infected patients admitted at different time periods. Eur Rev Med Pharmacol Sci 2020;24:7826–33. https://doi.org/10.26355/eurrev_202007_22287.
[37] Meduri A, Oliverio GW, Mancuso G, Giuffrida A, Guarneri C, Venanzi Rullo E, et al. Ocular surface manifestation of COVID-19 and tear film analysis. Sci Rep 2020;10:20178. https://doi.org/10.1038/s41598-020-77194-9.
[38] Seah IYJ, Anderson DE, Kang AEZ, Wang L, Rao P, Young BE, et al. Assessing viral shedding and infectivity of tears in coronavirus disease 2019 (COVID-19) patients. Ophthalmology 2020;127:977–9. https://doi.org/10.1016/j.ophtha.2020.03.026.
[39] Shahriarirad R, Khodamoradi Z, Erfani A, Hosseinpour H, Ranjbar K, Emami Y, et al. Epidemiological and clinical features of 2019 novel coronavirus diseases (COVID-19) in the South of Iran. BMC Infect Dis 2020;20:427. https://doi.org/10.1186/s12879-020-05128-x.
[40] Shemer A, Einan-Lifshitz A, Itah A, Dubinsky-Pertzov B, Pras E, Hecht I. Ocular involvement in coronavirus disease 2019 (COVID-19): a clinical and molecular analysis. Int Ophthalmol 2021;41:433–40. https://doi.org/10.1007/s10792-020-01592-1.
[41] Sindhuja K, Lomi N, Asif MI, Tandon R. Clinical profile and prevalence of conjunctivitis in mild COVID-19 patients in a tertiary care COVID-19 hospital: a retrospective cross-sectional study. Indian J Ophthalmol 2020;68:1546–50. https://doi.org/10.4103/ijo.IJO_1319_20.
[42] Valente P, Iarossi G, Federici M, Petroni S, Palma P, Cotugno N, et al. Ocular manifestations and viral shedding in tears of pediatric patients with coronavirus disease 2019: a preliminary report. J Am Assoc Pediatr Ophthalmol Strabismus JAAPOS 2020;24:212–5. https://doi.org/10.1016/j.jaapos.2020.05.002.
[43] Wei Y, Zeng W, Huang X, Li J, Qiu X, Li H, et al. Clinical characteristics of 276 hospitalized patients with coronavirus disease 2019 in Zengdu District, Hubei Province: a single-center descriptive study. BMC Infect Dis 2020;20:549. https://doi.org/10.1186/s12879-020-05252-8.
[44] Wu P, Duan F, Luo C, Liu Q, Qu X, Liang L, et al. Characteristics of ocular findings of patients with coronavirus disease 2019 (COVID-19) in Hubei province, China. JAMA Ophthalmol 2020;138:575. https://doi.org/10.1001/jamaophthalmol.2020.1291.
[45] Xia J, Tong J, Liu M, Shen Y, Guo D. Evaluation of coronavirus in tears and conjunctival secretions of patients with SARS-CoV-2 infection. J Med Virol 2020;92:589–94. https://doi.org/10.1002/jmv.25725.
[46] Xie H-T, Jiang S-Y, Xu K-K, Liu X, Xu B, Wang L, et al. SARS-CoV-2 in the ocular surface of COVID-19 patients. Eye Vis Lond Engl 2020;7:23. https://doi.org/10.1186/s40662-020-00189-0.
[47] Abrishami M, Tohidinezhad F, Daneshvar R, Omidtabrizi A, Amini M, Sedaghat A, et al. Ocular manifestations of hospitalized patients with COVID-19 in Northeast of Iran. Ocul Immunol Inflamm 2020;28:739–44. https://doi.org/10.1080/09273948.2020.1773868.
[48] Arora R, Goel R, Kumar S, Chhabra M, Saxena S, Manchanda V, et al. Evaluation of SARS-CoV-2 in tears of patients with moderate to severe COVID-19. Ophthalmology 2021;128:494–503. https://doi.org/10.1016/j.ophtha.2020.08.029.
[49] Cavalleri M, Brambati M, Starace V, Capone L, Nadin F, Pederzolli M, et al. Ocular features and associated systemic findings in SARS-CoV-2 infection. Ocul Immunol Inflamm 2020;28:916–21. https://doi.org/10.1080/09273948.2020.1781198.
[50] Chen L, Deng C, Chen X, Zhang X, Chen B, Yu H, et al. Ocular manifestations and clinical characteristics of 535 cases of COVID-19 in Wuhan, China: a cross-sectional study. Acta Ophthalmol 2020;98. https://doi.org/10.1111/aos.14472.
[51] Feng Y, Park J, Zhou Y, Armenti ST, Musch DC, Mian SI. Ocular manifestations of hospitalized COVID-19 patients in a tertiary care academic medical center in the United States: a cross-sectional study. Clin Ophthalmol 2021;15:1551–6. https://doi.org/10.2147/OPTH.S301040.
[52] Gangaputra SS, Patel SN. Ocular symptoms among Nonhospitalized patients who underwent COVID-19 testing. Ophthalmology 2020;127:1425–7. https://doi.org/10.1016/j.ophtha.2020.06.037.
[53] Güemes-Villahoz N, Burgos-Blasco B, Arribi-Vilela A, Arriola-Villalobos P, Rico-Luna CM, Cuiña-Sardiña R, et al. Detecting SARS-CoV-2 RNA in conjunctival secretions: is it a valuable diagnostic method of COVID-19? J Med Virol 2021;93:383–8. https://doi.org/10.1002/jmv.26219.
[54] Pirraglia MP, Ceccarelli G, Cerini A, Visioli G, d'Ettorre G, Mastroianni CM, et al. Retinal involvement and ocular findings in COVID-19 pneumonia patients. Sci Rep 2020;10:17419. https://doi.org/10.1038/s41598-020-74446-6.
[55] Zhang X, Chen X, Chen L, Deng C, Zou X, Liu W, et al. The evidence of SARS-CoV-2 infection on ocular surface. Ocul Surf 2020;18:360–2. https://doi.org/10.1016/j.jtos.2020.03.010.
[56] Zhou Y, Duan C, Zeng Y, Tong Y, Nie Y, Yang Y, et al. Ocular findings and proportion with conjunctival SARS-COV-2 in COVID-19 patients. Ophthalmology 2020;127:982–3. https://doi.org/10.1016/j.ophtha.2020.04.028.
[57] Chen L, Liu M, Zhang Z, Qiao K, Huang T, Chen M, et al. Ocular manifestations of a hospitalised patient with confirmed 2019 novel coronavirus disease. Br J Ophthalmol 2020;104:748–51. https://doi.org/10.1136/bjophthalmol-2020-316304.
[58] Dumitrascu OM, Volod O, Bose S, Wang Y, Biousse V, Lyden PD. Acute ophthalmic artery occlusion in a COVID-19 patient on apixaban. J Stroke Cerebrovasc Dis Off J Natl Stroke Assoc 2020;29:104982. https://doi.org/10.1016/j.jstrokecerebrovasdis.2020.104982.
[59] François J, Collery AS, Hayek G, Sot M, Zaidi M, Lhuillier L, et al. Coronavirus disease 2019–associated ocular neuropathy with panuveitis: a case report. JAMA Ophthalmol 2021;139:247. https://doi.org/10.1001/jamaophthalmol.2020.5695.
[60] Gascon P, Briantais A, Bertrand E, Ramtohul P, Comet A, Beylerian M, et al. Covid-19-Associated retinopathy: a case report. Ocul Immunol Inflamm 2020;28:1293–7. https://doi.org/10.1080/09273948.2020.1825751.
[61] Lani-Louzada R, Ramos C do VF, Cordeiro RM, Sadun AA. Retinal changes in COVID-19 hospitalized cases. PLoS One 2020;15:e0243346. https://doi.org/10.1371/journal.pone.0243346.
[62] Marinho PM, Marcos AAA, Romano AC, Nascimento H, Belfort R. Retinal findings in patients with COVID-19. Lancet Lond Engl 2020;395:1610. https://doi.org/10.1016/S0140-6736(20)31014-X.
[63] Murchison AP, Sweid A, Dharia R, Theofanis TN, Tjoumakaris SI, Jabbour PM, et al. Monocular visual loss as the presenting symptom of COVID-19 infection. Clin Neurol Neurosurg 2021;201:106440. https://doi.org/10.1016/j.clineuro.2020.106440.
[64] Navel V, Chiambaretta F, Dutheil F. Haemorrhagic conjunctivitis with pseudomembranous related to SARS-CoV-2. Am J Ophthalmol Case Rep 2020:100735. https://doi.org/10.1016/j.ajoc.2020.100735.
[65] Wu P, Liang L, Chen C, Nie S. A child confirmed COVID-19 with only symptoms of conjunctivitis and eyelid dermatitis. Graefes Arch Clin Exp Ophthalmol Albrecht Von Graefes Arch Klin Exp Ophthalmol 2020;258:1565–6. https://doi.org/10.1007/s00417-020-04708-6.
[66] Barendregt JJ, Doi SA, Lee YY, Norman RE, Vos T. Meta-analysis of prevalence. J Epidemiol Community Health 2013;67:974–8. https://doi.org/10.1136/jech-2013-203104.
[67] Belser JA, Lash RR, Garg S, Tumpey TM, Maines TR. The eyes have it: influenza virus infection beyond the respiratory tract. Lancet Infect Dis 2018;18:e220–7. https://doi.org/10.1016/S1473-3099(18)30102-6.
[68] Azari AA, Barney NP. Conjunctivitis: a systematic review of diagnosis and treatment. JAMA 2013;310:1721–9. https://doi.org/10.1001/jama.2013.280318.
[69] Gangaputra SS, Patel SN. Ocular symptoms among Nonhospitalized patients who underwent COVID-19 testing. Ophthalmology 2020;127:1425–7. https://doi.org/10.1016/j.ophtha.2020.06.037.
[70] Al Wahaibi A, Al Rawahi B, Patel PK, Al Khalili S, Al Maani A, Al-Abri S. COVID-19 disease severity and mortality determinants: a large population-based analysis in Oman. Trav Med Infect Dis 2021;39:101923. https://doi.org/10.1016/j.tmaid.2020.101923.
[71] Wu J, Liu J, Li S, Peng Z, Xiao Z, Wang X, et al. Detection and analysis of nucleic acid in various biological samples of COVID-19 patients. Trav Med Infect Dis 2020;37:101673. https://doi.org/10.1016/j.tmaid.2020.101673.
[72] Creager HM, Kumar A, Zeng H, Maines TR, Tumpey TM, Belser JA. Infection and replication of influenza virus at the ocular surface. J Virol 2018;92. https://doi.org/10.1128/JVI.02192-17.
[73] Hoffmann M, Kleine-Weber H, Schroeder S, Krüger N, Herrler T, Erichsen S, et al. SARS-CoV-2 cell entry Depends on ACE2 and TMPRSS2 and is blocked by a clinically proven protease inhibitor. Cell 2020;181:271–80. https://doi.org/10.1016/j.cell.2020.02.052. e8.
[74] Collin J, Queen R, Zerti D, Dorgau B, Georgiou M, Djidrovski I, et al. Co-expression of SARS-CoV-2 entry genes in the superficial adult human conjunctival, limbal and corneal epithelium suggests an additional route of entry via the ocular surface. Ocul Surf 2021;19:190–200. https://doi.org/10.1016/j.jtos.2020.05.013.

[75] Lagier J-C, Million M, Gautret P, Colson P, Cortaredona S, Giraud-Gatineau A, et al. Outcomes of 3,737 COVID-19 patients treated with hydroxychloroquine/azithromycin and other regimens in Marseille, France: a retrospective analysis. Trav Med Infect Dis 2020;36:101791. https://doi.org/10.1016/j.tmaid.2020.101791.

[76] Lebeaux D, Revest M. No evidence of clinical benefits of early treatment of COVID-19 patients with hydroxychloroquine and azithromycin: comment on "Early treatment of COVID-19 patients with hydroxychloroquine and azithromycin: a retrospective analysis of 1061 cases in Marseille, France. Trav Med Infect Dis 2020;36:101819. https://doi.org/10.1016/j.tmaid.2020.101819.

[77] Boulware DR, Pullen MF, Bangdiwala AS, Pastick KA, Lofgren SM, Okafor EC, et al. A randomized trial of hydroxychloroquine as postexposure prophylaxis for covid-19. N Engl J Med 2020;383:517–25. https://doi.org/10.1056/NEJMoa2016638.

[78] Costedoat-Chalumeau N, Dunogué B, Leroux G, Morel N, Jallouli M, Le Guern V, et al. A critical review of the effects of hydroxychloroquine and chloroquine on the eye. Clin Rev Allergy Immunol 2015;49:317–26. https://doi.org/10.1007/s12016-015-8469-8.

[79] Ruamviboonsuk P, Lai TYY, Chang A, Lai C-C, Mieler WF, Lam DSC, et al. Chloroquine and hydroxychloroquine retinal toxicity consideration in the treatment of COVID-19. Asia-Pac J Ophthalmol Phila Pa 2020;9:85–7. https://doi.org/10.1097/APO.0000000000000289.

[80] Marmor MF, Kellner U, Lai TYY, Melles RB, Mieler WF, American Academy of Ophthalmology. Recommendations on screening for chloroquine and hydroxychloroquine retinopathy (2016 revision). Ophthalmology 2016;123:1386–94. https://doi.org/10.1016/j.ophtha.2016.01.058.

[81] Titiyal JS, Kaur M, Falera R, Bharghava A, Sah R, Sen S. Efficacy and safety of topical chloroquine in mild to moderate dry eye disease. Curr Eye Res 2019;44:1306–12. https://doi.org/10.1080/02713683.2019.1641824.

[82] Important coronavirus updates for ophthalmologists - American Academy of Ophthalmology n.d. https://www.aao.org/headline/alert-important-coronavirus-context. [Accessed 11 August 2020]. accessed.

[83] Li M, Yang Y, He T, Wei R, Shen Y, Qi T, et al. Detection of SARS-CoV-2 in the ocular surface in different phases of COVID-19 patients in Shanghai, China. Ann Transl Med 2021;9. https://doi.org/10.21037/atm-20-6026. 100–100.