Published online: 2020-07-06

Open Galeazzi's Fracture-Dislocation in a 13-Year-Old Boy: A Case Report

Valentino Coppa, MD[1] Filippo M. Senes, MD[2]

[1] Clinica di Ortopedia adulta e pediatrica, Ospedale Pediatrico Salesi, Ancona, Italy
[2] UOSD Centro Chirurgia Ricostruttiva e della Mano, IRCCS Istituto G. Gaslini—Genova, Italy

Address for correspondence Valentino Coppa, MD, Clinica di Ortopedia adulta e pediatrica, Ospedale Pediatrico Salesi, Via Corridoni 11-60123 Ancona, Italy (e-mail: coppa.valentino@ospedaliriuniti.marche.it).

J Wrist Surg 2021;10:53–57.

Abstract

Background Galeazzi's fracture-dislocation (GFD) is a rare and complex injury consisting of a radial fracture associated with distal radioulnar joint (DRUJ) dislocation.

Case Description We are presenting a case of a boy, who at the onset showed an open GFD and his assessment after a 1-year follow-up. As a treatment, closed reduction and long-arm cast were performed. At the last follow-up, the patient presented a complete recovery of range of motion and function of the affected wrist.

Literature Review To the best of our knowledge, in the current literature, there are no reported cases of open GFD.

Clinical Relevance Although open GFD is rare this case report may suggest orthopaedic surgeon how to approach and manage it.

Keywords
- open Galeazzi's fracture
- open fracture dislocation
- pediatric trauma
- pediatric distal radioulnar joint lesion

Galeazzi's fracture-dislocation (GFD) is a complex injury presenting with a radial fracture and disruption of the distal radioulnar joint (DRUJ).[1]

GFD was first described in 1822 by Cooper and is named after the Italian Orthopaedic surgeon Riccardo Galeazzi, who described a group of 18 cases in 1934.[2]

It is a relatively rare injury in children ranging from 9 to 13 years[1–3] with a reported occurrence of 3% of pediatric distal radial fractures.

The mechanism of injury is typically an axial load to the wrist with outstretched hand along with extreme forearm rotation. Supination usually leads to a volar apex fracture of the radius and volar displacement of the distal ulna, while pronation of the forearm usually causes a dorsal apex fracture of the radius along with dorsal dislocation of the distal ulna. Commonly, GFDs are classified in true GFD, when the DRUJ is disrupted and in equivalent GFD, in which separation of the distal ulnar growth plate and displacement of ulnar metaphysis occur (►**Table 1**). Classification by Walsh et al,[3] further modified by Wilkins and O'Brienranks GFD by the direction of distal radial fracture displacement and divides the GFD in two main types of injury: type I (dorsal and volar apex) and type II (volar and dorsal apex). Both types are further subdivided in relation to the radial fracture (incomplete and complete) and ulnar injury (true dislocation versus physeal fracture).[4] Letts and Rowhani classified GFD using the direction of the ulna: volar or dorsal.[5]

Acute dislocations are also classified as simple, when a reduction can be easily achieved, and complex characterized by irreducibility or unstable reduction.[6]

Closed reduction performed under sedation or general anesthesia is the treatment of choice in children. The reduction is followed by immobilization for 4 to 6 weeks, no matter if a long- or short-arm cast is made.[1,7] Surgical treatment is indicated in rare cases of complex dislocation, secondary loss of reduction, or complete fracture and displacement in adolescents, when growth plate is about to closure.[8]

We report an unusual case of open type GFD secondary to a low-energy trauma.

Case Report

A 13-year-old boy was admitted to the Emergency Department (ED) of "Giannina Gaslini" Children's Hospital of Genoa because of an acute wrist injury, which occurred after falling from a park bench.

received
March 9, 2020
accepted
April 13, 2020
published online
July 6, 2020

© 2020. Thieme. All rights reserved.
Thieme Medical Publishers, Inc.,
333 Seventh Avenue, 18th Floor,
New York, NY 10001, USA

DOI https://doi.org/10.1055/s-0040-1712515.
ISSN 2163-3916.

This document was downloaded for personal use only. Unauthorized distribution is strictly prohibited.

Table 1 Classifications of Galeazzi's fracture dislocation in children

Walsh et al[3]: Displacement of the radius and level of radial fracture
Posterior (dorsal or volar apex)
i) Within distal third
ii) At junction of distal and middle third
Anterior (volar or dorsal apex)
i) Within distal third
ii) At junction of distal and middle third
LETTS - Level of radial fractures and direction of ulnar displacement
Type A: fracture of the radius at junction of middle and distal thirds with
i) dorsal dislocation of distal ulna[a]
ii) epiphyseal fracture of distal ulna with dorsal displacement of ulnar metaphysis[b]
Type B - fracture of the distal third of the radius with
i) dorsal dislocation of distal ulna[a]
ii) epiphyseal fracture of distal ulna with dorsal displacement of ulnar metaphysis[b]
Type C: greenstick fracture of the radius with dorsal bowing and
i) dorsal dislocation of distal ulna[a]
ii) epiphyseal fracture of distal ulna with displacement of ulnar metaphysis[b]
Type D: fracture of distal radius with volar bowing and
i) vorsal dislocation of distal ulna[a]
ii) epiphyseal fracture of distal ulna with voalr displacement of ulnar metaphysis[b]
Wilkins and O'Brien[4]: displacement of the radius and type of radial fracture
Type I: dorsal (apex volar) displacement of distal radius
– Radius fracture pattern
i) Greenstick
ii) Complete
– Distal ulnar physis
i) Intact[a]
ii) Disrupted [b]
Type II: volar (apex dorsal) displacement of distal radius
– Radius fracture pattern
i) Greenstick
ii) Complete
– Distal ulna physis
i) Intact[a]
ii) Disrupted[b]

Note: The table reports classifications according to different authors and the main parameters of assessment.
[a]True Galeazzi's fracture -dislocation.
[b]Equivalent Galeazzi's fracture dislocation.

Fig. 1 (**A, B**) Clinical presentation at the emergency department with dorsal displaced radial fracture and open wound exposing the distal ulnar epiphysis on the volar side of the left wrist.

Clinical examination showed an anatomical deformity of the wrist with open wound exposing the distal ulnar epiphysis on the volar side combined with a volar apex displacement of the radius (►**Fig. 1**). X-ray performed in ED showed a complete distal radial fracture with volar displacement and disruption of DRUJ (►**Fig. 2**).

An antibiotic intravenous therapy (amoxicillin/clavulanate and gentamicin) was immediately started before the patient's admission in the operating theater. Irrigation and debridement of the wound and a closed reduction were performed under sedation. The reduction of the open dislocation was achieved by axial traction of the wrist combined with pushing on the caput ulnae to make it covered by skin. The maneuver was completed by a wrist dorsal flexion followed by a volar flexion to reduce the radial fracture. Though such maneuver, both radial fracture reduction and ulnar exposure and dislocation of the DRUJ were achieved.

Stress maneuvers showed no signs of instability while the C-arm confirmed the restoration of normal anatomical relationships. A long-arm cast in full pronation of the forearm was applied. X-ray (►**Fig. 3**) and computed tomography (CT) scan (►**Fig. 4**) were taken to assess DRUJ stability.

After 2 days of hospitalization, the patient was discharged, being observed as an outpatient in every 3 days for wound control and dressing through an opening in the cast. X-ray of the wrist and forearm in the cast were taken after 7 and 14 days to assess wrist stability. The cast was removed after 4 weeks and the patient was invited to start motion and return to daily activity, avoiding trauma and contact sports for 2 months from injury.

No wound closure complications and signs of local or systemic infection were found. The sequential X-rays showed maintenance of the reduction (►**Figs. 5** and **6**).

This document was downloaded for personal use only. Unauthorized distribution is strictly prohibited.

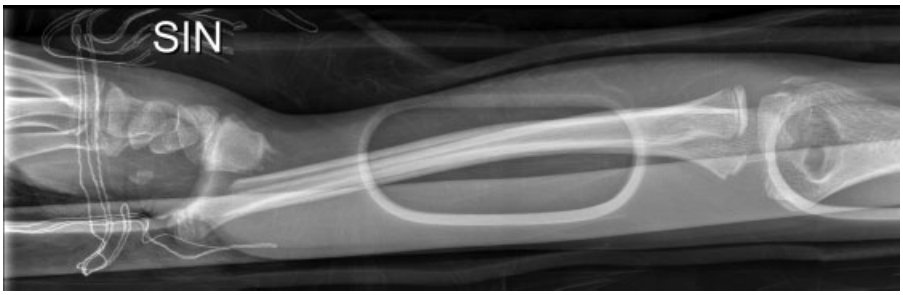

Fig. 2 The lateral view of the X-ray performed at the emergency department confirmed the dorsal radial displacement and disruption of the distal radioulnar joint.

Fig. 3 (**A**, **B**) Post-reduction X-ray showed the restoration of distal radioulnar joint and an acceptable reduction of the radial fracture.

One year after injury the patient showed a complete recovery of range of motion which was equal to the contralateral, healthy side (►**Figs. 4** and **5**) with the Mayo wrist score[9] of 100.

Discussion

GFD is an uncommon injury in children and, to best of our knowledge, this is the first report of open GFD in pediatric population.

In skeletally mature population this lesion is also known as the fracture of necessity, which refers to the need for surgical treatment to achieve optimal results. In the event of pediatric GFD, closed reduction and immobilization without surgery is the first line of treatment.[1,7]

Reduction maneuver usually consists of a traction applied on the contrary of the traumatic mechanism. After reduction, the stability of the DRUJ should be assessed under dynamic fluoroscopy. When an anatomic and stable reduction is obtained, the right position has to be maintained in a long

This document was downloaded for personal use only. Unauthorized distribution is strictly prohibited.

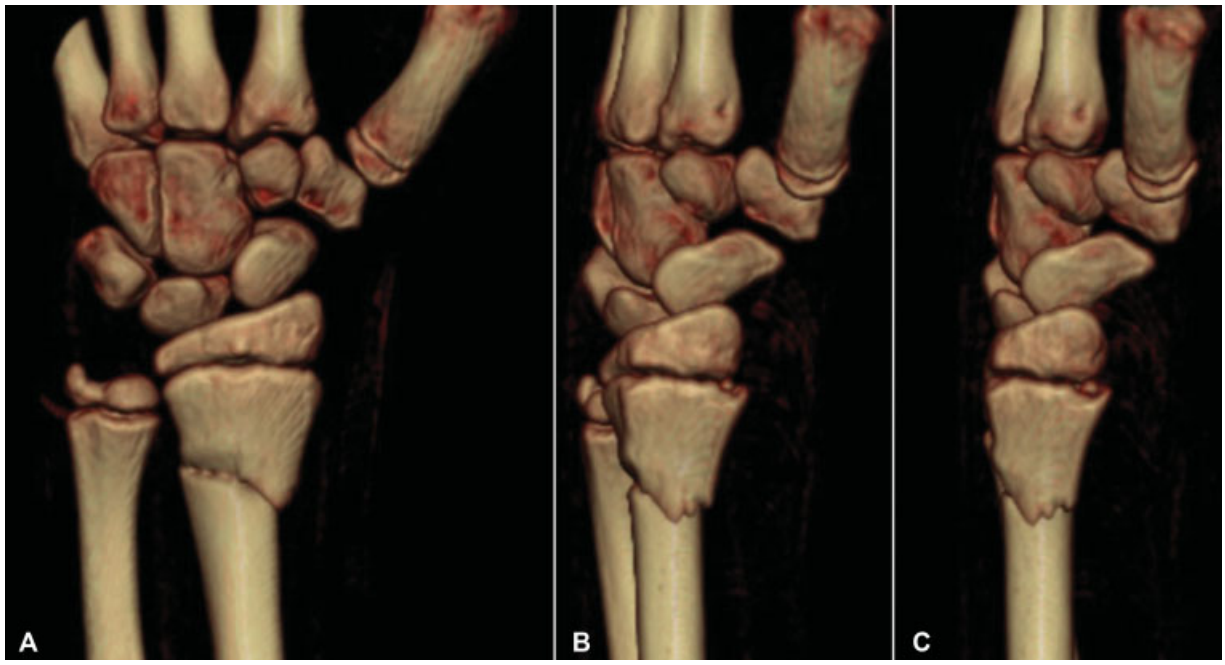

Fig. 4 (**A-C**) Post-reduction computed tomography scan with 3D reconstruction confirmed the distal radioulnar joint reduction.

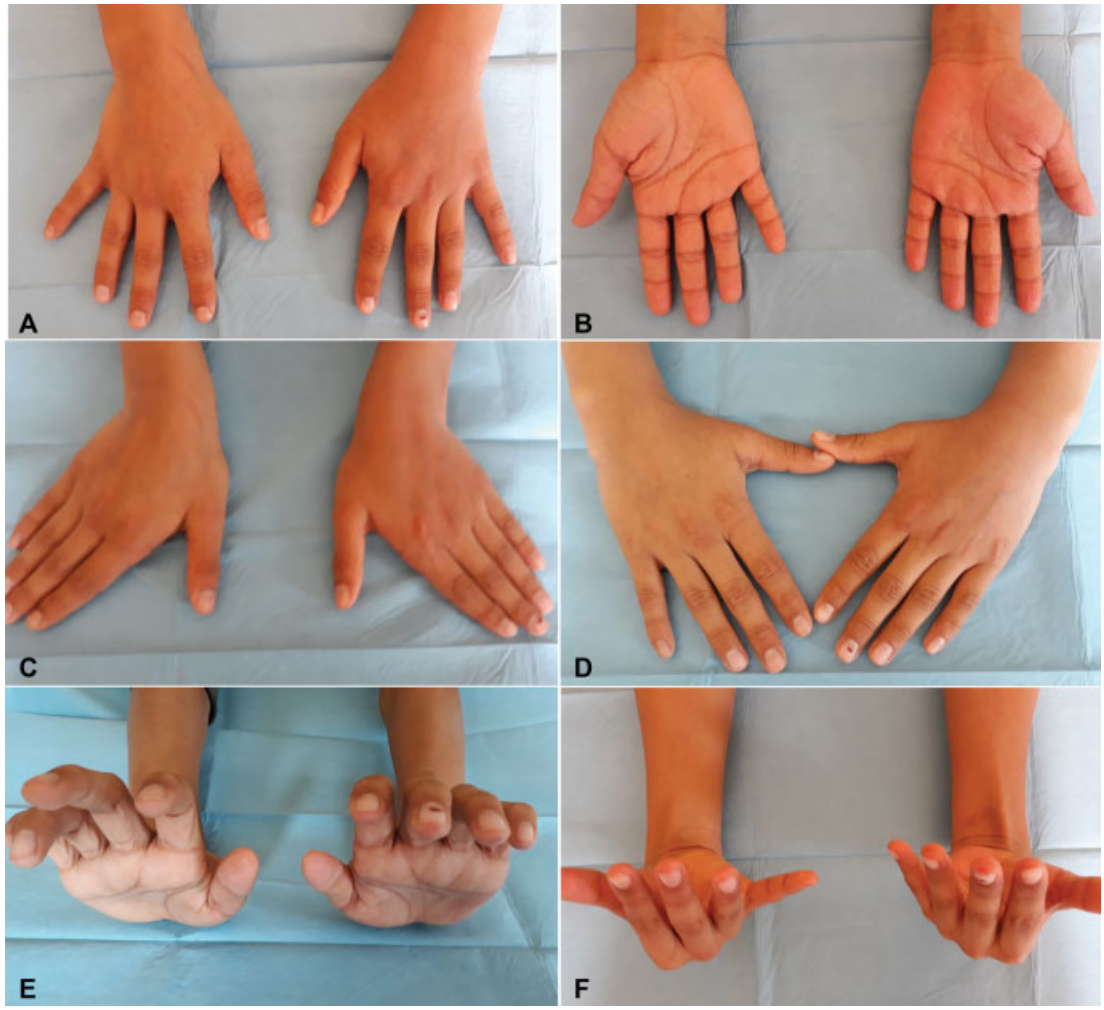

Fig. 5 (**A-F**) Clinical examination at the last follow-up showed a complete restoration of active ROM of the affected wrist compared with the normal side.

This document was downloaded for personal use only. Unauthorized distribution is strictly prohibited.

Fig. 6 (**A, B**) The X-ray at 6 months showed complete healing of the fracture without any signs of bony infection or articular joint degeneration and normal distal radioulnar joint.

cast for 4 to 6 weeks, depending on radial fracture healing. However, some Authors advocated also the efficacy of below-elbow cast.[1] In our reported case, the chosen therapeutic approach led to a good clinical and radiographic outcome.

The most important parameter of reduction is DRUJ conformation, which has to be as much reduced and stable as possible, despite of a nonanatomic reduction of radius fracture.[8] In fact, the remaining bone remodeling potential, due to both the growth plate and periosteal membrane, can compensate an incomplete reduction of distal radius fracture. DRUJ congruity and stability depend on distal ulnar alignment, so that great care should be taken into the assessment of DRUJ when accepting a nonanatomic reduction.[4]

The surgical approach should be reserved to complex GFD, when is not possible to achieve a satisfying reduction and stability or in the adolescent close to skeletal maturity.[7,10]

In the current literature, there are no indications about open GFD treatment in the pediatric population. Even though a standard treatment cannot stem from a very single case, it might hypothesize that, in the event of open GFD, the best treatment should be the one reserved to closed GFD, after reduction of the exposed and dislocated ulnar end.

Note

The study was performed at IRCCS Istituto G. Gaslini, Genova, Italy.

Conflict of Interest

None declared.

References

1 Eberl R, Singer G, Schalamon J, Petnehazy T, Hoellwarth ME. Galeazzi lesions in children and adolescents: treatment and outcome. Clin Orthop Relat Res 2008;466(07):1705–1709
2 Giannoulis FS, Sotereanos DG. Galeazzi fractures and dislocations. Hand Clin 2007;23(02):153–163, v
3 Walsh HP, McLaren CA, Owen R. Galeazzi fractures in children. J Bone Joint Surg Br 1987;69(05):730–733
4 Schoenecker JG, Bae DS. Fractures of the distal radius and ulna. In: Flynn JM, Skaggs DL, Waters PM, eds. Rockwood and Wilkins' Fractures in Children. 8th ed. Philadelphia, PA: Lippincott Williams & Wilkins; 2014:349–406
5 Letts M, Rowhani N. Galeazzi-equivalent injuries of the wrist in children. J Pediatr Orthop 1993;13(05):561–566
6 Tsai PC, Paksima N. The distal radioulnar joint. Bull NYU Hosp Jt Dis 2009;67(01):90–96
7 Atesok KI, Jupiter JB, Weiss A-PC. Galeazzi fracture. J Am Acad Orthop Surg 2011;19(10):623–633
8 Dello Russo B, Miscione HF. Delayed diagnosis and management of injuries involving the distal radioulnar joint and distal ulna in the pediatric population: recognition and conduct. J Child Orthop 2009;3(06):465–472
9 Slutsky DJ. Outcomes assessment in wrist surgery. J Wrist Surg 2013;2(01):1–4
10 Cha SM, Shin HD, Jeon JH. Long-term results of Galeazzi-equivalent injuries in adolescents–open reduction and internal fixation of the ulna. J Pediatr Orthop B 2016;25(02):174–182

This document was downloaded for personal use only. Unauthorized distribution is strictly prohibited.