Since January 2020 Elsevier has created a COVID-19 resource centre with free information in English and Mandarin on the novel coronavirus COVID-19. The COVID-19 resource centre is hosted on Elsevier Connect, the company's public news and information website.

Elsevier hereby grants permission to make all its COVID-19-related research that is available on the COVID-19 resource centre - including this research content - immediately available in PubMed Central and other publicly funded repositories, such as the WHO COVID database with rights for unrestricted research re-use and analyses in any form or by any means with acknowledgement of the original source. These permissions are granted for free by Elsevier for as long as the COVID-19 resource centre remains active.

Journal of Cardiothoracic and Vascular Anesthesia 36 (2022) 1115–1117

Contents lists available at ScienceDirect

Journal of Cardiothoracic and Vascular Anesthesia

journal homepage: www.jcvaonline.com

Case Report

Successful Management of COVID-19 With Adalimumab in a Post-Coronary Artery Bypass Graft Surgery Patient

Atefeh Fakharian*, Saghar Barati†, Monir Mohamadi‡, Farzaneh Dastan*,†,1

*Chronic Respiratory Diseases Research Center (CRDRC), National Research Institute of Tuberculosis and Lung Diseases (NRITLD), Shahid Beheshti University of Medical Sciences, Tehran, Iran

†Department of Clinical Pharmacy, School of Pharmacy, Shahid Beheshti University of Medical Sciences, Tehran, Iran

‡Nikan Hospital, Tehran, Iran

Key Words: adalimumab; Coronary Artery Bypass Graft Surgery; COVID-19

Several hypotheses and evidence suggest the role of immune system overactivity, including cytokine release syndrome, in the severity of signs, symptoms, and multiorgan failure processes in patients with coronavirus disease 2019 (COVID-19).[1,2] Studies have concluded that the elevation of TNF-α may be associated with severe cases of COVID-19.[3] TNF-α inhibitors have shown to be effective in preventing lung injury in animal models.[4] Therefore, blocking TNF-α may play a reasonable intervening role in COVID-19 disease modification.

Here the authors report a case of a 50-year-old male patient undergoing coronary artery bypass graft (CABG) surgery, with confirmed COVID-19 pneumonia, who successfully was treated with adalimumab. The control chest computed tomography (CT) scan also revealed radiologically improved lungs without any complications.

Case Report

A patient with acute myocardial infarction (fewer than 24 hours) was admitted to the authors' department on July 19, 2020. He had been a smoker for the last 15 years, and no extraordinary medical history was recorded. After he underwent coronary angiography, it was revealed that he had three-vessel disease. Thus, the patient was considered a candidate for CABG surgery. The surgery was done on July 20, 2020. During the surgery, the posterior descending artery was grafted with the saphenous vein, and the left anterior descending artery was bypassed with the left internal mammary artery. The left ventricular ejection fraction (LVEF) was 55% before the surgery.

The real-time polymerase chain reaction (RT-PCR), immunoglobulin M, and immunoglobulin G for severe acute respiratory syndrome coronavirus 2 (SARS-CoV-2) were negative, and the chest x-ray (CXR) and CT scan revealed no abnormal findings before the surgery. The surgery was successful, and the patient did not receive any blood products. The ejection fraction after the procedure was 50%. In the first 24 hours after CABG, the CXR still was normal, and the patient was alert and oriented. However, by the second day aftersurgery, the patient complained of shortness of breath, dyspnea, and dizziness, which were not modified with O_2 administration. The patient developed fever (39.1°C) and leukocytosis.

The study was supported by Shahid Beheshti University of Medical Sciences.

The study was approved by the Ethics Committee of the National Research Institute of Tuberculosis and Lung Diseases (NRITLD), Shahid Beheshti University of Medical Sciences, Tehran, Iran, with the ethics code number of IR.SBMU.NRITLD.REC.1399.154.

[1]*Address correspondence to* Farzaneh Dastan, Department of Clinical Pharmacy, School of Pharmacy, Shahid Beheshti University of Medical Sciences, Rafsanjani Highway, Valiasr Ave., Tehran 6153-14155, Iran.

E-mail address: fzh.dastan@gmail.com (F. Dastan).

https://doi.org/10.1053/j.jvca.2020.12.023
1053-0770/© 2020 Elsevier Inc. All rights reserved.

Meropenem, 1 g TDS , and vancomycin, 1 g BD, were administered for the patient as empiric therapy. Due to the COVID-19 pandemic, he also received hydroxychloroquine, 200 mg BD, and lopinavir/ritonavir (200/50 mg) two tablets BD, based on Iranian national COVID-19 guidelines. On the third day, the patient had cardiac arrest. Fortunately, cardiopulmonary resuscitation (CPR) was successful, and the patient underwent mechanical ventilation. Following the stability of the patient, chest CT imaging revealed massive involvement of the lungs. The second RT-PCR for SARS-CoV-2 confirmed COVID-19 pneumonia in the patient.

Based on the comment published in terms of the necessity of conducting trials evaluating the beneficial effects of anti-TNF-α therapy in COVID-19,[5] adalimumab (CinnoRA, CinnaGen, Iran), a fully human monoclonal anti-TNF-α antibody, was administered subcutaneously to the patient on the second day of intubation (third day postsurgery) at 40 mg. Moreover, the patient received standard of care, including oxygen and fluid support, 40 mg of pantoprazole daily for stress ulcer prophylaxis, and 40 mg of enoxaparin daily for deep vein thrombosis (DVT) prophylaxis. Meropenem and vancomycin were discontinued.

On the fourth day after intubation (fifth day after surgery), the patient was extubated with stable vital signs. The control CT scan on the same day of extubation (after stabilizing) revealed radiologically improved lungs. The O_2 saturation was increased to 96% from 88%. Respiratory rate was decreased from 32 to 23 breaths/min. White blood cells also were reduced from 19.0×10^9/L to 10.0 10^9/L. The patient became afebrile, and the cardiac medications, including metoprolol, nitroglycerin, atorvastatin, aspirin, and clopidogrel , were initiated for him. The serial CT imaging of the patient is shown in Figure 1.

Discussion

Adalimumab was shown to be an effective treatment for the management of patients with COVID-19 disease. Studies have shown that immune response management could reduce complications in COVID-19 patients.[2,6,7] TNF-α is an inflammatory cytokine involved in acute phase reaction and mostly is secreted via macrophages.[8,9] This cytokine is associated with deterioration of lung function in COVID-19 pneumonia.[10] Excessive production of TNF-α may be immunosuppressive.[11] Some experimental reports have shown that anti−TNF-α therapy is associated with disease amelioration in mice with influenza or respiratory syncytial virus (RSV).[12] Hence, medications inhibiting TNF-α may help ameliorate the inflammatory response in human lung disease. It is believed that a single dose of a TNF-α inhibitor might reduce pathologic immune response in COVID-19 via decreasing inflammatory mediators, exudate, and cellularity.[5] Some authors believe that conducting trials evaluating the beneficial effects of TNF-α seems crucial in this respect.[5]

A study showed that patients with rheumatologic disorders who were already on TNF-α inhibitors developed less-severe forms of COVID-19.[13] Tursi et al. suggested that adalimumab may be beneficial not only in improving Crohn disease symptoms, but also in treating COVID-19 in these patients.[14] Conti et al. reported the case of a patient with psoriasis who was on adalimumab therapy and did not develop COVID-19−related symptoms despite close contact with the infected patients.[15] Based on the evidence regarding the proliferation of monocytes expressing TNF-α in severe COVID-19 patients, some studies supported the use of anti−TNF-α agents in this regard.[16,17] Valent et al. reported a case of a psoriatic man on

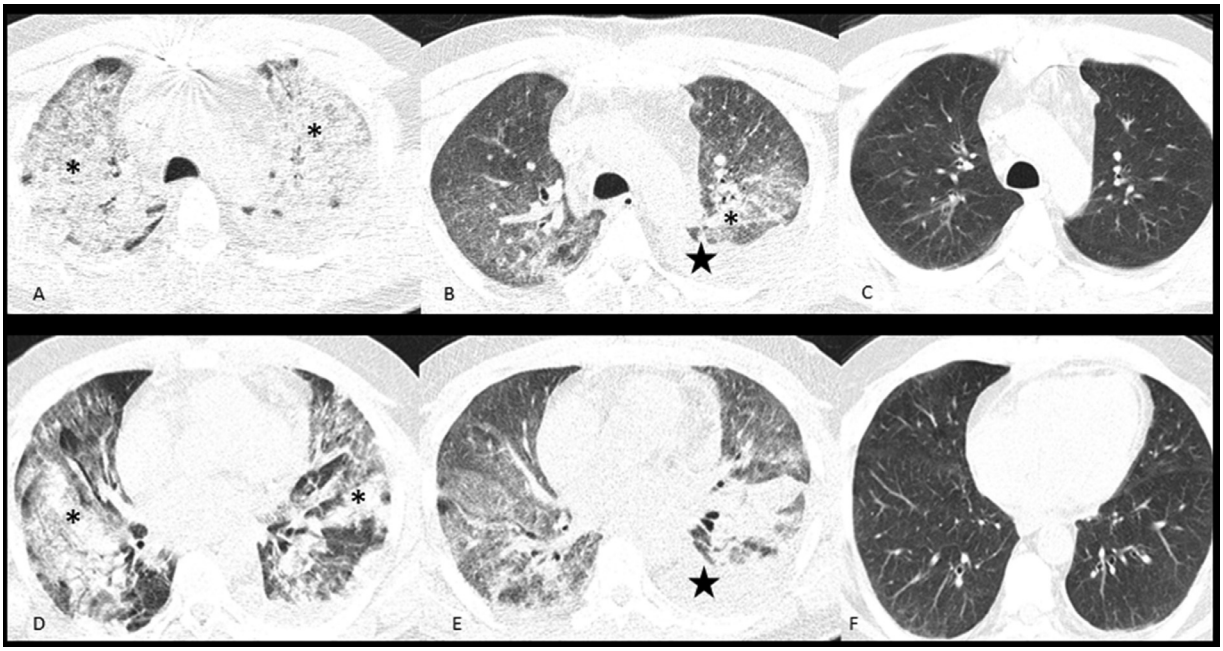

Fig 1. Review of serial computed tomography (CT) scans of a 50-year-old man with confirmed coronavirus disease 2019 bronchopneumonia: axial noncontrast CT scan of lung shows bilateral multifocal patchy area of consolidations (*) on first day of admission (A, D). Second CT scan (B, E) was performed two days after injection of adalimumab. It shows partial resolution in the previous consolidations and left-sided pleural effusion () as a result of partial response to treatment. On final CT scan images (C, F) four days after treatment, complete resolve is identified.

adalimumab therapy every two weeks for almost a year, who rapidly recovered from COVID-19. [15] The patient in the authors' department also rapidly recovered. However, he did not have a previous history of receiving adalimumab. This report's novelty lies in the speed of the effect observed on the patient and the lungs' healing. There are several anti-TNF-α agents with the same mechanisms available, including infliximab or etanercept. The authors chose adalimumab based on its potential beneficial effects reported in the literature for COVID-19 and lower risk of hypersensitivity reactions. Adalimumab was shown to be a promising agent for COVID-19 inflammation control.

There was another case report of a man who developed COVID-19 symptoms with negative RT-PCR results shortly after cardiac surgery. He received 150 mg of oseltamivir, 800 mg of hydroxychloroquine, followed by 400 mg, and 500 mg of azithromycin, followed by 250 mg daily, suggested by the Turkish Republic Ministry of Health. The patient became afebrile the third day after treatment, and the vital signs were stable by the fifth day of surgery.[18]

Another point to consider is that cardiac surgery is associated with a significant increase in some inflammatory markers, including TNF-α and high-sensitive CRP.[19,20] TNF-α is considered a mediator for the pathogenesis of myocardial infarction and may cause heart damage after surgery.[21] Moreover, it has been shown that COVID-19 is associated with cardiac complications, including changes in myocardial demand and supply leading to further myocardial infarction.[22] Hence, considering the patient's concomitant cardiac surgery and COVID-19 development, adalimumab seemed a reasonable therapeutic agent that may be beneficial for managing both heart and lung injury.

Adalimumab is a recombinant fully human IgG_1 monoclonal antibody that binds to TNF-α and inhibits its interaction with the p55 and p75 cell surface TNF receptors.[23] Some studies have shown the suppressive effects of adalimumab on C-reactive protein, IL-6, and matrix metalloproteinases (MMP-1 and MMP-3) related to tissue remodeling and matrix destruction.[23] The decrease in MMPs activities also can help to control COVID-19 tissue damage.[24] According to the current knowledge of the authors and the mentioned evidence, adalimumab may be a valuable therapeutic agent for the management of patients with COVID-19 pneumonia considering its rapid clinical responses. Further trials are needed to confirm its beneficial effects.

Conflict of Interest

The authors declare no conflict of interests.

References

1 Zhou F, Yu T, Du R, et al. Clinical course and risk factors for mortality of adult inpatients with COVID-19 in Wuhan, China: A retrospective cohort study. Lancet 2020;395:1054–62.

2 Dastan F, Saffaei A, Haseli S, et al. Promising effects of tocilizumab in COVID-19: A non-controlled, prospective clinical trial. Int Immunopharmacol 2020;88:106869.

3 Chen G, Wu D, Guo W, et al. Clinical and immunological features of severe and moderate coronavirus disease 2019. J Clin Invest 2020;130:2620–9.

4 Malaviya R, Laskin JD, Laskin DL. Anti-TNFα therapy in inflammatory lung diseases. Pharmacol Ther 2017;180:90–8.

5 Feldmann M, Maini RN, Woody JN, et al. Trials of anti-tumour necrosis factor therapy for COVID-19 are urgently needed. Lancet 2020;395:1407–9.

6 Collange O, Tacquard C, Delabranche X, et al. Coronavirus disease 2019: Associated multiple organ damage. Open Forum Infect Dis 2020;7:ofaa249.

7 Sedokani A, Feizollahzadeh S. Plasmapheresis, anti-ACE2 and anti-FcγRII monoclonal antibodies: A possible treatment for severe cases of COVID-19. Drug Des Devel Ther 2020;14:2607–11.

8 Kuppen PJ, Jonges LE, van de Velde CJ, et al. Liver and tumour tissue concentrations of TNF-alpha in cancer patients treated with TNF-alpha and melphalan by isolated liver perfusion. Br J Cancer 1997;75:1497–500.

9 Sidhu RS, Bollon AP. Tumor necrosis factor activities and cancer therapy—A perspective. Pharmacol Ther 1993;57:79–128.

10 Charles P, Elliott MJ, Davis D, et al. Regulation of cytokines, cytokine inhibitors, and acute-phase proteins following anti-TNF-alpha therapy in rheumatoid arthritis. J Immunol 1999;163:1521–8.

11 Clark J, Vagenas P, Panesar M, et al. What does tumour necrosis factor excess do to the immune system long term? Ann Rheum Dis 2005;64 (Suppl 4):iv70–6.

12 Hussell T, Pennycook A, Openshaw PJ. Inhibition of tumor necrosis factor reduces the severity of virus-specific lung immunopathology. Eur J Immunol 2001;31:2566–73.

13 Brito CA, Paiva JG, Pimentel FN, et al. COVID-19 in patients with rheumatological diseases treated with anti-TNF [e-pub ahead of print]. Ann Rheum Dis 2021. https://doi.org/10.1136/annrheumdis-2020-218171; Accessed August 2, 2020.

14 Tursi A, Angarano G, Monno L, et al. COVID-19 infection in Crohn's disease under treatment with adalimumab. Gut 2020;69:1364–5.

15 Conti A, Lasagni C, Bigi L, et al. Evolution of COVID-19 infection in 4 psoriatic patients treated with biological drugs. J Eur Acad Dermatol Venereol 2020;34:e360–1.

16 Tufan A, Avanoglu Guler A, Matucci-Cerinic M. COVID-19, immune system response, hyperinflammation and repurposing antirheumatic drugs. Turk J Med Sci 2020;50:620–32.

17 Tursi A, Vetrone LM, Papa A. Anti-TNF-α agents in inflammatory bowel disease and course of COVID-19. Inflamm Bowel Dis 2020;26:e73.

18 Çelik E, Çora AR. Treatment approach to coronavirus disease (COVID-19) seen early after open heart surgery. Case Report [e-pub ahead of print]. SN Compr Clin Med 2021. https://doi.org/10.1007/s42399-020-00377-y; Accessed August 15, 2020.

19 Javadzadegan H, Nezami N, Ghobadi K, et al. High-sensitivity C-reactive protein (hs-CRP) and tumor necrotizing factor-alpha (TNF-alpha) after on- and off-pump coronary artery bypass grafting. HSR Proc Intensive Care Cardiovasc Anesth 2010;2:27–33.

20 Abacilar F, Dogan O, Duman U, et al. The changes and effects of the plasma levels of tumor necrosis factor after coronary artery bypass surgery with cardiopulmonary bypass. Heart Surg Forum 2006;9:E703–9.

21 Tian M, Yuan Y-C, Li J-Y, et al. Tumor necrosis factor-α and its role as a mediator in myocardial infarction: A brief review. Chronic Dis Transl Med 2015;1:18–26.

22 Lang JP, Wang X, Moura FA, et al. A current review of COVID-19 for the cardiovascular specialist. Am Heart J 2020;226:29–44.

23 Scheinfeld N. Adalimumab (HUMIRA): A review. J Drugs Dermatol 2003;2:375–7.

24 Solun B, Shoenfeld Y. Inhibition of metalloproteinases in therapy for severe lung injury due to COVID-19. Med Drug Discov 2020;7:100052.