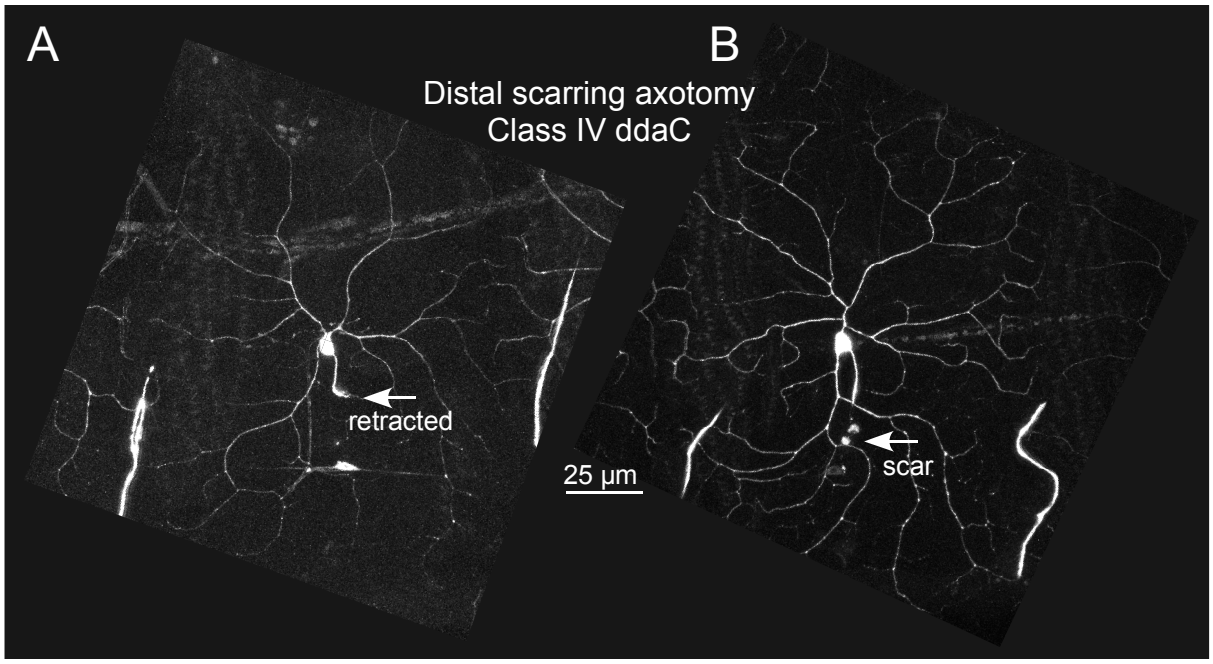
A
B
Distal scarring axotomy
Class IV ddaC
retracted
25 µm
scar