Cite as: Białek EJ, Jakubowski W:
Mistakes in ultrasound diagnosis of superficial lymph nodes.
J Ultrason 2017; 17: 59–65.

Submitted: 31.01.2016
Accepted: 12.04.2016
Published: 31.03.2017

Mistakes in ultrasound diagnosis of superficial lymph nodes

Ewa J. Białek[1], Wiesław Jakubowski[2]

[1] *Department of Diagnostic Ultrasound, Masovian Bródnowski Hospital, Warsaw, Poland*
[2] *Department of Diagnostic Imaging, Medical University of Warsaw, Poland*

Correspondence: Ewa J. Białek, Department of Diagnostic Ultrasound, Masovian Bródnowski Hospital, Kondratowicza 8, 03-242 Warsaw, Poland, tel.: +48 22 326 58 10, fax: +48 22 326 59 91, e-mail: ewa.ewa.01@gmail.com

DOI: 10.15557/JoU.2017.0008

Key words
lymph nodes, ultrasound, mistake, lesion

Abstract

The article discusses basic mistakes that can occur during ultrasound imaging of superficial lymph nodes. Ultrasound is the first imaging method used in the diseases of superficial organs and tissues, including lymph nodes. The causes of mistakes can be either dependent or independent of the performing physician. The first group of mistakes includes inappropriate interpretation of images of anatomical structures, while the latter group includes, among other things, similar ultrasound images of different pathologies. For instance, a lymph node, whether normal or abnormal, may be mimicked by anatomical structures, such as a partially visible, compressed vein. Lymph nodes in lymphomas may be indistinguishable from reactive lymph nodes, even when using Doppler option, as well as morphologically difficult to distinguish from metastases. Metastatic lymph nodes can mimic e.g. nodular, separated postoperative thyroid fragments, a lateral neck cyst, chemodectoma (carotid body tumor) or neuroma. The appearance of lymph nodes in granulomatous diseases, such as tuberculosis or sarcoidosis, can be very similar to that of typical metastatic lymph nodes or lymphomas. Anechoic or hypoechoic areas in a lymph node can represent necrosis or metastatic hemorrhages, but also suppuration in inflamed lymph nodes. Lymph nodes in lymphomas, metastatic and reactive lymph nodes can adopt the classical characteristics of a simple cyst. The overall ultrasound picture along with all criteria for the assessment of a lymph node should be taken into account during ultrasound imaging. It seems that the safest management is to refer patients diagnosed with lymph node abnormalities for ultrasound-guided targeted fine needle aspiration biopsy followed by a total lymph node resection for histopathological examination in the case of suspected lymphoma.

The causes of mistakes in ultrasonographic diagnosis of superficial lymph nodes include:

- difficult conditions of US examination (technical or patient-related);
- lack of knowledge on normal anatomy;
- lack of knowledge on US image characteristics in different lymph node conditions;
- similarity between US images in different pathologies;
- lack of knowledge on or being excessively influenced by the statistical incidence of diseases;
- missing/insufficient/incorrect medical history, clinical data, laboratory findings or conclusions from other diagnostic tests

Difficult conditions of the ultrasound examination

Ultrasound of neck lymph nodes can be significantly hindered by: a short and thick patient's neck; poor ultrasound penetration of the tissues or limited mobility of the neck causing insufficient head extension or lateral turning. Furthermore, reliable imaging can be significantly hindered or even impossible due to the lack of communication or cooperation with the patient (e.g. talking and moving during the diagnostic procedure). The clinical condition of the patient, e.g. rapid and deep breathing, can also hinder proper evaluation, Doppler measurements in particular.

© Polish Ultrasound Society. Published by Medical Communications Sp. z o.o. This is an open-access article distributed under the terms of the Creative Commons Attribution-NonCommercial-NoDerivatives License (CC BY-NC-ND). Reproduction is permitted for personal, educational, non-commercial use, provided that the original article is in whole, unmodified, and properly cited.

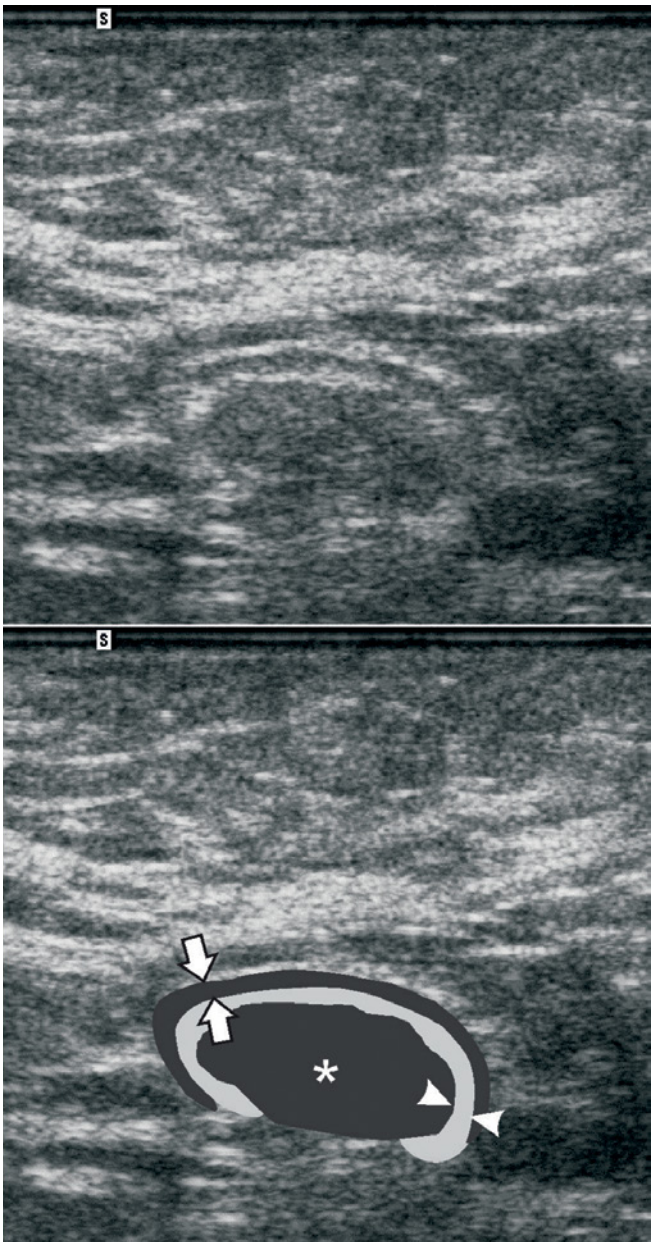

Fig. 1. *An axillary lymph node. The thin parenchymal layer is hypoechoic (arrows) and is followed by another, internal hyperechoic layer, which represents translocated connective tissue of the hilum along with blood and lymphatic vessels (arrowheads). An extensive hypoechoic area representing homogeneous fat cells with a relatively small number of vessels (arrow) is visualized centrally. The image should not be confused with a focal thickening of the parenchymal layer, which can occur in metastases and requires US guided FNAB.*

Ultrasound beam penetration may be worse in some patients. This can be due to e.g. obesity, postoperative lesions or other causes of steatosis, fibrosis and impaired tissue architecture. The available US options to improve image quality can be particularly useful in such cases[1]. Evaluation of deeper-located tissues can be impossible due to subcutaneous emphysema.

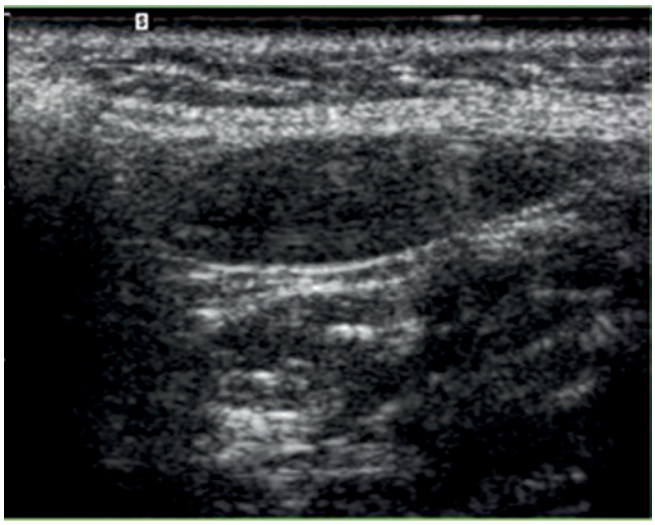

Fig. 2. *A longitudinal hypoechoic focal lesion similar in shape to a lymph node is visible in the region of the mandibular body. No hilum is visible. The compression of the tissue with the probe should be reduced (by applying more gel if needed) and the lesion should be visualized in different planes, transverse plane in particular, to avoid misdiagnosis of the suspicious lymph node. This is a segment of the facial vein compressed between the poles of the probe.*

It seems advisable to include the type of encountered difficulties in US imaging description so that the doctor responsible for referring the patient for the diagnostic procedure would be aware of potentially limited reliability of the performed scan and could recommend additional tests, such as computed tomography or magnetic resonance in the case of non-compliance with the clinical picture.

Normal anatomy

The knowledge on the course of lymphatic vessels and ducts, the location of lymph nodes as well as the junctions between them allows paying particular attention to the regions of lymph node location during ultrasound imaging. Sometimes, a change in frequency or the type of ultrasound transducer allows visualization of previously unseen pathology.

The knowledge on the areas drained by different groups of lymph nodes is useful in the differential diagnosis of lymph node diseases.

The knowledge on the details of histological and ultrasonographic correlation of normal lymph node structure increases diagnostic accuracy and the value of ultrasound. For example, axillary lymph nodes may present a specific picture due to hilar steatosis (Fig. 1). Apart from the hypoechoic crescent-shaped parenchymal layer followed by an internal hyperechoic layer representing translocated connective tissue of the hilum along with blood and lymphatic vessels, a central hypoechoic (usually large) region, which represents homogeneous fat cells with a relatively small number of vessels, can be often seen[2]. This area

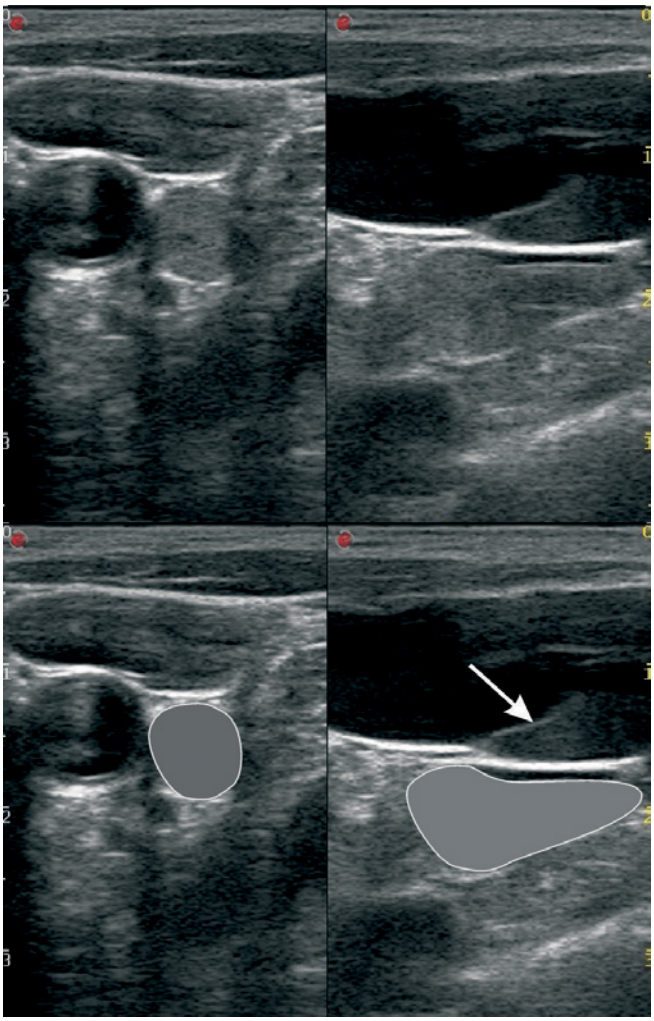

Fig. 3. *A cross-sectional (on the left) and a longitudinal (on the right) ultrasound of the region at the left base of the neck. A longitudinal, hypoechoic focal lesion (marked in grey in the lower images), which can be confused with an abnormal lymph node or other solid lesion (e.g. an enlarged thyroid gland) is visualized laterally to the common carotid artery and below the internal jugular vein. This corresponds to the branch of the internal jugular vein with erythrocyte rouleaux (visible segmentallys). Minor rouleaux can be also seen in the longitudinal view – in the internal jugular vein below the valve (arrow).*

should not be confused with a focal thickening of the parenchymal layer, which belongs to images suggestive of a metastatic focus and should be verified based on ultrasound guided fine needle aspiration biopsy (US-FNAB).

Normal anatomical structures can mimic both normal and pathological lymph nodes.

An image of a lymph node with no visible hilum

The whole neck region is characterized by the presence of many curves on a small area as well as bony structures,

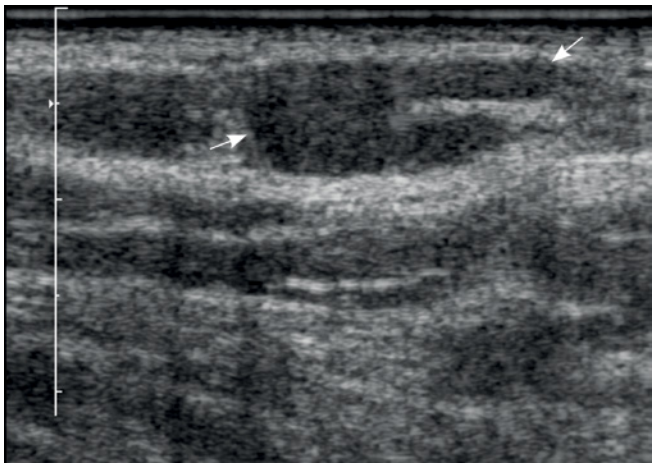

Fig. 4. *An longitudinal lymph node (arrows) with a homogeneous parenchymal layer and a maintained, undisturbed linear hyperechoic hilum – an US image of a reactive lymph node. Histopathological examination of the resected lymph node revealed a lymphocytic lymphoma.*

which can make it difficult to move the US transducer and prevent its adhesion to skin, particularly in thin, cachectic or emaciated patients. Under these conditions, one of the jugular veins, e.g. the internal jugular vein or the facial vein, can be unconsciously compressed with the transducer poles, producing an image of an abnormal lymph node with no hilum (Fig. 2). If this happens, obviously no blood flow will be observed inside the structure. It may seem hypoechogenic due to artifacts in the superficial tissues, but even if it is anechoic, a pseudocyst can be suspected (see below). The mistake can be identified simply by reducing transducer compression on the tissues, and if the transducer no longer adheres to the skin, more ultrasound gel should be applied between the transducer and the skin, and the image should be tracked in the transverse plane.

At the base of the neck, compression of the veins located in the region of the upper thoracic outlet can occur. This may lead to erythrocyte rouleau formation in the internal jugular vein or its branches, which results in a hypoechoic image of the inside of the vein, simulating solid tissue in an ultrasound image. The visualized segments of the internal jugular vein branch may, in this case, appear like an longitudinal hypoechoic or hyperechoic focal lesion with no visible internal blood flow, which can be confused with a pathological lymph node or other solid lesion, such as an enlarged parathyroid gland (Fig. 3). Different inhomogeneities or artifacts (e.g. reverberation) can suggest the presence of a hyperechoic hilum and further confirm the mistake. A change in the position of the head or an examination in a sitting position should restore normal, spontaneous blood flow in the vein and explain the mistake.

An image of a reactive lymph node

Lymph nodes in lymphomas may be indistinguishable from reactive lymph nodes in ultrasound, also with the application of color or power Doppler option (Fig. 4) [3,4].

Therefore, clinical and family history as well as information on the course of disease, e.g. lack of response to anti-inflammatory treatment or antibiotic therapy, are crucial. After excluding metastasis based on ultrasound guided fine needle aspiration biopsy (US-FNAB), a total resection of the suspected lymph node followed by histopathological examination should be performed.

Micrometastases

The overall ultrasound appearance of metastatic lymph nodes is usually abnormal: an inhomogeneous focal lesion with no hilum, with the possible presence of anechoic regions and calcifications as well as chaotic, peripheral vascular pattern. However, micrometastases cannot be excluded even in a lymph node that meets all ultrasonographic criteria for a reactive lymph node. This difficulty occurs in all imaging methods.

An image of a metastatic lymph node

Lymph nodes in lymphomas may be morphologically difficult to distinguish from metastatic lymph nodes based on ultrasound alone – e.g. they become round in shape and present chaotic or peripheral vascular pattern[3,5].

A clearly pathological appearance of an oval, inhomogenous focal lesion with the possible presence of chaotic or peripheral vascular pattern may be presented by a thyroid nodule isolated from the rest of the thyroid parenchyma after partial thyroidectomy, e.g. in a resected parenchyma of pyramidal lobe. Although a lesion found accidentally in a patient with no suspicion of cancer, which is located in the vicinity of the trachea, larynx, or above in the projection of the hypothetically possible course of the pyramidal lobe, raises less concern, it still requires US-FNAB verification. A similar lesion in a patient with known or suspected cancer is usually ultrasonographically indistinguishable from a metastatic lymph node.

Fig. 5. *Multiple enlarged lymph nodes (arrows) along the sternocleidomastoid muscle (M): oval, round and longitudinal, hypoechoic, with no clearly visible hilum. The ultrasound image is ambiguous – it could indicate lymphoma, however, metastases cannot be excluded. Final diagnosis: sarcoidosis.*

An image of a lateral cyst of the neck may be interpreted as an abnormal lymph node. Both lesions require verification based on US-FNAB, which should differentiate between them.

Carotid body tumor, presenting as an oval hypoechoic focal lesion, may be confused with an abnormal lymph node. However, its typical location within the common carotid

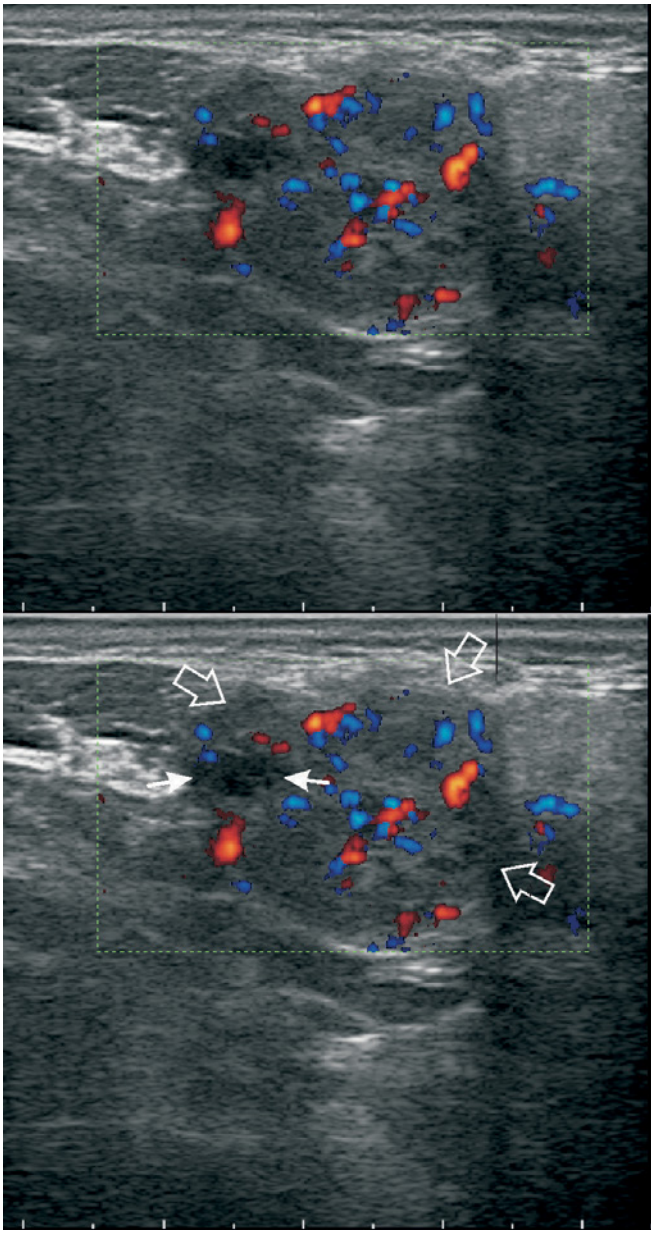

Fig. 6. *A suppurative reactive lymph node. A cross-sectional view of a lymph node (thick arrows) located near the mandible angle. Increased blood flow and anechoic area with no blood flow (thin arrows) can be seen inside the lymph node. However, if no acute clinical symptoms are present and no laboratory findings indicating acute infection are reported for this lymph node image, US-guided FNAB should be performed – with no correlation with the clinical picture, a metastatic lymph node may have the same appearance.*

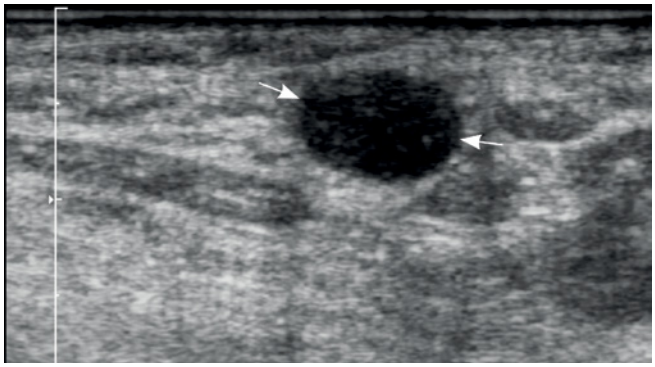

Fig. 7. *An oval, well-delineated focal lesion (arrows) with acoustic enhancement behind the posterior outline – a grey-scale ultrasound image of a simple cyst. Lymphocytic lymphoma (after histopathological examination of the totally resected lymph node).*

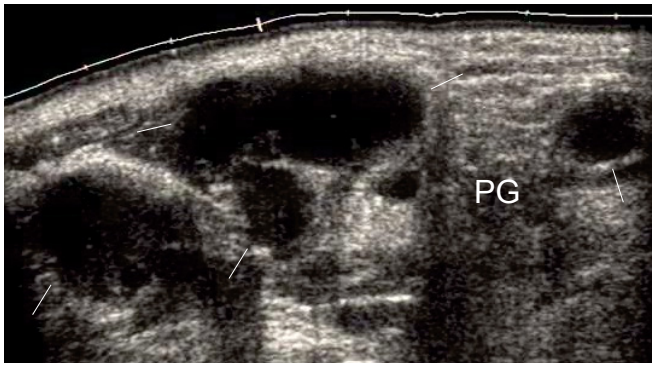

Fig. 8. *Multiple oval and polycyclic, anechoic or nearly anechoic focal lesions (arrows) in the parotid gland (PG). US-FNAB-based diagnosis: poorly differentiated cancer.*

artery bifurcation and abundant vasculature with low resistance flow should help make a proper diagnosis.

The ultrasound appearance of neuroma can also resemble a lymph node. If the lesion originates from a small nerve invisible on ultrasound, the US image may not be enough to distinguish it. Both lesions require US-FNAB, therefore the potential mistake should be revealed.

The differential diagnosis of the inguinal region should take into account other pathologies, such as inguinal hernia, postoperative lesions (e.g. hematomas) or an undescended testicle in men.

An image of metastatic lymph node or lymphoma

Lymph nodes in granulomatous diseases, such as tuberculosis or sarcoidosis, can resemble metastatic lymph nodes (i.e. include calcifications, anechoic areas, lack the hilum, show heterogeneous structure) or lymphomas (i.e. present as hypoechoic, have no clear hilum) (Fig. 5)[6]. The differential diagnosis of these conditions is particularly problematic, especially in the world regions of their common coexistence. The optimal management is to first perform US-FNAB and, depending on the findings, perform another biopsy or a total resection of the lymph node (following an exclusion of metastatic lesions) and a chest X-ray. Visualization of oval, heterogeneous focal lesions, possibly with anechoic areas and calcifications, within the neck in a patient with a primary neoplastic focus indicates high probability of metastases. In the case of accidental detection of a lesion or lesions with the above characteristics, other primary tumors that can occur in this region as well as non-neoplastic lesions and primary lymph node diseases should be considered in the differential diagnosis. Preferably, US-FNAB should be performed, together with further diagnosis aimed to search for the primary tumor.

Anechoic and/or hypoechoic lymph node areas

Inflamed lymph nodes can undergo suppuration. This results in the occurrence of irregular anechoic and/or hypoechoic areas with no features of blood flow within these lymph nodes (Fig. 6). A similar picture can be observed in necrosis and/or bleeding to metastatic lymph nodes. Clinical data and laboratory findings are therefore of key importance in the differential diagnosis. In exceptional cases, such as immunodeficiency, these data can be misleading. Suppurative lymph nodes should not be overinterpreted and considered metastatic. A follow-up ultrasound after treatment should be recommended instead, but not later than after a month. On the other hand, the diagnosis of metastasis should not be delayed by suggesting lymph node suppuration. In the case of doubts or evident metastases, US guided FNAB should be performed immediately.

Misdiagnosis of cysts (an image of a pseudocyst)

The classical characteristics of cysts can be mimicked by:
- lymph nodes in lymphomas;
- benign and malignant tumors of the salivary glands;
- metastatic lymph nodes;
- reactive lymph nodes.

Lymph nodes can mimic a simple cyst in grey-scale ultrasound, particularly in lymphomas and some types of metastases (e.g. in poorly differentiated cancers, melanoma) (Figs. 7 and 8)[4].

Lymph nodes with a misleading US picture of a simple cyst can be found not only in a typical location within the neck (e.g. in the submandibular area, along the borders of or under the sternocleidomastoid muscle, along the large neck vessels), but also in the parotid gland parenchyma. The frequency of a pseudocystic appearance of lymphomas decreases with increasing ultrasound resolution. Grey-scale ultrasound using high-frequency probes usually reveals a delicate hyperechoic network or fine punctate echoes

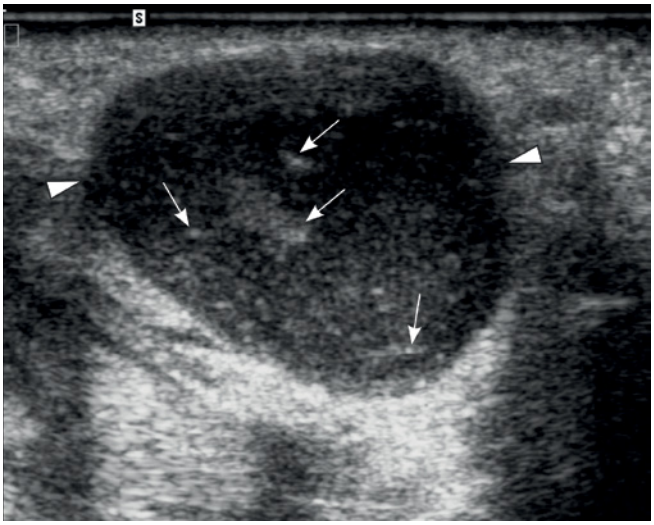

Fig. 9. *An oval, well-delineated, nearly anechoic focal lesion in the submental-submandibular region (arrowheads) with acoustic enhancement behind the posterior outline. Inside the lesion, delicate hyperechoic structures can be seen: linear, point or diffuse (examples marked with arrows). Non-Hodgkin lymphoma (histopathological diagnosis).*

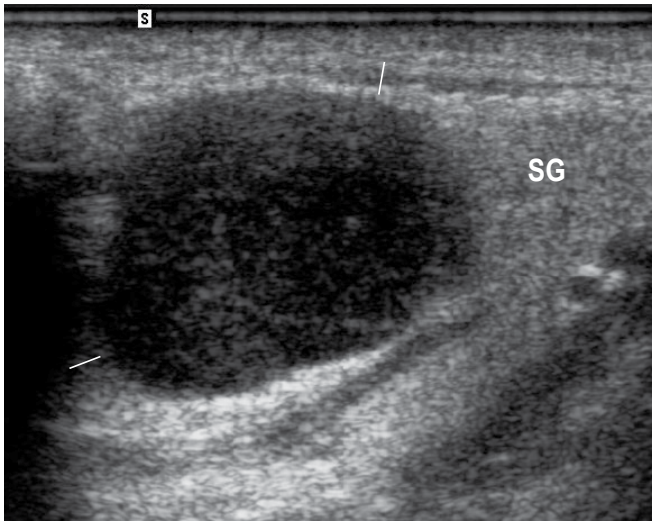

Fig. 10. *An oval, well-delineated, nearly anechoic focal lesion (arrows) with acoustic enhancement behind the posterior outline, compressing the submandibular gland (SG) parenchyma – the grey-scale image may indicate a cyst with dense contents. Non-Hodgkin lymphoma (histopathological diagnosis).*

(Fig. 9)[4,7]. A hyperechoic hilum can be absent or very narrow in lymphomas.

Reactive lymph nodes can also mimic a simple cyst in grey-scale ultrasound, similarly as lymph nodes with total central necrosis and cystic metastases, e.g. of papillary thyroid cancer, when the entire interior of the metastasis is filled with fluid, and histopathological evaluation shows that only the external layer of the cystic lining is comprised of neoplastic cells. Particular problems arise when abnormal lymph nodes are single (Fig. 10). Although this is rare, it can occur in both lymphomas and metastases.

Vasculature

Excessive compression of a lymph node with the ultrasound probe can result in the tightening of blood vessels and their insufficient visualization, making the assessment of blood flow intensity and vascular system, i.e. other elements that are essential for an overall differential diagnosis, either difficult or impossible.

Vascularization of lymphomas, similarly as their grey-scale image, can be identical or very similar to that of a reactive lymph node (see the suggested procedure in section *An image of a reactive lymph node*)[4].

A single criterion vs. complex assessment

The overall ultrasound picture and all criteria for the assessment of a lymph node should be always considered together.

Conclusions

The overall conclusion is that anyone can make a mistake in ultrasound diagnosis, even when using the highest quality ultrasound equipment. However, we should strive to reduce and, finally, eliminate errors resulting from the lack of knowledge. The need to continuously expand one's knowledge applies to everyone, regardless of the level of the already gained expertise.

Conflict of interest

Authors do not report any financial or personal links with other persons or organizations, which might negatively affect the contents of this publication and/or claim authorship rights to this publication. A financial model is constructed by our own resources from hospital researchers fund.

This paper was prepared partly based on: Białek EJ: Błędy i pomyłki w diagnostyce USG ślinianek i węzłów chłonnych położonych powierzchownie. W: Jakubowski W (red.): Błędy i pomyłki w diagnostyce ultrasonograficznej. Roztoczańska Szkoła Ultrasonografii, Warszawa – Zamość 2005: 45–58.

Piśmiennictwo

1. Białek EJ, Jakubowski W, Szczepanik AB, Maryniak RK, Prochorec-Sobieszek M, Bilski R *et al.*: Zastosowanie obrazowania harmonicznego i panoramicznego w ultrasonograficznej ocenie powierzchownych węzłów chłonnych. Ultrasonografia 2006; 27: 42–47.
2. Bedi DG, Krishnamurthy R, Krishnamurthy S, Edeiken BS, Le-Petross H, Fornage BD *et al.*: Cortical morphologic features of axillary lymph nodes as a predictor of metastasis in breast cancer: in vitro sonographic study. AJR Am J Roentgenol 2008; 191: 646–652.
3. Białek EJ, Jakubowski W, Szczepanik AB, Maryniak RK, Prochorec-Sobieszek M, Bilski R *et al.*: Vascular patterns in superficial lymphomatous lymph nodes: a detailed sonographic analysis. J Ultrasound 2007; 10: 128–134.
4. Białek EJ, Jakubowski W, Szczepanik AB, Maryniak RK, Prochorec-Sobieszek M, Bilski R: Superficial lymph nodes involved by lymphoma in modern gray-scale ultrasound imaging. Pol J Radiol 2007; 72: 30–34.
5. Tschammler A, Hahn D: Multivariate analysis of the adjustment of the colour duplex unit for the differential diagnosis of lymph node alterations. Eur Radiol 1999; 9: 1445–1450.
6. Ying M, Ahuja AT, Evans R, King W, Metreweli C: Cervical lymphadenopathy: sonographic differentiation between tuberculous nodes and nodal metastases from non-head and neck carcinomas. J Clin Ultrasound 1998; 26: 383–389.
7. Ahuja AT, Ying M, Yuen HY, Metreweli C: 'Pseudocystic' appearance of non-Hodgkin's lymphomatous nodes: an infrequent finding with high-resolution transducers. Clin Radiol 2001; 56: 111–115.