Hardware-Related Complications Following Radiocarpal Arthrodesis Using a Dorsal Plate

Stephen E. Berling, BS[1] Thomas R. Kiefhaber, MD[2] Peter J. Stern, MD[2,3]

[1] University of Cincinnati College of Medicine, Cincinnati, Ohio
[2] TriHealth Hand Surgery Specialists, Cincinnati, Ohio
[3] Department of Orthopaedic Surgery, University of Cincinnati College of Medicine, Cincinnati, Ohio

Address for correspondence Stephen E. Berling, BS, University of Cincinnati College of Medicine, CARE/Crawley Building, 3235 Eden Avenue, Cincinnati, OH 45267 (e-mail: berlinse@mail.uc.edu).

J Wrist Surg 2015;4:56–60.

Abstract

Background Hardware-related complications more than 6 months after total wrist arthrodesis are rarely reported, and controversy remains around the inclusion of the middle finger carpometacarpal joint (CMCJ) in the fusion mass.

Purpose To determine the frequency of hardware-related complications including plate fractures, screw fractures, and symptomatic plate/screw loosening, and to investigate whether failure to fuse the middle finger CMCJ contributed to these hardware complications.

Patients and Methods A retrospective chart review was designed to identify long-term hardware-related complications following 122 wrist arthrodeses using plate fixation. Patients with at least 6 months of follow-up were reviewed to determine the number of complications, the involvement of the middle finger CMCJ, and the procedures required to address these complications.

Results At a median of 2.5 years following arthrodesis (range, 6 months–19 years), 20 (16%) hardware-related complications occurred and included screw fracture ($n = 12$), plate loosening ($n = 5$), and plate fracture ($n = 3$). Thirteen (65%) of the hardware complications occurred after the CMCJ was not fused during the procedure. The CMCJ did not fuse after attempted arthrodesis in 6 additional wrists.

Conclusions Persistent middle finger CMCJ micromotion was likely present in 19/20 wrists (95%) that experienced symptomatic hardware complications. Given the occurrence of hardware failures centering on this joint, it is our recommendation that, unless one plans for routine plate removal within a given timeframe, the middle finger CMCJ must be included in the fusion mass.

Level 4 Therapeutic Case Series

Keywords
- wrist
- arthritis
- complications
- arthrodesis
- hardware
- total wrist fusion
- carpometacarpal joint

Total wrist arthrodesis is indicated for longstanding inflammatory, degenerative and/or posttraumatic conditions to provide pain relief, stability, and increased hand function that could not be attained by motion-sparing procedures.[1] Wrist arthrodesis can be performed using a 3.5-mm or 2.7/3.5-mm dorsal plate and is the treatment of choice in the presence of adequate bone stock and healthy soft tissue.[2] Current plate designs are straight or contoured and are designed to hold the wrist in 0° to 15° of extension and neutral radioulnar deviation.[3] The plate is then secured with two to four screws into the middle finger metacarpal and as many screws into the distal radius. The most common joints fused include the radioscaphoid, radiolunate, scapholunate, scaphocapitate, and lunocapitate articulations. Supplemental bone graft from the iliac crest or distal radius is commonly used.[2]

Copyright © 2015 by Thieme Medical Publishers, Inc., 333 Seventh Avenue, New York, NY 10001, USA. Tel: +1(212) 584-4662.

DOI http://dx.doi.org/10.1055/s-0034-1400069.
ISSN 2163-3916.

This document was downloaded for personal use only. Unauthorized distribution is strictly prohibited.

Dorsal plate fixation results in high fusion rates (96% to 98%) compared with older techniques, which had nonunion rates as high as 19%.[3,4] Older techniques included uninstrumented bone grafting, intrameduallary pinning with a Steinmann or Rush pin, and transarticular pinning with Kirschner wire (K-wire).[5–8] High union rates using dorsal plating have best been achieved without use in rheumatoid patients.[9] Multiple studies have shown high complication rates associated with dorsal plate fixation despite the high union rates.[3,4,10,11] Hardware complications involving plate fractures have been reported in two previous studies.[10,11] Controversy exists with regards to inclusion of the middle finger carpometacarpal joint (CMCJ) in the fusion mass and the consequences of its inclusion or omission.[2] Nagy and Büchler investigated the impact of wrist arthrodesis both with and without inclusion of the third CMCJ in the fusion mass.[11] They recommended leaving the CMCJ intact, followed by plate removal when there was a solid fusion mass. Our study was designed to investigate any adverse consequences if the middle finger CMCJ is not included in the fusion mass and the plate is left in place. We hypothesized that the risk for plate or screw failure and symptomatic hardware complications are higher if the middle finger CMC joint is not successfully fused.

The study was designed to determine the frequency of hardware-related complications including plate fractures, screw fractures, and symptomatic plate/screw loosening. The wrists would then be assessed to investigate whether failure to fuse the middle finger CMCJ contributed to these hardware complications.

Materials and Methods

Utilizing an institutional review board–approved protocol, a retrospective chart review was completed to determine the incidence of hardware-related complications related to wrist arthrodesis using dorsal plate fixation and screws. Patients treated between 1988 and 2012 were identified by searching the appropriate billing codes and text based surgical database. Indications for arthrodesis included posttraumatic arthritis (37), scapholunate advanced collapse (SLAC) wrist (31), degenerative joint disease (16), scaphoid nonunion (12), nonunion of distal radius fracture (8), Kienböck disease (5), severe wrist contractures (5), failed four-corner arthrodesis (4), cerebral palsy contractures (2), failed silicone scaphoid implant (1), and multifocal motor neuropathy (1). Exclusion criteria included crystalline arthritis, psoriatic arthritis, rheumatoid arthritis, and wrist arthrodesis following tumor resection of the distal radius and failed wrist arthroplasty. We identified 122 patients (122 wrists) who underwent wrist arthrodesis with a follow-up of at least 6-months.

The technique used for wrist arthrodesis is this case series is as follows. The radiocarpal joint is approached through an 8-cm dorsal longitudinal incision just ulnar to the Lister tubercle. The extensor pollicis longus is identified, delivered from the third dorsal compartment, and retracted radially. The wrist joint is entered through a dorsal longitudinal capsulotomy just ulnar to the extensor carpi radialis brevis. The wrist capsule is elevated subperiosteally from the radius from the tip of the radial styloid to just radial to the distal radioulnar joint. The articular surfaces of the distal radius, scaphoid, lunate, and head of capitate are denuded of eburnated bone and remaining cartilage with a combination of osteotomes, curettes, and rongeurs. The triquetrum is routinely removed to prevent ulnar abutment. The middle finger CMCJ, based on the findings in this article, is routinely arthrodesed. A proximal row carpectomy (PRC) is done at the surgeon's discretion and is indicated when there is a severe wrist flexion contracture or the proximal carpal bone stock is deficient. Once the articular surfaces have been prepared, a dorsal plate is applied. Before the early 1990s, we used a straight 3.5-mm locking plate and subsequently have used a 2.7-mm/ 3.5-mm Synthes (Synthes Corporation, Paoli, PA, USA) straight or contoured plate. The plate runs from the third metacarpal to the radius with a minimum of six cortices proximally and distally. Usually one or two screws are placed into the carpus. We prefer neutral position for the arthrodesis in both the coronal and sagittal planes. Bone graft is harvested from the radial styloid as necessary. If a large amount of graft is necessary, it is obtained from the iliac crest. The wound is closed in layers over a drain, and the wrist is immobilized in a bulky dressing and volar splint.

Long-term complications were defined as any occurring or persisting more than 6 months following arthrodesis. Records were reviewed to determine complications, and operative notes were reviewed to determine which joints at the radiocarpal, midcarpal. and CMC levels underwent formal arthrodesis. Postoperative posteroanterior (PA), lateral, and oblique radiographs were used to evaluate for nonunion, fracture of the metacarpal or radius, plate failure, and poor hardware placement. Radiographs were obtained preoperatively and postoperatively until there was X-ray evidence that the fusion mass had consolidated. Additional radiographs were not obtained the time of the review. Additionally, the number of procedures needed to address complications, including plate and screw removal, was quantified. Fisher's exact test was used for statistical analysis.

Results

Twenty long-term, hardware-related complications occurred following arthrodesis of 122 wrists (16%). These 20 complications included screw fracture ($n = 12$), plate loosening ($n = 5$), and plate fracture ($n = 3$). Sixty-seven of the 122 wrists did not have the middle finger CMCJ included in the original arthrodesis. Thirteen of 20 (65%) of the hardware complications occurred in these 67 wrists. Of the remaining 55 wrists that did undergo formal CMCJ arthrodesis, seven hardware-related complications occurred. However, upon removal of the plates, there was radiographic evidence of a nonunion at the CMCJ in six out of the seven wrists (►**Table 1**). The difference between the incidences of hardware-related complications when the middle finger CMCJ was not fused and when there was solid fusion was highly significant ($p = 0.004$). Thus, in 13/20 wrists in which there were symptomatic hardware-related complications, the middle finger CMCJ was not fused (►**Table 2**).

This document was downloaded for personal use only. Unauthorized distribution is strictly prohibited.

Table 1 Complications based on inclusion of CMCJ

Total wrists reviewed	n = 122
CMCJ arthrodesis not performed	n = 67
Number of complications when CMCJ arthrodesis not performed	n = 13
CMCJ arthrodesis performed	n = 55
Number of complications when CMCJ arthrodesis performed	n = 7
X-ray evidence of nonunion when CMCJ arthrodesis performed	n = 6

Table 2 Involvement of the third CMCJ in hardware-related complications

Complication	Occurrence	CMCJ arthrodesis performed	Nonunion following fusion attempt
Screw fracture	12	4	4
Plate fracture	3	0	N/A
Plate loosening	5	3	2

Symptomatic hardware complications presented between 6 months and 19 years after arthrodesis, with a median occurrence of 2.5 years. Of these 20 hardware complications, 12 wrists presented with one or more screw fractures at or distal to the CMCJ (range, 6 months to 8 years after surgery) (►**Fig. 1**). Three additional hardware complications included dorsal plate fractures, which presented between 12 and 19 years after arthrodesis (►**Fig. 2**). Two plate fractures occurred directly over the middle CMCJ, and one occurred over the distal radius. The plate fracture that occurred over the distal radius was at the site of a radiocarpal nonunion that required revision fusion with autogenous bone graft and replating.

The five remaining hardware complications included gradual plate loosening from the middle finger metacarpal (11 months–8 years after the original procedure). The one instance where the middle finger CMCJ was solidly fused and still resulted in symptomatic hardware-related complications was in this group. In total, hardware-related complications (screw fracture, plate loosening or fracture) required removal of 16 original plates, and in five of those plate removals a repeat fusion to include the middle finger CMCJ was performed to prevent development of pseudarthrosis due to motion at the joint. One repeat fusion also included the radiocarpal joint following radiocarpal nonunion and plate fracture (►**Table 3**).

The indications for arthrodesis of patients who had a hardware complication included posttraumatic arthritis (9), SLAC wrist (6), scaphoid nonunion (3), degenerative joint disease (1), and nonunion of distal radius fracture (1). Use of a PRC was not statistically significant between those patients who did not have the middle finger CMCJ included in the fusion mass and those

Fig. 1 PA and lateral X-ray demonstrating screw fractures distal to CMCJ 6 months after wrist arthrodesis when CMCJ was not included in fusion mass. Patient had previous PRC.

Fig. 2 PA and lateral X-ray demonstrating plate and screw fracture 19 years after failure to fuse the middle CMCJ. Patient had previous PRC.

This document was downloaded for personal use only. Unauthorized distribution is strictly prohibited.

Table 3 Additional procedures secondary to complications

Procedure	No.
Plate removals	n = 16 (13%)
Repeat fusion + plate	n = 5 (4%)
Screw removal	n = 1 (0.8%)

who did. In patients who did not have the middle finger CMCJ in the fusion mass, 12 had a prior PRC, and five had a concurrent PRC with the arthrodesis. In patients who did have the middle finger CMCJ in the fusion mass, three had a prior PRC, and four had a concurrent PRC with the arthrodesis. The type of plate used varied over time as previously described, with a transition from the straight 3.5-mm plate to the 2.7/3.5-mm Synthes wrist fusion plate (straight or contoured). The types of plates used when the middle finger CMCJ was not included in the arthrodesis can be seen in ►**Fig. 3**, and those used when the middle finger CMCJ was included can be seen in ►**Fig. 4**. There was not a significant difference between those two groups; however, there was a potential difference noted between the eight complications seen with 20 contoured AO plates and the nine complications seen in 77 straight AO plates. Additional variation in technique differed in site of bone graft, including iliac crest, distal radius, triquetrum, and proximal row.

Discussion

Wrist arthrodesis is an excellent salvage procedure; however, we found hardware-related complications (greater than 6 months after surgery) occurred frequently (16%, $n = 20$). We believe micromotion at the middle finger CMCJ contributed to hardware failure in 19/20 wrists when the plate was left in place over the long term. Because of the severity of these hardware-related complications, secondary procedures are required. In a previous study, we did not routinely fuse the middle finger CMCJ, as the senior author was not aware of future problems related to omission of fusion at this joint.[3] It was only as a result of the presentation of some of the complications and the beginning of this review that we became aware of the problem and started to fuse the middle finger CMCJ routinely. Each of the patients who presented with a hardware-related complication presented with persistent pain over the plate or screws. It is possible that this pain was due to extensor tendon irritation; however, no patient required extensor tendon repair due to hardware complications. When the patients who had pain over the hardware were revised, the middle finger CMCJ was assessed and fused to eliminate pain due to pseudarthritis at this joint without fear of loss of function. Bolano and Green showed that functional grip strength curves were similar between fused



Fig. 3 Plate type of wrist arthrodesis with dorsal plate without middle finger CMCJ included in the fusion mass.

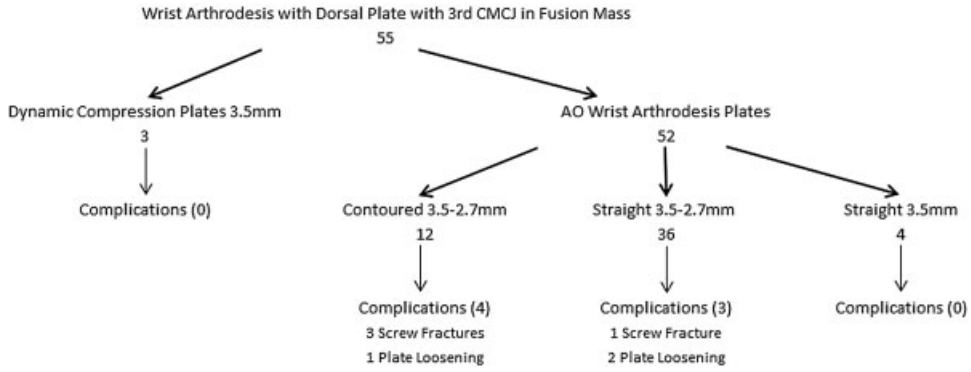

Fig. 4 Plate type of wrist arthrodesis with dorsal plate with middle finger CMCJ included in the fusion mass.

This document was downloaded for personal use only. Unauthorized distribution is strictly prohibited.

and unfused CMCJs, and patients who did not have the CMCJs fused had pain requiring an additional arthrodesis.[12]

This study has several limitations. It was retrospective and patients were not directly contacted; therefore, some complications undoubtedly were missed. In addition, over a long period of time, more complications may have been identified. For example, the three dorsal plate fractures presented between 12 and 19 years after arthrodesis. If more patients could be followed for a longer period, it is likely that a higher complication rate related to the plate and screws would have been detected. Further limitations included inability to formally assess persistent pain levels that required plate removal.

All three plate failures occurred in straight 3.5-mm dorsal plates, but it cannot be stated with any certainty that these failures would not also occur in contoured plates. Richards and coworkers showed in biomechanical testing that contoured arthrodesis plates are approximately equal in strength compared with traditional 3.5-mm dynamic compression plates, and the decision of which type of plate should be directly based on the best mechanical fit on the patient.[13] Additional time is needed to assess whether the switch to 2.7/3.5-mm AO wrist arthrodesis plates will prevent plate failures, given that the dynamic compression plates were used prior to the AO plates and given the significant amount of time required for plates to fail with motion present at the CMCJ. Additionally, both straight and contoured AO wrist arthrodesis plates were involved in screw fractures and plate loosening; the switch from dynamic compression plates to the AO wrist arthrodesis plates is unlikely to eliminate hardware complication, including plate fractures. There was statistical significance shown between AO 2.7/3.5-mm contoured and straight plates; however, much of that difference may be due to the number of patients with contoured plates who were lost to follow-up.

Houshian and Schrøder reviewed AO wrist arthrodesis with a maximum follow-up of 50 months in 42 wrists and included arthrodesis of the middle finger CMCJ.[14] They noted one nonunion at the radiocarpal joint and one nonunion of the intercarpal joint, both of which required arthrodesis revision; no plate fractures were reported. One patient had broken screws and a corresponding nonunion at the middle finger CMCJ.[14] Hastings et al retrospectively reviewed 89 patients who underwent a total wrist arthrodesis of whom 57 patients were fused with a dorsal plate.[6] Hastings included the middle finger CMCJ in the fusion mass in addition to the scaphoid–lunate–capitate and radius–scaphoid–lunate joints. The patients were followed for an average of 32 months with the minimum of 15 months, and they reported no hardware failures. Three patients (5.3%) had a painful nonunion at the middle finger carpometacarpal arthrodesis, which required a second arthrodesis at the site to relieve pain. As Hastings et al did not routinely remove the dorsal plate, they recommended fusion at the CMCJ to prevent hardware fatigue and failure.[6]

Nagy and Büchler assessed the involvement of the middle finger CMCJ in symptomatic dorsal pain following plate and screw arthrodesis in 81 wrists out of 146 consecutive procedures.[11] Because of their high plate removal rate (55%), they assessed for radiographic evidence of nonunions in wrists after plate removal. There were six instances of hardware failure out of 81 arthrodeses: four after attempted arthrodesis of the middle finger CMCJ and two after simply bridging the middle finger CMCJ. Based on their results, they strongly recommended against primary arthrodesis of the middle finger CMCJ when the implant is routinely removed.[11]

Unlike Nagy and Büchler, we do not routinely remove the plate and screws. However, based on the findings, we now recommend formal arthrodesis of the middle finger CMCJ due to the high number of symptomatic hardware-related complications in wrists where the plate has remained in place. Longevity of a plate and screw construct, we believe, is associated with successful fusion of the middle finger CMCJ. Any sign of fixation failure should lead the surgeon to consider nonunion of the middle finger CMCJ, and this complication may need to be surgically addressed with plate removal or arthrodesis of the middle finger CMCJ if a dorsal plate is reapplied.

Note
Research performed at University of Cincinnati Department of Orthopaedic Surgery.

Conflict of Interest
None

References

1 Jebson PJ, Adams BD. Wrist arthrodesis: review of current techniques. J Am Acad Orthop Surg 2001;9(1):53–60
2 Hayden RJ, Jebson PJ. Wrist arthrodesis. Hand Clin 2005;21(4): 631–640
3 Zachary SV, Stern PJ. Complications following AO/ASIF wrist arthrodesis. J Hand Surg Am 1995;20(2):339–344
4 Wysocki RW, Cohen MS. Complications of limited and total wrist arthrodesis. Hand Clin 2010;26(2):221–228
5 De Smet L, Truyen J. Arthrodesis of the wrist for osteoarthritis: outcome with a minimum follow-up of 4 years. J Hand Surg [Br] 2003;28(6):575–577
6 Hastings H II, Weiss AP, Quenzer D, Wiedeman GP, Hanington KR, Strickland JW. Arthrodesis of the wrist for post-traumatic disorders. J Bone Joint Surg Am 1996;78(6):897–902
7 Mannerfelt L, Malmsten M. Arthrodesis of the wrist in rheumatoid arthritis. A technique without external fixation. Scand J Plast Reconstr Surg 1971;5(2):124–130
8 Campbell CJ, Keokarn T. Total and subtotal arthrodesis. J Bone Joint Surg Am 1964;46:1520–1533
9 Clendenin MB, Green DP. Arthrodesis of the wrist—complications and their management. J Hand Surg Am 1981;6(3):253–257
10 Bracey DJ, McMurtry RY, Walton D. Arthrodesis in the rheumatoid hand using the AO technique. Orthop Rev 1980;9:65–69
11 Nagy L, Büchler U. AO-wrist arthrodesis: with and without arthrodesis of the third carpometacarpal joint. J Hand Surg Am 2002; 27(6):940–947
12 Bolano LE, Green DP. Wrist arthrodesis in post-traumatic arthritis: a comparison of two methods. J Hand Surg Am 1993;18(5):786–791
13 Richards RR, Patterson SD, Hearn TC. A special plate for arthrodesis of the wrist: design considerations and biomechanical testing. J Hand Surg Am 1993;18(3):476–483
14 Houshian S, Schrøder HA. Wrist arthrodesis with the AO titanium wrist fusion plate: a consecutive series of 42 cases. J Hand Surg [Br] 2001;26(4):355–359

This document was downloaded for personal use only. Unauthorized distribution is strictly prohibited.