Improvement of Functional Magnetic Resonance Imaging by a Novel Fibre-optic Device and 3D Software

T. HOELL, F. OLTMANNS, A. SCHILLING, H.M. STOCKHAUSEN, K.J. WOLF, M. BROCK

Key words: *functional MRI (fMRI), fibre-optic image transmission, 3D segmentation, localization of speech areas*

Summary

This report describes three years of clinical experience with a new set of devices aimed at improving functional MRI of speech areas. They provide a valuable tool for pre-operative definition of hemispheric localization and spatial extension of these areas, especially in left-handed persons.

The fibre-optic device described here transmits stimuli for cognitive tasks to patients undergoing MR investigations. Cognitive tasks elicit a defined brain activity lasting for several minutes. The resultant metabolic changes are detectable by functional MRI. The software (FIT ware) applied to process raw data allows semi-automated segmentation of the brain so as to obtain 3D images. Furthermore it allows the superposition of functional data. The effectiveness of the equipment was assessed on the basis of data from 140 fMRI studies. Intra-operative verification in eight patients with tumours located in the speech areas showed that the new set-up identified the speech-dominant side in each case and located speech areas in accordance with electrophysiological procedures.

Introduction

Various electrophysiological procedures, cognitive tests [1], PET studies [2], and the Wada test [3] are able to localize the speech-dominant hemisphere. With the exception of fMRI none of these techniques is universally available to the neurosurgeon.

Functional MRI [4] is a fast, reliable and inexpensive technique for localizing speech areas. It is possible to obtain satisfactory fMRI single-slice images even with older 1.5 Tesla equipment. To date, the major problem has been to convey adequate speech tasks to the patient. This problem has been solved by a fibre-optic image transmission system (figure 1).

Speech tasks traditionally used in PET studies are presented to the patient inside the scanner with the new fibre-optic image transmission system.

The software discussed in this paper allows semi-automatic rapid processing of the enormous amount of imaging data. During the last 5 years many types of software have been expected to achieve 3D imaging of the brain. Some software provides good images of the brain, but much of the segmentation work has ultimately to be done by hand. Processing of imaging data by hand, however, is too time-consuming to be suitable for clinical purposes.

Technical Description

The fibre-optic system was developed under the auspices of our department in 1993 [5]. The optical device consists of a pair of objective lenses mounted in front of a TV or computer monitor and a pair of ocular lenses mounted in front of the patient's eyes.

Conventional TV monitors or liquid crystal display are used for presentation of stimuli for cognitive tasks. The ten metre fibre length



Figure 1 A) Eyepiece (ocular) attached to the receptacle. The round red knob adjusts for individual eye distance. The optical fibre is covered by a multilayer silicon tube for protection against mechanical hazards. B) Objectives at the tip of both fibres integrated into a blue plug and ready for placement in front of a monitor. C) Optical system mounted in the head coil of an MRI scanner. Different receptacles allow fitting into all major MR scanner brands.

allows the monitor to be operated in the MR control room. This is important when working with unshielded scanners. An actively shielded scanner was chosen for this investigation, and the TV monitor was fixed at the foot of the patient's table.

Technical data on the fibre-optic tool: the fibreglass strands have a diameter of 0.8 mm. Each of them consists of 30,000 fibres. This system allows presentation of words with up to 20 letters in a row.

An eyepiece device (figures 1A, 1B) presents the images to the patient. The adjustable lens in the eyepiece device allows vision correction. The virtual angle (opening) is 20°.

The eyepiece, made entirely of glass and plastic, is mounted in front of the patient's eyes by means of a special receptacle in the head coil of the MR scanner (figure 1C). This ensures a comfortable non-contact procedure for the patient. The eyepiece device can also be integrated into the frame of a special mask for use in other imaging environments such as magneto-encephalography (MEG) or PET which has been successfully tested.

The 3D software package is based on the visualization software IDL and runs on Windows-, Mac- and Unix-based computers. The main feature is its ability to choose the best segmentation algorithm without human help.

This allows semi-automatic visualization of the brain in three dimensions without surrounding structures (segmentation). MR angiography and functional data can be superimposed.

Methods and Procedures

Once the patient had been positioned on the MRI table, the optical system was attached to the head coil of the scanner. The patient could adjust the system to achieve good vision with both eyes.

During morphological diagnostic MRI, the patient was entertained by cartoon videos. The magnetic field of the target region was homogenized to acquire better functional MR images.

While performing the functional sequence, cognitive tasks like "verb generation" or

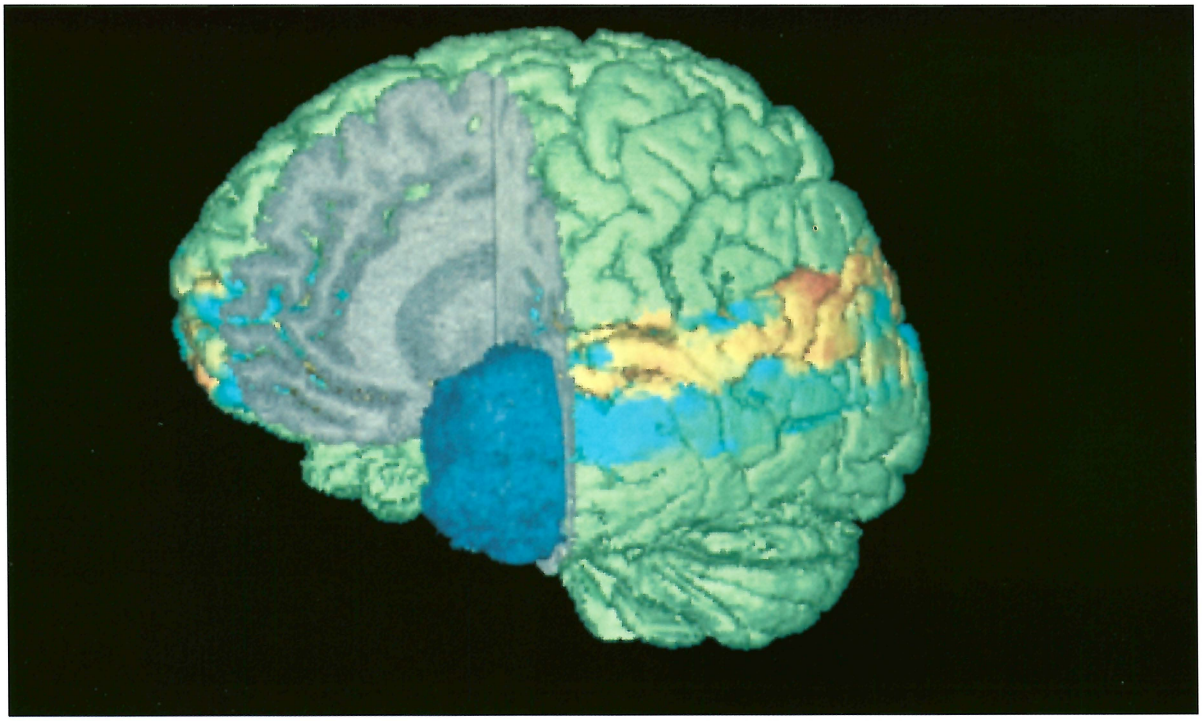

Figure 2 Morphological reconstruction (segmentation) of the MR data set. The brain surface of left and right hemisphere with functional MR data superimposed. Speech-activated areas are highlighted in orange on the right hemisphere of a left-handed patient. The blue colour indicates areas that are inversely correlated with the cognitive task.

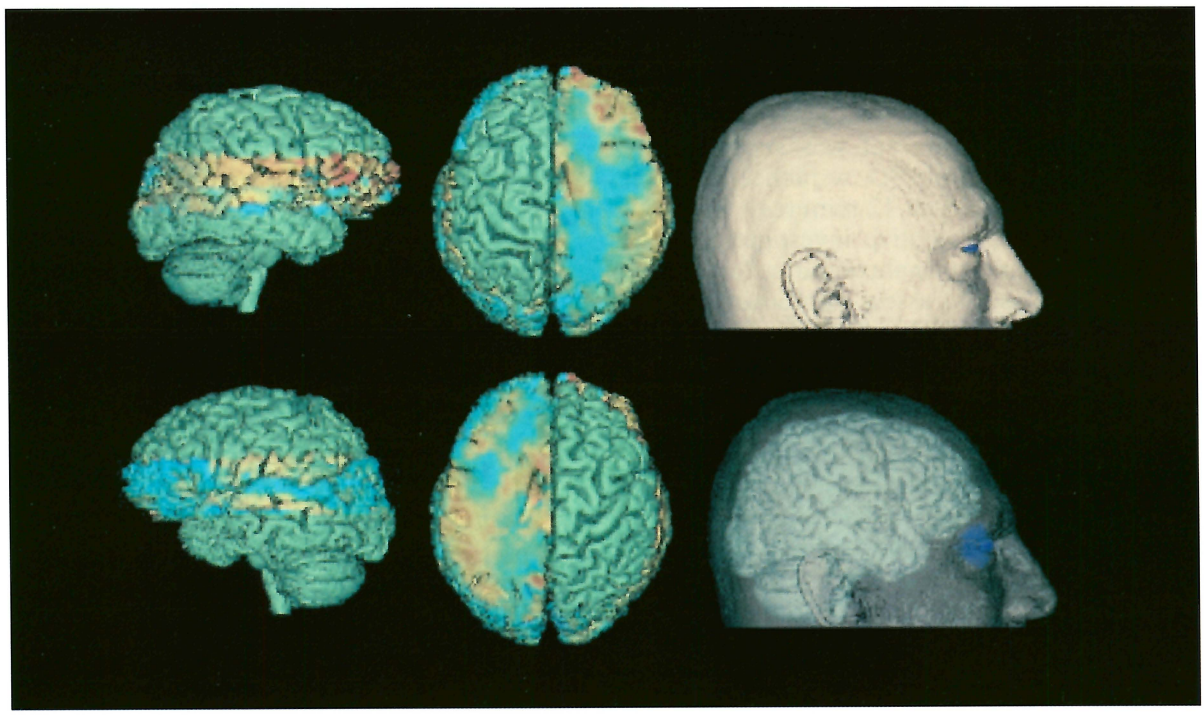

Figure 3 Functional data superimposed on the individual reconstructed brain of a patient. Virtual brain sectioning combines the functional data and the lesion site in one image.

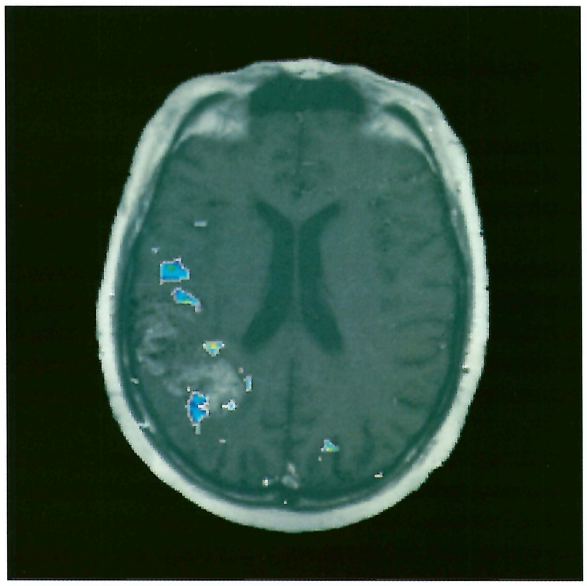

Figure 4 T1-weighted image with functional data of a speech task superimposed. This technique allows the fusion of functional information with a 2D single slice image. It is the simplest technique to perform fMRI with older scanners.

"object-naming" were presented to the patient for up to 60 seconds. New items were presented at two-second intervals. In between the trials the patients were told to relax and not to think of anything while looking at a picture of a starry sky presented to them for equivalent times. One investigation lasted six minutes. The complete functional examination took 30 minutes. The 3D data set was subsequently obtained with a flash 3D sequence in 1mm slices, which took about 12 minutes.

Data from the cognitive investigation were transferred to an external computer for further statistical analysis, to assess significant clusters in each slice. Functional and 3D data were then fused into one image (figure 4). Alternatively, functional data can be superimposed on T1-weighted anatomical MR images (figure 5). This procedure was used to obtain images of target regions to investigate, for example, the relation between eloquent areas and approach zones for neurosurgical interventions.

To obtain information on the quality and handling of the equipment, 140 investigations were assessed by a questionnaire. The validity and reliability of the functional images were evaluated by comparison with photographs of the brain surface taken during intra-operative monitoring of speech regions (figure 6).

Results

Technical Comments on the Optical System

- *Advantages*

Handling of the optical system was easy and safe. No member of the team had any difficulty. None of the components were accidentally misused.

There was no interference between the monitor and the fibre pixels. Colours were transmitted true-to-life, and suffered only a slight loss of brilliance. Movement of the fibre strands during the imaging procedure did not influence the imaging quality.

The fibre strands did not suffer any mechanical damage despite their routine application. None of the 30,000 single fibres cracked during the three-year period, and the high image quality was maintained.

Another advantage is the improvement of anatomical MR images due to the optimal positioning of the patient's head in the head coil. They do not tire, and do not skip so that movement artifacts are significantly reduced.

Only two patients had panic attacks during the examination (0.01%) versus the usual 5%. This increases patient compliance and saves time and money. Binocular vision was satisfactory in 116 patients (83%). Sufficient monocular vision was achieved by 137 patients (98%). The three patients who did not see properly had blurred vision because of either tears or make-up in their eyes and presented no information on this fact during the investigation.

- *Disadvantages*

The optical system is susceptible to destruction of its fibre strands despite its mechanical protection. Moreover the system is more expensive than mirror systems. Some patients had difficulty fusing the left and right image, and several complained about the small opening of the ocular (20°).

Technical Comments on the Software Components

- *Advantages*

The "FIT ware" 3D tool provides adequate visualization for neurosurgical purposes. Its main advantage is the essentially automatic segmentation of the brain as well as of brain tumours, AVMs and other lesions.

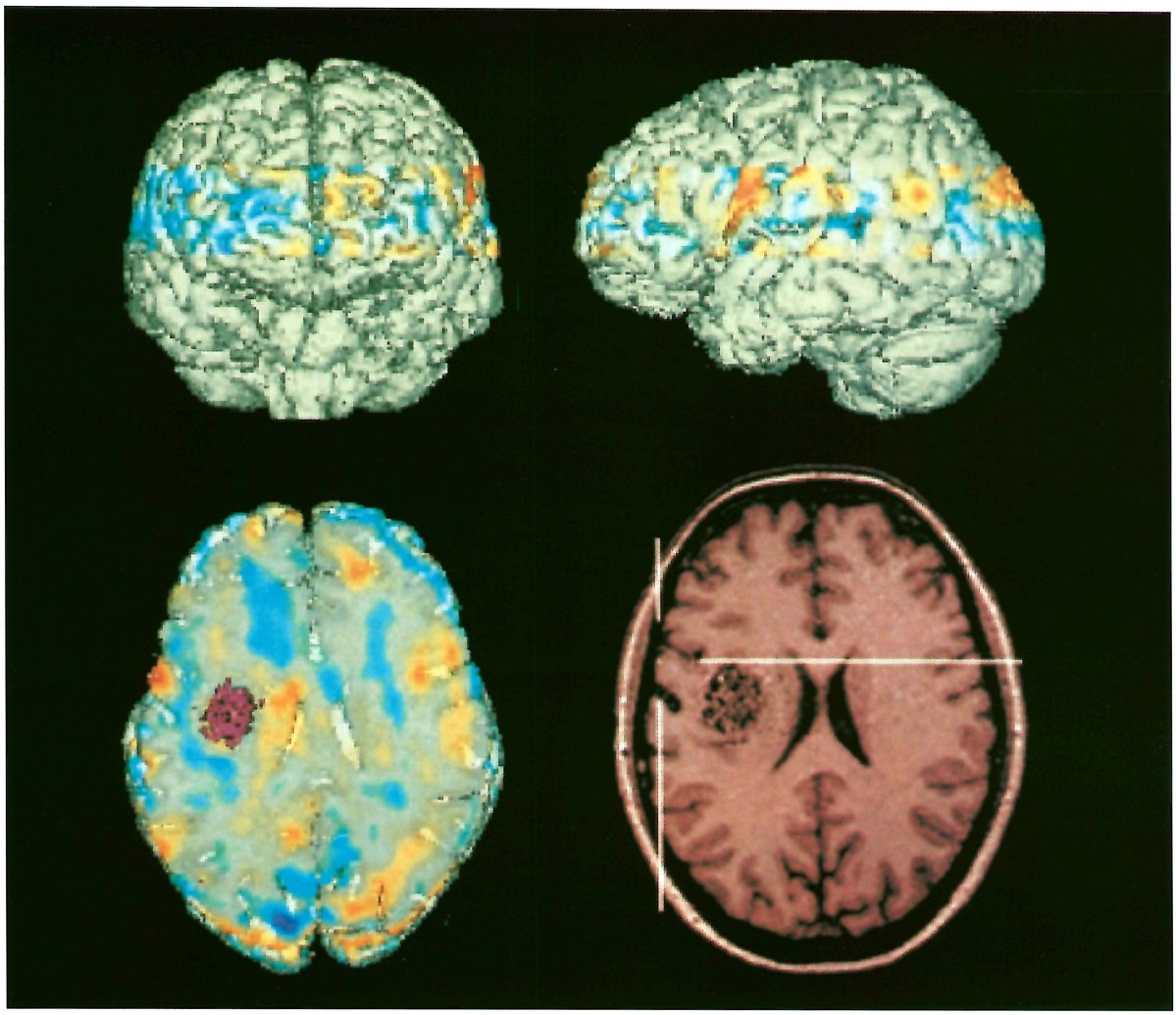

Figure 5 Top: 3D reconstruction of the left side of a patient's brain. The coloured band represents the functional data superimposed on the anatomical site. Bottom right: Photographed brain surface of the same patient. The paper tags are upside down with respect to the intra-operative situation. Yellow tags represent speech areas, blue tags show areas with no influence under electrical stimulation. Bottom left: Montage of the 3D reconstruction and picture with paper tags of the brain surface superimposed.

The segmentation quality is high with respect to spatial resolution. No inadequate rendering procedures are processed to soften the brain surface with the aim of achieving better design. This prevents sacrificing anatomical details.

The quality of the imaged brain surface is virtually identical to the intra-operative view, which has been proven with intra-operative photo documentation. The major statistical and mathematical procedures needed for processing different aspects of functional data are available. It is easy to superimpose functional on anatomical data.

- *Disadvantages*

The software requires expensive computers and additional RAM of 120MB. Transformation of raw data into arrays that can be processed by the software still takes 10 minutes of handwork.

Segmentation near the skull base is not as perfect as at the parietal and temporal brain surface. The user interface needs some hours of adjustment and accommodation to be handled without difficulty.

Another unsolved problem is the transfer of anatomic and functional data to the brain surface during surgery. A combined navigation system would be helpful.

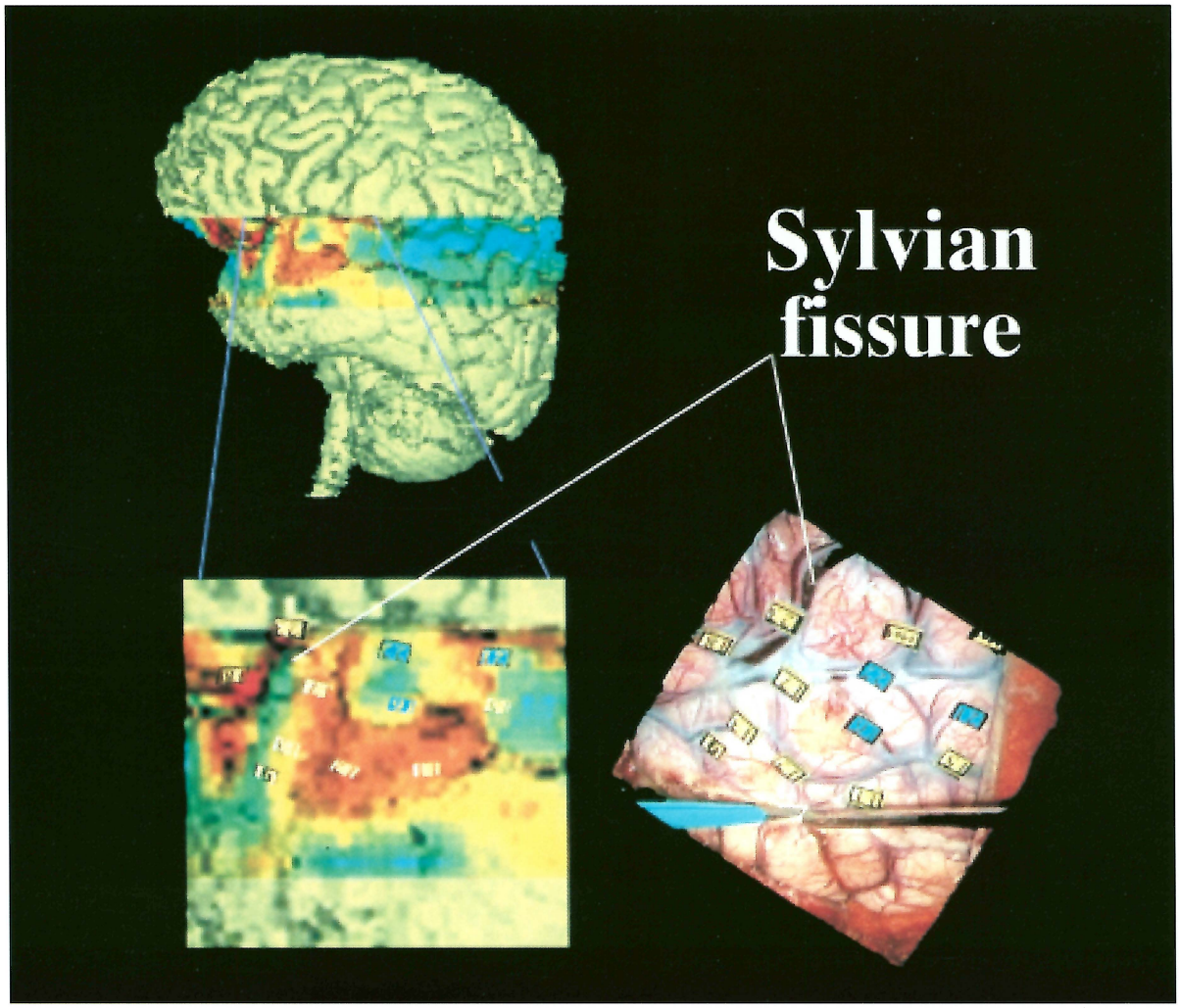

Figure 6 Top: Montage showing front and left side of a female patient's brain with a left-sided AVM. Note significant activation at the inferior frontal gyrus. This is thought to be the correlate of Broca's area. Bottom: Functional and morpholocical section of the same brain presenting the AVM.

Summary of Technical Comments

The fibre-optic system combined with 3D software is a reliable tool for localizing speech function. The main advantage is the mechanical robustness of the optical system combined with sophisticated and time-saving software.

Localization of other higher cognitive functions now only depends on the quality of the cognitive material being presented. A typical MRI for functional speech analysis takes about twice as long as anatomic investigation. It therefore costs less than a PET scan and is also cheaper than electrophysiological or excessive cognitive procedures.

Comparison of Speech Areas Determined by Functional Imaging and Intra-operative Electrophysiological Monitoring

Data-matching of intra-operative electrophysiological speech mapping with functional MRI of speech areas yielded the following results. All speech-eloquent areas identified intra-operatively were likewise identified by functional imaging. However, functional imaging with the introduced equipment identified additional territories not detected by intra-operative mapping.

Both methods identify eloquent areas with a spatial resolution of 0.5 cm. Functional MRI is

precise in predicting the motor "Broca" speech area which are usually found on Brodmann areas 44 and 45 but less reliable in predicting the localization of the Wernicke areas.

Discussion

Detection of speech areas prior to neurosurgical and interventional neuroradiological procedures is becoming a necessity. The reliability of functional MRI has been low, however, because most of the available hard and software did not meet professional criteria.

With the accession of a standardized fibre-optic system the quality and reliability of information transfer to the patient's eyes has markedly improved. Elaborate and individually adapted cognitive stimuli enable such systems to be used for functional examinations. The information contained in the data set is interpreted by software providing for 3D reconstruction of the brain and superimposition of functional information.

The high accuracy and easy handling of soft and hardware components of the system are helping to establish functional MRI as a useful and safe method in pre-operative care.

The question remains whether functional MRI with its recent improvements identifies speech regions more accurately than the amytal test of Wada. Critically considered fMRI might be less valid than a carefully performed Wada test.

However, functional imaging is the least invasive and least expensive method for obtaining information on the spatial distribution of speech-activated cortex areas.

Discussing the advantages of fMRI compared to electrophysiological intraoperative monitoring [6] it has to be mentioned first that speech investigation in awake patients is still the gold standard. It successfully detects all essential brain areas and has been doing so since the 1940s. The general problem while comparing the results of the two methods, however, is the fact that electrophysiological monitoring detects those parts of the brain essential for speech function, whereas fMRI detects all parts of the brain involved in speech production. Intra-operative experience has shown that most of the active sites detected by fMRI in Wernicke's area are not essential for speech production.

Therefore information obtained by functional imaging might lead to an overprotective less invasive approach that might reduce the quality of curative interventions.

Conclusions

With the reported improvements, it is likely that fMRI will soon be widely applied for pre-operative detection of speech-eloquent areas. This will improve the general safety of surgery. In contrast, the Wada test and intra-operative monitoring in conscious patients are rarely performed because of their higher risk and therefore have a limited impact on surgical safety.

References

1 Schmidgen H, Hoell T et Al: The "Neuropsychological Screening Test (NST)": First validation and reliability studies. Zentralblatt für Neurochirurgie 55: 185-192, 1994.

2 Herholz K, Petrzyk U et Al: Individual metabolic anatomy of repeating words demonstrated by MRI-guided positron emission tomography. Neurosci Lett 182: 47-50, 1994.

3 Wada J, Rasmussen T: Intracarotid injection of sodium amytal for the lateralization of cerebral speech dominance. Neurosurgery 17: 266-282, 1960.

4 Ogawa S, Menon R et Al: Functional brainmapping by blood oxygenation level-dependent contrast magnetic resonance imaging. Biophysical Journal 64: 803-812, 1993.

5 Hoell T, Sander M et Al: A new system for image transmission into MRI scanners for functional MRI investigation: MR-EYE. Proceedings of the 10th European Congress of Neurosurgery, Berlin 1995: 67-68.

6 Ojemann G, Ojemann J et Al: Cortical language localization in left, dominant hemisphere. An electrical stimulation mapping investigation in 117 patients. J Neurosurg 71: 316-326, 1989.