Resurfacing the Distal Radioulnar Joint with Rib Perichondrium–A Novel Method

Torbjörn Vedung, MD, PhD[1,2] Bertil Vinnars, MD, PhD[1,2]

[1] Department of Hand Surgery, Uppsala University Hospital, Uppsala, Sweden
[2] Department of Surgical Sciences, Uppsala University, Uppsala, Sweden

Address for correspondence Torbjörn Vedung, MD, PhD, Department of Hand Surgery, Uppsala University Hospital, SE-751 85 Uppsala, Sweden (e-mail: torbjorn.vedung@surgsci.uu.se).

J Wrist Surg 2014;3:206–210.

Abstract

Background Osteoarthritis in the distal radioulnar joint (DRUJ) is a challenging condition with few really reliable surgical options, particularly in young individuals. Traditional methods as hemiresection, the Darrach procedure, and the Sauvé-Kapandji procedure have less favorable results in the nonrheumatoid patient. The results after implant arthroplasty have improved, but long-term results are yet to be presented before implant arthroplasty can be recommended to young individuals with osteoarthritis in the DRUJ. An alternative method to treat osteoarthritic joints is surface replacement with free costal perichondrium. The technique has been used since the 1970s for other joints.

Case Description We adapted the method and used it in two female patients (37 and 38 years old) with nontraumatic osteoarthritis in the DRUJ. Both patients had severe pain and were unable to work. The eroded joint surfaces were resected down to bleeding subchondral cortex. Perichondrium from the seventh rib was osteo-sutured and glued to the ulnar head and the sigmoid notch.

Results The maximum follow-up-time in this retrospective review is 25 months. Our short-term results are encouraging in terms of pain relief, motion, grip strength, and return to work. The first patient had an excellent result and was completely normalized. The second patient has improved significantly and experiences only slight pain on heavy lifting and rotational load.

Clinical Relevance Free costal perichondrium may be a useful alternative for treating osteoarthritis in the DRUJ, especially in young individuals. The option for a later implant arthroplasty is preserved because most of the anatomy of the joint and all the soft tissue stabilizers are intact.

Level of Evidence Therapeutic IV, Case series

Keywords
- costal perichondrium
- Darrach
- distal radioulnar joint
- hemiresection
- implant arthroplasty
- osteoarthritis
- Sauvé-Kapandji

Historically several surgical methods have been used for treatment of the osteoarthritic distal radioulnar joint (DRUJ), particularly hemiresection and the Darrach and the Sauvé-Kapandji procedures. Less favorable results have been reported after these traditional methods in the nonrheumatoid patient. Significant problems with instability and impingement of the ulna stump against the radius may follow any of these methods.[1] Although the results after implant arthroplasty have improved, problems with instability, restricted range of motion (ROM), and implant loosening may occur. These problems are especially troublesome in the young individual with a long expected lifetime and high manual demands.

Resurfacing arthroplasty with transplantation of costal perichondrium is an alternative method for treating osteoarthritic joints.[2] Initially the method was used for the

Copyright © 2014 by Thieme Medical Publishers, Inc., 333 Seventh Avenue, New York, NY 10001, USA. Tel: +1(212) 584-4662.

DOI http://dx.doi.org/10.1055/s-0034-1384837.
ISSN 2163-3916.

This document was downloaded for personal use only. Unauthorized distribution is strictly prohibited.

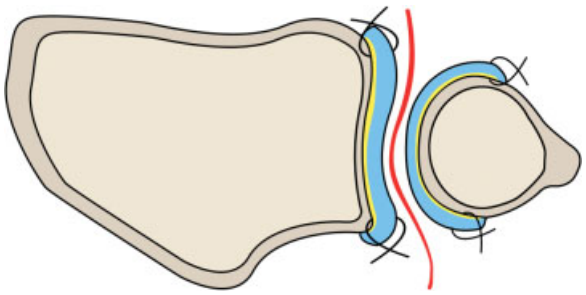

Fig. 1 Axial illustration of the DRUJ. The perichondrial grafts (blue) were secured with osteo-sutures and fibrin glue (yellow). A thin Silastic sheet (red) was temporarily positioned between the grafts to prevent adherences.

metacarpophalangeal (MCP) joint.[2] Later it was adapted to the proximal interphalangeal (PIP) joints[3] and the interphalangeal joint of the thumb.[4] The use of the technique has decreased as results after implant arthroplasty have improved. The second surgical site at the rib level may also be part of the reason why the technique is not widely used. However, perichondrial transplantation is still a reasonable alternative in selected cases, such as young individuals with high manual demands. The method is used regularly at our unit to resurface the osteoarthritic MCP joint in such patients.

Surgical Technique

The DRUJ is opened both dorsally and volarly. The volar approach is performed through a straight incision parallel to the flexor carpi ulnaris (FCU) tendon. The FCU tendon and the ulnar nerve and artery are carefully retracted ulnarly, whereas the finger flexors are drawn radially. The capsule of the DRUJ is incised longitudinally, and the eroded cartilage is exposed. Care is taken not to incise and retract more then necessary of the distal part of the pronator quadrator muscle. The dorsal approach is performed through a zigzag skin incision. The fifth extensor compartment is opened, and the extensor digiti minimi is retracted radially. The floor of the fifth extensor compartment is incised, and the sixth extensor compartment is retracted *en bloc* in the ulnar direction in a subperiosteal fashion. The triangular fibrocartilage complex (TFCC) is identified both volarly and dorsally and carefully spared. The eroded joint surfaces are resected with an air-driven oscillating chisel with careful preservation of the anatomical contours. A thin layer of the subchondral cortex is left in place to give the new joint surface a stable ground to attach to. After the preparation, both recipient sites consist of well-vascularized and stable subchondral bone. Through an incision in the sub-mammary crease, the seventh thoracic rib is identified between the pectoralis major and the abdominal muscles. Fibers and fascia of the rectus abdominis muscle are divided transversely, and the anterior surface of the cartilaginous part of the rib is exposed. The osteochondral junction is easily identified as a slightly elevated rim in the mid-clavicular line. The perichondrium is incised along the borders of the rib and peeled off the cartilage with a blunt dissector, from the osteochondral junction to the sternum. Care is taken not to include any underlying cartilage. After hemostasis the donor site is closed. The graft is divided in two pieces: one for the sigmoid notch and a slightly longer part to be wrapped around the ulnar head. The inner layer of the perichondrium, the cambium layer, which is considered to have the best chondrogenic potential, is turned toward the joint space. Both grafts are sutured through drill holes in the bone both volarly and dorsally (►**Figs. 1**, **2**). Before the second row of sutures is tightened, fibrin glue (TISSEEL, Baxter Healthcare Corporation, Westlake, CA, USA) is deposited under each graft (►**Fig. 2**). A thin Silastic sheet (0.5 mm, Atos Medical AB, Hörby, Sweden) is positioned between the two surfaces to prevent adherences,[3] and the forearm and elbow is immobilized with a long cast. Forearm rotation is initiated after 4 weeks, employing a protective splint in between exercises. The Silastic sheet is removed 2 months postoperative through a small incision in the scar (we did so volarly in case 1 and dorsally in case 2). Great care is taken to minimize the soft tissue trauma to avoid unnecessary immobilization and additional scarring.

Case 1

A right-handed 38-year-old woman with nontraumatic osteoarthritis of her right DRUJ and severe pain on forearm rotation was admitted to our unit (►**Fig. 3a**). There was no history of rheumatoid arthritis or any other autoimmune joint disease. The symptoms started at the age of 20 with a gradual

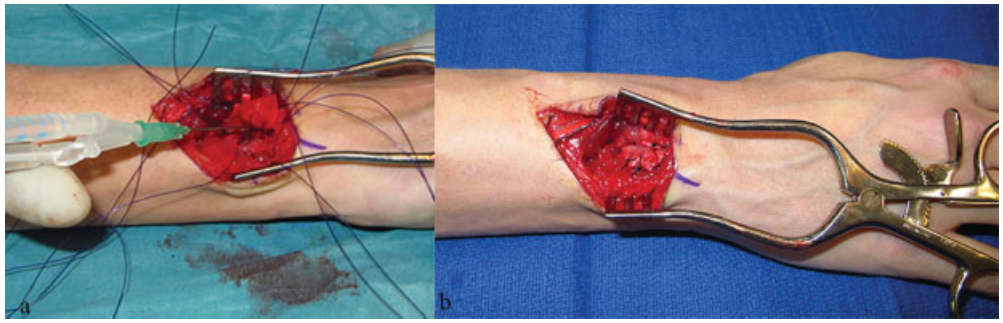

Fig. 2 (**a**) Fibrin glue was deposited under each graft before the second row of sutures was tightened. (**b**) The tight relation between the perichondrial grafts is illustrated on the right panel.

This document was downloaded for personal use only. Unauthorized distribution is strictly prohibited.

Fig. 3 Posteroanterior (PA) radiographs of the wrist. The preoperative images on the left are showing osteoarthritis in the DRUJ in case 1 (**a**) and case 2 (**d**). The postoperative radiographs in the middle display a gap in the joint occupied by the perichondrial grafts, in case 1 (**b**) and case 2 (**e**). Radiography, 30 months postoperative in case 1 (**c**) and at the 12-month follow-up in case 2 (**f**) indicates some bone resorption and remodeling over time.

increase in severity over time. The ulna was ~3.8 mm shorter than the radius, and the sigmoid notch had a relative ulnar angulation toward and slightly over the distal end of the ulnar head. The articulation of the ulnar head against the radius was almost proximal to the sigmoid notch (►**Fig. 3a**). The contralateral (left) side had a 3.4-mm short ulna and a sigmoid notch with normal appearance. Forearm rotation was decreased ~40 degrees as compared with the contralateral side (►**Table 1**). The ROM in the wrist was normal. Rotational stress caused severe pain, graded as 9 on the visual analog scale (VAS). The TFCC was found to be competent. Plain radiographs showed osteoarthritic changes in the DRUJ (►**Fig. 3a**). Magnetic resonance imaging (MRI) revealed signs of impingement between the ulnar head and the radius proximal to the malformed sigmoid notch (►**Fig. 4a**).

Conservative treatment had failed. Supportive splints restraining forearm rotation was insufficient and nonsteroidal anti-inflammatory drugs (NSAIDs) gave no pain relief. As a result of the pain the patient was unable to work (nurse).

Postoperative radiographs showed a ~6-mm-wide joint space in the DRUJ with no signs of ulnar impingement versus the preoperative films (►**Fig. 3b**). The outcomes are listed in ►**Table 1**. At the one-year-follow up, ROM was normal, and the DRUJ was stable and pain-free (VAS 0). The grip strength had increased to 38 kg, and the Quick DASH (Disabilities of the Arm, Shoulder, and Hand) score was 4. Similar figures were obtained at the 2-year follow-up (►**Table 1**). Fifteen months postoperative, MRI indicated thick perichondrial grafts on both sides of the joint and an intact TFCC (►**Fig. 4b**). Radiography 30 months postoperative revealed some bone resorption but also remodeling over time (►**Fig. 3c**).

Case 2

The second case had many similarities with the first one. A right-handed 37-year-old woman with no history of any previous trauma to the right wrist presented with pain on forearm rotation. No history of autoimmune joint disease was found. The symptoms in her right DRUJ started about 2 years

This document was downloaded for personal use only. Unauthorized distribution is strictly prohibited.

Table 1 Table and control with pre- and postoperative range of motion, grip strength and subjective evaluations at different time points

Case	Motion/ Strenght/Pain	Preoperative	6 weeks postop	4 months postop	12 months postop	25 months postop	Contra lateral side
1	Supination	70	70	90	90	90	90
1	Pronation	50	60	75	75	80	70
1	Flexion	70	65	65	75	75	75
1	Extension	75	65	65	75	75	75
1	JAMAR (kg)[a]	36	–	32	38	36	30
1	VAS	9	7	3	0	0	0
1	Quick DASH	77	95	75	4	0	0
2	Supination	70	25	30	40	–	80
2	Pronation	70	40	75	80	–	70
2	Flexion	75	20	55	70	–	75
2	Extension	60	30	50	75	–	70
2	JAMAR (kg)[a]	26	–	–	27	–	30
2	VAS	9	7	5	3	–	0
2	Quick DASH	77	75	66	23	–	0

Abbreviations: VAS, visual analog scale for pain; DASH, Disabilities of the Arm, Shoulder, and Hand.
[a]JAMAR, Sammons Preston Inc., Bolingbrook, IL, USA, average of three consecutive measurements

prior to admittance and had increased gradually. Rotational load and stress caused intense pain (VAS 9), and the DRUJ had been almost locked a few times. The ulna was ~4 mm shorter than the radius, and the sigmoid notch was angulated ulnarly and slightly over the top of the ulnar head (►**Fig. 3d**). On the pain-free left side the forearm bones had equal length and the sigmoid notch had normal appearance. The ROM in the wrist was slightly decreased (►**Table 1**). MRI confirmed osteoarthritis in the right DRUJ. The TFCC was intact. Two intra-articular steroid injections had been given prior to admittance without effect. Non-steroid-anti-inflammatory-drugs and supportive splints were insufficient. The symptoms caused inability to work (nurse assistant).

Postoperative radiographs showed a ~5-mm-wide gap in the DRUJ with no signs of ulnar impingement vs the preoperative X-rays (►**Fig. 3e**). The outcomes are listed in ►**Table 1**. It is of note, however, that supination was only 40 degrees, as compared with a preoperative value of 70 degrees. Pain was felt only on heavy lifting and rotational load (VAS 3). The Quick DASH score had improved to 23. The patient was completely satisfied with the result. Radiography showed similar findings as in case 1 (►**Fig. 3f**).

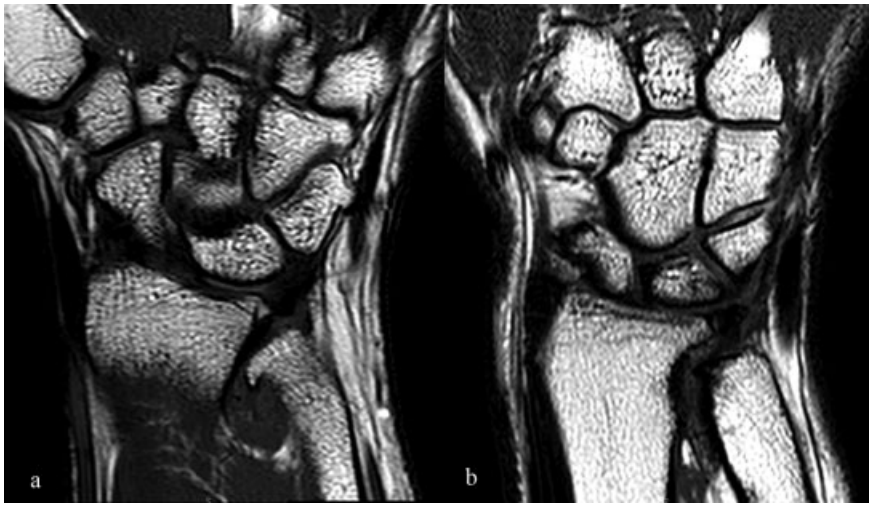

Fig. 4 Case 1. (**a**) PA, preoperative MRI image revealing osteoarthritis in the DRUJ. (**b**) MRI fifteen months postoperative indicating thick perichondrial grafts in the joint and an intact TFCC.

This document was downloaded for personal use only. Unauthorized distribution is strictly prohibited.

Discussion

Osteoarthritis in the DRUJ represents a challenging problem with limited surgical options, especially in the young individual. We present a novel method for reconstructing the DRUJ surfaces with perichondrial graft from the rib. Although our experience with the technique is limited to only two cases with short-term follow-up, the results are promising.

Acknowledgment
This study was funded by grants from the Uppsala County Council.

Conflict of Interest
None

References

1 Lees VC. The functional anatomy of forearm rotation. J Hand Microsurg 2009;1(2):92–99
2 Skoog T, Johansson SH. The formation of articular cartilage from free perichondrial grafts. Plast Reconstr Surg 1976;57(1):1–6
3 Engkvist O, Johansson SH. Perichondrial arthroplasty. A clinical study in twenty-six patients. Scand J Plast Reconstr Surg 1980; 14(1):71–87
4 Katsaros J, Milner R, Marshall NJ. Perichondrial arthroplasty incorporating costal cartilage. J Hand Surg [Br] 1995;20(2): 137–142

This document was downloaded for personal use only. Unauthorized distribution is strictly prohibited.