DERMATOLOGY PRACTICAL & CONCEPTUAL
www.derm101.com

Combining in vivo reflectance with fluorescence confocal microscopy provides additive information on skin morphology

Hans Skvara, M.D.[1], Ulrike Plut, M.D.[1], Johannes A. Schmid, M.D.[2] and Constanze Jonak, M.D.[3]

[1] Department of Dermatology, Division of Immunology, Allergy and Infectious Diseases, Medical University of Vienna, Vienna, Austria
[2] Center for Physiology and Pharmacology, Department of Vascular Biology, Medical University Vienna, Vienna, Austria
[3] Department of Dermatology, Division of General Dermatology, Medical University of Vienna, Vienna, Austria.

Key words: confocal microscopy, fluorescence, reflectance, sodium fluorescein, in vivo, healthy human skin

Citation: Skvara H, Plut U, Schmid JA, Jonak C. Combining in vivo reflectance with fluorescence confocal microscopy provides additive information on skin morphology. Dermatol Pract Conc. 2012;2(1):2. http://dx.doi.org/10.5826/dpc.0201a02.

Editor: Alon Scope, M.D.

Received: August 17, 2011; Accepted: October 31, 2011; Published: January 31, 2012

Copyright: ©2012 Skvara et al. This is an open-access article distributed under the terms of the Creative Commons Attribution License, which permits unrestricted use, distribution, and reproduction in any medium, provided the original author and source are credited.

Funding: None.

Competing interests: The authors have no conflicts of interest to disclose.

All authors have contributed significantly to this publication.

Corresponding author: Hans Skvara, M.D., Department of Dermatology, Division of Immunology, Allergy and Infectious Diseases, Medical University of Vienna, Vienna, Austria, Währinger Gürtel 18–20, 1090 Vienna. Tel. +43 1 40400 7736; Fax. +43 1 40400 7574. Email: hans.skvara@meduniwien.ac.at.

ABSTRACT

Background: Within the last decade, confocal microscopy has become a valuable non-invasive diagnostic tool in imaging human skin in vivo. Of the two different methods that exist, reflectance confocal microscopy (RCM) displays the backscattering signal of naturally occurring skin components, whereas fluorescence confocal microscopy (FCM) provides contrast by using an exogenously applied fluorescent dye.

Methodology: A newly developed multilaser device, in which both techniques are implemented, has been used to combine both methods and allows to highlight different information in one image. In our study, we applied the fluorophore sodium fluorescein (SFL) intradermally on forearm skin of 10 healthy volunteers followed by fluorescence and reflectance imaging.

Results: In fluorescence mode the intercellular distribution of SFL clearly outlines every single cell in the epidermis, whereas in reflectance mode keratin and melanin-rich cells and structures provide additional information. The combination of both methods enables a clear delineation between the cell border, the cytoplasm and the nucleus. Imaging immediately, 20, 40 and 60 minutes after SFL injection, represents the dynamic distribution pattern of the dye.

Conclusion: The synergism of RCM and FCM in one device delivering accurate information on skin architecture and pigmentation will have a great impact on in vivo diagnosis of human skin in the future.

Introduction

In recent years, reflectance confocal microscopy (RCM) has brought essential improvements in imaging human skin in vivo. This technique enables noninvasive optical sectioning of the tissue at a resolution that allows visualization of histological details [1,2]. The reflection of various skin components as for instance melanin, keratin, lipids or collagen, provides the source of contrast [3]. More recently certain investigators have demonstrated that also exogenous fluorescent contrast agents can successfully be applied to the tissue providing complementary information on skin morphology [4,5]. The in vivo confocal technique has therefore expanded from a reflectance to a fluorescence mode. Fluorescence confocal microscopy (FCM) relies on the excitation of exogenous fluorophores with a laser light source that offers the appropriate wavelength [6,7]. Thereon, the emitted fluorescence signal can be detected. The image quality provided by a fluorophore depends on several factors, including diffusion properties, solubility, clearance and pH-value [7]. To date, only very few Food and Drug Administration (FDA) approved fluorescent dyes for use in humans exist. Sodium fluorescein (SFL) is one of them. It has a peak spectral absorption at 490 nm and is FDA approved since 1976 as a contrast agent for angiography when applied intravenously [8]. Lately the properties of SFL in non-lesional and lesional human skin after topical and intradermal administration have also been characterized and studied in combination with in vivo FCM [4–6,9].

The newly developed Vivascope® 1500 Multilaser (Lucid Inc, Rochester, New York; USA) now offers the possibility of combining reflectance with fluorescence confocal microscopy in one single device. One of the three lasers that are integrated in this machine has a wavelength of 488 nm and therefore closely matches the excitation maximum of SFL. The aim of our study was to link and compare reflectance with fluorescence in vivo confocal microscopy of healthy human skin after intradermal injection of SFL and to investigate and highlight different and therefore additional information on skin morphology.

Methods

Participants

Ten individuals, five men and five women, aged between 25 and 43 years, were asked to participate in the study. The research protocol was approved by the local ethics committee of the Medical University of Vienna and the Austrian health authority (Bundesministerium für Gesundheit, Vienna, Austria). All individuals were Caucasian, with skin types ranging from II to IV. Clinically healthy, non-sun-damaged skin on the inner forearm was scanned with the confocal microscope. The study was conducted in Vienna (Department of Dermatology, Medical University of Vienna, Austria). Written consent was obtained before enrollment. The clinical investigation was conducted according to the principles of the Declaration of Helsinki.

In vivo fluorescence/reflectance confocal microscopy

Reflectance and fluorescence images were obtained using a commercially available confocal laser scanning microscope (Vivascope® 1500 Multilaser [Lucid Inc, Rochester, New York; USA]). A comprehensive review of the optical principles of the reflectance-only VivaScope® has been published elsewhere [1]. The multilaser system differs in that it is equipped with three lasers with wavelengths of 488 nm (blue), 658 nm (red) and 785 nm (near-infrared), and three corresponding filter sets. Each filter set is mounted in a bar. The user inserts the filter bar into the side of the confocal module. After application of a specific fluorescent dye the compatible laser is used to illuminate the tissue, thereby exciting the appropriate fluorophore within the specimen. Spectral filtering can be selected while imaging the same tissue site without stopping the scanning session. The position of the filter bar enables imaging in the different modes. Each filter bar has three positions which allow, respectively, all returning light, only reflectance, or only fluorescence to reach the detector. In one position reflected or backscattered laser light is eliminated by a fluorescence band-pass filter, whereas in another position fluorescence is eliminated by a reflectance band-pass filter. In the final position, no filter is present, allowing both reflectance and fluorescence signals to return to the detector. In all filtering configurations, a pinhole blocks the light from out-of-focus planes. The scanned field of view is 500 µm x 500 µm, producing images of 1000 x 1000 pixels. Image magnification is dependent on screen size. When displayed on the standard 19-inch monitor, magnification is approximately 600X. Axial resolution (section thickness) is 4.5 µm. By moving the objective lens in the z (vertical) plane with respect to the skin surface, it is possible to image at different horizontal directions (x and y axis) within the tissue. By zeroing the imaging depth at the level of the most superficial layer before going vertically into the tissue, depth measurements can be obtained.

A 0.08 % solution of sodium fluorescein (Thilorbin® eye drops, Alcon Pharma, Freiburg, Germany) was used as fluorescent dye and contrast agent for labeling of human skin structures. Approximately 20 µl of the solution were injected intradermally under standardized conditions using a 0.3 ml insulin syringe fitted with a 30-gauge needle. The syringe was placed at an angle of 5 to 10 degrees with respect to the skin surface. Minimal pain is associated with administration of the dye. Imaging was performed immediately at

20, 40 and 60 minutes after introduction of the fluorescent contrast agent. Between the imaging sessions, the injection site was light protected with a band-aid (Curapor®, 7 x 5 cm). The standard procedure for in vivo scanning with the Vivascope® has been described previously [10]. SFL has a maximum absorption rate at a wavelength around 490 nm and the fluorescence emission is peaking at about 520 nm. The tissue was illuminated with blue laser light (488 nm). Automatic image control was active, which allows the Vivascope® to automatically optimize the laser power so that the image is displayed with the proper illumination. Representative images at different layers of the epidermis down to the dermal-epidermal junction were acquired by varying the imaging depth. By changing the corresponding filter position, reflectance and fluorescence images were obtained consecutively from the same area and level within the tissue. We evaluated the depicted representations from both in vivo confocal imaging modes. Colour images (Figures 1E, 2E, 3E) were processed with Image J (National Institute of Health, Bethesda, Maryland, USA). Green and red colours were used to highlight reflectance and fluorescence mode, respectively. There was no processing of any other images with any software before analysis and reproduction for this paper.

Results

The in vivo confocal technique provides real-time scan sequences with gray-scaled images obtained in horizontal (en face) view to the skin surface. Therefore, no painful punch biopsies have to be obtained for morphological evaluation of the epidermis. Reflectance mode (RM) and fluorescence mode (FM) images of different skin layers are presented, beginning from the stratum corneum down to the dermal-epidermal junction. Immediately after intradermal injection SFL starts to distribute within the viable epidermis but does not diffuse upward into the non-viable stratum corneum according to the barrier properties between the cornified and the granular layer. Therefore, the RM image of the stratum corneum (Figure 1A) shows the typical bright backscattering signal of keratin-rich corneocytes as the corresponding FM image (Figure 1B) exhibits no signal. In the underlying stratum granulosum, the RM (Figure 1C) displays polygonal keratinocytes with a grainy cytoplasm and dark central nuclei. In FM (Figure 1D), the cell borders are significantly more pronounced and focused, whereas the inner cell structures can only be appreciated to some extent. Small bright spots at certain areas have previously been described as an artefact when extracellular SFL is impeded in its movement between desmosomal adhesion molecules [11]. In Figure 1E the RM and FM images are merged with two different colours (RM-green, FM-red) and the information of both techniques is combined. This representation now enables a clear distinction between areas of keratinisation and cells of the stratum granulosum. Moreover, the cell border, the cytoplasm and the nucleus can be differentiated in some cells using this fusion method. In contrast to the RM (Figure 2A), the homogeneous distribution of the fluorescent dye in FM (Figure 2B) clearly shows the outline of every single keratinocyte in the upper stratum spinosum at a depth of 15 µm. RM of the lower stratum spinosum at 25µm (Figure 2C) demonstrates roundish to oval areas containing highly refractive cells on top of the dermal papillae corresponding to basal cells and melanocytes. The cell borders between the keratinocytes can barley be detected. In the FM image (Figure 2D) every single keratinocyte is outlined due to the homogenous extracellular concentration of the fluorescent dye. In addition small areas of intense luminosity occur at the central "hilltops" of the papillary dermis. This strong signal results from an enriched distribution of SFL in the relatively acellular dermis. It is of particular note that this dermal area that appears with intense brightness in FM shows a reverse contrast in RM where it is darker than the surrounding melanin-containing cells. This is clearly illustrated when RM and FM images are again merged with different colours [RM-green, FM-red (Figure 2E)]. The red colour represents the fluorescent signal between the keratinocytes and in the papillary "hilltops," whereas the green colour pictures highly reflective melanin- and keratin-rich cells and structures. Moving the focal plane a few microns deeper to 35 µm below the skin surface, both modes, although scanned at the same area and level, exhibit a considerably different pattern. In RM, again, melanin-containing cells are displayed, partly demarcating the dermis shaped as a bright rim (Figure 3A). In FM (Figure 3B), dermal papillae now appear even brighter interposed among the deeper epidermal layers, and every single and polygonal keratinocyte can still be identified. In RM at 50 µm, highly refractive basal cells and melanocytes enclose the papillary dermis (Figure 3C), which in FM is strongly contrasted by the fluorescent dye (Figure 3D). Capillary loops can be identified and compared to each other in both modes but are more clearly contoured in the FM. In Figure 3E, RM and FM images are again fused with two colours (RM-green, FM-red). A bright green rim represents the backscattering signal of melanin-containing cells, whereas the encased dermal areas provide a red shining contrast. At 65 µm the short-wave laser has reached its limit and the RM image is markedly degraded (Figure 4A). An eccrine duct is displayed as a highly reflective, unfocused whitish structure. In FM capillary vessels can be appreciated inside lucid dermal areas, whereas the eccrine duct appears dark (Figure 4B).

Within five to ten minutes after injection, the fluorescent dye is taken up from the extracellular space into the cytoplasm of the keratinocytes. Figure 5A and B show a RM and

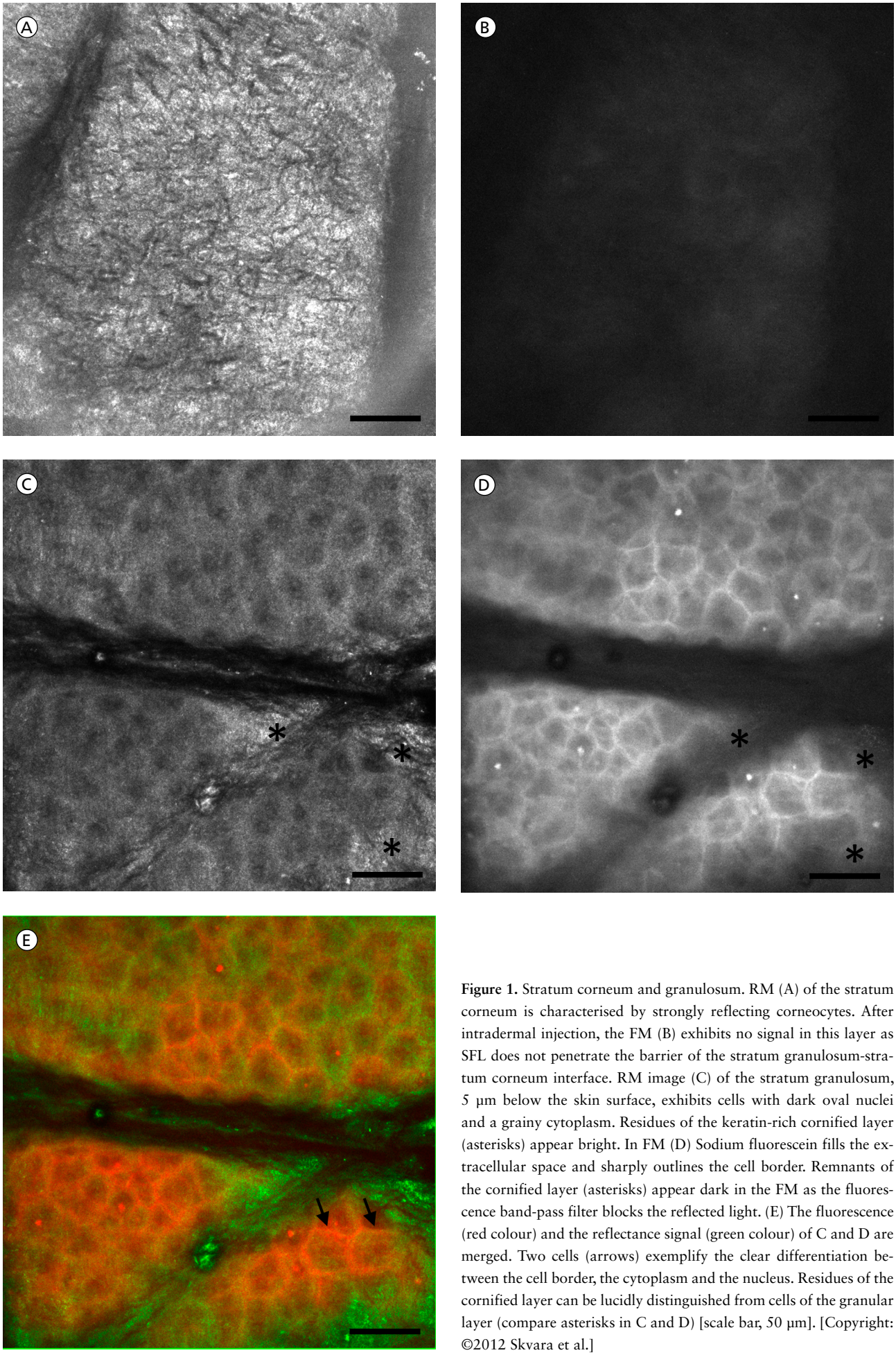

Figure 1. Stratum corneum and granulosum. RM (A) of the stratum corneum is characterised by strongly reflecting corneocytes. After intradermal injection, the FM (B) exhibits no signal in this layer as SFL does not penetrate the barrier of the stratum granulosum-stratum corneum interface. RM image (C) of the stratum granulosum, 5 µm below the skin surface, exhibits cells with dark oval nuclei and a grainy cytoplasm. Residues of the keratin-rich cornified layer (asterisks) appear bright. In FM (D) Sodium fluorescein fills the extracellular space and sharply outlines the cell border. Remnants of the cornified layer (asterisks) appear dark in the FM as the fluorescence band-pass filter blocks the reflected light. (E) The fluorescence (red colour) and the reflectance signal (green colour) of C and D are merged. Two cells (arrows) exemplify the clear differentiation between the cell border, the cytoplasm and the nucleus. Residues of the cornified layer can be lucidly distinguished from cells of the granular layer (compare asterisks in C and D) [scale bar, 50 µm]. [Copyright: ©2012 Skvara et al.]

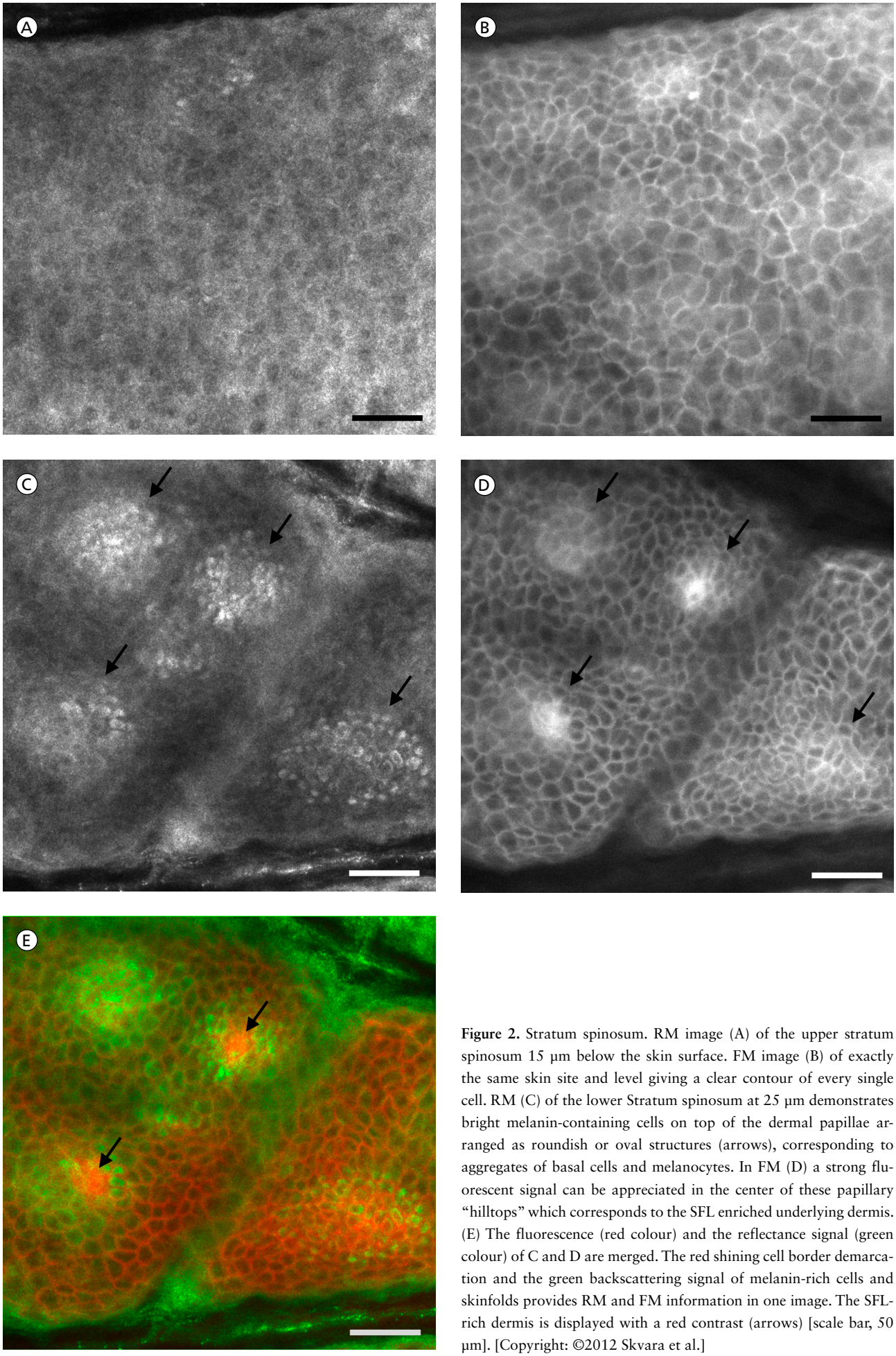

Figure 2. Stratum spinosum. RM image (A) of the upper stratum spinosum 15 µm below the skin surface. FM image (B) of exactly the same skin site and level giving a clear contour of every single cell. RM (C) of the lower Stratum spinosum at 25 µm demonstrates bright melanin-containing cells on top of the dermal papillae arranged as roundish or oval structures (arrows), corresponding to aggregates of basal cells and melanocytes. In FM (D) a strong fluorescent signal can be appreciated in the center of these papillary "hilltops" which corresponds to the SFL enriched underlying dermis. (E) The fluorescence (red colour) and the reflectance signal (green colour) of C and D are merged. The red shining cell border demarcation and the green backscattering signal of melanin-rich cells and skinfolds provides RM and FM information in one image. The SFL-rich dermis is displayed with a red contrast (arrows) [scale bar, 50 µm]. [Copyright: ©2012 Skvara et al.]

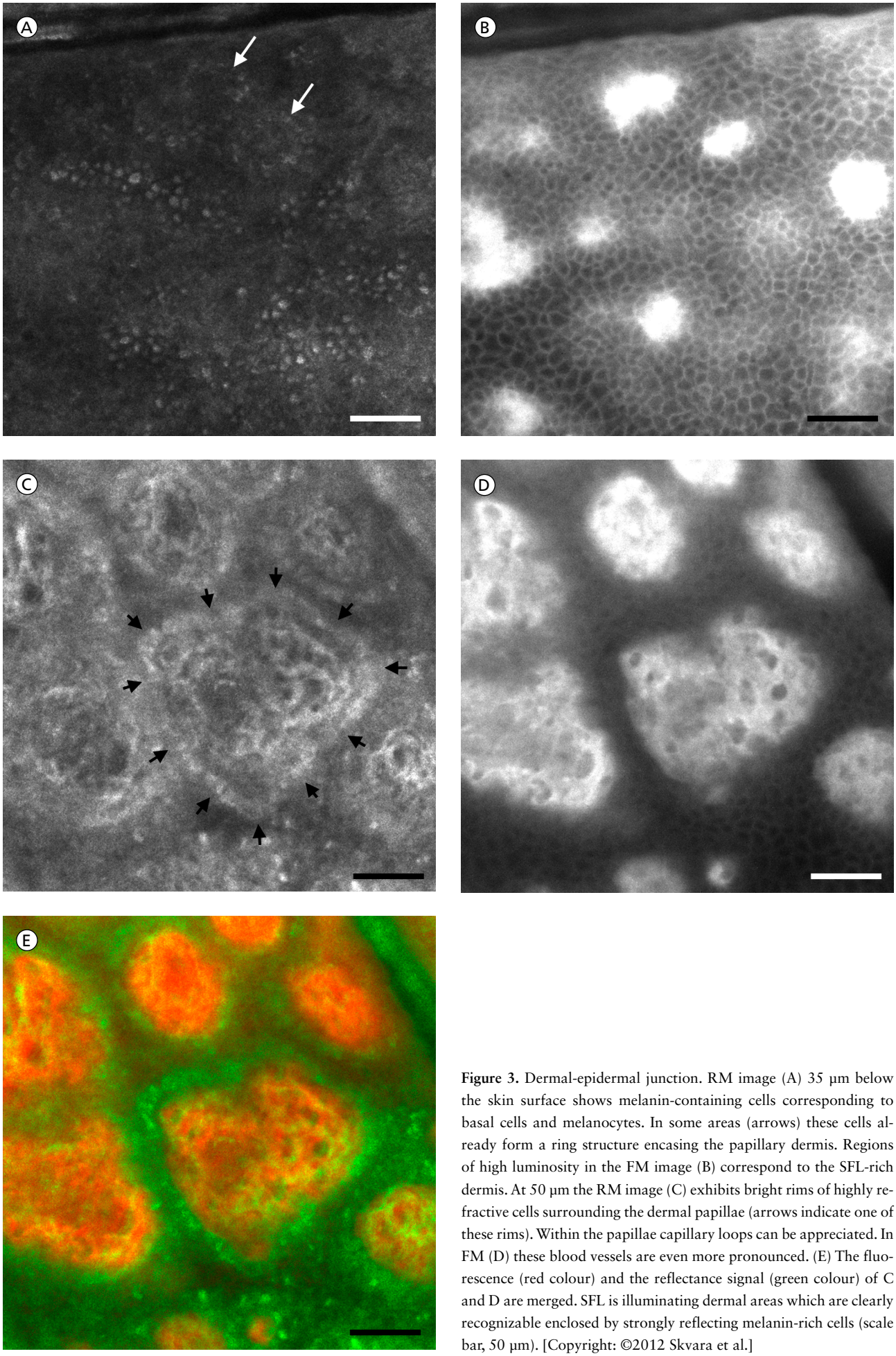

Figure 3. Dermal-epidermal junction. RM image (A) 35 µm below the skin surface shows melanin-containing cells corresponding to basal cells and melanocytes. In some areas (arrows) these cells already form a ring structure encasing the papillary dermis. Regions of high luminosity in the FM image (B) correspond to the SFL-rich dermis. At 50 µm the RM image (C) exhibits bright rims of highly refractive cells surrounding the dermal papillae (arrows indicate one of these rims). Within the papillae capillary loops can be appreciated. In FM (D) these blood vessels are even more pronounced. (E) The fluorescence (red colour) and the reflectance signal (green colour) of C and D are merged. SFL is illuminating dermal areas which are clearly recognizable enclosed by strongly reflecting melanin-rich cells (scale bar, 50 µm). [Copyright: ©2012 Skvara et al.]

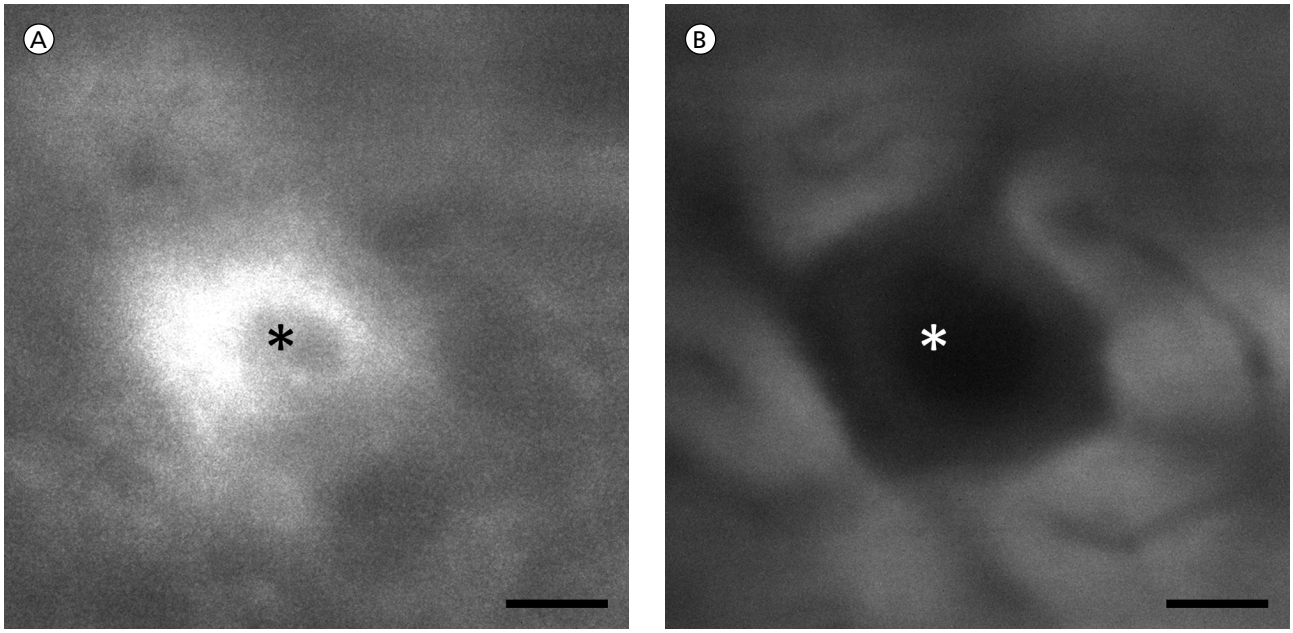

Figure 4. Dermal-epidermal junction/papillary dermis. (A) The RM image 65 µm below the skin surface as well as the corresponding FM image (B) are degraded as the capacity of the 488 nm laser does not allow focused imaging beyond a penetration depth of about 60 µm; eccrine duct (asterisk)[scale bar, 50 µm]. [Copyright: ©2012 Skvara et al.]

the corresponding FM image 20 minutes after injection of SFL at the level of the stratum spinosum at 25 µm below the skin surface. According to the redistribution of the dye the cytoplasm and the nucleus can now clearly be distinguished in FM, however, this happens to the disadvantage of cell border demarcation. The cells of an eccrine duct can be identified as such and are appreciably larger than keratinocytes. Forty minutes after application, the contrast agent has left the intercellular space in most parts of the injected skin (Figure 5C and D). Therefore, the area surrounding the cell now appears dark, which contours the cell border again. The intracellularly redistributed dye makes the cytoplasm shine bright and outlines the nucleus. Subsequently, the fluorescence intensity starts to decrease and about 60 minutes after introduction of SFL further evaluations in FM do not provide anymore diagnostic benefit (Figure 5E and F). The results were reproducible and consistent for all ten subjects. We observed that the redistribution occurred more rapidly at the center of the injected site which could be explained by the fact that the dye concentration was highest in this area. The application of SFL was safe and well tolerated and no adverse event occurred in any of the participants. A slight yellow discoloration remained visible at the injection site but completely disappeared about 24 hours after intradermal administration.

Discussion

Non-invasive or minimally invasive diagnostic assessment of human skin is not only desirable but also becomes more and more feasible as devices improve and increasingly become commercially available. In vivo confocal microscopy is probably one of the best established non-invasive techniques to study the skin at a cellular and sub-cellular level [12]. To date, two different methods, each of which has its own special qualities, exist: the reflectance and the fluorescence mode. RCM, on the one hand, relies on the presentation of backscattering signals of naturally occurring skin components. Numerous studies have already confirmed the immense diagnostic potential of RCM [13–15]. The detection and differentiation of melanoma and non-melanoma skin cancer is the main indication for this technique, one which has already been established in routine clinical settings. FCM, on the other hand, is dependent on topical or intracutaneous application of an exogenous contrast dye. The fluorescent molecules within the tissue then are excited by a laser source with the appropriate wavelength and the fluorescence emission can be detected and analyzed to create an image contrast.

In a recent study FCM has been shown to enable a systematic, minimally invasive histomorphometric evaluation of actinic keratosis and has been successfully used to monitor the therapeutic response of basal cell carcinomas during topical treatment with imiquimod [5]. Furthermore, inflammatory and infectious skin diseases have been effectively studied by this method [4, 9]. Even though promising results in non-lesional and lesional human skin have been published, FCM is still in the experimental stage. Notwithstanding that fact, it is obvious that the combination of both techniques provides supplementary information which could be useful in order to improve diagnostic evidence.

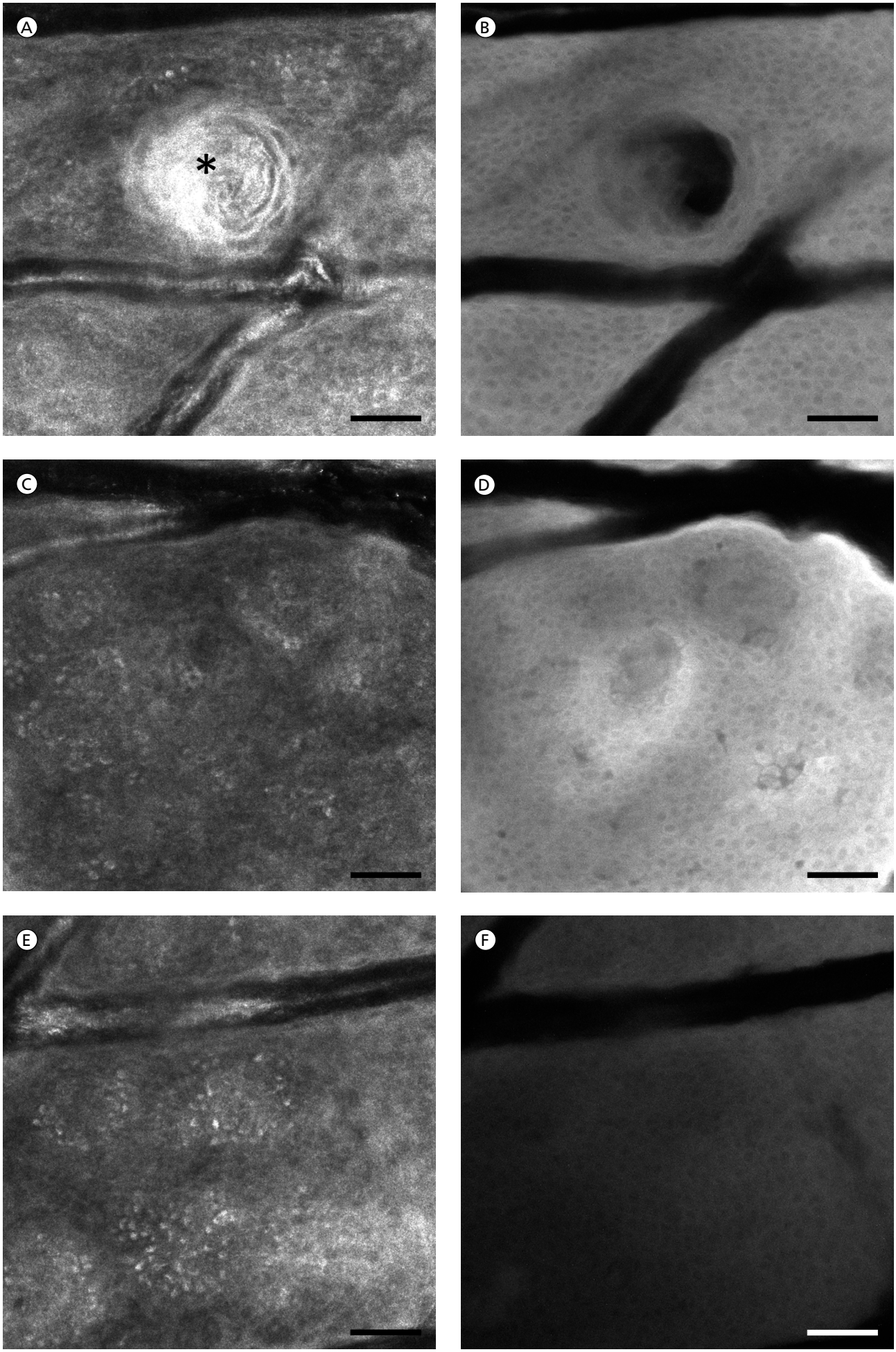
A
B
C
D
E
F

Figure 5 (left page). Time kinetics 20, 40, and 60 minutes after intradermal SFL injection. Images in RM (A) and FM (B) captured after 20 minutes (stratum spinosum, 25 µm below the skin surface, asterisk indicates an eccrine gland) are displayed. In FM a redistribution of SFL from the extracellular space into the cell enables a clear differentiation between the cytoplasm and the nucleus. RM (C) and FM (D) images after 40 minutes are opposed. In most areas the dye has completely left the extracellular space and invaded the cells. RM (E) and FM (F) images after 60 minutes are confronted (scale bar, 50 µm). [Copyright: ©2012 Skvara et al.]

The new VivaScope® 1500 Multilaser now offers the possibility of applying and combining these two technologies, as both of them are implemented in that device. This multilaser machine consists of several lasers of different wavelengths and was designed to be utilized for the in vivo examination of human skin. In general, shorter wavelengths have limited penetration depth but provide a better resolution in higher cellular layers, whereas longer wavelengths penetrate deeper into the skin but yield a lower resolution. In our study, however, all data presented refer to the use of only one of these lasers, the blue short-wave 488 nm laser in combination with sodium fluorescein. RM and FM images were captured from the same tissue area and level within a few seconds by simply relocating a filter element. Our results clearly show that imaging of the same skin site with both confocal modes provides useful additional information. Whereas FCM clearly outlines the cell border throughout the whole epidermis, melanin- and keratin-containing cells and structures can be shown distinctly with RCM. Therefore, a device that offers both modes at once enormously enhances diagnostic quality. A further advancement would combine the distinct identification of certain cell types (e.g. melanocytes and Langerhans cells) with the use of particular fluorescently labelled antibodies to target specific cell surface molecules. Recently, selective antibodies labelled with fluorescein to detect melanoma have been used successfully in a mouse model [16].

For human application, however, there is a limited panel of fluorescent dyes that are FDA approved so far. In our study we used SFL, which has been applied safely for decades as a contrast agent for ophthalmic angiography [17]. After intradermal injection the rapid extracellular distribution of the dye enabled an immediate evaluation. Soon thereafter, SFL starts to diffuse into the cells. After about an hour the fluorescent signal had all but disappeared, comparable to previously performed kinetic studies [4]. However, though the pharmacokinetic process of SFL provides additional functional information on the state of the tissue, its rapid redistribution can also be considered a handicap during evaluation. The restriction in penetration depth with the short-wave 488 nm laser is one of the key technical limitations of this method. The identification of other fluorophores that can be combined with longer-wavelength lasers that are integrated in the device will allow deeper penetration and, therefore, extend the clinical and experimental applicability.

RCM and FCM linked together have been shown to provide synergy of information. An accurate assessment of cell morphology with FCM is supplemented by identification of pigmented cells and structures with RCM, proving the usefulness of this combined technology in the evaluation of healthy and pathological human skin.

Acknowledgments

The authors want to thank Dan Koon (Lucid Inc, Rochester, New York, USA) and Yvonne Franke (Mavig GmbH, Munich, Germany) for their technical help.

References

1. Calzavara-Pinton P, Longo C, Venturini M, Sala R, Pellacani G. Reflectance confocal microscopy for in vivo skin imaging. Photochem Photobiol. 2008;84(6):1421–30.
2. Branzan AL, Landthaler M, Szeimies RM. In vivo confocal scanning laser microscopy in dermatology. Lasers Med Sci. 2007;22(2):78–82.
3. Marghoob AA, Swindle LD, Moricz CZ, et al. Instruments and new technologies for the in vivo diagnosis of melanoma. J Am Acad Dermatol. 2003;49(5):777–97.
4. Meyer LE, Otberg N, Sterry W, Lademann J. In vivo confocal scanning laser microscopy: comparison of the reflectance and fluorescence mode by imaging human skin. J Biomed Opt. 2006;11 (4): 044012.
5. Astner S, Dietterle S, Otberg N. Röwert-Huber HJ, Stockfieth E, Lademann J. Clinical applicability of in vivo fluorescence confocal microscopy for noninvasive diagnosis and therapeutic monitoring of nonmelanoma skin cancer. J Biomed Opt. 2008;13(1):014003.
6. Leeson DT, Lynn Meyers C, Subramanyan K. In vivo confocal fluorescence imaging of skin surface cellular morphology: a pilot study of its potential as a clinical tool in skin research. Int J Cosmet Sci. 2006;28(1):9–20.
7. Swindle LD, Thomas SG, Freeman M, Delaney PM. View of normal human skin in vivo as observed using fluorescent fiber-optic confocal microscopic imaging. J Invest Dermatol. 2003;121(4):706–12.
8. Alford R, Simpson HM, Duberman J, et al. Toxicity of organic fluorophores used in molecular imaging: literature review. Mol Imaging. 2009;8(6):341–54.
9. Suihko C, Serup J. Fluorescence confocal laser scanning microscopy for in vivo imaging of epidermal reactions to two experimental irritants. Skin Res Technol. 2008;14(4): 498–503.
10. González S. Confocal reflectance microscopy in dermatology: promise and reality of non-invasive diagnosis and monitoring. Actas Dermosifiliogr. 2009;100 Suppl 2:59–69.
11. Suihko C, Swindle LD, Thomas SG, Serup J. Fluorescence fibre-optic confocal microscopy of skin in vivo: microscope and fluorophores. Skin Res Technol 2005;11(4): 254–67.

12. Rajadhyaksha M, González S, Zavislan JM, Anderson RR, Webb RH. In vivo confocal scanning laser microscopy of human skin II: advances in instrumentation and comparison with histology. J Invest Dermatol. 1999;113(3):293–303.
13. Kang HY, Bahadoran P, Ortonne JP. Reflectance confocal microscopy for pigmentary disorders. Exp Dermatol. 2010;19(3):233–9.
14. Pellacani G, Longo C, Malvehy J, et al. In vivo confocal microscopic and histopathologic correlations of dermoscopic features in 202 melanocytic lesions. Arch Dermatol. 2008;144(12):1597–608.
15. Ulrich M, Roewert-Huber J, González S, Rius-Diaz F, Stockfieth E, Kanitakis J. Peritumoral clefting in basal cell carcinoma: correlation of in vivo reflectance confocal microscopy and routine histology. J Cutan Pathol. 2011;38(2):190–5.
16. Anikijenko P, Vo LT, Murr ER. In vivo detection of small subsurface melanomas in athymic mice using noninvasive fiber optic confocal imaging. J Invest Dermatol. 2001; 117(6):1442–8.
17. O'Goshi K, Serup J. Safety of sodium fluorescein for in vivo study of skin. Skin Res Technol. 2006;12(3):155–61.