Metastatic Amelanotic Melanoma of the Jejunum Diagnosed on Capsule Endoscopy

Omair Atiq, MD[1]
Ali S. Khan, MD[2]
Gary A. Abrams, MD[1]

[1]Department of Internal Medicine, UAB Health Center, Montgomery, Alabama; [2]Department of Gastroenterology, UAB, Birmingham, Alabama

Gastrointestinal (GI) metastasis of malignant melanomas from known primary tumors is a common autopsy finding (50–60%). However, early detection of small bowel melanomas remains a challenge for both radiologists and clinicians. Capsule endoscopy (CE) may be able to detect the presence of small bowel metastases in patients with melanomas more reliably than conventional investigative techniques. We report a case of small bowel metastatic amelanotic melanoma found on CE. A brief review of the literature focusing on the diagnostic yield of CE is also given.

Case Report

An 81-year-old white male presented with a 1-week history of intractable nausea and vomiting. He denied having abdominal pain, hematemesis, melena, hematochezia, or weight loss. The patient's medical history was remarkable for iron-deficiency anemia, hypertension, dyslipidemia, and a remote history of a cutaneous melanoma on the right side of the neck, which was resected in 2004. Pathologic examination of this melanoma showed a lesion that was 2.4 mm in thickness (stage II, T3bN0M0). Physical examination revealed pale conjunctiva and palms. Laboratory data were significant for a hematocrit level of 27.2; carcinoembryonic antigen, lactate dehydrogenase, and electrolyte levels were normal.

Due to his history of melanoma and iron-deficiency anemia, the patient had had an extensive work-up performed in the past—including repeated computed tomography (CT) scans of the neck, chest, and abdomen, all of which had normal findings. He also had 2 esophagogastroduodenoscopies and a colonoscopy, all of which had normal findings. The patient was started on intravenous iron for management of his anemia. Given his prior negative work-up, a CE was performed; this procedure showed an actively bleeding, ulcerated, small bowel mass (Figure 1). The capsule was retained. Enteroscopy or surgery was recommended.

Figure 1. Capsule endoscope in the small intestine showing active bleeding.

On surgical exploration, a large (7 cm × 9 cm), irregular, multilobed, midjejunal mass was found; this mass extended into the mesentery. Immunohistochemical staining with S-100 and human melanoma black 45 antibody was positive in tumor cells (Figures 2A and 2B). No nodal metastasis was seen. Histopathology showed an amelanotic malignant melanoma invading the muscularis propria and subserosal tissue without involvement of the visceral peritoneum. A positron emission tomography (PET) scan showed a solitary hepatic metastasis, which was destroyed with CT-guided radioablation (Figure 3).

Address correspondence to:
Dr. Omair Atiq, 2055 East South Blvd, Suite 202, Montgomery, AL 36116;
Tel: 224-538-1235; E-mail: dromair@hotmail.com

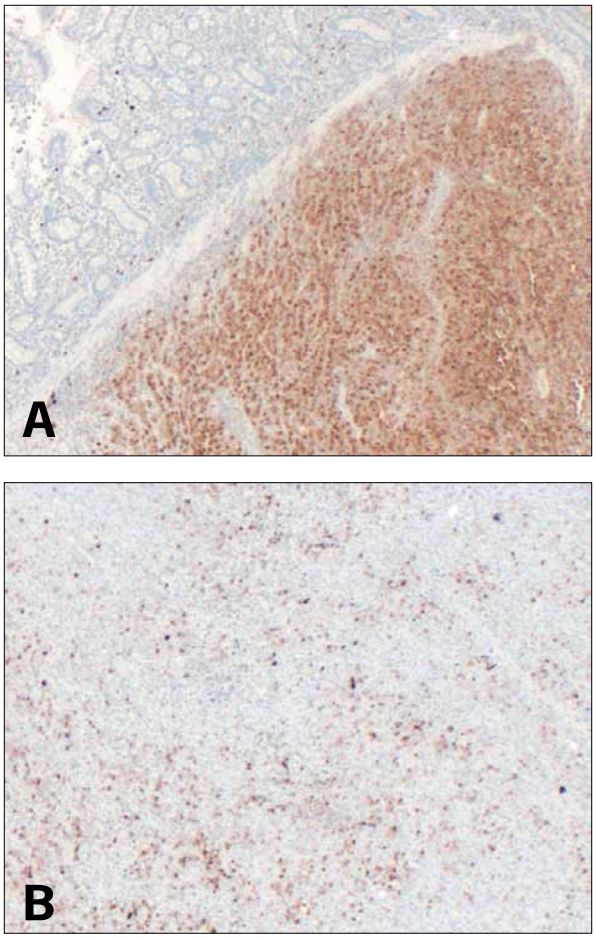

Figure 2. S-100 immunostaining showing pigmented cells (25× magnification). This marker is relatively nonspecific but is rather sensitive for melanomas (**A**). View showing scattered cells positive for the human melanoma black 45 antibody (brown cells are positive), a marker commonly seen in melanomas (25× magnification; **B**).

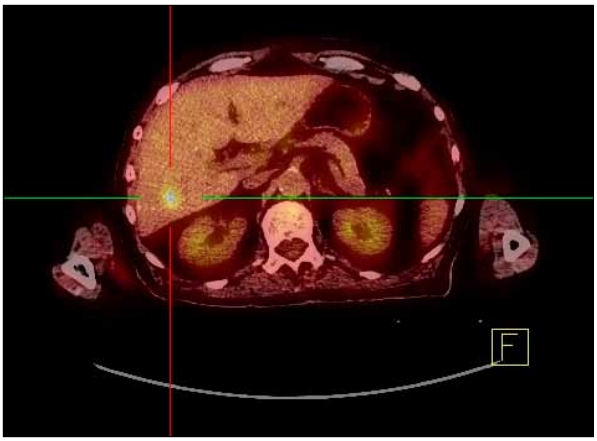

Figure 3. Positron emission tomography–computed tomography scan showing the intrahepatic lesion.

Discussion

Small bowel tumors are rare, accounting for only 3–6% of all GI tumors.[1] Melanomas of the GI tract are either primary or metastatic. Primary tumors are extremely rare. According to some researchers, primary melanoma of the GI tract does not exist as a separate clinical entity but rather represents metastatic lesions from unknown or regressed primary cutaneous melanomas.[2,3] Therefore, establishing the exact origin (primary or secondary) of a small bowel melanoma can be difficult or impossible and remains a challenge for both clinicians and radiologists.

Among patients who are diagnosed with a cutaneous melanoma, approximately 60% have a GI metastasis, but only 1.5–4% of these metastases are diagnosed during the patient's lifetime, as evidenced by autopsy series.[4-8] Superficial spreading melanoma is the most common type of melanoma that metastasizes to the small bowel. The primary tumor is typically located in the extremities (15–57%), the trunk (13–54%), or, less frequently, in the head and neck (5–33%). Metastatic melanoma can present as 1 of 4 different morphologies: cavitary, infiltrating, exoenteric, or polypoid.[9]

The period between the diagnosis of the primary melanoma and the GI metastasis is reported to be 60–90 months.[10] Clinical signs and symptoms of GI metastases include abdominal pain, intestinal obstruction, constipation, hematemesis, melena, anemia, fatigue, weight loss, and the presence of a palpable abdominal mass. GI metastases predominantly present in 2 ways.[11,12] The most common presentation is as a submucosal implant that extends intraluminally, where it eventually leads to pain, obstruction, ulceration, and acute or chronic blood loss. The other common presentation is a polypoid lesion, which can present as an intussusception, as described in this case report.[8]

The diagnosis of small bowel melanomas remains a challenge for both clinicians and radiologists. Previously, ultrasonography, small bowel follow-through, enteroclysis, computed axial tomography scans, and CT enteroclysis were common radiographic modalities for diagnosing small bowel tumors. Conventional enteroclysis was the primary method for early detection of small bowel melanomas. CT scans have a sensitivity of 60–70% for detecting metastases.

Modalities that were previously used to investigate obscure GI bleeding (OGIB), such as push enteroscopy (PE) and intraoperative enteroscopy, are now limited to increasingly selective situations. Newer technologies, including CE and double-balloon enteroscopy (DBE), now play a major role in the evaluation of OGIB. DBE is better than CE, as biopsies can be taken under direct visualization with DBE, but CE has the advantages of being noninvasive and less expensive. CE has consistently been shown to be superior to PE and small bowel radiography for detecting small bowel

lesions. A meta-analysis of studies comparing the yield of CE to those of other diagnostic modalities in patients with OGIB showed that the yield of CE was double that of PE (63% vs 28%).[13] The same meta-analysis reported the yield of CE to be higher than the yield of small bowel radiography for clinically significant lesions (42% vs 6%).[13] Another meta-analysis of 24 studies reported the yield of CE (for all indications) to be 87%, compared to 14.8% and 9.9% for PE and small bowel series, respectively.[14]

Magnetic resonance enterography (MRE) is a relatively new modality that has emerged along with CE. No large trials have been performed to compare CE and MRE. A small study showed better diagnostic yield with CE compared to MRE (100% vs 67%) for detection of small bowel tumors, but this study was limited due to its small size.[15] CE and MRE are complementary for the evaluation of the small bowel. CE can readily depict and characterize subtle mucosal lesions, which may be missed with MRE, whereas MRE offers a rapid overview of the small bowel and provides additional mural, perienteric, and extraenteric information.

More recently, fludeoxyglucose (FDG) PET-CT has been used to identify sites of metastasis. Prakoso and colleagues compared CE and PET-CT scanning for detection of small bowel metastases.[16] They concluded that CE was better than FDG PET-CT scanning for localizing small bowel melanomas and that CE is an ideal complementary investigative modality both for patients with known metastatic melanomas who are undergoing preoperative work-ups and for patients with unexplained anemia or GI symptoms.[16] Another single-center trial showed that CE is superior to other diagnostic modalities for diagnosing small bowel tumors. In 77% of cases, CE was able to demonstrate malignancies that were not identified during the previous diagnostic work-up.[17]

The main limitation of CE is its inability to obtain biopsies or administer therapy. The most common complication of CE is capsule retention, which occurred in our patient due to an obstructive lesion. Pooled retention rates were found to be 1.4% overall and 1.2%, 2.6%, and 2.1% for CE performed in patients with OGIB, Crohn's disease, and neoplastic lesions, respectively.[18] Risk factors for capsule retention include use of nonsteroidal anti-inflammatory drugs, abdominal radiation injury, extensive Crohn's disease, and previous major abdominal surgery.[19]

Surgery is the treatment of choice for metastatic small bowel melanomas. Surgery is not a curative treatment, but it is effective in palliating symptoms and may prolong survival. The significance of complete resection on postoperative survival is well described in the literature.[11,20,21]

Systemic chemotherapy and immunotherapy have a limited role in these patients. Dacarbazine has been used in the past with little or no benefit. Ipilimumab (Yervoy, Bristol-Myers Squibb), a cytotoxic T-lymphocyte antigen 4 receptor blocker, has been recently approved by the US Food and Drug Administration (FDA). Ipilimumab is the first agent that has increased median survival, from 6.4 months to 10 months.[22] Another agent, vemurafenib (Zelboraf, Hoffmann-La Roche), which targets the *BRAF* mutation, was approved in August 2011 for treatment of unresectable or metastatic melanoma with the *BRAF* v600E mutation, which is detected by an FDA-approved test.

References

1. Naef M, Bühlmann M, Baer HU. Small bowel tumors: diagnosis, therapy and prognostic factors. *Langenbecks Arch Surg*. 1999;384:176-180.
2. Elsayed AM, Albahra M, Nzeako UC, Sobin LH. Malignant melanomas in the small intestine: a study of 103 patients. *Am J Gastroenterol*. 1996;91:1001-1006.
3. McGovern VJ. Spontaneous regression of melanoma. *Pathology*. 1975;7:91-99.
4. Ihde JK, Coit DG. Melanoma metastatic to stomach, small bowel, or colon. *Am J Surg*. 1991;162:208-211.
5. Manola J, Atkins M, Ibrahim J, Kirkwood J. Prognostic factors in metastatic melanoma: a pooled analysis of Eastern Cooperative Oncology Group trials. *J Clin Oncol*. 2000;18:3782-3793.
6. Patel JK, Didolkar MS, Pickren JW, Moore RH. Metastatic pattern of malignant melanoma. A study of 216 autopsy cases. *Am J Surg*. 1978;135:807-810.
7. Reintgen DS, Thompson W, Garbutt J, Seigler HF. Radiologic, endoscopic, and surgical considerations of melanoma metastatic to the gastrointestinal tract. *Surgery*. 1984;95:635-639.
8. Aktaş A, Hoş G, Topaloğlu S, Calık A, Reis A, Pişkin B. Metastatic cutaneous melanoma presented with ileal invagination: report of a case. *Ulus Travma Acil Cerrahi Derg*. 2010;16:469-472.
9. Bender GN, Maglinte DD, McLarney JH, Rex D, Kelvin FM. Malignant melanoma: patterns of metastasis to the small bowel, reliability of imaging studies, and clinical relevance. *Am J Gastroenterol*. 2001;96:2392-2400.
10. Jorge E, Harvey HA, Simmonds MA, Lipton A, Joehl RJ. Symptomatic malignant melanoma of the gastrointestinal tract. Operative treatment and survival. *Ann Surg*. 1984;199:328-331.
11. Ricaniadis N, Konstadoulakis MM, Walsh D, Karakousis CP. Gastrointestinal metastases from malignant melanoma. *Surg Oncol*. 1995;4:105-110.
12. Berger AC, Buell JF, Venzon D, Baker AR, Libutti SK. Management of symptomatic malignant melanoma of the gastrointestinal tract. *Ann Surg Oncol*. 1999;6:155-160.
13. Triester SL, Leighton JA, Leontiadis GI, et al. A meta-analysis of the yield of capsule endoscopy compared to other diagnostic modalities in patients with obscure gastrointestinal bleeding. *Am J Gastroenterol*. 2005;100:2407-2418.
14. Lewis BS, Eisen GM, Friedman S. A pooled analysis to evaluate results of capsule endoscopy trials. *Endoscopy*. 2005;37:960-965.
15. Crook DW, Knuesel PR, Froehlich JM, et al. Comparison of magnetic resonance enterography and video capsule endoscopy in evaluating small bowel disease. *Eur J Gastroenterol Hepatol*. 2009;21:54-65.
16. Prakoso E, Fulham M, Thompson JF, Selby WS. Capsule endoscopy versus positron emission tomography for detection of small-bowel metastatic melanoma: a pilot study. *Gastrointest Endosc*. 2011;73:750-756.
17. Spada C, Riccioni ME, Familiari P, Marchese M, Bizzotto A, Costamagna G. Video capsule endoscopy in small-bowel tumours: a single centre experience. *Scand J Gastroenterol*. 2008;43:497-505.
18. Liao Z, Gao R, Xu C, Li ZS. Indications and detection, completion, and retention rates of small-bowel capsule endoscopy: a systematic review. *Gastrointest Endosc*. 2010;71:280-286.
19. Liu K, Kaffes AJ. Review article: the diagnosis and investigation of obscure gastrointestinal bleeding. *Aliment Pharmacol Ther*. 2011;34:416-423.
20. Gutman H, Hess KR, Kokotsakis JA, Ross MI, Guinee VF, Balch CM. Surgery for abdominal metastases of cutaneous melanoma. *World J Surg*. 2001;25:750-758.
21. Akaraviputh T, Arunakul S, Lohsiriwat V, Iramaneerat C, Trakarnsanga A. Surgery for gastrointestinal malignant melanoma: experience from surgical training center. *World J Gastroenterol*. 2010;16:745-748.
22. Hodi FS, O'Day SJ, McDermott DF, et al. Improved survival with ipilimumab in patients with metastatic melanoma. *N Engl J Med*. 2010;363:711-723.