DERMATOLOGY PRACTICAL & CONCEPTUAL
www.derm101.com

A novel treatment for non-melanoma skin cancer of the ear: V to Y full thickness skin graft

Graham Sivyer, MBBS[1]

[1] Mermaid Beach Medical Centre, Queensland, Australia

Key words: non melanoma skin cancer, basal cell carcinoma, squamous cell carcinoma, auricular helix, posterior ear, full thickness skin graft

Citation: Sivyer G. A novel treatment for non-melanoma skin cancer of the ear: V to Y full thickness skin graft. Dermatol Pract Conc. 2012;2(4):11. http://dx.doi.org/10.5826/dpc.0204a11.

Received: January 29, 2012; **Accepted:** August 15, 2012; **Published:** October 31, 2012

Copyright: ©2012 Sivyer. This is an open-access article distributed under the terms of the Creative Commons Attribution License, which permits unrestricted use, distribution, and reproduction in any medium, provided the original author and source are credited.

Funding: None.

Competing interests: The authors have no conflicts of interest to disclose.

Corresponding author: Graham Sivyer MBBS(Hons) FSCCANZ, Mermaid Beach Medical Centre, 2506 Gold Coast Highway, Mermaid Beach, Queensland 4218 Australia. Tel. +61(0)755721668; Fax. +61(0)755722866. Email: graham.sivyer@ipnet.com.au.

Introduction

The incidence rates of skin cancer in Australia are the highest in the world. In 2002 the age-standardised incident rate for basal cell carcinoma (BCC) was estimated to be 884 per 100,000 of the population. This rate showed a threefold gradient between northern and southern Australia [1]. BCCs are the most common cutaneous tumours, accounting for approximately 70% of all malignant diseases of the skin. They are found predominantly on areas of skin exposed to the sun, particularly in fair skinned individuals. Up to 80% of all BCCs are found on the head and neck. They are more common in males, presumably related to occupational and recreational exposure to UV light. They tend to occur in older people [2]. In 2002 the age-standardised incidence of squamous cell carcinoma (SCC) was estimated to be 387 per 100,000 of the population with a significant latitude gradient (similar to BCCs). Also, as for BCCs, the incidence of SCCs increases with increasing age. The head and neck are the most common sites of occurrence for SCC in men, while upper limbs are the most common sites for women. When body surface area is taken into account the highest SCC incidence in both men and women is found on the face, especially the lips nose cheek eyelids and ears [3].

In general the surgical management of SCC is more radical than for BCC because SCCs are potentially more aggressive, have a greater potential for local recurrence and may spread to regional lymph nodes and distant sites. Over 70% of the BCCs in Australia were surgically excised [1]. The majority of SCCs were surgically excised [1]. In Australia about 400 people die from skin cancers other than melanoma each year. These are predominantly SCC but some deaths are due to BCC [1]. The recommended surgical margin of excision for SCC varies from 2 mm to 10 mm. Histological margins of 1 mm or less mandates consideration of further therapy [3]. The diameter of SCC correlates with risk of recurrence. Lesions thicker than 4 mm or extending to at least the reticular dermis are associated with a higher rate of recurrence. A higher risk of local recurrence includes the ear. The majority of clinically favourable SCCs of less than 2 cm can be excised with a margin of at least 4 mm [4].

V to Y full thickness skin graft

The majority of non-melanoma skin cancer (NMSC) occurs on the auricular helix and periauricular areas that are especially susceptible as they are exposed to the most UV light. Defects of the upper third of the helical rim can be diffi-

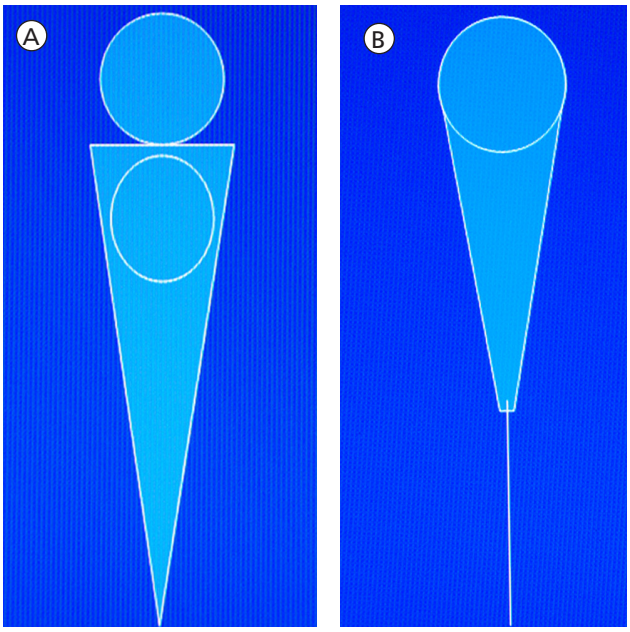

Figure 1. (A) Diagrammatic outline of circular lesion to be removed from the helical rim of the ear and the outline of the full thickness graft donor site on the posterior aspect of the ear. (B) Diagram of completed V to Y full thickness graft moved to cover the defect on the helical rim. [Copyright: ©2012 Sivyer.]

cult to repair. The area is highly visible, making cosmetic results of utmost importance. It is also important to retain the supra-auricular sulcus to enable patients to wear glasses and hearing aids [5]. The objectives of surgical treatment of BCCs and SCCs are: (1) to cure by achieving histological confirmed complete excision of the tumour with a clear margin in width and depth, (2) to maintain normal function where possible, and (3) to achieve a good cosmetic result [6]. Repair options of the middle and upper third of the ear include: side to side closure, wedge excision, bilobed transposition flap, banner transposition flap, helical crus rotation flap, helical rim advancement flap, and full thickness graft. The epidermis on the convex (posterior) aspect of the ear has a thicker subcutis of fat. This allows for a degree of laxity and movement as compared to the concave (anterior) aspect surface. The V to Y full thickness graft (V2YFTG) to repair defects on the helical rim makes use of this laxity (Figure 1). Once the FTG has been mobilised from the donor site on the convex aspect of the ear, it is advanced forward to cover the defect on the helical rim where the cancer has been excised (Figure 2). The FTG is then sutured and if necessary a bolster tied over the area to minimise haematoma collection under the graft. Sutures are removed after seven days. The principle of closure is similar to a V to Y island flap without the attached pedicle. Advantages of the V2Y FTG include: (1) one wound only to manage, (2) good skin match and good cosmetic result, (3) less pain for the patient (particularly with wedge excisions), and (4) a relatively easy procedure to perform.

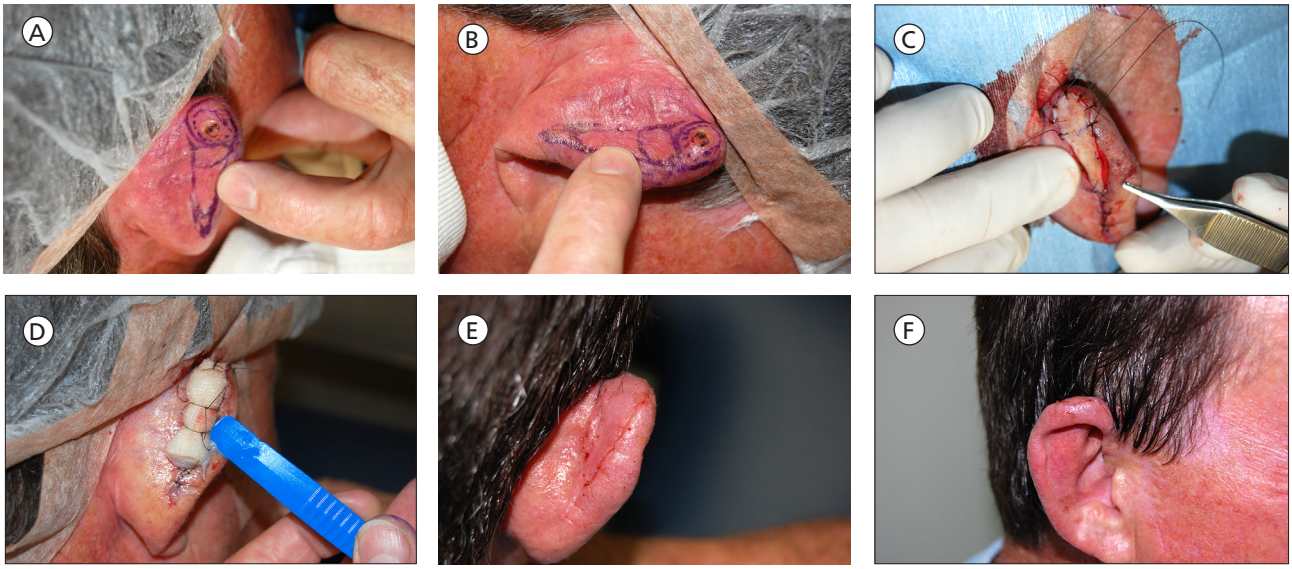

Figure 2. (A) Cancer with margins on the helical rim and the full thickness graft donor area outlined. (B) Cancer with margins on helical rim and full thickness graft donor on the posterior ear outlined. (C) Full thickness graft after being moved forward to cover the defect being sutured into place. (D) Bolster sutured over the full thickness graft. (E) Posterior ear view after removal of sutures one week post surgery. (F) Anterior ear view after removal of sutures one week post surgery. [Copyright: ©2012 Sivyer.]

References

1. Basal cell carcinoma, squamous cell carcinoma (and related lesions)—a guide to clinical management in Australia. Cancer Council Australia and Australian Cancer Network. Sydney, 2008:4.
2. Weedon D. *Weedon's Skin Pathology.* 3rd ed. London, England: Churchill Livingstone Elsevier 2010:682-3.
3. Basal cell carcinoma, squamous cell carcinoma (and related lesions)—a guide to clinical management in Australia. Cancer Council Australia and Australian Cancer Network. Sydney, 2008,51.
4. Basal cell carcinoma, squamous cell carcinoma (and related lesions)—a guide to clinical management in Australia. Cancer Council Australia and Australian Cancer Network. Sydney, 2008:53.
5. Paver R, Stanford D, Storey L. *Dermatologic Surgery: A Manual of Defect Repair Options.* Australia: McGraw Hill. 2011:243-95.
6. Basal cell carcinoma, squamous cell carcinoma (and related lesions)—a guide to clinical management in Australia. Cancer Council Australia and Australian Cancer Network. Sydney, 2008:44.