MAYO CLINIC

Severe Spruelike Enteropathy Associated With Olmesartan

Alberto Rubio-Tapia, MD; Margot L. Herman, MD; Jonas F. Ludvigsson, MD, PhD; Darlene G. Kelly, MD, PhD; Thomas F. Mangan, MD; Tsung-Teh Wu, MD, PhD; and Joseph A. Murray, MD

Abstract

Objective: To report the response to discontinuation of olmesartan, an angiotensin II receptor antagonist commonly prescribed for treatment of hypertension, in patients with unexplained severe spruelike enteropathy.

Patients and Methods: All 22 patients included in this report were seen at Mayo Clinic in Rochester, Minnesota, between August 1, 2008, and August 1, 2011, for evaluation of unexplained chronic diarrhea and enteropathy while taking olmesartan. Celiac disease was ruled out in all cases. To be included in the study, the patients also had to have clinical improvement after suspension of olmesartan.

Results: The 22 patients (13 women) had a median age of 69.5 years (range, 47-81 years). Most patients were taking 40 mg/d of olmesartan (range, 10-40 mg/d). The clinical presentation was of chronic diarrhea and weight loss (median, 18 kg; range, 2.5-57 kg), which required hospitalization in 14 patients (64%). Intestinal biopsies showed both villous atrophy and variable degrees of mucosal inflammation in 15 patients, and marked subepithelial collagen deposition (collagenous sprue) in 7. Tissue transglutaminase antibodies were not detected. A gluten-free diet was not helpful. Collagenous or lymphocytic gastritis was documented in 7 patients, and microscopic colitis was documented in 5 patients. Clinical response, with a mean weight gain of 12.2 kg, was demonstrated in all cases. Histologic recovery or improvement of the duodenum after discontinuation of olmesartan was confirmed in all 18 patients who underwent follow-up biopsies.

Conclusion: Olmesartan may be associated with a severe form of spruelike enteropathy. Clinical response and histologic recovery are expected after suspension of the drug.

© 2012 Mayo Foundation for Medical Education and Research ■ Mayo Clin Proc. 2012;87(8):732-738

From the Division of Gastroenterology and Hepatology (A.R.-T., J.F.L., D.G.K., T.F.M., J.A.M.), Department of Internal Medicine (M.L.H.), and Department of Laboratory Medicine and Pathology (T.-T.W.), Mayo Clinic, Rochester, MN; Clinical Epidemiology Unit, Department of Medicine, Karolinska University Hospital and Karolinska Institutet, Stockholm, Sweden (J.F.L.); and Department of Pediatrics, Örebro University Hospital, Örebro University, Örebro, Sweden (J.F.L.).

Olmesartan is one of several angiotensin II receptor antagonists used for management of hypertension since 2002.[1] Diarrhea is a common adverse effect of many medications, although the mechanisms underlying diarrhea remain unclear in most cases. Enteropathy as a cause of drug-induced diarrhea has been reported previously with the use of azathioprine and mycophenolate mofetil.[2-4] We first suspected the possible connection between enteropathy and olmesartan when 2 consecutive patients referred to our institution for evaluation of presumed refractory celiac disease reported unexplained clinical improvement during hospitalization but prompt relapse following hospital discharge. They asked if the disease course could have been due to their hypertensive medications, which were withheld on hospitalization because of hypotension. At the same time, we were studying a cohort of patients with collagenous sprue and discovered olmesartan use in one-third of the patients with a recent diagnosis of the disorder.[5] As additional patients were identified with similar clinical features (eg, chronic diarrhea, weight loss, unexplained spruelike enteropathy with or without abnormal subepithelial collagen deposition, negative celiac serology, and lack of response to gluten exclusion), a perceived association between these features and olmesartan evolved. It also became clear that these patients were unlikely to have celiac disease, as all lacked IgA tissue transglutaminase antibodies and had never responded to a gluten-free diet. The clinical observation of improvement of gastrointestinal symptoms and subsequent demonstration of histologic recovery after olmesartan withdrawal prompted us to advise our patients with unexplained spruelike enteropathy to discontinue olmesartan. We reported our observation to US Food and Drug Administration officials and submitted reports using the MedWatch system.

In this article, we describe the clinical manifestations in 22 patients with unexplained spruelike enteropathy that improved clinically after discontinuation of olmesartan.

PATIENTS AND METHODS

This study was approved by the Mayo Clinic Institutional Review Board. Patients were considered for inclusion in the study if they had chronic diarrhea (>4 weeks) while taking olmesartan and met 2 additional criteria. First, the cause of their enteropathy

could not be established after a systematic diagnostic evaluation that included investigation for disorders associated with nonresponsive celiac disease as previously reported by our group.[6] Second, they had to improve clinically after discontinuation of olmesartan. Most of these patients had undergone extensive evaluation by their referring physicians and had had several therapeutic trials, without benefit. The electronic medical records of 24 such patients seen at Mayo Clinic in Rochester, Minnesota, between August 1, 2008, and August 1, 2011, were reviewed by one physician (M.L.H.). Two of the 24 patients were excluded from the study, 1 who had tropical sprue and 1 who improved clinically and histologically with oral budesonide before suspension of olmesartan.

Data Abstraction

Clinical and laboratory data were abstracted from the medical record. Only data that reflected conditions that existed before suspension of olmesartan were included as baseline data. We defined categories of body weight using body mass index and World Health Organization criteria.[7] Anemia was defined in women as a hemoglobin level of less than 12 g/dL (to convert to g/L, multiply by 10) and in men as a hemoglobin level of less than 13.5 g/dL. Hypoalbuminemia was defined as an albumin value lower than 3.5 g/dL (to convert to g/L, multiply by 10). HLA-DQ typing,[8] celiac disease serology (tissue transglutaminase antibodies or deamidated gliadin peptide antibodies by enzyme-linked immunosorbent assay and endomysial antibodies on monkey esophagus by indirect immunofluorescence),[9-11] and assessment of response to a gluten-free diet were investigated. Anti-enterocyte antibodies were tested using primate intestine by indirect immunofluorescence and were performed at The Children's Hospital of Philadelphia, as reported by Akram et al.[12] *Severe enteropathy* was defined by the presence of at least one of the following criteria: (1) need for hospitalization because of severe dehydration, electrolyte imbalance, and/or acute renal failure, (2) need for total parenteral nutrition, and (3) weight loss of more than 10 kg.

Histopathology

Pathology material (biopsy samples from the gastrointestinal tract) was reviewed by one of the authors (T.-T.W.). The number of intraepithelial lymphocytes per 100 epithelial cells, degree of villous atrophy graded with the modified Marsh classification,[13] presence of subepithelial collagen, degree of lamina propria inflammation, and presence of acute inflammation were assessed. The presence of aberrant or clonal intraepithelial lymphocytes was investigated by CD3 and CD8 immunostaining[14] and polymerase chain reaction,[15] respectively. When multiple small bowel biopsies were performed as part of the diagnostic evaluation and before withdrawal of the drug, the baseline biopsy was considered to be the small bowel biopsy performed closest to the date of suspension of olmesartan. Follow-up biopsies were defined as biopsies performed at least 30 days after the date of suspension of olmesartan. Other disorders of the gastrointestinal tract (when present) were diagnosed using accepted pathologic criteria (eg, microscopic colitis).[16]

Outcomes After Suspension of Olmesartan

Clinical response was defined as the resolution of diarrhea. Weight gain was considered a positive finding. *Remission* required both a clinical response and confirmation by normal findings on intestinal biopsy during follow-up. All patients who had been on a gluten-free diet were followed up after reintroduction of gluten and withdrawal of corticosteroids.

Medication Use

We reviewed the medication history of all patients, including the duration of treatment, dosage, and response of diarrhea to a trial of olmesartan withdrawal. Alternative antihypertensive drugs used after suspension of olmesartan are reported.

Statistical Analyses

Data were summarized using descriptive statistics, including total numbers and percentages for categorical variables and median or mean (range) for continuous variables.

RESULTS

The 22 patients (13 women) had a median age of 69.5 years (range, 47-81 years). Twenty-one of the patients were non-Hispanic white, and 1 patient was black. Patients were residents of 16 different US states (Table 1).

The most frequent clinical diagnoses at time of referral were nonresponsive/refractory celiac disease (n=10) and unexplained sprue (n=6). Most patients were taking 40 mg/d of olmesartan (range, 10-40 mg/d) for several months or years before the onset of diarrhea. Detailed information about the duration of exposure to olmesartan before onset of diarrhea was available in the medical record in 14 patients (64%). Among these, the mean duration was 3.1 years (range, 0.5-7 years). An additional 5 patients were taking olmesartan for at least 1 year before the onset of symptoms. Information about duration of exposure to olmesartan before onset of diarrhea was not available in 3 patients.

TABLE 1. Demographic Characteristics, Outcome, and Alternative Antihypertensive Drugs Used After Suspension of Olmesartan in 22 Patients With Spruelike Enteropathy

Patient No./ sex/age (y)	Weight loss (kg)	Outcome after suspension of olmesartan[a]	Alternative antihypertensive drug
1/F/59	14	Remission	Metoprolol
2/F/62	11	Clinical response	None
3/F/72	31	Remission, weight gain (13.3 kg)	Bisoprostol-hydrochlorothiazide
4/M/66[b]	18	Remission, weight gain (11 kg)	Metoprolol
5/M/81	2.5	Remission, weight loss (4.1 kg)	Lisinopril, metoprolol
6/M/64	14	Clinical response	Amlodipine
7/F/65	11	Remission, weight gain (4.2 kg)	Amlodipine, hydrochlorothiazide
8/M/76	12	Remission, weight gain (13.4 kg)	Amlodipine, hydrochlorothiazide
9/M/64	20.5	Remission, weight gain (15.7 kg)	Amlodipine, hydrochlorothiazide
10/F/72	30	Remission, weight gain (28 kg)	Amlodipine, atenolol, hydrochlorothiazide
11/M/74	15	Clinical response	Hydrochlorothiazide
12/M/58	57	Remission, weight gain (23.4 kg)	Amlodipine, metoprolol
13/F/77	29	Remission, weight gain (9.7 kg)	Atenolol, hydrochlorothiazide
14/F/76	7	Remission, weight gain (2.9 kg)	Hydrochlorothiazide
15/M/68	18	Remission, weight gain (14.9 kg)	Metoprolol
16/F/71	9	Remission, weight gain (11.9 kg)	Triamterene, hydrochlorothiazide
17/F/66[b]	20.5	Clinical response, weight gain (13.4 kg)	Spironolactone, carvedilol
18/F/64[c]	50	Clinical response, weight gain (4 kg)	Amlodipine
19/F/75	41	Remission	None
20/M/47	32	Remission, weight gain (13.9 kg)	Metoprolol, amlodipine, doxazosin
21/F/71	18	Remission, weight gain (10.2 kg)	Atenolol, hydralazine
22/F/74	40	Remission, weight gain (6.3 kg)	None

[a] Weight change (defined by weight at diagnosis minus weight at last follow-up visit) is provided when available in the medical record.
[b] Case previously published.[5]
[c] Non-Hispanic black.

Clinical Manifestations

Diarrhea had been present for a median of 19.2 months (range, 3-53 months) before suspension of the drug. At the time of presentation, all patients had diarrhea and weight loss (median weight loss, 18 kg; range, 2.5-57 kg). Nausea and vomiting were present in 15 patients (68%), abdominal pain in 11 (50%), bloating in 9 (41%), and fatigue in 15 (68%). The onset of diarrhea was sudden in 9 patients. The stool frequency was extremely abnormal, with a median of 6 evacuations per day (range, 3-42 evacuations per day). Among 8 patients with timed stool collection, the mean stool weight was 933.1 g/24 h (range, 225-3225 g/24 h), and mean fecal fat was 28.3 g/24 h (range, 8-50 g/24 h). Although timed stool weight was not investigated in all patients, 14 patients (64%) required hospitalization because of severe dehydration (4 patients had acute renal failure). Total parenteral nutrition was necessary in 4 patients. At the time of the first visit at Mayo Clinic, 11 of the patients had normal weight, 6 were underweight, 4 were overweight, and 1 was obese. All but one patient (patient 16) met criteria for severe enteropathy.

Laboratory Findings

Results of IgA tissue transglutaminase antibody testing were negative in all patients. IgA endomysial antibody results were negative in all 9 patients who underwent testing. HLA-DQ typing was performed in 21 patients: DQ2 was present in 15 patients, DQ8 in 2 patients, and neither DQ2 nor DQ8 in 4 patients. Anti-enterocyte antibody testing was done in 19 patients (86%), and results were negative in 16 (including 7 patients who had a positive nonspecific nuclear pattern of unknown clinical significance) and positive with a linear/apical pattern in 3.

Fourteen patients (64%) had normocytic normochromic anemia (2 had elevated red blood cell distribution width suggesting anisocytosis); the lowest hemoglobin level was 9.3 g/dL. Ten patients (45%) had hypoalbuminemia; the lowest albumin

level was 2 g/dL. Twelve patients (55%) had one (n=3) or multiple (n=9) electrolyte abnormalities. Zinc deficiency was documented in 7 patients.

Small bowel bacterial overgrowth was confirmed by culture of duodenal aspirate (>10^5 colony-forming units per milliliter) in 12 patients at some point during clinical evolution. A trial of oral antibiotics was used in 10 patients without clinical benefit (rifaximin in 5, tetracycline in 3, ciprofloxacin in 1, and ciprofloxacin-metronidazole in 1). An additional 2 patients received no therapy for small bowel bacterial overgrowth.

Histologic Findings

In all patients, baseline intestinal biopsies demonstrated villous atrophy with variable degrees of mucosal inflammation (Table 2). Total villous atrophy was observed in 15 patients and partial villous atrophy in 7 patients. A thick band of subepithelial collagen deposition (collagenous sprue) was seen in 7 patients (2 cases had been reported previously[5]). Active/acute inflammation was observed in 15 patients, and increased intraepithelial lymphocytes were found in 14 patients. Aberrant (or clonal) intraepithelial lymphocytes were not detected among the 12 patients tested.

Colonoscopy with random colonic biopsies was performed in 13 patients (59%). Microscopic colitis was found in 5 patients (2 had lymphocytic colitis and 3 had collagenous colitis).

Biopsies of the stomach were available in 14 patients (64%). Lymphocytic gastritis was diagnosed in 5 patients and collagenous gastritis in 2 patients. Chronic gastritis was diagnosed in an additional 7 patients (1 had *Helicobacter pylori* infection).

Treatment and Subsequent Course

Most of the patients in our study had undergone several therapeutic trials, without apparent clinical benefit, before referral to Mayo Clinic, including the use of a gluten-free diet for months (n=20), systemic corticosteroids and/or budesonide (n=20), opioid-derived antidiarrheal agents (most often loperamide) (n=10), pancreatic enzymes (n=4), bile acid sequestrant (n=4), metronidazole (n=4), azathioprine (n=3), and octreotide (n=3).

Clinical response was observed in all 22 patients after suspension of olmesartan. Besides tapering of corticosteroids, no medication was needed to control diarrhea after clinical response was achieved with suspension of the drug. Patients following a gluten-free diet were advised to abandon the diet immediately if they lacked the celiac susceptibility genotypes or to gradually reintroduce gluten if they were HLA-DQ2 or DQ8 positive. No patient had recurrence of symptoms after restarting a gluten-containing diet. Follow-up body weight after suspension of olmesartan was available in 17 patients; 16 had weight gain, with a mean weight gain of 12.2 kg (range, 2.9-28 kg), and 1 patient (patient 5) who had edema at diagnosis lost 4.1 kg during follow-up despite clinical remission.

At the time of this report, follow-up intestinal biopsies have been performed in 18 patients (82%) after a mean of 242.3 days (range, 54-707 days) from the date of suspension of olmesartan. Histologic recovery of the duodenum was documented in 17 patients (Figure). Focal partial villous atrophy was observed in 1 case (patient 2) on a follow-up duodenal biopsy obtained 54 days after suspension of olmesartan. Follow-up gastric biopsies were performed at the same time as repeated biopsy of the duodenum in 6 of the 7 patients with either lymphocytic or collagenous gastritis (no gastric biopsy results were available for patient 11). Follow-up gastric biopsies showed normal mucosa in 4 patients and nonspecific mild chronic gastritis in 2 patients (patients 20 and 22). Follow-up colonoscopies with biopsies of the colon were not performed in the 5 patients with microscopic colitis.

DISCUSSION

We describe a group of patients with unexplained severe spruelike enteropathy while taking olmesartan. We also provide evidence of both clinical and histologic improvement after suspension of olmesartan. Celiac disease was excluded by conventional methods of serology and the absence of clinical response to a gluten-free diet.[17] Other less common enteropathies were excluded (Table 3).

We acknowledge that this case series lacks all the information necessary to prove causality but rather reflects an association. No deliberate rechallenge test with olmesartan was undertaken because of the life-threatening nature of the syndrome, although 2 patients reported anecdotally that their symptoms had worsened when they restarted olmesartan before the potential association was recognized, and 2 patients experienced improvement when olmesartan was stopped when they were hospitalized (for dehydration and hypotension) and worsened in the weeks following discharge and reintroduction of olmesartan. Resolution of the presenting symptoms and subsequent histologic improvement after suspension of olmesartan, in the absence of clinical evidence of other diseases associated with enteropathy, suggest that the association is not likely to be due to chance.

Pathologic findings in the duodenal biopsy can mimic celiac disease or collagenous sprue. Clinicopathologic correlation is advised to confirm the diagnosis of olmesartan-associated enteropathy. Pathologic evidence of involvement of other organs (eg, the

TABLE 2. Histologic Findings in 22 Patients With Spruelike Enteropathy Associated With Olmesartan[a]

Patient No.	Baseline duodenal biopsy results: Villous atrophy	IELs (/100 epithelial cells)[b]	Acute/active inflammation	Thickened collagen band	Aberrant cells/clone[c]	Outcome follow-up duodenal biopsy results	Time d[d]	Other GI findings[e]: Gastric	Colorectal
1	Total	Normal	Yes	No	No/No	Normal	404	Lymphocytic gastritis (HP negative, immunostain)	Collagenous colitis
2	Total	80-100	Yes	Yes	No/NA	Improvement, focal partial villous atrophy	54	Chronic gastritis (HP negative, immunostain)	Normal
3	Total	Normal	Yes	No	No/No	Normal	231	NA	Collagenous colitis
4	Total	40	Yes	Yes	No/No	Normal	263	Collagenous gastritis	NA
5	Total	>100	Yes	No	NA/NA	Normal	54	NA	Normal
6	Partial	60	Yes	No	NA/NA	NA	NA	NA	NA
7	Partial	>100	No	No	No/No	Normal	159	NA	Normal
8	Total	40-60	Yes	No	NA/NA	Normal	143	Lymphocytic gastritis (HP negative, immunostain)	Normal
9	Total	60-80	Yes	No	No/No	Normal	188	NA	NA
10	Partial	Normal	No	No	No/No	Normal	404	NA	NA
11	Partial	50	Yes	No	No/No	NA	NA	Mild lymphocytic gastritis (HP negative, immunostain)	NA
12	Partial	Normal	Yes	No	No/No	Normal, focal active duodenitis	116	Mild active chronic gastritis (HP negative, immunostain)	Mild active chronic colitis
13	Total	40	Yes	Yes	NA/NA	Normal	171	Active chronic gastritis (HP negative, immunostain)	NA
14	Partial	60-80	No	No	NA/NA	Normal	240	Mild active chronic gastritis (HP negative, immunostain)	NA
15	Total	Normal	No	Yes	NA/NA	Normal	181	Mild chronic gastritis (HP negative, no immunostain)	Normal
16	Total	Normal	No	Yes	No/No	Normal	607	Collagenous gastritis	Collagenous colitis
17	Total	40-60	Yes	Yes	No/No	NA	NA	Mild chronic gastritis (HP negative, no immunostain)	Focal acute colitis
18	Partial	Normal	No (marked eosinophilia)	No	NA/NA	NA	NA	NA	NA
19	Total	30	Yes	No	NA/NA	Normal	76	Severe active chronic gastritis and ulceration (HP negative, immunostain)	NA
20	Total	Normal	No	Yes	No/No	Normal	707	Lymphocytic gastritis (HP positive)	Lymphocytic colitis
21	Total	80-100	Yes	No	NA/NA	Normal	179	NA	Lymphocytic colitis
22	Total	80	Yes	No	NA/NA	Normal	184	Lymphocytic gastritis (HP negative, immunostain)	Normal

[a] HP = *Helicobacter pylori*; IELs = intraepithelial lymphocytes; NA = not available.
[b] Normal, <25/100 epithelial cells.
[c] Aberrant cells defined by >50% $CD3^+/CD8^-$ IELs on immunostaining; clone defined by T-cell receptor gene clonal rearrangement by polymerase chain reaction.
[d] Time from suspension of olmesartan to follow-up biopsy.
[e] Any time before suspension of olmesartan.

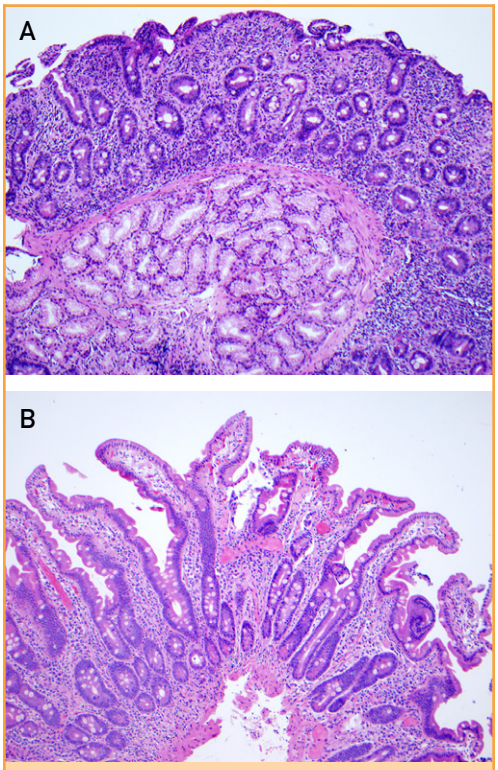

FIGURE. Photomicrographs showing reversible spruelike enteropathy associated with olmesartan (hematoxylin-eosin, original magnification ×100). A, Duodenal biopsy specimen obtained while the patient was taking olmesartan shows total villous atrophy and intraepithelial lymphocytosis. B, Biopsy specimen obtained 6 months after withdrawal of olmesartan and initiation of a gluten-containing diet shows recovery of villi on duodenal mucosa.

stomach and colon) suggests that this disorder may affect the entire gastrointestinal tract. We provide evidence of resolution of inflammation and/or fibrosis in the stomach and duodenum after suspension of olmesartan, implying that these changes are associated with the use of olmesartan. Even though follow-up colonoscopies were not performed in the 5 patients with documented microscopic colitis, clinical remission was achieved in all of these patients, a very unlikely outcome in the presence of persistent inflammation or fibrosis of the colon. Recovery of duodenal mucosa in a relatively short time (median of 8 months from suspension of olmesartan to follow-up biopsies) is a relevant clinical observation because mucosal recovery in other small bowel disorders, such as celiac disease, may take years to occur despite adherence to a gluten-free diet, especially in older adults.[18,19]

Finding small bowel bacterial overgrowth in 12 patients is intriguing and consistent with prior observations of association of small bowel bacterial overgrowth and enteropathy in symptomatic patients with celiac disease.[20,21] The reason for this association is unknown. Thus, although small bowel bacterial overgrowth is a well-recognized cause of chronic diarrhea in the right clinical setting,[22] in this series, the lack of clinical response to oral antibiotics suggests that gastrointestinal symptoms are not explained by the effects of an increased number of bacteria in the small bowel.

The mechanisms underlying olmesartan-associated enteropathy are unknown. The long delay between onset of olmesartan therapy and the development of diarrhea (and enteropathy) suggests cell-mediated immunity damage rather than type I hypersensitivity. Recently, angiotensin receptor blockers have been suggested to have inhibitory effects on transforming growth factor β action.[23,24] Transforming growth factor β is crucially important in the maintenance of gut immune homeostasis.[25,26] Olmesartan is an orally administrated prodrug (olmesartan medoxomil) that is rapidly metabolized to the active component (olmesartan) by esterases in the gastrointestinal mucosa, portal blood, and liver.[27] Nevertheless, the possible role of transforming growth factor β inhibition in olmesartan-associated enteropathy is a question that requires investigation. We do not know if other angiotensin II receptor blockers can be associated with a similar form of enteropathy, but active investigation for similar cases among patients using other drugs of the same class is under way. All our patients with olmesartan-associated enteropathy received antihypertensive drugs from a different class after suspension of olmesartan. HLA-DQ2 was present in 68% of patients with olmesartan-associated enteropathy, a prevalence higher than the 25% to 30% expected for the general population,[28,29] suggesting that perhaps

TABLE 3. Clinical Features of Spruelike Enteropathy Associated With Olmesartan

Gastrointestinal symptoms (eg, chronic diarrhea, weight loss, steatorrhea)
Negative IgA tissue transglutaminase antibodies (or endomysial antibodies)
Evidence of enteropathy (villous atrophy) with or without collagen deposition or intraepithelial lymphocytosis
Lack of clinical response to gluten exclusion
Exclusion of other causes of enteropathy (eg, celiac disease)
Evidence of clinical and histologic improvement after suspension of olmesartan

the presence of HLA-DQ2 may increase the risk of immune-mediated damage in these patients. This may be another example of drug-associated enteropathy of which the medical community should be aware and could result in the identification of several more cases.

CONCLUSION

We report a unique case series to support a novel association between severe spruelike enteropathy and olmesartan. Physicians who encounter patients with diarrheal syndromes should consider medications as a cause, although the potential role for olmesartan had not been considered in these patients by any of the physicians prescribing the medications or treating the diarrheal illness.

Grant Support: This study was supported by National Institutes of Health grant R01-DK57892 (J.A.M.); American College of Gastroenterology Junior Faculty Development Award (A.R.-T.); The Swedish Society of Medicine, the Swedish Research Council – Medicine (522-2A09-195), the Swedish Celiac Society, and the Fulbright Commission (J.F.L.).

Correspondence: Address to Joseph A. Murray, MD, Division of Gastroenterology and Hepatology, Mayo Clinic, 200 First St SW, Rochester, MN 55905 (murray.joseph@mayo.edu).

REFERENCES

1. The Seventh Report of the Joint National Committee on Prevention, Detection, Evaluation, and Treatment of High Blood Pressure. Bethesda, MD: National Institutes of Health, National Heart, Lung, and Blood Institute, US Department of Health and Human Services; 2004. NIH Publication No. 04-5230.
2. Ziegler TR, Fernández-Estívariz C, Gu LH, Fried MW, Leader LM. Severe villus atrophy and chronic malabsorption induced by azathioprine. *Gastroenterology*. 2003;124(7):1950-1957.
3. Kamar N, Faure P, Dupuis E, et al. Villous atrophy induced by mycophenolate mofetil in renal-transplant patients. *Transpl Int*. 2004;17(8):463-467.
4. Weclawiak H, Ould-Mohamed A, Bournet B, et al. Duodenal villous atrophy: a cause of chronic diarrhea after solid-organ transplantation. *Am J Transplant*. 2011;11(3):575-582.
5. Rubio-Tapia A, Talley NJ, Gurudu SR, Wu TT, Murray JA. Gluten-free diet and steroid treatment are effective therapy for most patients with collagenous sprue. *Clin Gastroenterol Hepatol*. 2010;8(4):344-349.e3.
6. Abdulkarim AS, Burgart LJ, See J, Murray JA. Etiology of nonresponsive celiac disease: results of a systematic approach. *Am J Gastroenterol*. 2002;97(8):2016-2021.
7. Global Database on Body Mass Index. World Health Organization Web site. http://apps.who.int/bmi/index.jsp?introPage=intro_3.html. Updated August 6, 2011. Accessed April 12, 2012.
8. Olerup O, Aldener A, Fogdell A. HLA-DQB1 and -DQA1 typing by PCR amplification with sequence-specific primers (PCR-SSP) in 2 hours. *Tissue Antigens*. 1993;41(3):119-134.
9. Collin P, Kaukinen K, Vogelsang H, et al. Antiendomysial and antihuman recombinant tissue transglutaminase antibodies in the diagnosis of coeliac disease: a biopsy-proven European multicentre study. *Eur J Gastroenterol Hepatol*. 2005;17(1):85-91.
10. Chorzelski TP, Beutner EH, Sulej J, et al. IgA anti-endomysium antibody: a new immunological marker of dermatitis herpetiformis and coeliac disease. *Br J Dermatol*. 1984;111(4):395-402.
11. Ladinser B, Rossipal E, Pittschieler K. Endomysium antibodies in coeliac disease: an improved method. *Gut*. 1994;35(6):776-778.
12. Akram S, Murray JA, Pardi DS, et al. Adult autoimmune enteropathy: Mayo Clinic Rochester experience. *Clin Gastroenterol Hepatol*. 2007;5(11):1282-1290; quiz 1245.
13. Marsh MN. Gluten, major histocompatibility complex, and the small intestine: a molecular and immunobiologic approach to the spectrum of gluten sensitivity ('celiac sprue'). *Gastroenterology*. 1992;102(1):330-354.
14. Patey-Mariaud De Serre N, Cellier C, Jabri B, et al. Distinction between coeliac disease and refractory sprue: a simple immunohistochemical method. *Histopathology*. 2000;37(1):70-77.
15. Ashton-Key M, Diss TC, Pan L, Du MQ, Isaacson PG. Molecular analysis of T-cell clonality in ulcerative jejunitis and enteropathy-associated T-cell lymphoma. *Am J Pathol*. 1997;151(2):493-498.
16. Pardi DS, Kelly CP. Microscopic colitis. *Gastroenterology*. 2011;140(4):1155-1165.
17. Rostom A, Murray JA, Kagnoff MF. American Gastroenterological Association (AGA) Institute technical review on the diagnosis and management of celiac disease. *Gastroenterology*. 2006;131(6):1981-2002.
18. Rubio-Tapia A, Rahim MW, See JA, Lahr BD, Wu TT, Murray JA. Mucosal recovery and mortality in adults with celiac disease after treatment with a gluten-free diet. *Am J Gastroenterol*. 2010;105(6):1412-1420.
19. Wahab PJ, Meijer JW, Mulder CJ. Histologic follow-up of people with celiac disease on a gluten-free diet: slow and incomplete recovery. *Am J Clin Pathol*. 2002;118(3):459-463.
20. Tursi A, Brandimarte G, Giorgetti G. High prevalence of small intestinal bacterial overgrowth in celiac patients with persistence of gastrointestinal symptoms after gluten withdrawal. *Am J Gastroenterol*. 2003;98(4):839-843.
21. Rubio-Tapia A, Barton SH, Rosenblatt JE, Murray JA. Prevalence of small intestine bacterial overgrowth diagnosed by quantitative culture of intestinal aspirate in celiac disease. *J Clin Gastroenterol*. 2009;43(2):157-161.
22. Teo M, Chung S, Chitti L, et al. Small bowel bacterial overgrowth is a common cause of chronic diarrhea. *J Gastroenterol Hepatol*. 2004;19(8):904-909.
23. Matt P, Schoenhoff F, Habashi J, et al; GenTAC Consortium. Circulating transforming growth factor-beta in Marfan syndrome. *Circulation*. 2009;120(6):526-532.
24. Kagami S, Border WA, Miller DE, Noble NA. Angiotensin II stimulates extracellular matrix protein synthesis through induction of transforming growth factor-beta expression in rat glomerular mesangial cells. *J Clin Invest*. 1994;93(6):2431-2437.
25. Macdonald TT, Monteleone G. Immunity, inflammation, and allergy in the gut. *Science*. 2005;307(5717):1920-1925.
26. Coombes JL, Robinson NJ, Maloy KJ, Uhlig HH, Powrie F. Regulatory T cells and intestinal homeostasis. *Immunol Rev*. 2005;204:184-194.
27. Scott LJ, McCormack PL. Olmesartan medoxomil: a review of its use in the management of hypertension. *Drugs*. 2008;68(9):1239-1272.
28. Sollid LM, Markussen G, Ek J, Gjerde H, Vartdal F, Thorsby E. Evidence for a primary association of celiac disease to a particular HLA-DQ alpha/beta heterodimer. *J Exp Med*. 1989;169(1):345-350.
29. Kaukinen K, Partanen J, Mäki M, Collin P. HLA-DQ typing in the diagnosis of celiac disease. *Am J Gastroenterol*. 2002;97(3):695-699.