Interventional Neuroradiology 10 (Suppl 1): 93-96, 2004

Treatment Outcome of Carotid Stenting and CEA in the Same Period

E. KOBAYASHI, Y. UCHINO, J. ONO*, A. YAMAURA

Department of Neurosurgery, Chiba University School of Medicine
**Department of Neurosurgery, Chiba Cardiovascular Center; Japan*

Key words: stents, carotid arteries, CEA, follow-up

Summary

Angioplasty with stent deployment is a promising option for the treatment of carotid stenosis. However, the definite treatment indication is still unknown through lack of scientific evidences in the randomized controlled trial, which is now on going. We compared the short-term outcome, such as periprocedural complication rate, cerebral blood flow, subsequent ischemic events and restenosis, between carotid stenting (CS) and carotid endarterectomy (CEA) in the same period to investigate the justice of our present indication for CS.

Fifty-five patients with carotid stenosis greater than 70% were treated by CS or CEA in a constant indication. Twenty-five times of CEA were indicated in patients who satisfied the inclusion criteria of NASCET without the exclusion criteria, 30 times of CS in patients with the exclusion criteria. No major procedure-related complication was found in either group. One patient (3.3%) in CS group suffered a minor ischemic stroke during the procedure, just after postdilatation. One patient underwent myocardial infarction in CEA group, and one patient congestive heart failure in CS group within one week after the procedure. During a mean follow-up period of 19 months, no further stroke occurred in either group. There was no lesion-related mortality, but one patient in each group was dead of heart disease. As for restenosis, one patient in each group showed recurrent stenosis on angiogram 12 and 24 months after the treatment. Restenosis rate calculated by the person-year method in CEA and CS group was almost same, 2.3% per year.

Stenting seemed to be so safe and effective for cases refractory to CEA that the present indication for CS is thought to be reasonable, though it is necessary to draw a decisive conclusion in randomized trials.

Introduction

Stent deployment can be now performed for the treatment of extracranial carotid stenotic lesions, with the recent advances in interventional neuroradiology. The procedure is thought to be getting safer, especially with introduction of distal balloon protection system (PercuSurge GuardWire™ system), the definite indication of this treatment is unclear through lack of scientific evidences. While many scientific evidences has been accumulated in carotid endarterectomy (CEA) since early '80s, many patients with exclusion criteria for CEA still have no evidence as to prevention of further stroke. So far we have experienced fifty-five patients with severe carotid stenotic lesions in a constant indication after the introduction of carotid stenting (CS). We compared the short-term outcome be-

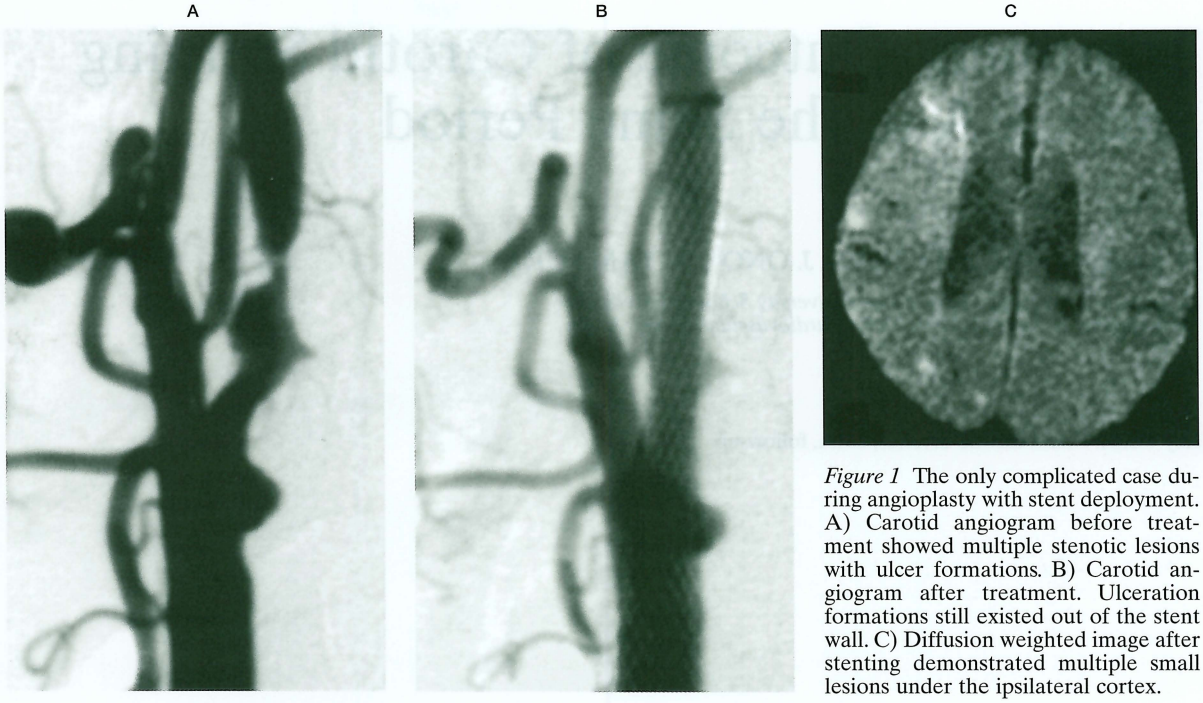

Figure 1 The only complicated case during angioplasty with stent deployment. A) Carotid angiogram before treatment showed multiple stenotic lesions with ulcer formations. B) Carotid angiogram after treatment. Ulceration formations still existed out of the stent wall. C) Diffusion weighted image after stenting demonstrated multiple small lesions under the ipsilateral cortex.

tween carotid stenting (CS) and carotid endarterectomy (CEA) to investigate the justice of our present indication for CS.

Material and Methods

From March 1998 to April 2002, CS was performed in 30 patients and CEA was carried out in 25 patients with severe extracranial carotid stenosis. The age of the patients varied from 52 to 78 years, the mean age in CS and CEA group was 67.5 ± 7.8 and 64.7 ± 8.9, respectively. The mean stenosis rate in CS and CEA group was 84% and 80%, and symptomatic rate was 83% and 68%, respectively. The baseline characteristics in each group were showed in table 1.

All CS procedures but one were performed with distal balloon protection during postdilatation, and all CEA procedures were done with an indwelling shunt system. The endovascular procedure was carried out from a transfemoral approach under local anesthesia and full heparinazation. Activated clotting time (ACT) was maintained in the range from 2 to 2.5 times as long as preprocedural control one. The used stents were Palmaz stent, Easy Wallstent, SMART stent and S670 stent. After placement of 9 Fr angio-sheath at the femoral artery, a coaxial catheter was introduced to the common carotid artery on the lesion side, 0.014" or 0.010" microguidewire was passed across the stenosis and then a predilatation balloon catheter followed by stent deployment was navigated over the wire. Postdilatation in the stent lumen was performed with distal balloon protection system (NaviballoonTM). Atheromatous debris that arose from postdilatation was removed by aspiration or flushing into the external carotid artery. Occlusion time was usually three to six minutes. Full heparinization was maintained for 48 hours after stenting and then oral anti-platelets were administered.

CEA was performed under general anesthesia. Patch graft or stay suture was occasionally used if necessary. Intraoperative cerebral blood flow (CBF) was monitored by near infrared spectroscopy. The operation was done only by a expert surgeon who had acceptable procedure-related risk refered by NSCET1 (under 6% in symptomatic cases, under 3% in asymptomatic cases). CEA was performed in patients conformed to the inclusion criteria without exclusion criteria advocated by NASCET1, and CS in patients with the exclusion criteria. The main reasons for CS were the presence of ischemic heart disease in 16 cases and contralateral occlusive lesion in 6 cases. Best medical treatment was taken together after CS or CEA.

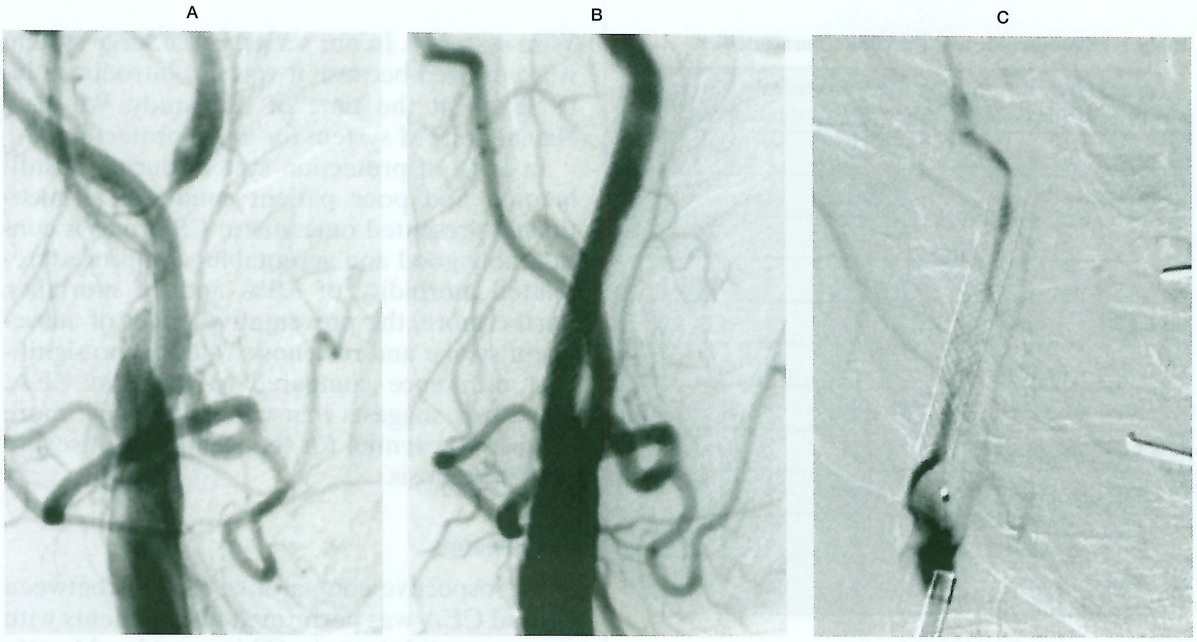

Figure 2 Serial angiogram of a restenosis case before and after stenting. A) Before stenting. B) After stenting. C) 12 months after stenting.

We compared the short-term outcome, such as periprocedural complication rate, cerebral blood flow (CBF), subsequent ischemic events and restenosis between CS and CEA group to investigate the justice of our present indication for CS. The mean follow-up period was 19 months. Stenosis rate in this paper was measured according to the method from NASCET[1].

Results

All CS and CEA procedures were done successfully and good initial gain with residual stenosis less than 30% was achieved.

1) No major (Modified Rankin scale = or > 3) procedure-related complication was seen in both group. Minor procedure-related complication caused by distal embolism was seen in one patient of CS group (figure 1). Then, procedure-related morbidity was 3% and 0% in CS and CEA, respectively. There was no procedure-related mortality.

2) Two patients suffered congestive heart failure or acute myocardial infarction after CS, and one patient underwent congestive heart failure after CEA. These evens, which were not related directly to the procedure, occurred in the first week after procedure, so were defined as non-procedure-related complications.

3) CBF was measured by three dimensional stereotactic surface projection (3DSSP) method based on SPECT. Eighteen cases in CS group and 6 cases in CEA group could be evaluated by 3D-SSP both before and after the procedure. Second exam was performed within one month after procedure. CBF was markedly improved in four (22%) and one (17%) patients who underwent CS and CEA, respectively. In contrast, hypoperfusion territory was slightly expanded in seven patients with CS and four patients with CEA.

4) Restenosis defined as 50% stenosis or more was found in one patient in each group during the follow-up period (figure 2). The restenosis rate between two groups calculated by the person-year method had no difference, 2.3%. They were both asymptomatic.

5) Subsequent asymptomatic stroke during the follow-up period was seen in one patient (3%) in CS group. No further stroke occurred in CEA group.

6) One patient in each group was dead during follow-up period, both due to heart attack. One patient who were taking Warfarin for the prevention of recurrent cardioembolism were dead due to severe cerebral contusion after head injury. No lesion-related death was found.

Table 1 **Demographic and Baseline Characteristics**

From March 1998 to May 2002, 55 patients with carotid stenosis underwent either carotid stenting or CEA.		
• Stenting	30 cases	
• CEA	25 cases	
	Stenting	**CEA**
• Age	67.5 ± 7.8	64.7±8.9
• Male / Female	27 / 3	22 / 3
• Stenosis rate	84 ± 13	80 ± 15
• Symptomatic	83%	68%
• Hypertension	76%	66%
• DM	40%	38%
• Heart disease	53%	24%

Discussion

The predominant treatment requires high efficacy with a good risk. In case of carotid stenosis, the efficacy is to prevent the subsequent stroke and the risk implies periprocedural complications. Restenosis reduce the efficacy by increasing the further stroke rate again. Though the definite conclusion is carried only by randomized controlled trials removing any statistical bias, they are on going now. We need to clarify the present valid indication of CS for patients refractory to CEA.

As indicated in table 1, patients who underwent CS were in poor risk. In comparison with CEA patients, they were higher-aged with higher stenosis rate, and with more risk factors. Majority of this group had past history of ischemic heart disease. They are supposed to be in the poor risk not only of further stroke, but also the risk of possible procedure-related complications. In other words, they may be under the necessity to receive adequate treatments, of which the risk may be high. For this reason, we investigate and compared the short-term outcome between CS and CEA.

Distal embolism during CS is one of the most important problem to be solved[2,3,4]. Distal balloon protection was introduced by Theron et Al[5]. They presented for the first time that such a protection system could reduce the risk of distal embolism. In recent, Henry et Al reported the excellent outcome, 30-day stroke & death rate of 2.7%, using PercuSurge GuardWire system[6,7]. In our series, PercuSurge system was not used because it was not introduced into Japan at the time of this study. We used NavialloonTM system for distal protection.

In spite of protection system during postdilatation and poor patient condition as mentioned, presented outcome in CS group is considerably good and acceptable with procedure-related morbidity of 3.3% and no mortality. Furthermore, the preventative effect of subsequent stroke and restenosis rate had no significant difference compared to those in CEA. Our study suggests that CS may involve more extensive potential for the treatment of severe carotid stenosis.

Conclusions

Retrospective comparative analysis between CS and CEA was performed in 55 patients with severe carotid stenosis. CS is considerably safe and feasible for the treatment in patients refractory to CEA. The management of heart disease after CS is essential to achieve better outcome. The conclusion must be confirmed by long-term randomized studies.

References

1 North American Symptomatic Carotid Endarterectomy Trial (NASCET) Collaborators: Beneficial effect of carotid endarterectomy in symptomatic patients with high-grade carotid stenosis. N Engl J Med 325 (7): 445-453, 1991.
2 Wholey MH, Wholey M et Al: Global experience in cervical carotid artery stent placement. Catheter & Cardiovasc Interv 50 (2): 160-167, 2000.
3 Dietz A, Berkefeld J at Al: Endovascular treatment of symptomatic carotid stenosis using stent placement: long-term follow-up of patients with a balanced surgical risk/benefit ratio. Stroke 32 (8): 1855-1859, 2001.
4 Martin JB, Murphy KJ et Al: In vitro evaluation of the effectiveness of distal protection in the prevention of cerebral thromboembolism during carotid stent placement. Acad Radiol 8 (7): 623-628, 2001.
5 Theron JG, Payelle GG et Al: Carotid artery stenosis: treatment with protected balloon angioplasty and stent placement. Radiology 201 (3): 627-636, 1996.
6 Henry M, Amor M et Al: Carotid stenting with cerebral protection: first clinical experience using the PercuSurge GuardWire system. J Endovasc Surg 6 (4): 321-31, 1999.
7 Henry M, Henry I et Al: Benefits of cerebral protection during carotid stenting with the PercuSurge GuardWire system: midterm results. J Endovasc Therapy 9 (1): 1-13, 2002.

Eiichi Kobayashi, M.D.
Department of Neurosurgery, Chiba University School of Medicine
1-8-1, Inohana, Chuo-ku, Chiba, 260-8670, Japan