Received: 15.9.2010 **Accepted: 13.1.2011**

Case Report

Malignant endometrial polyps: Report of two cases and review of literature with emphasize on recent advances

Ali Dastranj Tabrizi[a], Amir Vahedi[a], Hiedar Ali Esmaily[a]*

Abstract

Endometrial polyps are common pathologic findings in gynecologic pathology practice. Although malignant changes in these lesions are uncommon, numerous studies confirmed this association especially with endometrial serous and clear cell carcinoma. Two cases of malignant endometrial polyps in association with presumed precursor lesion in one of them are presented.

KEYWORDS: Polyps, Adenocarcinoma, Papillary, Endometrium.

JRMS 2010; 16(4): 574-579

Endometrial polyps are common pathologic findings in gynecologic pathology and their prevalence range is between 16% to 34% depending on characteristics of the population studied and detecting methods.[1] Polyps are biphasic benign endometrial lesions that classically have been defined as 'benign nodular protrusions above the endometrial surface, consisting of irregularly distributed endometrial glands and stroma'.[2] Specific rearrangement of 12p15 and 6p21 resulting in HMGI-C and HMGI(Y) dysregulation have been reported in stromal cells of endometrial polyps.[3-7] Overall the prevalence of malignant and premalignant lesions found in the endometrial polyps ranges from 0.8% to 4.8%.[8-11] There are numerous studies, which confirm association of uterine serous papillary carcinoma with endometrial polyps especially the larger and symptomatic ones.[12,13] In the report of Ferrazzi et al,[13] the histotype of the single case of cancer on polyp and the 3 cases of polypoid cancer in asymptomatic women were endometrioid carcinoma. In contrast, 9 out of 29 cases of cancer on polyps and polypoid cancers in symptomatic patients showed clear cell histology. The frequency of malignant endometrial polyps increased with age and reached statistical significance in the age group > 65.[14]

This is a report of histologic and immunhistochemical features of two cases of endometrial polyps in postmenopausal women revealed serous and clear cell carcinoma with review of literature, emphasizing on precursor lesions and recent advances on the molecular pathways.

Case Report

Case 1

A 65-year-old lady referred to our center for managing an abdominal pain she had for a 6 months period and right side adnexal mass. Imaging studies revealed a solid and cystic mass in right adnexa m. 108×65×64 mm indistinguishable from uterine border. Total hysterectomy with bilatereal salpigo-oopherectoy in association with complete staging procedure was done. Rt. and Lf. ovarian masses, m. 10 × 6 and 6 × 5 cm, respectively, with frozen pelvis was found in laparatomy. Gross examination of the received specimens revealed multiple discrete tumoral tissue m. up to 3 cm in diameter. Opening of the uterus showed an endometrial polyp m. 5 mm in diameter with soft consistency.

[a] Women's Reproductive Health Center, Tabriz University of Medical Sciences, Tabriz, Iran.
*Corresponding Author
E-mail: alidastranj@yahoo.co.in

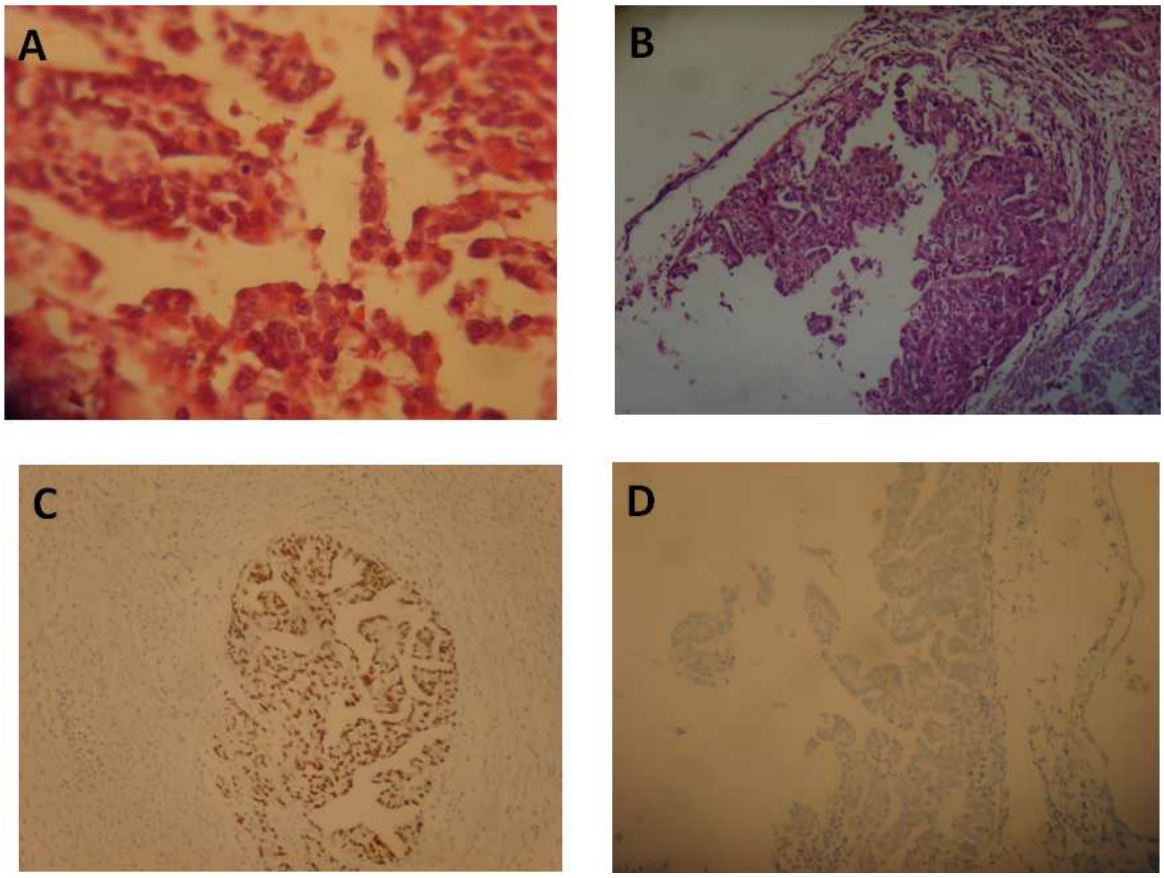

Figure 1. High grade ovarian serous carcinoma (A), the endometrial polyp with small foci of serous carcinoma (B), myometrial invasion by the serous carcinoma showing p35 positive staining (C) and small focus of serous papillary carcinoma in the endometrial polyp with negative p53 staining (D).

Cervix was unremarkable and gross appearance of the omentum was metastatic. Microscopic examination of the specimens revealed bilateral high grade ovarian serous carcinoma (Figure 1A), endometrial polyp with small foci of serous carcinoma (Figure 1B), massive full thickness myometrial invasion by the serous tumor (Figure 1C), lymphovascular space involvement, omentum metastasis, metastatic lymph nodes and positive ascetic fluid for malignant cells. Immunohistochemistry staining for P53, Ki-67, estrogen receptor and progesterone receptor was done. The invasive foci in the myometrium were positive for P53 (Figure 1C), estrogen receptor and progesterone receptor. Ki67 staining showed 30% positivity in these foci. In contrast the foci of serous carcinoma in the endometrial polyp were negative for P53 (Figure 1D). Unfortunately we missed the carcinomatous foci of the endometrial polyp in Ki-67, estrogen receptor and progesterone receptor staining due to repeated sections for IHC staining.

***Case* 2**

A 53-year-old lady with chief complaint of vaginal bleeding for 6 months period referred for further evaluation. Ultrasound study revealed mild increased endometrial thickness (10 mm) with no remarkable change in the cervix, myometrium or adnexa. Endometrial biopsy was done and histologic examination revealed endometrial clear cell carcinoma with serous carcinoma components in association with fragments of endometrial polyp m. up to 5 mm in diameter (Figure 2A, 2B). Total abdominal hysterectomy with bilateral salpingooopherectomy in association with staging procedure was

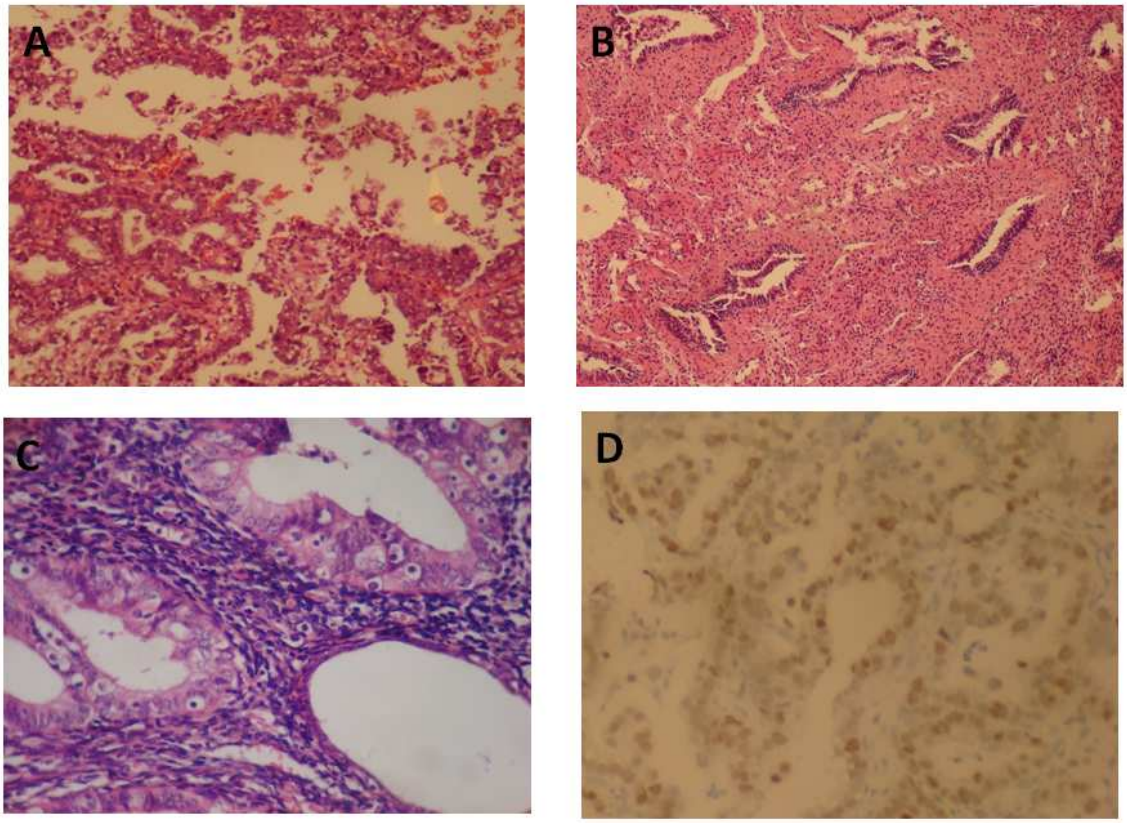

Figure 2. Foci of endometrial clear cell carcinoma in the endometrial biopsy (A), a fragment of endometrial polyp in the endometrial biopsy (B), clear cell endometrial glandular dysplasia, EmGD (C) and positive p53 reaction in the clear cell carcinoma (D).

done. Gross examination of the specimens revealed unremarkable endometrial cavity and the myometrium, cervix and ovaries showed no pathologic change. Microscopic examination of the endometrium showed endometrial glands with dysplstic nuclei and clear cytoplasm (clear cell glandular dysplasia) with no invasive component (Figure 2C). Figure 2D shows p53 positivity in clear cell carcinoma obtained by endometrial biopsy. The received omentum, lymph nodes, peritoneal biopsies, and peritoneal washing cytology were negative for malignancy.

Discussion

In a series including 455 patients with endometrial polyp diagnosed by hysteroscopy, endometrial adenocarcinoma was found in 2.7%, although they did not indicate the type of reported malignancy.[15] In another study, all of the 13 malignancies reported in the endometrial polyps were well to moderately differentiated endometriod adenocarcinoma.[16]

Although uterine serous carcnoma is an uncommon cancer, it accounts for a disproportionate number of endometrial cancer deaths. In a series studied by Hamilton et al, these tumors accounted for 10% of endometrial tumors, but comprised 39% of endometrial cancer deaths.[17] Its tendency for early spread results in upstaging of 50% to 70% of clinically stage I cancers at the time of operation.[18] Presentation of 19.7% and 31.1% of patients with uterine serous carcinoma in stage II-III, respectively in one study confirms the common perception that this histotype of endometrial carcinoma carry a worse prognosis due to advanced disease at the time of diagnosis.[19]

The first case reported here shows the coexistence of high grade bilateral ovarian serous carcinoma and small foci of invasive serous carcinoma in the endometrial polyp. Although metastatic spread to this endometrial polyp should be considered in differential diagnosis, the high

tendency of primary endometrial serous carcinoma to develop in endometrial polyps must be emphasized. In a study, 13 cases of primary endometrial serous carcinoma had developed in endometrial polyps and all of them except for one were limited to the endometrial polyps.[20] On the other hand, although apparently these lesions were limited in the polyps in the present study, extrauterine spread was found in four cases, three of which were microscopic. Even in the so-called intraepithelial form of serous carcinoma (endometrial intraepithelial carcinoma), the predilection and tendency for extra uterine spread has been noted.[21-24] In addition, minimal uterine serous carcinoma (including serous carcinoma with invasion limited to the endometrium and endometrial intraepithelial carcinoma) were found to involve endometrial polyps in 88% of the cases (35/40) and were confined to the polyp in 53% (21/40).[24] In an interesting case report that included 5 cases, the authors reported endometrial serous carcinoma confined to an endometrial polyp with ovarian vascular involvement.[25]

For this reason Clement and Young recommended that EIC should be considered as small foci of serous carcinoma and stressed that pathologists should indicate its malignant potential in the pathology report when it is unaccompanied by typical serous carcinoma and note its size and location.[26] It means that in all forms of uterine serous carcinoma including EIC, surgical staging should be performed regardless its location or limitation on endometrial polyp. Recently, it has been proposed that the term EIC should be discarded as a precursor lesion for endometrial serous carcinoma due to its well recognized potential for extra uterine spread. Furthermore, Endometrial Glandular Dysplasia (EmGD) has been proposed recently as a true precursor lesion for endometrial serous carcinoma.[27] In the our recent study EmGD was found in five out of 25 cases of endometrial serous carcinoma developed in endometrial polyp (unpublished data). Coexisting involvement of the endometrium or ovary is found in 10% and 5% of women with ovarian and endometrial cancer, respectively.[28] Although the presence of multifocal or multicentric serous neoplaia is possible, identical p53 mutation in multiple sites indicates metastatic origin.[29] In this case, positivity of tumor nests in the myometrium and negativity of the small foci of serous papillary carcinoma in the polyp for P53 favours independent primary tumors in both endometrium and ovaries (Figure 1C, 1D).

In the second case like the first one, the endometrial clear cell carcinoma had been developed in an endometrial polyp in association with clear cell EmGD. The criteria most commonly used for identification of serous EmGD are glands or groups of small glands in superficial endometrium or a flat layer of superficial epithelium. Since the level of atypia in these foci is not at the level of serous carcinoma, these lesions do not fit the designation of EIC. The typical changes in EmGD foci are nucleomegaly (2-4 times of resting endometrium nuclei), variably conspicuous nuclei, nuclear loss of polarity and changeable nuclear hyperchromasia.[30]

Clear cell EmGD is characterized by small glands or segments of slowly progressing nuclear atypia. Based on grade of nuclear atypia, the grades of these lesions vary from 1 to 3. Histologically, the lesions lined by cells with atypical nuclei and clear or eosinophilic cytoplasm were considered grade 3 while the lesions with grade 1 or 2 nuclear atypia were designated clear cell EmGD.[31]

Based on the molecular and immunohistochemical studies in this background,[32] it is reasonable to consider that EmGD may be the true precancerous lesion of endometrial serous carcinoma on the assumption that serous carcinogenesis in the endometrium is also identical to other carcinogenetic processes in terms of stepwiss progressing rather than "de novo" arising from resting endometrium.

Conclusions

In summary, this paper reported two cases of type II endometrial carcinoma in dualistic model of endometrial carcinogenesis in association with presumed precursor lesion in one

case developed on endometrial polyp. It should be emphasized that endometrial polyps especially the symptomatic and larger one and the polyps developed in postmenopausal patients have tendency to show malignant change. Therefore, careful histologic examination of these lesions to find premalignant and malignant lesions should be emphasized.

Conflict of Interest

Authors have no conflict of interests.

Authors' Contributions

ADT selected the cases and prepared the first draft. AV reviewed the drafts and helped as a consultant. HAE was the consultant pathologist and also helped editing the manuscript. All authors have read and approved the content of the manuscript.

References

1. Rahimi S, Marani C, Renzi C, Natale ME, Giovannini P, Zeloni R. Endometrial polyps and the risk of atypical hyperplasia on biopsies of unremarkable endometrium: a study on 694 patients with benign endometrial polyps. Int J Gynecol Pathol 2009; 28(6): 522-8.
2. Scott RB. The elusive endometrial polyp. Obstet Gynecol 1953; 1(2): 212-8.
3. Fletcher JA, Pinkus JL, Lage JM, Morton CC, Pinkus GS. Clonal 6p21 rearrangement is restricted to the mesenchymal component of an endometrial polyp. Genes Chromosomes Cancer 1992; 5(3): 260-3.
4. Dal Cin P, Vanni R, Marras S, Moerman P, Kools P, Andria M, et al. Four cytogenetic subgroups can be identified in endometrial polyps. Cancer Res 1995; 55(7): 1565-8.
5. Bol S, Wanschura S, Thode B, Deichert U, Van de Ven WJ, Bartnitzke S, et al. An endometrial polyp with a rearrangement of HMGI-C underlying a complex cytogenetic rearrangement involving chromosomes 2 and 12. Cancer Genet Cytogenet 1996; 90(1): 88-90.
6. Dal Cin P, Wanschura S, Kazmierczak B, Tallini G, Dei Tos A, Bullerdiek J, et al. Amplification and expression of the HMGIC gene in a benign endometrial polyp. Genes Chromosomes Cancer 1998; 22(2): 95-9.
7. Tallini G, Vanni R, Manfioletti G, Kazmierczak B, Faa G, Pauwels P, et al. HMGI-C and HMGI(Y) immunoreactivity correlates with cytogenetic abnormalities in lipomas, pulmonary chondroid hamartomas, endometrial polyps, and uterine leiomyomas and is compatible with rearrangement of the HMGI-C and HMGI(Y) genes. Lab Invest 2000; 80(3): 359-69.
8. Orvieto R, Bar-Hava I, Dicker D, Bar J, Ben-Rafael Z, Neri A. Endometrial polyps during menopause: characterization and significance. Acta Obstet Gynecol Scand 1999; 78(10): 883-6.
9. Anastasiadis PG, Koutlaki NG, Skaphida PG, Galazios GC, Tsikouras PN, Liberis VA. Endometrial polyps: prevalence, detection, and malignant potential in women with abnormal uterine bleeding. Eur J Gynaecol Oncol 2000; 21(2): 180-3.
10. Goldstein SR, Monteagudo A, Popiolek D, Mayberry P, Timor-Tritsch I. Evaluation of endometrial polyps. Am J Obstet Gynecol 2002; 186(4): 669-74.
11. Savelli L, De Iaco P, Santini D, Rosati F, Ghi T, Pignotti E, et al. Histopathologic features and risk factors for benignity, hyperplasia, and cancer in endometrial polyps. Am J Obstet Gynecol 2003; 188(4): 927-31.
12. Antunes A Jr, Costa-Paiva L, Arthuso M, Costa JV, Pinto-Neto AM. Endometrial polyps in pre- and postmenopausal women: factors associated with malignancy. Maturitas 2007; 57(4): 415-21.
13. Ferrazzi E, Zupi E, Leone FP, Savelli L, Omodei U, Moscarini M, et al. How often are endometrial polyps malignant in asymptomatic postmenopausal women? A multicenter study. Am J Obstet Gynecol 2009; 200(3): 235.e1-6.
14. Hileeto D, Fadare O, Martel M, Zheng W. Age dependent association of endometrial polyps with increased risk of cancer involvement. World J Surg Oncol 2005; 3: 8.
15. Ben-Arie A, Goldchmit C, Laviv Y, Levy R, Caspi B, Huszar M, et al. The malignant potential of endometrial polyps. Eur J Obstet Gynecol Reprod Biol 2004; 115(2): 206-10.
16. Carcangiu ML, Tan LK, Chambers JT. Stage IA uterine serous carcinoma: a study of 13 cases. Am J Surg Pathol 1997; 21(12): 1507-14.
17. Hamilton CA, Cheung MK, Osann K, Chen L, Teng NN, Longacre TA, et al. Uterine papillary serous and clear cell carcinomas predict for poorer survival compared to grade 3 endometrioid corpus cancers. Br J Cancer 2006; 94(5): 642-6.
18. Faratian D, Stillie A, Busby-Earle RM, Cowie VJ, Monaghan H. A review of the pathology and management of uterine papillary serous carcinoma and correlation with outcome. Int J Gynecol Cancer 2006; 16(3): 972-8.

19. Benito V, Lubrano A, Arencibia O, Alvarez EE, León L, Medina N, et al. Pure papillary serous tumors of the endometrium: a clinicopathological analysis of 61 cases from a single institution. Int J Gynecol Cancer 2009; 19(8): 1364-9.
20. Trahan S, Têtu B, Raymond PE. Serous papillary carcinoma of the endometrium arising from endometrial polyps: a clinical, histological, and immunohistochemical study of 13 cases. Hum Pathol 2005; 36(12): 1316-21.
21. Rabban JT, Zaloudek CJ. Minimal uterine serous carcinoma: current concepts in diagnosis and prognosis. Pathology 2007; 39(1): 125-33.
22. Zheng W, Schwartz PE. Serous EIC as an early form of uterine papillary serous carcinoma: recent progress in understanding its pathogenesis and current opinions regarding pathologic and clinical management. Gynecol Oncol 2005; 96(3): 579-82.
23. Chan JK, Loizzi V, Youssef M, Osann K, Rutgers J, Vasilev SA, et al. Significance of comprehensive surgical staging in noninvasive papillary serous carcinoma of the endometrium. Gynecol Oncol 2003; 90(1): 181-5.
24. Hui P, Kelly M, O'Malley DM, Tavassoli F, Schwartz PE. Minimal uterine serous carcinoma: a clinicopathological study of 40 cases. Mod Pathol 2005; 18(1): 75-82.
25. McCluggage WG, Sumathi VP, McManus DT. Uterine serous carcinoma and endometrial intraepithelial carcinoma arising in endometrial polyps: report of 5 cases, including 2 associated with tamoxifen therapy. Hum Pathol 2003; 34(9): 939-43.
26. Clement PB, Young RH. Non-endometrioid carcinomas of the uterine corpus: a review of their pathology with emphasis on recent advances and problematic aspects. Adv Anat Pathol 2004; 11(3): 117-42.
27. Fadare O, Zheng W. Endometrial glandular dysplasia (EmGD): morphologically and biologically distinctive putative precursor lesions of type II endometrial cancers. Diagn Pathol 2008; 3(2): 6.
28. Adenocarcinoma, carcinosarcoma and other epithelial tumors of the endometrium. In: Crum CP, Lee KR, editors. Diagnostic gynecologic and obstetric pathology. Philadelphia: Elsevier; 2006. p. 585.
29. Baergen RN, Warren CD, Isacson C, Ellenson LH. Early uterine serous carcinoma: clonal origin of extrauterine disease. Int J Gynecol Pathol 2001; 20(3): 214-9.
30. Zheng W, Liang SX, Yu H, Rutherford T, Chambers SK, Schwartz PE. Endometrial glandular dysplasia: a newly defined precursor lesion of uterine papillary serous carcinoma. Part I: morphologic features. Int J Surg Pathol 2004; 12(3): 207-23.
31. Liang SX, Chambers SK, Cheng L, Zhang S, Zhou Y, Zheng W. Endometrial glandular dysplasia: a putative precursor lesion of uterine papillary serous carcinoma. Part II: molecular features. Int J Surg Pathol 2004; 12(4): 319-31.
32. Zheng W, Liang SX, Yi X, Ulukus EC, Davis JR, Chambers SK. Occurrence of endometrial glandular dysplasia precedes uterine papillary serous carcinoma. Int J Gynecol Pathol 2007; 26(1): 38-52.