SCIENTIFIC PAPER

Lifting of the Colon for Laparoscopic-Assisted Colectomy for Colon and Rectal Cancer

Shoichi Fujii, MD, Hiroshi Shimada, MD, Hideyuki Ike, MD, Toshio Imada, MD, Shigeru Yamagishi, MD, Shuji Saito, MD

ABSTRACT

Background and Objectives: Laparoscopic-assisted colectomy for colon and rectal cancer causes less surgical trauma than does open colectomy. However, current methods are more costly and require highly skilled staff. In addition, the technique for lymphadenectomy has yet to be standardized. We developed a technique that uses a nylon suture to elevate the colon. This method reduces costs without compromising the completeness of the resection.

Methods: Three trocars are introduced and a 1–0 nylon suture is passed into the abdominal cavity and through the mesocolon. The colon is retracted anteriorly and is fixed by this suture to the abdominal wall. The main mesenteric vessels are under tension, and lymph node dissection is performed easily. This method requires only 2 surgeons, an operator, and a scopist, because the colon is fixed to the abdominal wall. In addition, the working space is more stable because the colon is fixed to the abdominal wall. The procedure is relatively independent of the skill of the first assistant.

Results: From April 2000 to August 2002, this method was performed in 52 patients. The mean number of dissected lymph nodes was 16.9±9.0 (range, 6 to 41). Nine patients had lymph node metastases (17.3%). One patient developed hepatic recurrence; all patients are alive. No complication occurred that was related to lifting the colon.

Conclusions: Using a suture to lift the colon is a useful method for performing laparoscopic-assisted colectomy with lymphadenectomy. This method reduces the number of surgical staff and the expense of the procedure.

Key Words: Laparoscopic-assisted colectomy, Lifting of colon, Trocar, Lymphadenectomy.

Yokohama City University Medical Center Gastroenterological Center, Yokohama, Japan (Drs Fujii, Ike, Imada, Yamagishi).; Yokohama City University Medical Center, Second Department of Surgery, Yokohama, Japan (Drs Shimada, Saito).

Address reprint requests to: Shoichi Fujii, MD, Second Department of Surgery, Yokohama City University School of Medicine, 3–9 Fukuura, Kanazawa-ku, Yokohama 236-0004, Japan. Telephone: 81 45 787 2650, Fax: 81 45 782 9161, E-mail: fujii@rb4.so-net.ne.jp

© 2004 by *JSLS, Journal of the Society of Laparoendoscopic Surgeons.* Published by the Society of Laparoendoscopic Surgeons, Inc.

INTRODUCTION

Laparoscopic assisted colectomies (LAC) for colon and rectal cancer have recently become more common in Japan. This procedure minimizes surgical stress and has been recognized as acceptable treatment for colorectal cancer based on long-term outcome studies and a low complication rate.[1,2] Long-term survival after LAC is similar to survival after conventional surgery,[3–6] but it is more expensive in terms of surgical instruments and surgical staff. We have developed a colon-lifting method using a suture that requires only 2 operators and 3 trocars. This technique can be performed without compromising curability.

SURGICAL TECHNIQUE

The patient is placed in the lithotomy position at 15-degrees Trendelenburg. A 12-mm trocar is inserted below the navel through a small incision and pneumoperitoneum is created. Two additional trocars are placed superior and inferior to the lesion and serve as the working ports **(Figures 1 and 2)**. The mesocolon is pierced near the line of transection with dissecting forceps. A 1–0 nylon suture is introduced into the lower abdominal cavity with a grasping needle (GraNee Needle, R-Med, Inc., Oregon, OH, USA) and passed through the mesocolon **(Figure 3)**. The point of penetration of the mesocolon must be at least 10 cm from the edge of the tumor to avoid tumor implantation **(Figure 2)**. The colon is retracted anteriorly using the suture, exerting slow and steady pressure to avoid injury to the vessels in the mesocolon. The suture is fixed to the abdominal wall by forceps. Then, traction is placed on the main nutrient artery **(Figure 4)**. Lymph node dissection is performed easily because countertraction can be applied at the point of incision. The stability of the working space is achieved by fixing the colon to the abdominal wall. The main nutrient vessels are divided at their origin to facilitate lymph node dissection **(Figure 5)**. The mesocolon is dissected by medial approach. One port site for the trocars is enlarged, and the lesion is removed through it. The reconstruction is intracorporal for left-sided lesions and extracorporal for right-sided

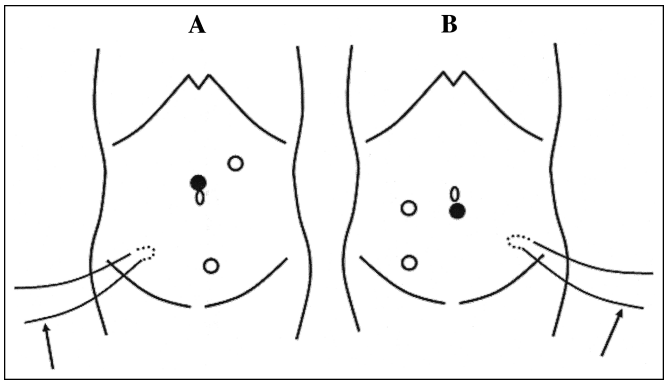

Figure 1. Trocar sites. Right-sided lesion (A). Left-sided lesion (B). The arrow is a nylon suture. The closed circle is the laparoscopic port. The open circles are manipulation ports.

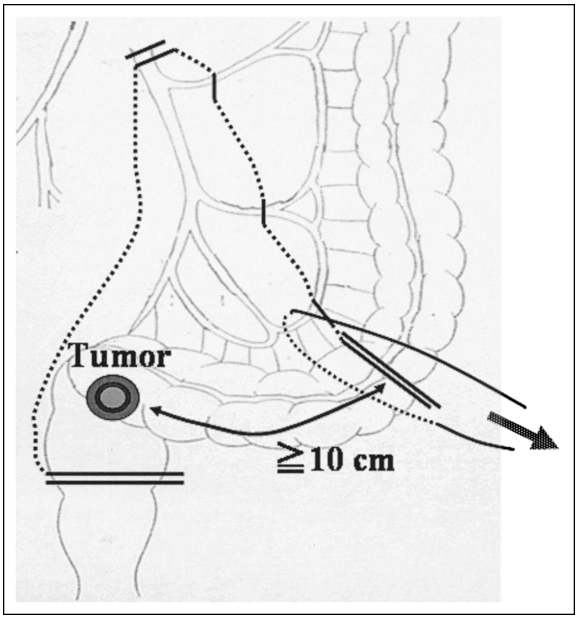

Figure 2. Schematic diagram showing technique for resecting a rectal cancer. The inferior mesenteric artery is divided. The autonomic nerve plexus is conserved. The sigmoid colon is lifted using the suture at least 10 cm from the edge of the tumor.

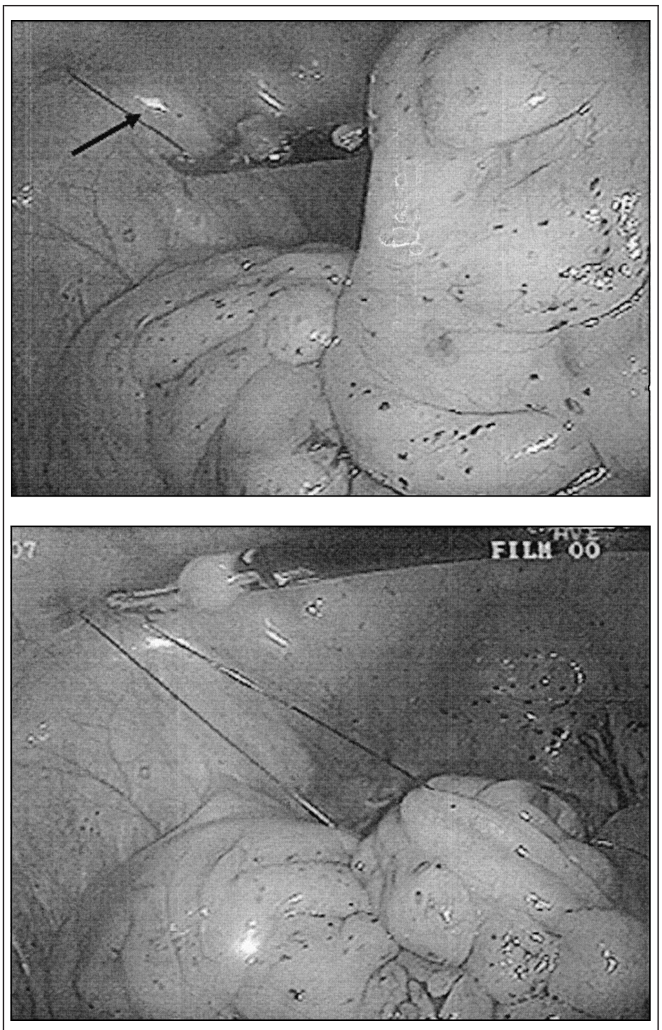

Figure 3. The mesocolon is pierced near the line of transection with dissecting forceps. A 1–0 nylon suture is inserted into the abdominal cavity and passed through the mesocolon. Arrow points to nylon suture.

lesions. This method requires only a scopist in addition to the operator. In some cases, an extra traction suture is needed for lesions of the right colon or when the left or sigmoid colon is redundant.

INDICATIONS

LAC is indicated for colon and upper rectal cancer ≤5 cm in diameter. The documented existence of lymph node metastases preoperatively is an exclusion criterion.

RESULTS

From April 2000 to August 2002, 52 laparoscopic colectomies were performed with this method. Thirty-one patients had colon cancer in the following locations: cecum, 2; ascending colon, 5; transverse colon, 3; descending colon, 1; and sigmoid colon, 21. Twenty-one patients had rectal cancer, 17 in the upper rectum and 4 in the lower. One patient had rectal and sigmoid cancer. The mean operative time was 278±50 minutes (range, 115 to 380 min). The mean blood loss was 137±158 mL (range, 10 to 800 mL). No operative complications were attributable to this technique. The disease stage of primary cancer was as

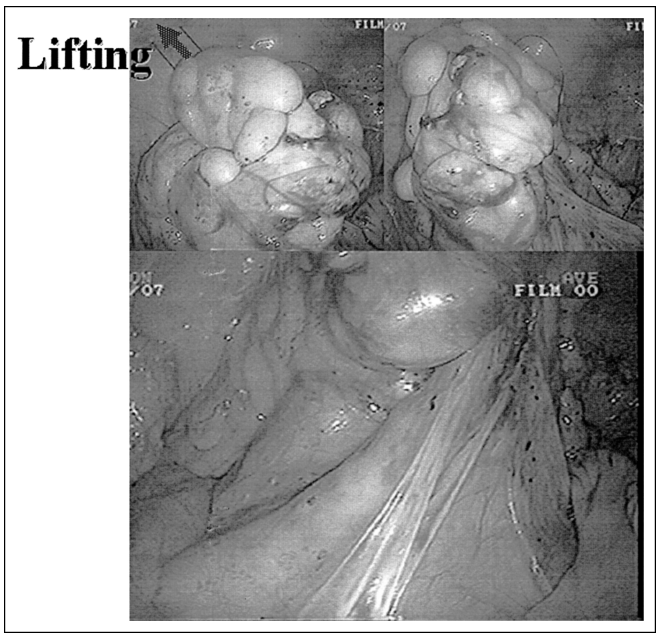

Figure 4. The colon is retracted anteriorly by pulling on the 1–0 nylon suture, placing traction on the main nutrient artery in the mesocolon; lymph node dissection is easily performed near the inferior mesenteric artery (arrow).

follows: Tis, 13; T1, 20; T2, 9; and T3, 10. The mean number of dissected lymph nodes was 16.9±9.0 (range, 5 to 41). Nine patients had lymph node metastases (17.3%). Thirty-three lesions were well-differentiated adenocarcinoma, 17 were moderately differentiated adenocarcinoma, and 2 lesions were carcinoid. All patients are alive, and one patient has experienced a hepatic recurrence during a mean follow-up of 16.0±8.4 months (range, 4 to 33).

DISCUSSION

Since LAC for colon cancer was first reported in 1991,[7] its use has increased worldwide. One long-term follow-up study[1] of LAC for stage 3 colon cancer reported results comparable to those of open colectomy (OC). The most recent study was a randomized trial comparing LAC and OC. This study found that LAC was superior to OC in terms of morbidity, length of hospital stay, incidence of recurrence, and cancer-related survival.[8] In economic studies of diverticular disease[9,10] and cancer,[11] the total hospital costs were similar to or less than those for LAC than for OC, although the operating room charges were greater for LAC due to the need for many disposable items. Therefore, reducing the amount of instrumentation will increase LAC's attractiveness as a surgical option. In most reports, LAC required 4 or 5 trocars.[12–15] In our technique, only 3 trocar sites were needed, and one surgeon was able to perform the laparoscopic procedure assisted only by a scopist. We selected nylon suture for the lifting tool because there are advantages in terms of medical costs and cosmesis; nylon is a very inexpensive tool, and wound to the abdomen is very slight. Our method saves 1 or 2 trocar implements, so the difference is 13,640 yen (about 114 US dollars) per operation. In Japan, the surgeon's cost is inexpensive; it is about 3,500 yen (about 29 US dollars) per hour. The length of time for a laparoscopic procedure is about 2.5 hours, so this method saves about 8,750 yen (about 73 US dollars) per operation.

A similar method has been reported previously,[16] but our method is different in that the colon is elevated using a ligature. This maneuver places the vessels in the mesocolon under tension and facilitates lymphadenectomy. This method allows the beginning LAC surgeon to easily understand the operative anatomy. Because of suspension and fixation of the colon, the surgical field becomes stable, and the colon and mesocolon are on the same plane. The nutritional vessel is stretched in the mesocolon. The dissection line was easily placed under tension by using the grasping forceps because the colon was fixed to the abdominal wall.

Care must be taken to avoid injuring vessels when the ligature is passed. The suture should be passed central to the mesenteric arcade. The suture should be drawn through slowly and gently to avoid vascular injury.

Another concern is the risk of tumor implantation of lymph node metastasis from the mesocolon to the abdominal wall. Therefore, the passed suture should be at least 10 cm from the tumor. We have not encountered a lymph node metastasis that distance from the primary tumor. In fact, this method seems to be more of a nontouch technique than other procedures because the colon is manipulated only at points far from the cancer.

Concerning the length of operation, the mean time was 278±50 minutes. It was slightly longer than open surgery. But the learning curve has become shorter lately; it was about 180 minutes for colon cancer and 240 minutes for rectal cancer in the last 10 cases. We performed 80 traditional laparoscopic procedures that required 4 or 5 ports and 3 surgical personnel between 1993 and 2001. The mean time of all cases was 336±75 minutes. From 2000, it has been 290±41 minutes in the last 25 cases. So, the time of our lifting method is the same as that of the traditional laparoscopic method.

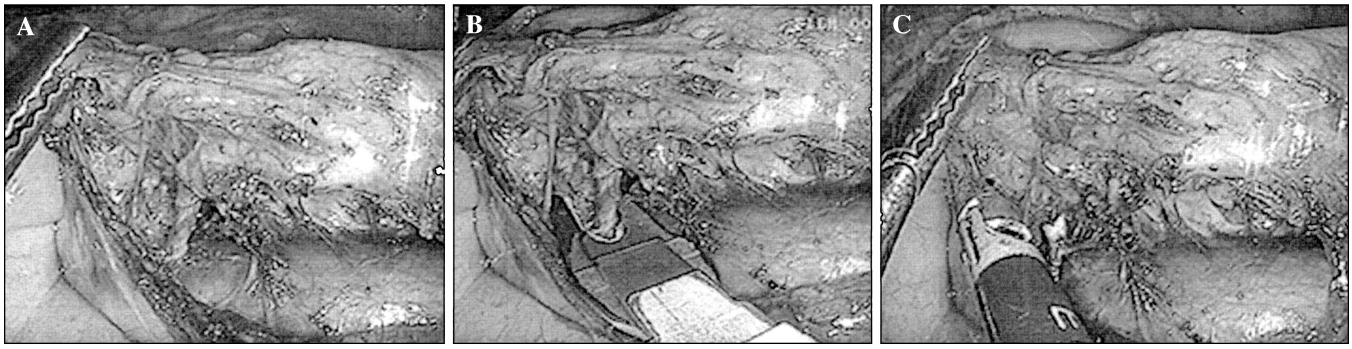

Figure 5. Lymphadenectomy. Exposure (A). Clipping (B). Division of the inferior mesenteric artery (C).

A unique advantage of this method is that the operator is much less dependent on the assistant's laparoscopic skills, giving the surgeon greater control over the operation. It is likely that the introduction of robotics to handle the laparoscope will make it possible for a single operator to perform this procedure in the future.

CONCLUSION

Lifting the colon using a ligature is a useful technique for performing LAC with lymph node dissection. This method reduces the surgical staff and the amount of instrumentation.

References:

1. Franklin ME, Kazantsec GB, Abrego D, Diaz-E JA, Balli J, Glass JL. Laparoscopic surgery for stage III colon cancer: long-term follow-up. *Surg Endosc*. 2000;14(7):312–316.

2. Lumley J, Stitz R, Stevenson A, Fielding G, Luck A. Laparoscopic colorectal surgery for cancer: intermediate to long-term outcomes. *Dis Colon Rectum*. 2002;45(7):867–872.

3. Hong D, Tabet J, Anvari M. Laparoscopic vs. open resection for colorectal adenocarcinoma. *Dis Colon Rectum*. 2001;44(1): 10–19.

4. Champault GG, Barrat C, Raselli R, Elizalde A, Catheline JM. Laparoscopic versus open surgery for colorectal carcinoma: a prospective clinical trial involving 157 cases with a mean follow-up of 5 years. *Surg Laparosc Endosc Percutan Tech*. 2002; 12(2):88–95.

5. Lezoche E, Feliciotti F, Paganini AM, et al. Laparoscopic vs open hemicolectomy for colon cancer. *Surg Endosc*. 2002;16(4): 596–602.

6. Feliciotti F, Paganini AM, Guerrierri M, Sanctis A, Campagnacci R, Lezoche E. Results of laparoscopic vs. open resection for colon cancer in patients with a minimum follow-up of 3 years. *Surg Endosc*. 2002;16(8):1158–1161.

7. Jacobs M, Verdeja JC, Goldstein HS. Minimally invasive colon cancer (laparoscopic colectomy). *Surg Laparosc Endosc*. 1991;1(3):144–150.

8. Lacy AM, Garcia-Valdecasas JC, Delgado S, et al. Laparoscopic assisted colectomy versus open colectomy for treatment of non-metastatic colon cancer: a randomized trial. *Lancet*. 2002; 359(29):2224–2229.

9. Liberman MA, Phillips EH, Carroll BJ, Fallas M, Rosenthal R. Laparoscopic colectomy vs. traditional colectomy for diverticulitis. Outcome and costs. *Surg Endosc*. 1996;10(1):15–18.

10. Senagore AJ, Duepree HJ, Delaney CP, Dissanaike S, Brady KM, Fazio VW. Cost structure of laparoscopic and open sigmoid colectomy for diverticular disease: similarities and differences. *Dis Colon Rectum*. 2002;45(4):485–490.

11. Bouvet M, Mansfield PF, Skibber JM, et al. Clinical, pathologic, and economic parameters of laparoscopic colon resection for cancer. *Am J Surg*. 1998;176(6):554–558.

12. Dennis L, Fowler MD, Sharon A, White RN. Laparoscopic-assisted sigmoid resection. *Surg Laparosc Endosc*. 1991;1(3): 183–188.

13. Pietrafitta JJ, Schultz LS, Graber JN, Hickok DF. An experimental technique of laparoscopic bowel resection and reanastomosis. *Surg Laparosc Endosc*. 1992;2(3):205–211.

14. Wexter SD, Johansen OB. Laparoscopic bowel resection: Advantages and limitations. *Ann Med*. 1992;24:105–110.

15. Zucker KA, Pitcher DE, Martin DT, Ford RS. Laparoscopic-assisted colon resection. *Surg Endosc*. 1994;8(1):12–18.

16. Allam M, Piskun G, Kothuru R, Fogler R. A three-trocar midline approach to laparoscopic-assisted colectomy. *J Laparoendosc Adv Surg Tech*. 1998;8(3):151–155.