OTOLOGY

Fully implantable Otologics MET Carina™ device for the treatment of sensorineural hearing loss. Preliminary surgical and clinical results

La protesi totalmente impiantabile Otologics MET Carina™ per il trattamento dell'ipoacusia neurosensoriale: la nostra esperienza chirurgica e clinica

L. BRUSCHINI, F. FORLI, A. SANTORO[1], P. BRUSCHINI[2], S. BERRETTINI

Otology and Cochlear Implants Division, University of Pisa; [1] ENT Unit 1, University of Pisa; [2] ENT Unit 2, University Hospital of Pisa, Italy

SUMMARY

Middle ear implants overcome some of the common problems of conventional hearing aid technology, such as feedback, signal distortion, ear canal occlusion and associated issues. The Otologics MET Carina™, Boulder, CO, USA, is a fully implantable hearing prosthesis designed to address the amplification needs of adults (> 18 years of age), with moderate to severe sensorineural hearing loss and normal middle ears, providing a mechanical direct stimulation of middle ear ossicles. Recently, it has been successfully used also in patients with conductive hearing loss. In the present report, personal surgical and clinical experience with the fully implantable Carina™ is described in 5 adults with moderate to severe sensorineural hearing loss, operated upon between November 2007 and May 2008 in the ENT Unit, University of Pisa. Mean follow-up was 10.2 months of device use (range 7-13). Surgery was performed under general anaesthesia, in ~3 hours, with no surgical complications in any of the patients. In these 5 cases, no significant post-operative variation was observed in hearing thresholds, either for air or bone conduction, indicating absence of surgical damage to the cochlea. All patients showed improvements in hearing thresholds, in free field and in speech perception abilities, with the device functioning, moreover, they reported subjective benefits. With regard to post-operative adverse effects, no cases of extrusion of the device, device failure, loss of external communication or increased charging times were observed. Problems of feedback noise occurred, which were resolved with minor fitting adjustments in 4 cases, while a second operation was required to change the microphone position in the other patient. The present results, in agreement with those reported in the literature, confirm that the Otologics MET Carina™ is viable treatment for moderate to severe sensorineural hearing loss and, in selected cases, may represent an alternative to conventional hearing aids.

KEY WORDS: Sensorineural hearing loss • Middle ear implants

RIASSUNTO

Le protesi impiantabili di orecchio medio permettono di superare alcune problematiche comunemente presenti con le protesi acustiche tradizionali, quali il feed-back, i fenomeni di distorsione e l'effetto occlusione. La protesi Otologics MET Carina™, Boulder, CO, USA è una protesi totalmente impiantabile, indicata per il trattamento di pazienti adulti, con età > 18 anni, affetti da ipoacusia neurosensoriale bilaterale di entità da moderata a grave, in assenza di patologia a carico dell'orecchio medio, ma recentemente utilizzata con successo anche in pazienti affetti da ipoacusia trasmissiva. In questo lavoro presentiamo la nostra esperienza preliminare chirurgica e clinica con la protesi Carina™ in 5 pazienti adulti, affetti da ipoacusia neurosensoriale bilaterale da moderata a grave, operati nel periodo novembre 2007-maggio 2008, presso la Clinica Otorinolaringoiatrica dell'Università di Pisa. La durata media del follow-up (considerato come tempo di utilizzo del dispositivo) è di 10,2 mesi (range 7-13). L'intervento chirurgico è stato eseguito in tutti i pazienti in anestesia generale; la durata è stata di ~3 ore e in nessun paziente si sono verificate complicanze intra-operatorie. In nessun paziente è stato osservato un deterioramento significativo post-operatorio della soglia uditiva sia per via aerea che per via ossea, a conferma di assenza di danno alle strutture cocleari. In tutti i pazienti abbiamo registrato miglioramenti della soglia uditiva in campo libero e nei test di percezione verbale con l'uso della protesi Carina™. Riguardo agli effetti avversi, non si è verificato nessun caso di estrusione dell'impianto, né di rottura, mancata comunicazione tra la parte impiantata e il controllo remoto o un aumento dei tempi di ricarica. In quattro casi, si sono verificati minimi problemi di feedback, che si sono risolti con modifiche minime di fitting. In un paziente invece le problematiche legate al feedback erano più importanti ed è stato necessario sottoporre il paziente ad un secondo intervento chirurgico, per modificare la posizione del microfono. I nostri risultati, in accordo con quelli della letteratura, attestano che la protesi impiantabile Otologics MET Carina™ è un trattamento alternativo per i pazienti affetti da sordità neurosensoriale da moderata a grave, che in casi selezionati può rappresentare una alternativa alla protesizzazione acustica convenzionale.

PAROLE CHIAVE: *Ipoacusia neurosensoriale • Protesi impiantabili*

Acta Otorhinolaryngol Ital 2009;29:79-85

Introduction

Middle ear implant technology represents the latest technological development in the treatment of patients suffering from moderate to severe hearing loss. Middle ear implants solve some of the problems of conventional hearing aid technology, such as *feedback*, signal distortion, ear canal occlusion and associated issues. While traditional hearing aids amplify sounds and then present them to the middle ear transducer mechanism via the external ear canal, implantable middle ear devices bypass the external auditory canal to directly vibrate the ossicular chain. These devices may be either totally or partially implantable, depending upon the location of the microphone and power source.

Semi-implantable prostheses are composed essentially of an external processor that converts acoustic sound into an electrical signal, an implanted receiver coil under the skin behind the ear and an electromechanical transducer applied to the ossicular chain, that transforms the electric signal into vibration. Currently, two different types of semi-implantable devices are available: the Vibrant Soundbridge (VSB), Med-El® Innsbruck, Austria [1-5] and the Otologics Middle Ear Transducer (MET), Otologics® Boulder, CO, USA [6 7].

As far as concerns totally implantable hearing aids, two different devices are currently available. The Esteem®-Hearing Implant™, Envoy Medical Corporation Saint Paul, MN, USA, is a totally implantable device, surgically implanted under the skin behind the ear, comprising two leads that extend into the middle ear from the device. It is composed of two piezoelectric bimorph crystals connected to a sound processor, containing electronics and battery source. One piezoelectric crystal, the sensor, is interfaced to the incus and serves, in conjunction with the patient's tympanic membrane, as a "semi-biologic" microphone. The second piezoelectric crystal, the driver, is coupled, through a facial recess tympano-mastoidectomy surgical approach, to the stapes. During the surgical procedure, the incus is separated from the stapes to prevent feedback vibrations [8]. The Envoy Medical has CE approval and is under clinical trial for FDA approval [8]. In 2008, Barbara et al. [9] published findings in a series of 6 patients implanted with the Esteem® device, concluding that it is a safe and reliable system for restoration of hearing in cases of moderate to severe sensorineural hearing loss (SNHL).

The MET Fully-Implantable Ossicular Stimulator (FIMOS) Carina™, from Otologics is a more recent version of the semi-implantable device, designed to address the amplification needs of adults with moderate to severe SNHL [10]. It obtained the CE approval both for sensorineural and conductive/mixed hearing loss in Europe, and is currently being investigated in clinical trials in the United States. The Carina™ device differs from the semi implantable version in that all components are implanted under the skin; this includes the microphone and the battery. There are no visible external components, thereby resolving many of the problems related to using external acoustic processors, such as swimming, sports activities and dusty work environments [10-14].

In this report, personal surgical and clinical experience with the fully implantable Carina™ is described in 5 patients with moderate to severe SNHL.

Patients and methods

Between November 2007 and May 2008, 5 patients (4 male, 1 female), mean age 44.4 years (range 34-66) were implanted with the FIMOS prosthesis in the ENT Unit of the University of Pisa. Of these 5 patients, 4 received the FIMOS prosthesis in the right ear and one in the left ear.

All patients presented a bilateral symmetrical post-lingual SNHL; hearing loss had been stable for one year at least and without fluctuations. All subjects were Italian speaking. Excluded from the study were patients with vestibular or osteo-degenerative disorders, middle ear pathology, a history of recurrent otitis media, conductive or mixed hearing loss, non-organic hearing loss, inner ear malformations, retro-cochlear hearing loss, central auditory nervous system disorder and prelinguistic onset of hearing loss.

Pre-operatively, all patients were submitted to otoscopy and otomicroscopy, pure tone audiometry for air conduction (AC) and bone conduction (BC), tympanometry and stapedial reflex study, speech audiometry with headphones and to pure tone audiometry in free field. Finally, pre-operatively, all the patients were submitted to a high resolution computed tomography (CT) scan of the petrous bone and a magnetic resonance imaging (MRI) of the inner ear and brain to establish whether they met the criteria for implantation.

Post-operatively, all patients were submitted to pure tone audiometry for AC and BC and to pure tone audiometry in free field, with the Carina™ switched on and the non-operated ear occluded, in order to calculate the functional gain (the difference between the pre-operative unaided and post-operative aided free field thresholds).

Moreover, post-operatively all patients were submitted to speech audiometry in free field both with the device switched on and off and to a speech perception test in the Italian language [15] both with the device switched on and off. The speech perception test was administered in sound-field, in a soundproof room, in quiet and without lip-reading, in live voice by the same speech therapist to all the patients, to avoid bias. The disyllabic words recognition score was evaluated, at a level of 65 dB. Both pre- and post-operatively during the tests performed in free-field, the non-operated ear was occluded.

Mean follow-up after surgery was 12.2 months (range 9-15), while mean follow-up after activation of Carina was 10.2 months (range 7-13).

Data were analysed by descriptive statistics, reporting the mean and the standard deviation (SD). Statistical significance was calculated by means of the analysis of variance (ANOVA), with $p < 0.05$ being considered statistically significant.

Pre-operatively the pure tone audiometry between 0.5-1-2-3 KHz (PTA) [16] in the ear to be treated was 64 dB HL (± 4 SD, range 57.5-67.5), while the pre-operative pure tone threshold in free field was 60.5 dB (± 8.1 SD, range 53.75-70); in this case, the non-operated ear was occluded. Middle ear anatomy and function were normal, as documented by otomicroscopy and middle ear immittance test.

Description of the device

The Otologics Carina™ consists of four primary components: 1) the implant (Figs. 1, 2), 2) the programming system, 3) the charger, and 4) the remote control. The implant contains the electronics capsule, microphone and the transducer. The electronics capsule contains the battery, magnet, digital signal processor, radiofrequency coil and connector. Sounds are picked up by a specially designed, extra-sensitive microphone, amplified and converted into an electrical signal that is then relayed to the transducer. The tip of the transducer is conventionally mounted in a hole drilled in the body of the incus; it can also be directly applied on the body of the incus. Furthermore, the tip of the transducer can be extended by applying a small titanium ball and placed on the body of the incus. The transducer translates electrical signals into a mechanical motion that directly stimulates the ossicles, enabling the wearer to perceive amplified sounds. The Otologics programming system consists of fitting software and a magnetically adherent radiofrequency coil. The charger system consists of a base station, charging coil and charger body. To charge the implant, the charging coil is placed on the skin, over the implant site. Typically, charging time requires 1 to 1.5 hours, if performed daily. A remote control placed over the implanted coil allows the implant to be turned on and off and to adjust the volume [10].

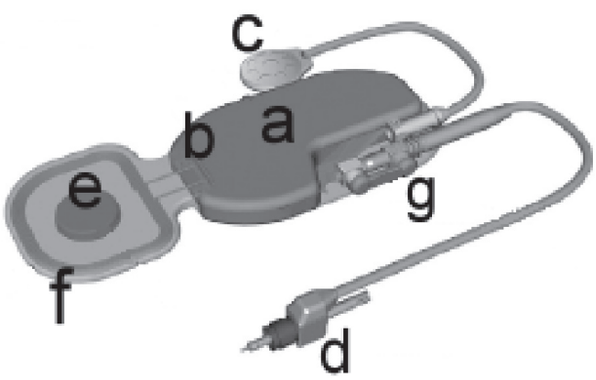

Fig. 1. Scheme of FIMOS Otologics MET Carina™ implant: a. battery; b. digital signal processor; c. microphone; d. transducer; e. magnet; f. receiver coil; g. connector.

Surgical technique

A slightly curved post-auricular incision was created; similar to that for a cochlear implant. Two flaps, cutaneous and muscular, were then developed until the spine of Henle and the mastoid region were visualized. A small superior atticotomy was created, about two cm wide, to expose the body of the incus and the head of the malleus and to introduce the transducer of the device. The arm of the mounting bracket of the device was modified to perfectly place the device on the incus. The mounting bracket was then fitted securely to the mastoid cortex using bone screws. The retaining ring was used to hold a KTP la-

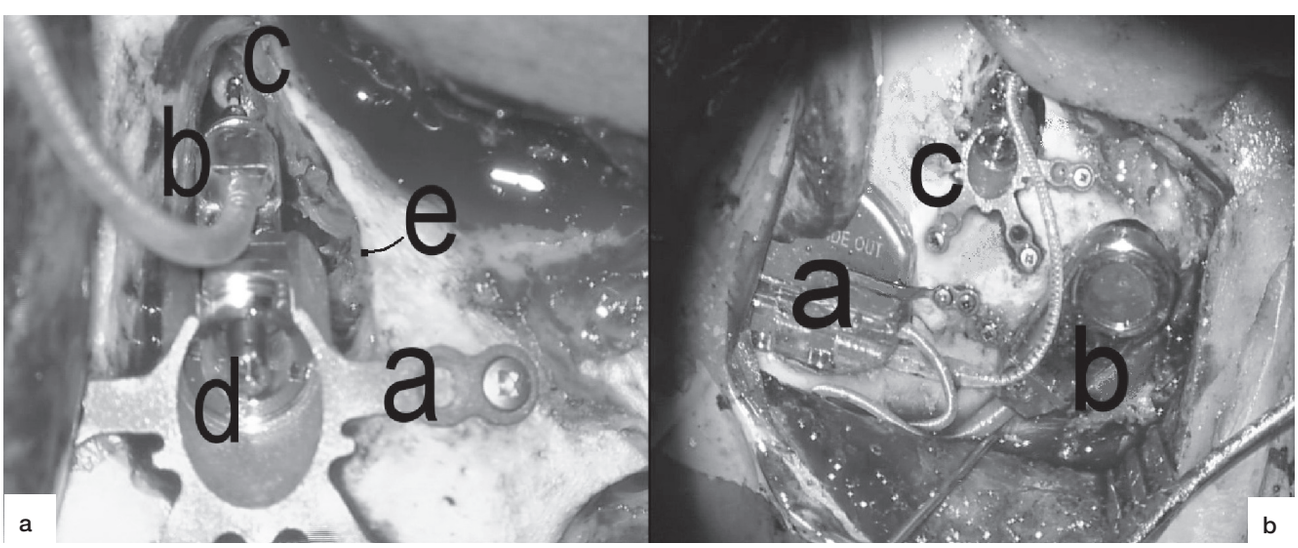

Fig. 2. Otologics Carina ™ placed on a right ear. 2a) Transducer in atticotomy. a: mounting bracket, b: transducer, c: incus and tip of transducer, d: transducer, e: atticotomy. 2b) all components of Otologics. a: device, b: microphone, c: transducer and mounting bracket.

Table I. Main audiological features of reported sample.

Patients	Operated ear	Pre-op. pure tone threshold in ear to be operated (0.5-1-2-3 KHz)*	Middle ear anatomy/ function	Pre-op. use of HA	Post-op. pure tone threshold in operated ear (0.5-1-2-3 KHz)*	Post-op. use of HA, contralaterally
1. ER, m, 41 yrs	Right	57.5 dB HL	Normal	Yes (left ear only). Recurrent external otitis in right ear	65 dB HL	No
2. MA, m, 43 yrs	Right	66.25 dB HL	Normal	No (personal choice)	70 dB HL	No
3. CA, m, 38 yrs	Right	67.5 dB HL	Normal	Yes (left ear only). Reported sound distortion and poor results in right ear	73.75 dB HL	Yes
4. DMD, m, 34 yrs	Left	66.25 dB HL	Normal	No (reported sound distortion and poor results)	70 dB HL	No
5. CL, f, 66 yrs	Right	62.5 dB HL	Mild presence of fibrous tissue/normal ossicular chain mobility	Yes (left ear only). Reported sound distortion in right ear	58.75 dB HL	Yes

*HA: hearing aids; * air conduction = bone conduction.*

ser guide, threaded with a 0.4-mm optic fibre. A 0.75 mm hole was then burned onto the incus body using the laser. Bone-beds for the device and the microphone were drilled so that the electronics capsule and the microphone could be positioned and secured (Fig. 2). The bone-bed was performed posterior and superior to the atticotomy. The microphone was placed on the mastoid tip in the first patients and in the retroauricular region in the others. The transducer was mounted in the retaining ring. The tip of the transducer was advanced into the hole on the incus and the positioning was evaluated using software specifically developed by Otologics to ensure correct placement of the device (Transducer Loading Assistant).

Laser was used only for the first patient. For the others, a surgical laser-less procedure was performed. For patients 2 and 5, the titanium ball was applied on the tip of the transducer and the titanium-ball placed directly on the incus. For patients 3 and 4, the tip of the transducer was applied directly on the incus, without the titanium-ball.

The main characteristics of the patients are outlined in Table I.

Results

Post-operatively, the mean pure tone audiometry threshold, in the operated ear, was 67.5 dB (± 5.8 SD, range 58.75-73.75), with a mean difference between pre- and post-operative thresholds in the operated ear of 3.5 dB (± 4.4 SD, range –3.75-7.5 dB). The difference between post-operative and pre-operative mean pure tone audiometry threshold in the operated ear was not significant ($p = 0.3$).

The mean post-operative threshold in free field with the Carina™ device switched on was 36.22 dB (± 4.9 SD, range 31.25-43.75) and the mean functional gain was 24.28 dB (± 10.17 SD, range 11.25-36.4 dB). The mean functional gain was statistically significant ($p = 0.0004$).

In Figure 3, the pre- and post-operative thresholds in the operated ear (3a) and the thresholds in free field

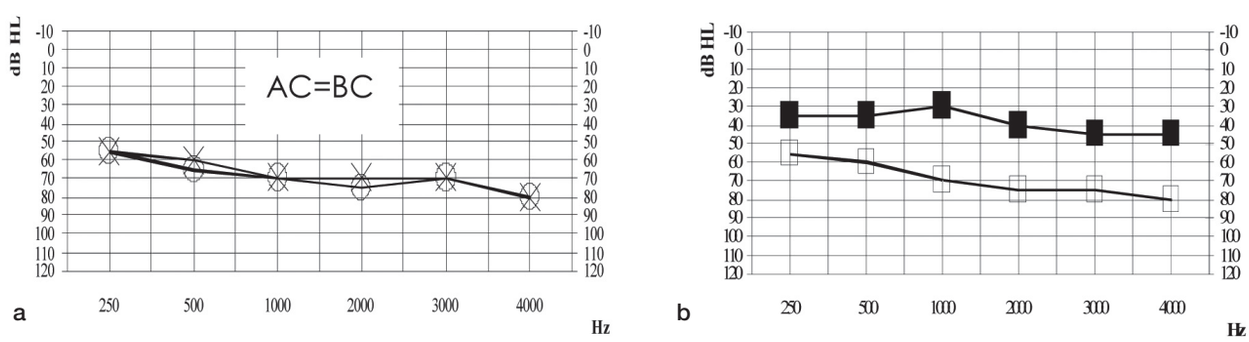

Fig. 3. Pre-operative pure tone audiometry of patient 2 (2a). Post-operative pure tone thresholds in free field without (empty square) and with Carina™ (full square) on right ear and left ear occluded (2b).

without and with Carina™ (3b) of a patient (MA) are reported.
The mean disyllabic words recognition score with the device switched off was 18% (± 25.6 SD, range 0-60%). The mean score rose to 58% (± 31.7 SD, range 15-90%) with the Carina™ switched on.
No surgical complications occurred. During follow-up, problems of feedback of variable degree presented in all patients. These problems were mild in 4 patients and were resolved with fitting adjustments. In one patient (ER), the first to be implanted, the feed back noise was higher, which presented every time while turning the head and it was necessary to reduce the gain. In this patient, it was decided to perform revision surgery to change the site of the microphone.

Discussion

The Otologics MET Carina™ is a fully implantable hearing prosthesis designed to address the amplification needs of adults, > 18 years of age, with moderate to severe SNHL and normal middle ears, providing a mechanical direct stimulation of the middle ear ossicles.
Jenkins et al., in two previous consecutive studies, namely in 2007 and 2008, reported the results with the Otologics fully implantable hearing system after 1, 3 months [10] and 1 year [13] of use in a Phase I clinical trial in 20 adult patients with moderate to severe bilateral, symmetrical, stable, not fluctuating SNHL. The majority of these patients were wearing bilateral hearing aids at the time of the study, while some of them started to use a single hearing aid in the ear to be implanted at the time of referral for implantation [10]. The devices were activated one month after the surgical procedure. In these cases, implantation of the electromechanical transducer in contact with the ossicular chain did not result in a change of middle ear function or cochlear status, as demonstrated by the stable post-operative air and bone conduction thresholds, that were similar to the pre-operative findings [10]. With regard to the adverse effects, after one year of follow-up Jenkins et al., in 2008, reported partial device extrusion in 3/20 subjects, requiring explantation in 2 patients, loss of external communication in 2/20 subjects, resulting in one explantation, increased charging times > 1.5 hours in 7/20 patients, resulting in 3 explantations and 2/20 patients not using their device while awaiting explantation [13]. Although some of the performance outcome measures with the Otologics FIMOS were lower than those pre-operatively with traditional hearing aids, the freedom and the cosmetic advantages obtained with the implant were appreciated by the patients, as emerged in the questionnaire for subjective benefits, that favoured the post-operative implant-aided condition [10 13]. The results reported following the study provided evidence that Carina™ device implantation is a safe and efficient procedure, indicating its usefulness as a feasible alternative to currently available hearing aids in selected patients with SNHL [10 13].
More recently, the Carina™ device was used in patients with ossicular chain malformations and conductive hearing loss. In these cases, the device must impart its mechanical energy to the cochlea via pathways other than the normal middle ear conductive pathway, such as the round window or the stapes footplate after a stapedotomy. In this regard Siegert et al, in 2007, implanted the Otologics MET Carina™ in 5 patients with congenital auricular atresia, using a modified transducer system, with satisfactory results [11], while Tringali et al., in 2008, successfully treated a case of severe conductive hearing loss by directly stimulating the stapes footplate with a MET™ V transducer for conductive applications, in a child with Franceschetti syndrome and bilateral auricular atresia associated with middle ear malformation [12].
In the present report, preliminary results with the Otologics MET Carina™ are outlined in 5 patients with moderate to severe SNHL.
The surgical procedure was performed under general anaesthesia, in about 3 hours, without surgical complications in any of the patients.
With regard to post-operative adverse effects, in our patients, after a mean period of 10.2 months of device use (range 7-13), no cases of extrusion of the device, device failure, loss of external communication or increased charging times were observed. Nevertheless, problems of feedback were observed in all patients. These problems were mild in 4 patients and were resolved with fitting adjustments. In one patient (patient n. 1) the feedback noise was higher, which presented every time while turning the head and it was necessary to reduce the gain. In this patient, it was decided to perform revision surgery to change the site of the microphone.
The position of the microphone seems to be crucial for proper functioning of the device. As reported by Jenkins et al. in 2008, there are 3 convenient microphone placement locations, in the temporalis region (anterior and superior to the external auditory canal), in the retro-auricular region (posterior to the external auditory canal) and on the mastoid tip. As the microphone is very sensitive to changes in tissue thickness over time, resulting in feedback, it is better to place it in a region with minimum tissue thickening changes during head and neck movements [13]. In patient n. 1, the microphone was placed near the tip of the mastoid; this caused noise and feedback. In the other patients, the microphone was placed in a higher position, in the retro-auricular region, with milder feedback problems. The tip of the mastoid is the region with the most changes in tissue thickening, during head and neck movements, resulting in feedback problems. In our opinion, placing the microphone, not on the mastoid tip, but posterior to the external ear canal, in a muscle pocket, could minimize feedback problems.

In the 5 patients, described, in the present report, no significant post-operative variation in hearing thresholds, were recorded either for AC or BC. The mean deterioration of the thresholds was 3.5 dB (p=0.3), confirming the absence of surgical damage to the cochlea.
The mean functional gain in free field, across the frequencies 0.5-1-2-3 KHz was 24.28 dB and was statistically significant (p=0.0004).
The coupling efficiency of the implant to the middle ear ossicles has been reported to be crucial for patient performance with an implantable hearing device: insufficient pressure placed on the ossicles limits the energy transfer, while too much pressure can result in a conductive loss. When properly placed, these devices can give the appropriate amplification to the wearer, with less battery consumption and a shorter daily recharge time [14]. Moreover, an increased coupling efficiency allows more amplification to be given before the feedback occurs [14]. The use of intra-operative loading instrumentation during surgery improves the coupling efficiency and consistency of a fully implantable hearing device to the ossicles, thus leading to better patient performance [14]. In our opinion, this intra-operative technique represents an important improvement for the surgeon's easiness and confidence during surgery, allowing better audiometric results.
As far as concerns the cases described herein, a hole was made, in the incus, using the laser only in the first patient. Making the hole in the incus is a dangerous step, with the risk of deterioration of residual hearing, thus in the following patients, laser was not used and no hole was made in the incus. Placing the tip of the transducer into the hole of the incus, definitely allows a perfect coupling of the implant to the middle ear ossicles. Nevertheless, perfect coupling of the tip of the transducer and of the titanium ball assembled on the tip of the transducer was achieved to the intact body of the incus as revealed by the Transducer Loading Assistant system. In our preliminary experience, the laser-less technique was easier, faster and safer than the conventional laser procedure; more cases and a longer follow-up will provide useful information to better understand the effectiveness of the laser-less technique.
Personal experience and the results reported in the literature, with the fully implantable Carina™ device, are positive and subjective satisfaction with the device is observed in relation to the absence of occlusion, the cleanliness of the external ear, the invisibility of the prosthesis, the possibility of practicing sports activities such as swimming, the quality of sound, the ability to regulate the volume of the implant, the better quality in a noisy environment etc. Nevertheless, considering recent improvements in hearing aid technology, it would be appropriate to analyze the results obtained with the Carina™ device in comparison to the results obtained with traditional digital last generation hearing aids, such as those with *open fitting* coupling. This would be useful to better define inclusion criteria for Carina™ device implantation. Moreover, there are some issues concerning this procedure to be taken into consideration. It requires a surgical procedure under general anaesthesia, even if no trauma to the inner ear structures have been reported, and no changes in the ossicular chain and middle ear are required, allowing the implant with *restitutio ad integrum* to be removed, if necessary. Moreover, some post-operative complications may occur, such as device extrusion or malfunctioning, requiring further surgery. The Carina™ implantation is an expensive procedure and, in Italy, the Public Health Service funds only one implant; this excludes patients from binaural hearing. In this regard, 2 of the patients described in the present report use a traditional hearing aid controlaterally to the implanted ear, with benefits derived from bilateral stimulation. Another issue concerning this procedure is the incompatibility with MR.
In conclusion, our results, in agreement with those reported in the literature, confirm that the Otologics MET Carina™ offers viable treatment for moderate to severe SNHL and that, in selected cases, it may represent an alternative to conventional hearing aids. The audiometric results demonstrate that the device can be implanted without affecting residual cochlear hearing levels and auditory performance has been shown to be similar or better than that reported with conventional hearing aids. Finally, the device proved to be well tolerated by the patients, without significant surgical or post-operative complications, offering the same freedom and comfort as the natural auditory system, allowing use in all environments with no limitations in normal activities. Nevertheless, more cases, with a longer follow-up and comparative studies with latest generation conventional digital hearing aids, are required to better define inclusion criteria and draw general conclusions.

References

1 Fisch U, Cremers CW, Lenarz T, Weber B, Babighian G, Uziel AS, et al. *Clinical experience with the Vibrant Soundbridge implant device*. Otol Neurotol 2001;22:962-72.

2 Lenarz T, Weber BP, Issing PR, Gnadeberg D, Ambjørnsen K, Mack KF, et al. *Vibrant Sound Bridge System. A new kind of hearing prosthesis for patients with sensorineural hearing loss. 2. Audiological results.* Laryngorhinootologie 2001;80:370-80.

3 Sterkers O, Boucarra D, Labassi S, Bebear JP, Dubreuil C, Frachet B, et al. *A middle ear implant, the Symphonix Vibrant SoundBridge: retrospective study of the first 125 patients implanted in France.* Otol Neurotol 2003;24:427-36.

4 Colletti V, Soli SD, Carner M, Colletti L. *Treatment of mixed*

hearing losses via implantation of a vibratory transducer on the round window. Int J Audiol 2006;45:600-8.

[5] Bruschini L, Forli F, Giannarelli M, Bruschini P, Berrettini S. *Exclusive transcanal surgical approach for Vibrant Soundbridge Implantation: surgical and functional results.* Otol Neurotol in press. (In press).

[6] Jenkins HA, Niparko JK, Slattery WH, Neely JG, Fredrickson JM. *Otologics Middle Ear Transducer Ossicular Stimulator: performance results with varying degrees of sensorineural hearing loss*. Acta Otolaryngol 2004;124:391-4.

[7] Kasic JF, Fredrickson JM. *The Otologics MET Ossicular Stimulator*. Otolaryngol Clin North Am 2001;34:501-13.

[8] Chen DA, Backous DD, Arriaga MA, Garvin R, Kobylek D, Littman T, et al. *Phase 1 clinical trial results of the Envoy System: a totally implantable middle ear device for sensorineural hearing loss.* Otolaryngol Head Neck Surg 2004;131:904-16.

[9] Barbara M, Manni V, Monini S. *Totally implantable middle ear device for rehabilitation of sensorineural hearing loss: preliminary experience with the Esteem(R), Envoy.* Acta Otolaryngol 2008;31:1-4.

[10] Jenkins HA, Atkins JS, Horlbeck D, Hoffer ME, Balough B, Arigo JV, et al. *Phase 1 preliminary results of use of the Otologics MET Fully Implantable Ossicular Stimulator*. Otolaryngology Head and Neck Surgery 2007;137:206-12.

[11] Siegert R, Mattheis S, Kasic J. *Fully implantable hearing aids in patients with congenital auricolar atresia.* Laryngoscope 2007; 117: 336-40.

[12] Tringali S, Pergola N, Ferber-Viart F, Truy E, Berger P, Dubreuil C. *Fully implantable hearing device as a new treatment of conductive hearing loss in Franceschetti syndrome.* Int J Pediatr Otorhinolaryngol 2008;72:513-7.

[13] Jenkins HA, Atkins JS, Horlbeck D, Hoffer ME, Balough B, Alexiades G, et al. *Otologics fully implantable hearing system: Phase I trial 1-year results*. Otol Neurotol 2008;29:534-41.

[14] Jenkins HA, Pergola N, Kasic J. *Intra-operative ossicular loading with the Otologics fully implantable hearing device.* Acta Otolaryngol 2007;127:360-4.

[15] *Protocollo comune per la valutazione dei risultati in audiologia riabilitativa*. I Care Ed. Firenze: C.R.O., 1997.

[16] *Committee on Hearing and Equilibrium guidelines for the evaluation of results of treatment of conductive hearing loss*. American Academy of Otolaryngology-Head and Neck Surgery Foundation, Inc. Otolaryngol Head Neck Surg 1995;113:186-7.

Received: February 18, 2009 – Accepted: March 15, 2009

Address for correspondence: Prof. S. Berrettini, SOD Otologia-Impianti Cocleari, Università di Pisa, Via Savi 10, 56126 Pisa, Italy. Fax +39 050 993544. E-mail : s.berrettini@med.unipi.it