J. Anat. (2009) **215**, pp300–319 doi: 10.1111/j.1469-7580.2009.01111.x

On the origin, homologies and evolution of primate facial muscles, with a particular focus on hominoids and a suggested unifying nomenclature for the facial muscles of the Mammalia

R. Diogo,[1] B. A. Wood,[1] M. A. Aziz[2] and A. Burrows[3,4]

[1]*Center for the Advanced Study of Hominid Paleobiology, Department of Anthropology, George Washington University, Washington, DC, USA*
[2]*Department of Anatomy, Howard University, Washington, DC, USA*
[3]*Department of Physical Therapy, Duquesne University, Pittsburgh, PA, USA*
[4]*Department of Anthropology, University of Pittsburgh, Pittsburgh, PA, USA*

Abstract

The mammalian facial muscles are a subgroup of hyoid muscles (i.e. muscles innervated by cranial nerve VII). They are usually attached to freely movable skin and are responsible for facial expressions. In this study we provide an account of the origin, homologies and evolution of the primate facial muscles, based on dissections of various primate and non-primate taxa and a review of the literature. We provide data not previously reported, including photographs showing in detail the facial muscles of primates such as gibbons and orangutans. We show that the facial muscles usually present in strepsirhines are basically the same muscles that are present in non-primate mammals such as tree-shrews. The exceptions are that strepsirhines often have a muscle that is usually not differentiated in tree-shrews, the depressor supercilii, and lack two muscles that are usually differentiated in these mammals, the zygomatico-orbicularis and sphincter colli superficialis. Monkeys such as macaques usually lack two muscles that are often present in strepsirhines, the sphincter colli profundus and mandibulo-auricularis, but have some muscles that are usually absent as distinct structures in non-anthropoid primates, e.g. the levator labii superioris alaeque nasi, levator labii superioris, nasalis, depressor septi nasi, depressor anguli oris and depressor labii inferioris. In turn, macaques typically lack a risorius, auricularis anterior and temporoparietalis, which are found in hominoids such as humans, but have muscles that are usually not differentiated in members of some hominoid taxa, e.g. the platysma cervicale (usually not differentiated in orangutans, panins and humans) and auricularis posterior (usually not differentiated in orangutans). Based on our observations, comparisons and review of the literature, we propose a unifying, coherent nomenclature for the facial muscles of the Mammalia as a whole and provide a list of more than 300 synonyms that have been used in the literature to designate the facial muscles of primates and other mammals. A main advantage of this nomenclature is that it combines, and thus creates a bridge between, those names used by human anatomists and the names often employed in the literature dealing with non-human primates and non-primate mammals.

Key words anatomy; evolution; facial muscles; hominoids; homologies; humans; mammals; nomenclature; primates.

Introduction

In a recent work Diogo et al. (2008) reported the results of their long-term study of the comparative anatomy, homologies and evolution of the head and neck muscles of sarcopterygians (the group comprising tetrapods and bony fish such as coelacanths and dipnoans). The study was mainly based on dissections of numerous non-primate sarcopterygians and a few primates, and on a review of the literature. Its goal was to present the homologies and evolution of the mandibular, hyoid, branchial and hypobranchial muscles of the Sarcopterygii as a whole, thus providing a background for more detailed morphological and taxon-based analyses. Of the nine sarcopterygian taxa featured in the tables of that study, only one, *Homo sapiens*, was a primate. In the present work we focus on the origin, evolution and homologies of the facial muscles of primates, particularly hominoids.

Correspondence
Dr Rui Diogo, Department of Anthropology, The George Washington University, 2110 G St. NW, Washington, DC 20052, USA.
T: 202-248-1440; F: 202-994-6097; E: Rui_Diogo@hotmail.com

Accepted for publication *15 May 2009*
Article published online *17 June 2009*

© 2009 The Authors
Journal compilation © 2009 Anatomical Society of Great Britain and Ireland

The facial muscles are a subgroup of the hyoid muscles *sensu* Edgeworth (1935) (i.e. muscles innervated by cranial nerve VII) (for a recent review, see Diogo et al. 2008). Except for the buccinatorius and mandibulo-auricularis muscles, they are attached to the dermis of the skin and the elastic cartilage of the pinna. They are involved in generating facial expressions during social interactions among conspecifics, as well as in feeding, chemosensation, whisker motility, hearing, vocalization and in human speech (e.g. Burrows, 2008). Unlike most skeletal muscles of vertebrates, the facial muscles usually do not attach via tendons but typically attach via a subcutaneous musculoaponeurotic sheath (e.g. Larrabee & Makielski, 1993). Many anatomical works have provided information about the facial muscles of primates, particularly in the 19th century and the first three quarters of the 20th century (e.g. Owen, 1830–1831; Duvernoy, 1855–1856; Wilder, 1862; Gratiolet & Alix, 1866; Broca, 1869; Bischoff, 1870, 1880; MacAlister, 1871; Champneys, 1872; Murie & Mivart, 1872; Sirena, 1876; Sutton, 1883; Chudzinski, 1885; Deniker, 1885; Ruge, 1885, 1887a,b, 1890, 1897, 1910, 1911; Le Double, 1897; Sperino, 1897; Zuckerlkandl, 1900; Sommer, 1907; Polak, 1908; Virchow, 1915; Sonntag, 1923, 1924a,b; Lightoller, 1925, 1928a,b, 1934, 1939, 1940a,b, 1942; Sullivan & Osgood, 1925; Woollard, 1925; Schreiber, 1928; Huber, 1930a,b, 1931, 1933; Loth, 1931; Edgeworth, 1935; Miller, 1952; Hill, 1953, 1955, 1957, 1959, 1960a,b, 1970, 1974; Shibata, 1959; Gasser, 1967; Schön, 1968; Seiler, 1970, 1971a,b,c,d,e, 1973, 1974a,b, 1975, 1977, 1979a,b, 1980; Jouffroy & Saban, 1971; Swindler & Wood, 1973; Pellatt, 1979a,b; Peng et al. 1982). In recent years, there has been a renewed interest in the comparative anatomy of the primate facial muscles. Burrows and colleagues have been re-examining the presence/absence, configuration and function of the facial muscles of various primates, using a new 'face mask' technique in which the superficial facial musculature, skin and fascia are carefully removed from the skull (e.g. Burrows & Smith, 2003; Burrows et al. 2006, in review; Burrows, 2008; Waller et al. 2008a,b; Rogers et al. 2009). They claim that, by using this methodology instead of the more traditional method of removing the skin and attempting to leave behind all of the musculature with the skull, a greater number of facial muscles is preserved. For instance, their results suggest that the muscles of facial expression in the common chimpanzee, *Pan troglodytes*, are more similar to the arrangement seen in *Homo sapiens* than previously reported (Burrows et al. 2006). These results were supported by the recent comparative studies of Diogo and colleagues, who used both the traditional dissection method and the new 'face mask' technique to reanalyse the facial muscles of primates and compare them with those of other mammals in order to investigate the identity and homologies of the primate muscles in a broader phylogenetic context (e.g. Diogo & Wood, 2008; Diogo et al. 2008; Diogo, 2009).

The present account of the origin, homologies and evolution of the primate facial muscles is based on the results of our own recent dissections of various primates combined with an exhaustive literature review. It includes a significant amount of new data, e.g. the results of our observations of the facial muscles of specimens of *Hylobates* and *Pongo*. To our knowledge, this is the first publication providing photographs that show in detail the facial muscles of primates such as hylobatids and orangutans. As we have now dissected specimens of each of the five main extant hominoid groups (Hylobatidae, Ponginae, Gorillini, Panini and Hominini; see Fig. 1), a significant part of this study and of Table 1 will be focused on the hominoids. The results of our observations and comparisons are summarized in Table 1, which presents the best supported hypotheses

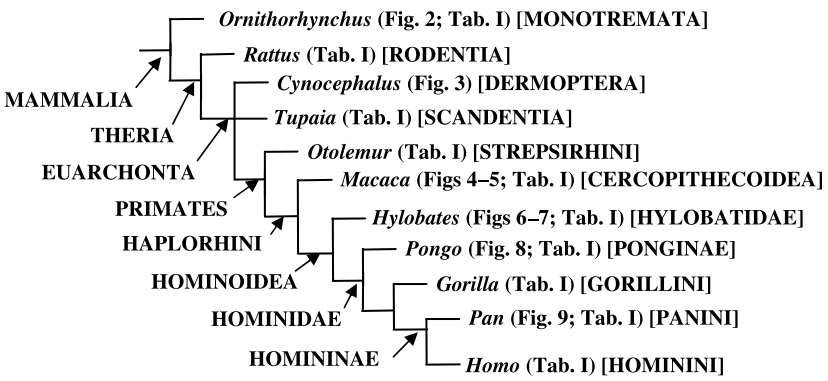

Fig. 1 Phylogenetic framework for the discussion provided in the present study and the comparison between the head and neck muscles of the genera listed in Table 1 and shown in Figs 2–9, based on Pough et al. (1996), Shoshani et al. (1996), Kardong (2002), Sargis (2002a,b, 2004), Dawkins (2004), Gunnell & Simons (2005), Kemp (2005), Marivaux et al. (2006), Janeka et al. (2007) and Silcox et al. (2007). The Primates, Dermoptera (including colugos or 'flying lemurs') and Scadentia (including tree-shrews) are placed in an unresolved trichotomy because the relationships between these three groups remain mainly unresolved (some authors continue to group colugos with tree-shrews, others group tree-shrews with primates and yet others group colugos with primates; see, e.g. Sargis, 2002a,b, 2004; Dawkins, 2004; Marivaux et al. 2006; Janeka et al. 2007; Silcox et al. 2007); the names of the primate subgroups are those used by Shoshani et al. (1996) [modified from Diogo et al. (2008); for more details see this latter work].

© 2009 The Authors
Journal compilation © 2009 Anatomical Society of Great Britain and Ireland

Table 1 Scheme illustrating the authors' hypotheses regarding the homologies of the facial muscles of adults of representative non-primate and primate mammalian taxa

Monotremata: *Ornithorhynchus anatinus* (10 mus. - not ex. ear)	Rodentia: *Rattus norvegicus* (20 mus. - not ex. ear)	Scandentia: *Tupaia* sp. (21 mus. - not ex. ear)	Primates, Strepsirhini: *Lepilemur ruficaudatus* (20 mus. - not ex. ear)	Primates, Cercopithecoidea: *Macaca mulatta* (23 mus. - not ex.ear)	Primates, Hominoidea: *Hylobates lar* (23 mus. - not ex. ear)	Primates, Hominoidea: *Pongo pygmaeus* (21 mus. - not ex. ear)	Primates, Hominoidea: *Gorilla gorilla* (24 mus. - not ex. ear)	Primates, Hominoidea: *Pan troglodytes* (22 mus. - not ex. ear)	Primates, Hominoidea: *Homo sapiens* (24 mus. - not ex. ear)
Platysma cervicale[1]	Platysma cervicale[2]	Platysma cervicale[3]	Platysma cervicale[4]	Platysma cervicale[5]	Platysma cervicale[6]	–	Platysma cervicale[7]	–[8]	–[9]
Platysma myoides[10]	Platysma myoides[11]	Platysma myoides[12]	Platysma myoides[13]	Platysma myoides[14]	Platysma myoides[15]	Platysma myoides[16]	Platysma myoides[17]	Platysma myoides[18]	Platysma myoides[19]
–[20]	Occipitalis[21]	Occipitalis[22]	Occipitalis[23]	Occipitalis[24]	Occipitalis[25]	Occipitalis[26]	Occipitalis[27]	Occipitalis[28]	Occipitalis[29]
–	Aur. posterior[30]	Aur. posterior	Aur. posterior[31]	Aur. posterior[32]	Aur. posterior[33]	–[34]	Aur. posterior	Aur. posterior[35]	Aur. posterior
Ex. ear mus.[36]	Ex. ear mus.[37]	Ex. ear mus.[37]	Ex. ear mus.[37]	Ex. ear mus.[37]	Ex. ear mus.[37]	Ex. ear mus.[37]	Ex. ear mus.[37]	Ex. ear mus.[37]	Ex. ear mus.[37]
–	Mandibulo-aur.	Mandibulo-aur.[38]	Mandibulo-aur.	–[39]	–	–	–	–	–[40]
–	–	–	–	–	–[41]	–[41]	–[41]	–[41]	Risorius
Interhyoideus prof.[42]	–	–	–	–	–	–	–	–	–
Sphincter colli supe.[43]	Sphincter colli supe.[44]	Sphincter colli supe.[45]	–	–	–	–	–	–[46]	–[47]
–(colli prof. in Echidna)[48]	Sphincter colli prof.[49]	Sphincter colli prof.	Sphincter colli prof.[50]	–[51]	–	–	–	–[46]	–[52]
–	Sternofacialis[53]	–	–	–	–	–	–	–	–
Cervicalis tra.	–	–	–	–	–	–	–	–	–
–	Interscutularis[54]	–	–	–	–	–	–	–	–
–	Zygomaticus maj.[55]	Zygomaticus maj.[56]	Zygomaticus maj.[57]	Zygomaticus maj.[58]	Zygomaticus maj.[59]	Zygomaticus maj.[60]	Zygomaticus maj.[61]	Zygomaticus maj.[62]	Zygomaticus maj.[63]
–	Zygomaticus min.[64]	Zygomaticus min.[65]	Zygomaticus min.[66]	Zygomaticus min.[67]	Zygomaticus min.[68]	Zygomaticus min.[69]	Zygomaticus min.[70]	Zygomaticus min.[71]	Zygomaticus min.
–	Orbito-temporo-aur.[72]	Frontalis	Frontalis	Frontalis	Frontalis	Frontalis	Frontalis[73]	Frontalis[74]	Frontalis[75]
–	–	Auriculo-orbitalis[76]	Auriculo-orbitalis[77]	Auriculo-orbitalis[78]	Auriculo-orbitalis[79]	Auriculo-orbitalis[80]	Temporoparietalis[81]	Auriculo-orbitalis[82]	Temporoparietalis
–	–	–[83]	–[84]	–[85]	–	–	Aur. anterior[86]	–[87]	Aur. anterior
–	–	Aur. superior	Aur. superior[88]	Aur. superior[89]	Aur. superior	Aur. superior	Aur. superior[90]	Aur. superior[91]	Aur. superior
Orbic. oculi	Orbic. oculi	Orbic. oculi[92]	Orbic. oculi[92]	Orbic. oculi[93]	Orbic. oculi	Orbic. oculi	Orbic. oculi	Orbic. oculi	Orbic. oculi
–	–	Zygomatico-orbic.	–[94]	–	–	–	–	–	–
–	–	–	De. supercilii[95]	De. supercilii[96]	De. supercilii	De. supercilii[97]	De. supercilii	De. supercilii	De. supercilii
–	–	Corru. supercilii[98]	Corru. supercilii[95]	Corru. supercilii	Corru. supercilii	Corru. supercilii	Corru. supercilii	Corru. supercilii	Corru. supercilii
Naso-labialis	Naso-labialis[99]	Naso-labialis[100]	Naso-labialis[101]	Le. labii sup.[102]	Le. labii sup.[103]	Le. labii sup.[104]	Le. labii sup.[105]	Le. labii sup.[106]	Le. labii sup.[107]
–	–	–	–	Le. labii sup. nasi.[108]	Le. labii sup. nasi.[109]	Le. labii sup. nasi.[110]	Le. labii sup. nasi.[111]	Le. labii sup. nasi.[112]	Le. labii sup. nasi.[113]
–	Procerus[114]	–	–[115]	Procerus[116]	Procerus[117]	Procerus[118]	Procerus[119]	Procerus[120]	Procerus[121]
Buccinatorius[122]	Buccinatorius[123]	Buccinatorius[124]	Buccinatorius	Buccinatorius	Buccinatorius	Buccinatorius	Buccinatorius	Buccinatorius	Buccinatorius
–	Dilatator nasi[125]	–	–	–	–	–	–	–	–
–	Maxillo-naso-lab.[126]	Maxillo-naso-lab.[127]	Maxillo-naso-lab.[128]	Nasalis[129]	Nasalis	Nasalis	Nasalis	Nasalis[130]	Nasalis[131]
–	–	–	–[132]	De. septi nasi[133]	De. septi nasi[134]	De. septi nasi[135]	De. septi nasi[136]	De. septi nasi[137]	De. septi nasi[138]
–	Le. anguli oris fac.[139]	Le. anguli oris fac.[140]	Le. anguli oris fac.[141]	Le. anguli oris fac.[142]	Le. anguli oris fac.[143]	Le. anguli oris fac.[144]	Le. anguli oris fac.[145]	Le. anguli oris fac.[146]	Le. anguli oris fac.[147]
Orbic. oris[148]	Orbic. oris	Orbic. oris	Orbic. oris[149]	Orbic. oris[150]	Orbic. oris[151]	Orbic. oris[152]	Orbic. oris[153]	Orbic. oris[154]	Orbic. oris[155]
–	–	–	–[156]	De. labii inf.[157]	De. labii inf.	De. labii inf.[158]	De. labii inf.[159]	De. labii inf.[160]	De. labii inf.[161]
–	–	–	–	De. anguli oris[162]	De. anguli oris[163]	De. anguli oris[164]	De. anguli oris[165]	De. anguli oris[166]	De. anguli oris[167]
Mentalis[168]	–	Mentalis[169]	Mentalis[170]	Mentalis[171]	Mentalis	Mentalis[172]	Mentalis	Mentalis	Mentalis[173]

© 2009 The Authors
Journal compilation © 2009 Anatomical Society of Great Britain and Ireland

Data from evidence provided by our own dissections and comparisons and by a review of the literature. The black arrows indicate the hypotheses that are most strongly supported by the evidence available; the grey arrows indicate alternative hypotheses that are supported by some of the data but overall they are not as strongly supported by the evidence available as are the hypotheses indicated by black arrows. In order to facilitate comparisons, in some cases names often used by other authors to designate a certain muscle/bundle are given between round brackets; additional comments are given between square brackets (see also text and Figs 2–9). aur., auricularis; corru., corrugator; fac., facialis; de., depressor; ex., extrinsic; inf., inferioris; lab., labialis; le., levator; nasi, alaeque nasi; maj., major; min., minor; mus., muscles; orbic., orbicularis; prof., profundus; sup., superioris; supe., superficialis; tra., transversus.

[1](Pars nuchalis of platysma *sensu* Saban 1971; part of the platysma *sensu* Lightoller 1942.)

[2](The cranial panniculus *sensu* Greene 1935 corresponds to the platysma cervicale + zygomaticus major *sensu* the present work; the superficial and deep portions of the cervical panniculus *sensu* Greene 1935 correspond to the sphincter colli profundus + superficialis and to the sternofacialis *sensu* the present work, respectively.)

[3](Part of platysma *sensu* Le Gros Clark 1924; part of notoplatysma *sensu* Lightoller 1934.)

[4](Notoplatysma *sensu* Lightoller 1934; part of platysma *sensu* Huber 1930a, 1931; Hill 1953 and Burrows & Smith 2003.)

[5](Notoplatysma *sensu* Lightoller 1928a.)

[6](Nuchal part of platysma *sensu* Huber 1930b, 1931; Loth 1931 and Edgeworth 1935.)

[7](Nuchal and deep portions of platysma *sensu* Raven 1950.)

[8][According to Macalister 1871, Loth 1931, Miller 1952 and Swindler & Wood 1973 a small platysma cervicale/transversus nuchae might be present in some chimpanzees and bonobos.]

[9][Aziz 1981 considers that the transversus nuchae found in some humans is a remnant of the platysma cervicale but Gasser 1967 describes both a platysma cervicale and a transversus nuchae in early human embryos.]

[10](Probably corresponds to pars omoidea *sensu* Saban 1971.)

[11][Mixed with platysma cervicale.]

[12][Mixed with platysma cervicale.]

[13](Tracheloplatysma *sensu* Lightoller 1934; part of platysma *sensu* Huber 1930a, 1931 and Burrows & Smith 2003) [mixed with platysma cervicale].

[14](Trachelo-platysma *sensu* Lightoller 1928a.)

[15](Part – not nuchal – of the platysma *sensu* Huber 1930b, 1931, Loth 1931 and Edgeworth 1935.)

[16](Subcutaneous colli or tracheoplatysma *sensu* Sullivan & Osgood 1925.)

[17](Part of platysma *sensu* Raven 1950.)

[18](Platysma *sensu* MacAlister 1871 and Miller 1952; tracheloplatysma *sensu* Swindler & Wood 1973.)

[19](Peaucier du coup *sensu* Loth 1931; platysma *sensu* Terminologia Anatomica 1998 and Netter 2006.)

[20][As described by e.g. Lightoller 1942 in the platypus specimens dissected by us there is a bundle of the platysma that is somewhat similar to the occipitalis of the other mammals listed on this Table I but this bundle is clearly part of the platysma, i.e. it does not constitute an independent muscle.]

[21](Cranial part of levator auris longus *sensu* Greene 1935) [the occipitalis of *Rattus* is similar to that of *Tupaia* and *Cynocephalus*, i.e. it has a medial portion (= occipitalis *sensu* Lightoller 1934) that extends anteriorly to mix with the frontalis and a lateral portion (= cervico-auriculo-occipitalis *sensu* Lightoller 1934) that runs anteroventrolaterally to attach on the posterior surface of the ear; these two portions are deeply mixed posteriorly, attaching to the dorsal region of the neck, just medially to the posterior attachment of the auricularis posterior].

[22](Occipitalis + cervico-auriculo-occipitalis *sensu* Lightoller 1934; see *Rattus*.)

[23](Occipitalis + cervico-auriculo-occipitalis *sensu* Lightoller 1934; see *Rattus*; possibly includes part of the attrahens aurem and/or retrahens aurem *sensu* Burrows & Smith 2003; see auricularis anterior.)

[24](Occipitalis + cervico-auriculo-occipitalis *sensu* Lightoller 1928a.)

[25](Occipitalis plus part of the auricularis posterior *sensu* Edgeworth 1935.)

[26](Part or totality of auriculo-occipitalis *sensu* Sullivan & Osgood 1925 and Lightoller 1928a and of auriculo-occipitalis proprius *sensu* Lightoller 1928a, which includes the occipitalis + posterior auricularis; part or totality of occipito-auricularis *sensu* Edgeworth 1935.)

[27](Occipito-auricularis *sensu* Edgeworth 1935; part of epicranius, or auriculo-occipitalis, *sensu* Raven 1950.)

[28](Part of occipito-frontalis *sensu* Owen 1830–1831, MacAlister 1871 and Sutton 1883.)

[29](Venter occipitalis of occipitofrontalis *sensu* Terminologia Anatomica 1998) [the developmental study of Gasser 1967 in modern humans indicates that the occipitalis, auricularis posterior and transversus nuchae develop from a same anlage.]

© 2009 The Authors
Journal compilation © 2009 Anatomical Society of Great Britain and Ireland

[30](Caudal part of levator auris longus *sensu* Greene 1935.)
[31](Retrahens aurem *sensu* Murie & Mivart 1872 and retrahens aurem and possibly attrahens aurem *sensu* Burrows & Smith 2003; see auricularis anterior.)
[32][The auricularis posterior is present in the *Macaca mulatta* specimens dissected by Lightoller 1928a, Huber 1930b, 1931, 1933, as well as in specimens such as HU-ANA-N01.]
[33](Part of the auricularis posterior *sensu* Edgeworth 1935.)
[34][But see text.]
[35](Retrahens aurem *sensu* Macalister 1871.)
[36][Our dissections and comparisons indicate that the platypus has at least some extrinsic muscles of the ear, as suggested by Lightoller 1942; according to Huber 1930a,b, 1931 and Jouffroy & Saban 1971, some of the extrinsic muscles of the ear derive from the platysma, whereas others derive from the sphincter colli profundus.]
[37][Examples of extrinsic, facial muscles of the ear present in therian mammals are the obliquus auriculae, transversus auriculae, helicis, tragicus, depressor helicis and/or antitragicus; see e.g. Jouffroy & Saban 1971.]
[38](Auriculo-mandibularis *sensu* Lightoller 1934.)
[39][But see text; the 'auricularis inferior' *sensu* Waller et al. 2008b might correspond to a 'vestigial mandibulo-auricularis' *sensu* Huber 1930b, 1931, 1933.]
[40][Probably corresponds to the stylo-mandibular ligament; according to Jouffroy & Saban 1971 it may possibly also correspond to the stylo-auricularis muscle abnormally present in a few modern humans.]
[41][But see text.]
[42](Sphincter colli profundus *sensu* Lightoller, 1942; hyomandibularis *sensu* Edgeworth, 1935.)
[43](Corresponds to Huber's 1930a sphincter colli externus – of platypus – and sphincter colli – of echidna.)
[44](Transitus *sensu* Lightoller 1942) [as explained by e.g. Lightoller 1940a, 1942, although much reduced, in rats the sphincter colli does have a component that is superficial to the platysma, i.e. a sphincter colli superficialis.]
[45](Probably corresponds to the occipito-cervicalis *sensu* Lightoller 1934 and might correspond to the cervico-mandibularis *sensu* Le Gros Clark 1926, which was originally described as part of the platysma of *Ptilocercus* but actually probably corresponds to the sphincter colli superficialis of *Tupaia* and other mammals.)
[46][It is commonly accepted that hominoids such as modern humans and chimpanzees do not have a sphincter colli superficialis or a sphincter colli profundus but according to Burrows et al. 2006 a 'sphincter colli' may be found in some chimpanzees; in the hominoids dissected for the present work none of these muscles was not present as an independent structure.]
[47][According to Loth 1931 some humans might have a muscle 'mandibulo-marginalis', which is a remnant of the 'sphincter colli' (sphincter colli superficialis *sensu* the present work because in his Fig. 8 the 'mandibulo-marginalis' is superficial to the platysma myoides).]
[48][Absent as an independent muscle in the platypus.]
[49](Superficial portion of cervical platysma *sensu* Greene 1935; sphincter colli profundus + 'primitive sphincter colli' of Fig. 6 of Huber 1930; transitus *sensu* Lightoller 1940a) [deeply mixed with the sphincter colli superficialis].
[50](Sphincter colli *sensu* Hill 1953, Seiler 1974b and Burrows & Smith 2003.)
[51][But see text.]
[52][According to Saban 1968 in humans the sphincter colli profundus is replaced by the 'fascia parotideo-massetericus'.]
[53](Deep cervical panniculus *sensu* Greene 1935; see platysma cervicale.)
[54][See cervicalis transversus.]
[55](Part or totality of auriculolabialis *sensu* Greene 1935; zygomatico-labialis superficialis and/or auriculolabialis inferior *sensu* Jouffroy & Saban 1971.)
[56](Auriculolabialis inferior or zygomatico-labialis *sensu* Jouffroy & Saban 1971, Le Gros Clark 1926 and Lightoller 1934.)
[57](Auriculolabialis inferior or zygomatico-labialis *sensu* Ruge 1885, Lightoller 1934, Jouffroy & Saban 1971 and Burrows & Smith 2003; zygomaticus *sensu* Seiler 1974b.)
[58](Zygomaticus *sensu* Lightoller 1928a; part of zygomatico-orbital mass *sensu* Huber 1930b, 1931, 1933; zygomaticus inferior *sensu* Seiler 1971d.)
[59](Part or totality of zygomatico-labialis *sensu* Edgeworth 1935; zygomaticus inferior *sensu* Seiler 1971d.)
[60](Orbito-labialis *sensu* Sullivan & Osgood 1925; part of malaris or orbiculo-labialis *sensu* Lightoller 1928a and of zygomatic mass *sensu* Sonntag 1924a) [partially blended with zygomaticus minor.]
[61](Zygomaticus *sensu* Sullivan & Osgood 1925 and Raven 1950); part of zygomaticus *sensu* Edgeworth 1935.)
[62](Zygomaticus + part or totality of orbito-labialis *sensu* Sullivan & Osgood 1925; zygomaticus *sensu* Miller 1952.)
[63](Caput zygomaticus of the quadratus labii superioris *sensu* Jouffroy & Saban 1971.)
[64](Zygomaticus *sensu* Greene 1935; zygomatico-labialis profundus and/or auriculolabialis superior *sensu* Jouffroy & Saban 1971.)
[65](Auriculolabialis superior *sensu* Jouffroy & Saban 1971, Le Gros Clark 1926 and Lightoller 1934.)

© 2009 The Authors
Journal compilation © 2009 Anatomical Society of Great Britain and Ireland

[66](Auriculolabialis superior or zygomatico-labialis *sensu* Ruge 1885, Lightoller 1934, Jouffroy & Saban 1971 and Burrows & Smith 2003; auriculolabialis *sensu* Seiler 1974b.)
[67](Pars peripheralis or postorbicularis, or muscle malaris, *sensu* Lightoller 1928a, Shibata 1959 and Jouffroy & Saban 1971; part of zygomatico-orbital mass *sensu* Huber 1930b, 1931, 1933; zygomaticus superior *sensu* Seiler 1971d.)
[68](Zygomaticus superior *sensu* Seiler 1971d.)
[69](Orbito-malaris *sensu* Sullivan & Osgood 1925; part of malaris or orbiculo-labialis *sensu* Lightoller 1928a and of zygomatic mass *sensu* Sonntag 1924a) [see zygomaticus minor].
[70](Orbicularis labialis *sensu* Sullivan & Osgood 1925; part of zygomaticus *sensu* Edgeworth 1935; caput zygomaticum of quadratus labii superioris *sensu* Raven 1950.)
[71](Zygomatic head of quadratus labii superioris *sensu* Miller 1952.)
[72](Frontalis *sensu* Greene 1935.)
[73](Part of epicranius *sensu* Raven 1950.)
[74](Part of occipito-frontalis *sensu* Owen 1830–1831, MacAlister 1871 and Sutton 1883.)
[75](Venter frontalis of occipitofrontalis *sensu* Terminologia Anatomica 1998.)
[76](Auriculo-orbitalis or orbito-auricularis *sensu* Lightoller 1934; it might correspond to *Tupaia*'s attrahens aurem *sensu* Le Gros Clark 1924 and/or to the *Ptilocercus*' scutularis + portio transiens *sensu* Le Gros Clark 1926.)
[77](Attrahens aurem *sensu* Murie & Mivart 1872; orbitoauricularis *sensu* Lightoller 1934 and Burrows & Smith 2003; orbitotemporalis + auricularis anterior *sensu* Seiler 1974b) [probably not differentiated into auriculo-orbitalis and auricularis anterior but see text].
[78](Orbiculo-auricularis + auricularis anterior *sensu* Waller et al. 2008b; see auricularis anterior.)
[79](Orbito-auricularis *sensu* Huber 1930b, 1931.)
[80](Orbitotemporalis or orbitoauricularis *sensu* Lightoller 1928a, Jouffroy & Saban 1971 and Winkler 1989.)
[81](Deep portion of auricularis anterior et superior *sensu* Raven 1950; probably corresponds to part of the auricularis anterior *sensu* Ruge 1887b and Gibbs 1999) [Raven 1950 shows, in his plates 8 and 9, a gorilla with a 'deep portion' of the 'auricularis anterior et superior' lying deep to the auricularis anterior and auricularis superior; as the auricularis anterior is thus present as a separate muscle, this 'deep' structure corresponds to the temporoparietalis *sensu* the present work].
[82](Auricularis anterior *sensu* Gratiolet & Alix 1866, Virchow 1915, Sonntag 1923, 1924b, Miller 1952, Swindler & Wood 1973, Gibbs 1999 and Burrows et al. 2006; attrahens aurem *sensu* MacAlister 1871; see text.)
[83][Contrary to *Ptilocercus*, *Tupaia* probably only has an auriculo-orbitalis *sensu* Lightoller 1934, i.e. it does not have a separate temporoparietalis and a separate auricularis anterior.]
[84][In human anatomy attrahens aurem is a synonym of auricularis anterior; however, the attrahens aurem *sensu* Burrows & Smith 2003 possibly corresponds to part of the occipitalis (namely the 'cervico-auriculo-occipitalis' part) or of the auricularis posterior *sensu* the present work or to the auricularis inferior *sensu* Seiler 1974b.]
[85][Waller et al. 2008b describe both an 'orbito-auricularis' and an auricularis anterior in *Macaca mulatta*, which would correspond to the temporoparietalis and auricularis anterior *sensu* this work, respectively; however, in the specimens dissected by authors such as Lightoller 1928a and Huber 1930b, 1931, 1933, as well as in specimens such as HU-ANA M01, the auricularis anterior does not seem to be present as an independent muscle].
[86](Auricularis anterior inferior *sensu* Raven 1950.)
[87][See text.]
[88][In human anatomy attolens aurem is synonym of auricularis superior; the attolens aurem *sensu* Murie & Mivart 1872 and Burrows & Smith 2003 probably corresponds to the auricularis superior *sensu* the present work.]
[89](Auricularis superior et anterior *sensu* Huber 1930b, 1931, 1933.)
[90](Auricularis anterior superior *sensu* Raven 1950.)
[91](Temporoparietalis *sensu* Virchow 1915.)
[92](Orbicularis palpebrarum *sensu* Murie & Mivart 1872.)
[93](Corresponds to the orbicularis oculi excluding the pars peripheralis or postorbicularis – or muscle malaris – *sensu* Lightoller 1928a, Shibata 1959 and Jouffroy & Saban 1971.)
[94][Probably not present as an independent muscle; it might correspond to the thin ventromedial group of fibers of the auriculolabialis that apparently runs from the orbicular region to the zygomatic arch in the *Eulemur macaco* specimen shown in Fig. 4 of Lightoller 1934; see Diogo 2009.]
[95][As stressed by Jouffroy & Saban 1971 and Seiler 1974b, the depressor supercilii and corrugator supercilii are present in strepsirhines such as *Lepilemur*, *Eulemur* and *Daubentonia*.]
[96](Depressor capitis *sensu* Lightoller 1928a) [the depressor supercilii is present as an independent muscle in the *Macaca mulatta* specimens dissected by authors such as Huber 1930b, 1931, 1933, Shibata 1959, Jouffroy & Saban 1971, Seiler 1971c and by one of us (R.D.)].
[97](Depressor capitis *sensu* Lightoller 1928a, retractor anguli oculi medialis *sensu* Jouffroy & Saban 1971.)
[98](Superciliaris *sensu* Jouffroy & Saban 1971.)

© 2009 The Authors
Journal compilation © 2009 Anatomical Society of Great Britain and Ireland

[99](Levator labii superioris *sensu* Parsons 1898 and Greene 1935; pars jugularis of superficial maxillo-naso-labialis *sensu* Lightoller 1940b.)
[100](Levator labii superioris *sensu* Le Gros Clark 1924) [not described by Le Gros Clark, 1926 but his Fig. 49 suggests that it may also be present in *Ptilocercus*.]
[101](Part of nasal muscles *sensu* Murie & Mivart 1872; levator labii superior + levator labii alaeque nasi *sensu* Seiler 1974b; levator labii *sensu* Burrows & Smith 2003) [probably not differentiated into levator labii superioris and levator labii superioris alaeque nasi, but see text].
[102](Caput infraorbitalis of muscle quadratus labii superioris of labiorum superficiales, or maxillo-naso-labialis, *sensu* Lightoller 1928a; levator labii superioris proprius *sensu* Huber 1930b, 1931, 1933; caput infraorbitalis of muscle quadratus labii superioris, maxillo-labialis or infraorbitalis *sensu* Shibata 1959.)
[103](Maxillo-naso-labialis *sensu* Huber 1930b, 1931; part of naso-labialis *sensu* Edgeworth 1935.)
[104](Part or totality of the maxillo-labialis *sensu* Sullivan & Osgood 1925 and of the angular head of the quadratus labii superioris *sensu* Lightoller 1928a and Jouffroy & Saban 1971; part of the labiorum superficialis *sensu* Lightoller 1928a.)
[105](Part or totality of maxillo-labialis *sensu* Edgeworth 1935; caput infraorbitale of quadratus labii superioris *sensu* Jouffroy 1971.)
[106](Part of levator labii superioris *sensu* MacAlister 1871; part or totality of maxillo-labialis *sensu* Edgeworth 1935; infraorbital head of quadratus labii superioris *sensu* Miller 1952.)
[107](Caput angulare musculi quadrati labii superioris *sensu* Jouffroy & Saban 1971) [the developmental study of Gasser 1967 suggests that in modern humans the levator labii superioris and levator labii superioris alaeque nasi appear ontogenetically in the orbital, and not in the oral, region of the face].
[108](Caput angulare of muscle quadratus labii superioris of labiorum superficiales *sensu* Lightoller 1928a; part of nasolabialis *sensu* Huber 1930b, 1931, 1933; caput angulare of muscle quadratus labii superioris, levator alae nasi or angularis *sensu* Shibata 1959) [see *Homo*].
[109](Part of naso-labialis *sensu* Edgeworth 1935.)
[110](Part or totality of the maxillo-labialis *sensu* Sullivan & Osgood 1925 and of the angular head of the quadratus labii superioris *sensu* Lightoller 1928a and Jouffroy & Saban 1971; part of the labiorum superficialis *sensu* Lightoller 1928a) [see *Homo*].
[111](Part or totality of naso-labialis *sensu* Edgeworth 1935; caput angulare of quadratus labii superioris *sensu* Jouffroy 1971.)
[112](Part of levator labii superioris *sensu* MacAlister 1871; angular head of quadratus labii superioris *sensu* Miller 1952) [see *Homo*].
[113][Seiler 1971d states that an independent muscle 'infraorbitalis' may be present in catarrhines such as *Macaca*, *Pongo*, *Pan* and *Homo*; however, in more recent publications the 'infraorbitalis' is usually considered to be part of the levator labii superioris alaeque nasi; see, e.g. Terminologia Anatomica 1998 and Diogo et al. 2008.]
[114](Nasolabialis superficialis *sensu* Ryan 1989) [not described by Greene 1935 but seems to be present in the rats dissected by us, see also, e.g., Ryan 1989; as explained by Jouffory & Saban 1971, the procerus is also present in other non-primate mammals and the muscle of rats and other mammals seems to be homologous to the procerus of primates].
[115][As stressed by Lightoller 1934, the procerus is not present as an independent muscle in lemurs.]
[116](Part of naso-labialis *sensu* Huber 1930b, 1931, 1933; depressor glabellae *sensu* Shibata 1959; procerus plus part or totality of depressor glabellae *sensu* Seiler 1971c.)
[117](Procerus nasi or depressor glabellae *sensu* Huber 1930b, 1931; procerus + part or totality of depressor glabellae *sensu* Seiler 1971c.)
[118](Procerus nasi or depressor glabellae *sensu* Huber 1930b, 1931; procerus plus part or totality of depressor glabellae *sensu* Seiler 1971c.)
[119](Pyramidalis *sensu* Chudzinski 1885; procerus nasi *sensu* Edgeworth 1935 and Raven 1950.)
[120](Pyramidalis nasi *sensu* Sutton 1883 and Sonntag 1923; depressor glabellae *sensu* Virchow 1915; naso-labialis superficialis, pyramidalis narium, frontalis pars per dorsum nasi ducta, dorsalis narium, retractor naso-labialis, levator naso-labialis vestibularis *sensu* Jouffroy & Saban 1971.)
[121][Seiler 1971c describes the 'depressor glabellae' as an independent muscle in the Cercopithecinae except *Macaca maura* and *Erythrocebus*, the Colobinae *Presbytis entellus* and *Presbytis melalophos*, and the hominoids except *Gorilla* and adult *Pan*; however, in recent publications the 'depressor glabellae' is usually considered to be part of the procerus; see, e.g. Terminologia Anatomica 1998 and Diogo et al. 2008.]
[122](The buccinatorius *sensu* Lightoller 1942 corresponds to the sphincter bursae buccalis *sensu* Huber 1930a; see Diogo et al. 2008.)
[123][Not described by Greene 1935 but it is clearly present in the rats dissected by us, being in fact subdivided into various sections; see also, e.g. Ryan 1989.]
[124][Not described by Le Gros Clark 1924 but it is clearly present in the *Tupaia* specimens we dissected; it is also present in *Ptilocercus*; see, e.g. Le Gros Clark 1926.]
[125](Dilatator naris *sensu* Greene 1935 and Peterka 1936) [we prefer to use the name dilatator nasi because the name dilatator naris is often used to designate the pars alaris of the nasalis; see Diogo et al. 2008].
[126](Probably incorporates the maxillo-labialis and naso-labiais profundus *sensu* Jouffroy & Saban 1971 and Ryan 1989) [not described by Greene 1935 but it is clearly present in the rats dissected by us; see also, e.g. Ryan 1989].
[127](Maxillo-nasalis *sensu* Jouffroy & Saban 1971) [might correspond to the dilator naris, zygomatici and/or erector vibrissae *sensu* Le Gros Clark 1924, and thus might possibly be included in the orbicularis oculi (*sensu* Le Gros Clark 1926) of *Ptilocercus*].
[128](Part of nasal muscles *sensu* Murie & Mivart 1872; nasalis *sensu* Seiler 1974b and Burrows & Smith 2003.)

© 2009 The Authors
Journal compilation © 2009 Anatomical Society of Great Britain and Ireland

[129][Hill 1974 states that Seiler 1970 wrote that the nasalis is not present as a distinct muscle in *Macaca* and *Cynopithecus* but occurs in *Erythrocebus* and *Cercopithecus*; however in Fig. 4521 of Seiler 1971 this author does show a nasalis in a specimen of *Macaca mulatta*; this muscle was also found in the *Macaca* specimens dissected by authors such as Lightoller 1928a, Shibata 1959, Waller et al. 2008b and by us: see Fig. 5.]
[130](Myrtiformi + transverse muscles *sensu* Gratiolet & Alix 1866; part of naso-labialis *sensu* Miller 1952.)
[131](Naso-labialis profundus pars anterior *sensu* Saban 1968.)
[132][Seems to be absent as a independent muscle; the fibers of the depressor septi nasi of the other primates listed in this Table might correspond to part of the fibers of the labialis superioris profundus *sensu* Seiler 1974b.]
[133](Labii profundus superioris or pars perpendicularis of the muscle malaris or of the muscle nasalis *sensu* Shibata 1959 and Jouffroy & Saban 1971; see text.)
[134][It is sometimes mentioned in the literature that non-human hominoids do not have a distinct depressor septi nasi; however, as described by Raven 1950 and Seiler 1971a,b,c,d, 1979a,b and corroborated by our own dissections, these primates do often have such a muscle.]
[135](Pars perpendicularis of nasalis or labii profundus superior *sensu* Lightoller 1928a) [see *Hylobates*].
[136][See *Hylobates*.]
[137](Part of naso-labialis *sensu* Miller 1952) [see *Hylobates*].
[138](Naso-labialis profundus pars mediana *sensu* Saban 1968.)
[139](Levator anguli oris or caninus *sensu* Lightoller 1934; bucco-naso-labialis *sensu* Ryan 1986; buccinatorius *sensu* Greene 1935 and Bryant 1945; pars profunda of maxillo-naso-labialis *sensu* Lightoller 1940b.)
[140](Levator anguli oris *sensu* Le Gros Clark 1926; incisivus superior + caninus *sensu* Lightoller 1934) [as noted by Lightoller 1934, it is deeply mixed with the orbicularis oris].
[141](Part of nasal muscles *sensu* Murie & Mivart 1872; caninus *sensu* Lightoller 1934; maxillolabialis *sensu* Hill 1953 and Burrows & Smith 2003; caninus and possibly at least part of labialis superioris profundus *sensu* Seiler 1974b.)
[142](Caninus or pars canina of orbicularis oris *sensu* Lightoller 1928a, Huber 1930b, 1931, 1933, Shibata 1959, Seiler 1970, 1971c,d and Hill 1974; levator anguli oris *sensu* Shibata 1959 and Jouffroy & Saban 1971.)
[143](Caninus *sensu* Huber 1930b, 1931.)
[144](Caninus *sensu* Lightoller 1928a; maxillo-labialis, depressor labi communis or pyramidalis menti *sensu* Jouffroy & Saban 1971.)
[145](Caninus *sensu* Raven 1950.)
[146](Caninus *sensu* Gratiolet & Alix 1866 and Miller 1952.)
[147](Levator anguli oris *sensu* Terminologia Anatomica 1998 and Netter 2006) [the study of Gasser 1967 of human development supports the claim that the levator anguli oris facialis, orbicularis oris, depressor labii inferioris, depressor anguli oris and mentalis have a common ontogenetic origin, being derived from his 'mandibular lamina'; see also, e.g. Sullivan & Osgood 1927 and Jouffroy & Saban 1971].
[148](Plicae anguli oris *sensu* Huber 1930a.)
[149](Might include the labialis inferioris profundus and possibly the labialis superioris profundus *sensu* Seiler 1974b; see levator anguli oris facialis.)
[150](Orbicularis oris plus incisivus superior – or oringo maxillaris orbicularis oris – and incisivus inferior – or oringo mandibularis orbicularis oris –*sensu* Lightoller 1928a, Shibata 1959 and Jouffroy & Saban 1971; orbicularis oris plus part or totality of cuspidator oris and subnasalis *sensu* Seiler 1970, 1971c,d.)
[151](Orbicularis oris plus part or totality of cuspidator oris and subnasalis *sensu* Seiler 1970, 1971c,d.)
[152](Orbicularis oris plus incisivus superior and incisivus inferior *sensu* Lightoller 1928a; orbicularis oris plus part or totality of cuspidator oris and subnasalis *sensu* Seiler 1970, 1971c,d.)
[153](Orbicularis oris plus part or totality of cuspidator oris *sensu* Seiler 1970, 1971c,d.)
[154](Orbicularis oris plus rectus labii inferioris and rectus labii superioris *sensu* Huber 1930b, 1931; orbicularis oris plus part or totality of cuspidator oris and subnasalis *sensu* Seiler 1970, 1971c,d.)
[155](Orbicularis oris plus rectus labii inferioris and rectus labii superioris and incisivus labii inferioris and incisivus labii superioris *sensu* Huber 1930b, 1931; orbicularis oris plus part or totality of cuspidator oris *sensu* Seiler 1970, 1971c,d.)
[156][But see text.]
[157][See text.]
[158](Quadratus labii inferioris *sensu* Sullivan & Osgood 1925; part of labiorum superficialis *sensu* Lightoller 1928a, buccinatorius pars mandibularis, quadratus menti or mento-labialis *sensu* Jouffroy & Saban 1971.)
[159](Quadratus labii inferioris *sensu* Raven 1950.)
[160](Quadratus labii inferioris *sensu* Sonntag 1923, 1924b, Miller 1952 and Jouffroy & Saban 1971.)
[161](Quadratus labii inferioris or carré du menton *sensu* Loth 1931) [see levator anguli oris facialis].

© 2009 The Authors
Journal compilation © 2009 Anatomical Society of Great Britain and Ireland

of homology for the facial muscles discussed in the present work. As stressed by Diogo (2007, 2008, 2009), one of the major problems that researchers face when they compare the muscles of modern humans with those of other primates and with non-primate mammals is the use of different names by different authors to designate the same muscle in the members of different clades, and even of the same clade. In order to reconcile these different nomenclatures we propose a unifying nomenclature for the facial muscles of the Mammalia as a whole that takes into account the data compiled in Table 1 and discussed in the text.

Materials and methods

The phylogenetic framework used in the present study, and specifically in the comparisons between the facial musculature of the genera set out in Table 1 and shown in Figs 2–9, is shown in Fig. 1. We dissected the facial muscles of various non-primate and primate mammals and were careful to include in Table 1: (1) a member of the most basal extant mammalian clade, the monotremes (*Ornithorhynchus anatinus*, or 'platypus'); (2) a member of the rodents, the Norwegian rat (*Rattus norvegicus*), because rodents and lagomorphs are included in the clade Glires, which is considered to be the sister-group of the clade Euarchonta (Fig. 1); (3) a member of the tree-shrews (*Tupaia* sp.), i.e. one of the two groups that are now considered to be the closest living relatives of primates (the other group being the colugos, or 'flying lemurs'; see Fig. 1); (4) a non-anthropoid primate taxon, the strepsirhine *Lepilemur ruficaudatus*; (5) a monkey, the cercopithecoid *Macaca mulatta*; and (6–10) members of each of the five major extant hominoid groups, i.e. *Hylobates lar* (Hylobatidae), *Pongo pygmaeus* (Ponginae), *Gorilla gorilla* (Gorillini), *Pan troglodytes* (Panini) and

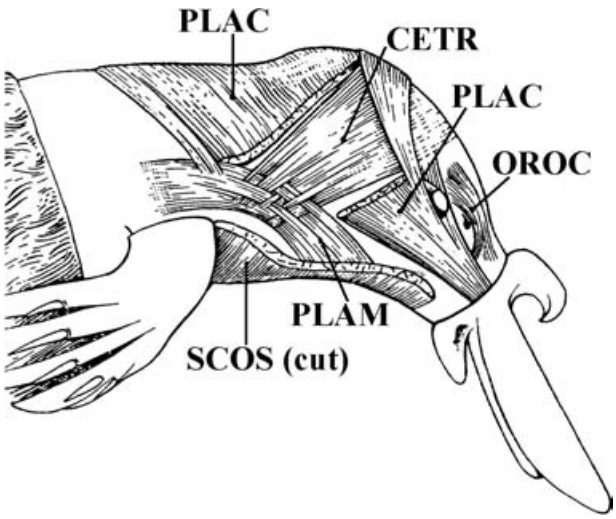

Fig. 2 *Ornithorhynchus anatinus* (Monotremata): lateral view of the deep facial musculature of an adult specimen. Muscles such as the interhyoideus profundus, buccinatorius, orbicularis oris and mentalis are not shown [modified from Lightoller (1942) and Saban (1971); the nomenclature of the structures illustrated follows that used in the present work; anterior is to the right]. CETR, cervicalis transversus; OROC, orbicularis oculi; PLAC, platysma cervicale; PLAM, platysma myoides; SCOS, sphincter colli superficialis.

[162](Triangularis *sensu* Lightoller 1928a, Huber 1930b, 1931, 1933, Shibata 1959 and Hill 1974) [according to Shibata 1959 the depressor anguli oris is most frequently absent in specimens of the species *Macaca cyclopis*].
[163](Triangularis *sensu* Huber 1930b, 1931 and Edgeworth 1935.)
[164](Triangularis *sensu sensu* Sonntag 1924a, Lightoller 1928a and Edgeworth 1935.)
[165](Triangularis *sensu* Chudzinski 1885, Edgeworth 1935 and Raven 1950.)
[166](Triangularis *sensu* Gratiolet & Alix 1866, Sonntag 1923, 1924b, Edgeworth 1935 and Miller 1952.)
[167][See levator anguli oris facialis.]
[168][Present in the platypus, but not in echidna, according to, e.g. Lightoller 1942 and Saban 1971.]
[169](Labiorum profundi inferioris *sensu* Lightoller 1934.)
[170](Labiorum profundi inferioris *sensu* Lightoller 1934.)
[171](Labii profundus inferioris *sensu* Lightoller 1928a, Shibata 1959 and Jouffroy & Saban 1971; labii inferioris profundus *sensu* Hill 1974.)
[172](Labii profundus inferior *sensu* Lightoller 1928a; levator labii inferioris, levator menti, incisivus labii inferioris or incisivus mandibularis *sensu* Jouffroy & Saban 1971.)
[173](Muscle de la houpe du menton *sensu* Loth 1931) [see levator anguli oris facialis].

© 2009 The Authors
Journal compilation © 2009 Anatomical Society of Great Britain and Ireland

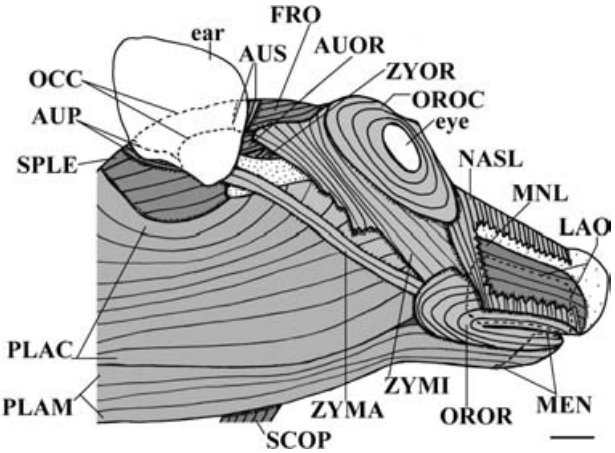

Fig. 3 *Cynocephalus volans* (Dermoptera): lateral view of the facial muscles of an adult specimen dissected in the course of this investigation (USNM, 144941), the splenius capitis is also shown. Anteriorly, the nasolabialis was partially cut in order to show the maxillo-naso-labialis [modified from Diogo (2009); the nomenclature of the structures illustrated basically follows that used in the present work, anterior is to the right; the scale bar shown on the right, at the bottom, corresponds to 5 mm]. AUOR, auriculo-orbitalis; AUP, auricularis posterior; AUS, auricularis superior; FRO, frontalis; LAO, levator anguli oris facialis; MEN, mentalis; MNL, maxillo-naso-labialis; NASL, naso-labialis; OCC, occipitalis; OROC, orbicularis oculi; OROR, orbicularis oris; PLAC, platysma cervicale; PLAM, platysma myoides; SCOP, sphincter colli profundus; SPLE, splenius capitis; ZYMA, zygomaticus major; ZYMI, zygomaticus minor; ZYOR, zygomatico-orbitalis.

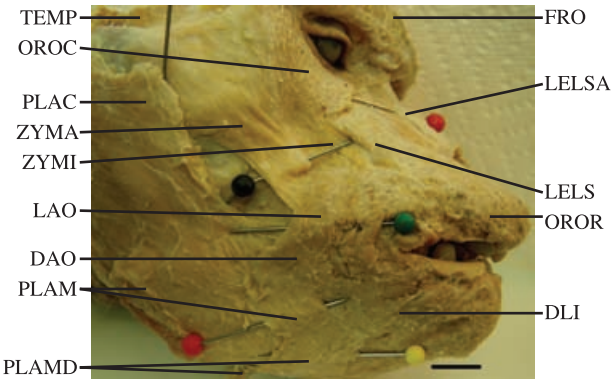

Fig. 4 *Macaca mulatta* (Primates): lateral view of the facial muscles of an adult specimen (HU-ANA, M01) dissected in the course of this investigation, the temporalis is also shown [anterior is to the right; the scale bar shown on the right, at the bottom, corresponds to 1 cm]. DAO, depressor anguli oris; DLI, depressor labii inferioris; FRO, frontalis; LAO, levator anguli oris facialis; LELS, levator labii superioris; LELSA, levator labii superioris alaeque nasi; OROC, orbicularis occuli; OROR, orbicularis oris; PLAC, platysma cervicale; PLAM, platysma myoides; PLAMD, decussating fibers of platysma myoides; TEMP, temporalis; ZYMA, zygomaticus major; ZYMI, zygomaticus minor.

Homo sapiens (Hominini). The dissected specimens are from the Colección Mamíferos Lillo of the Universidad Nacional de Tucumán (CML), the Primate Foundation of Arizona (PFA), the Department of Anatomy (GWU-ANA) and the Department of Anthropology (GWU-ANT) of the George Washington University, the Department

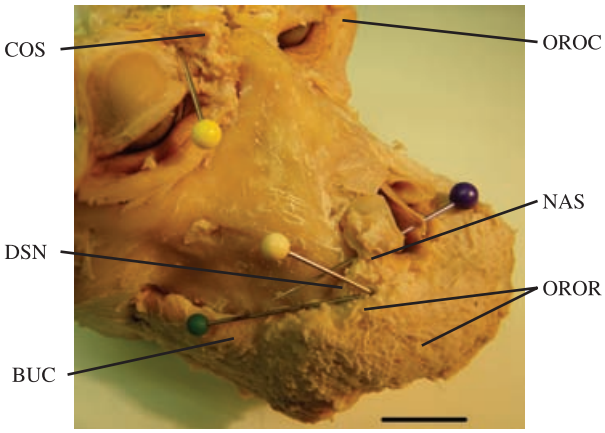

Fig. 5 *Macaca mulatta* (Primates): anterolateral view of the facial muscles of an adult specimen (HU-ANA, M01) dissected in the course of this investigation [anterior is to the right; the scale bar shown on the right, at the bottom, corresponds to 1 cm]. BUC, buccinatorius; COS, corrugator supercilii; DSN, depressor septi nasi; NAS, nasalis; OROC, orbicularis occuli; OROR, orbicularis oris.

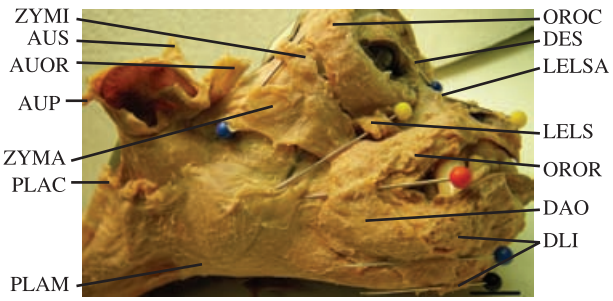

Fig. 6 *Hylobates lar* (Primates): lateral view of the facial muscles of an adult specimen (HU-ANA, H01) dissected in the course of this investigation [anterior is to the right; the scale bar shown on the right, at the bottom, corresponds to 1 cm]. AUOR, auriculo-orbitalis; AUP, auricularis posterior; AUS, auricularis superior; DAO, depressor anguli oris; DES, depressor supercilii; DLI, depressor labii inferioris; LELS, levator labii superioris; LELSA, levator labii superioris alaeque nasi; OROC, orbicularis occuli; OROR, orbicularis oris; PLAC, platysma cervicale; PLAM, platysma myoides; ZYMA, zygomaticus major; ZYMI, zygomaticus minor.

of Anatomy of Howard University (HU-ANA), the Smithsonian Institution's National Museum of Natural History (USNM), the Cleveland Metroparks Zoo (CMZ), the Yerkes National Primate Research Center (YNPRC), and the Duke Lemur Center (DLC). The list of specimens examined is given in Appendix 1; the number of specimens dissected is followed by an abbreviation that refers to the state of the specimen (alc, alcohol fixed; fre, fresh; for, formalin embalmed). In our dissections, other than their color, there were no notable differences regarding the attachments, overall configuration and general appearance of the muscles of fresh, alcohol-fixed and formalin-embalmed specimens. Regarding the nomenclature for the facial muscles, we use a system that takes into account the names used by researchers working with non-human primates and non-primate mammals (e.g. Jouffroy & Saban, 1971) and those employed by human anatomists (e.g. Terminologia Anatomica, 1998) (see below). When we cite studies that use a nomenclature

© 2009 The Authors
Journal compilation © 2009 Anatomical Society of Great Britain and Ireland

Fig. 7 *Hylobates lar* (Primates): anterolateral view of the facial muscles of an adult specimen (HU-ANA, H01) dissected in the course of this investigation [anterior is to the right; the scale bar shown on the right, at the bottom, corresponds to 1 cm]. BUC, buccinatorius; DES, depressor supercilii; DSN, depressor septi nasi; LAO, levator anguli oris facialis; LELS, levator labii superioris; LELSA, levator labii superioris alaeque nasi; MEN, mentalis; NAS, nasalis; OROC, orbicularis occuli; OROR, orbicularis oris.



Fig. 9 *Pan troglodytes* (Primates): lateral view of the facial muscles of an infant specimen (HU-ANA, C104) dissected in the course of this investigation [anterior is to the right; the scale bar shown on the right, at the bottom, corresponds to 1 cm]. DAO, depressor anguli oris; DES, depressor supercilii; DLI, depressor labii inferioris; FRO, frontalis; LELS, levator labii superioris; LELSA, levator labii superioris alaeque nasi; OROC, orbicularis occuli; OROR, orbicularis oris; PLAM, platysma myoides; ZYMA, zygomaticus major; ZYMI, zygomaticus minor.

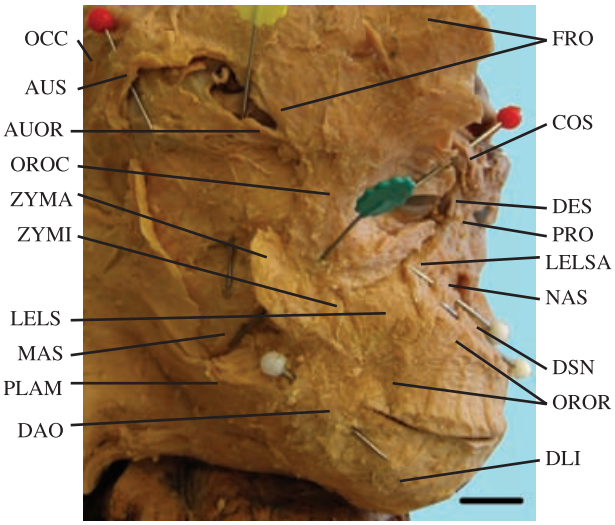

Fig. 8 *Pongo pygmaeus* (Primates): lateral view of the facial muscles of a neonatal specimen (HU-ANA, O01) dissected in the course of this investigation, the masseter is also shown [anterior is to the right; the scale bar shown on the right, at the bottom, corresponds to 1 cm]. AUOR, auriculo-orbitalis; AUS, auricularis superior; COS, corrugator supercilii; DAO, depressor anguli oris; DES, depressor supercilii; DSN, depressor septi nasi; DLI, depressor labii inferioris; FRO, frontalis; LELS, levator labii superioris; LELSA, levator labii superioris alaeque nasi; MAS, masseter; NAS, nasalis; OCC, occipitalis; OROC, orbicularis occuli; OROR, orbicularis oris; PLAM, platysma myoides; PRO, procerus; ZYMA, zygomaticus major; ZYMI, zygomaticus minor.

that differs from that proposed here, the respective synonymy is given in Table 1. The muscles listed in Table 1 are those that are usually present in adults of the respective taxa; we do not list all of the muscles that occasionally appear as variants in the members of these taxa (e.g. although a few modern humans may have a platysma cervicale, in the vast majority of cases this muscle is lacking; see Diogo et al. 2008). In Table 1, the muscles are listed in the order used by Diogo et al. (2008), which takes into account the homologies and evolutionary history of the hyoid muscles in the sarcopterygian clade as a whole; as done by those authors, we list the extrinsic musculature of the ear (which includes muscles such as, e.g. the obliquus auriculae, transversus auriculae, helicis, tragicus, depressor helicis and/or antitragicus, among others; see Jouffroy & Saban, 1971; Table 1) as a single group. When we use the terms anterior, posterior, dorsal and ventral, we do so in the sense that the terms are used for pronograde tetrapods (e.g. in mammals the eye, and thus the orbicularis oculi, is usually anterior to the ear, and thus to the auricularis superior, and dorsal to the mandible, and thus to the orbicularis oris). Although there is obviously some subjectivity concerning the identification of separate muscles, we followed as strictly as possible the criteria of Edgeworth (1935) for analysing the evidence acquired by others and ourselves, which include criteria such as, e.g. the degree of separation of the fibers, differences in origin and/or insertion, differences in function, orientation of the fibers and/or differences in innervation, among others (see Diogo, 2007, 2008; Diogo et al. 2008).

The definition of homology and its use in systematics and comparative anatomy has been discussed by several authors (e.g. Patterson, 1988; De Pinna, 1991; Agnarsson & Coddington, 2007). The simplest meaning of homology is equivalence of parts (e.g. De Pinna, 1991). In the present work we follow the phylogenetic definition of homology, as proposed by Patterson (1988): homology is equal to synapomorphy. Therefore, following De Pinna (1991), we recognize two main types of muscular homology. 'Primary homology' hypotheses are conjectures or hypotheses about the common origin of muscular characters that are established after a careful analysis of criteria such as function, topology and ontogeny (i.e. after the so-called test of similarity). In this study we follow the

© 2009 The Authors
Journal compilation © 2009 Anatomical Society of Great Britain and Ireland

same methodology that we have employed and carefully explained in previous works (e.g. Diogo, 2007, 2008; Diogo et al. 2008, 2009) and thus take into account all of the lines of evidence obtained either from our dissections or gleaned from the literature in order to formulate such 'primary homology' hypotheses (e.g. the innervation of the muscles, their relationships with other muscular structures, their relationships with hard tissues, the configuration/orientation of their fibers, their development, their function, etc.). This is because, as pointed out by Edgeworth (1935), no single criterion is sufficient. For instance, although the innervation of a muscle generally remains constant and corresponds to its segment of origin, there are cases in which the same muscle has different innervations in different taxa (e.g. although wholly of mandibular origin, the intermandibularis of dipnoans is innervated by the Vth and/or VII nerve; Edgeworth, 1935). Also, there are cases in which the same muscle may be ontogenetically derived from different regions and/or segments of the body in different taxa (e.g. the trapezius of *Ornithorhynchus* is derived from the third branchial muscle-plate, that of *Talusia* from the second branchial muscle-plate and that of *Sus* from the first branchial muscle-plate; Edgeworth, 1935). As noted by Edgeworth (1935, p. 224), there are also cases in which 'an old structure or group of structures may be transformed' (e.g. the levator hyoideus 'may be transformed, either partially or wholly, into a depressor mandibulae').

Following De Pinna (1991), the 'primary homology' hypotheses have, however, to pass the second, or 'hard', test of homology, i.e. the test of phylogenetic conjunction and congruence (agreement in supporting the same phylogenetic relationships), before they can actually be considered as solid hypotheses of homology, i.e. as 'secondary homology' hypotheses. The important point is, thus, that under the phylogenetic definition of homology it is the test of phylogenetic conjunction and congruence that ultimately determines if a hypothesis can, or cannot, be considered as a solid hypothesis of homology. Therefore, if for instance a muscle A of a taxon X and a muscle B of a taxon Y have a similar innervation, function, topology and development but the phylogenetic data available strongly support the idea that muscles A and B were the result of convergent evolution [i.e. that they were acquired independently in evolution and do not correspond to a structure that was present in the last common ancestor (LCA) of A and B], then the phylogenetic criterion has preponderance over the other criteria. As explained above, in the specific case of the present work the phylogenetic framework that we use to investigate and discuss the evolution and homologies of the facial musculature of the taxa listed in Table 1 is shown in Fig. 1. Therefore, following the methodology explained above, if for example an analysis of the data provided by some lines of evidence (e.g. innervation, function and relationships with other muscular and hard structures) indicates that muscles C and D could be homologous ('primary homology' hypothesis) but within all mammals muscle C is only present in monotremes and muscle D in modern humans, then we would consider that muscles C and D were probably independently acquired in monotremes and modern humans, respectively, i.e. that these muscles are probably not homologous (i.e. the 'primary homology' hypothesis did not pass the 'hard' test of homology, that is the test of phylogenetic conjunction and congruence; see Diogo, 2007, 2008, and Diogo et al. 2008, 2009, for more details on this subject). Therefore, the hypotheses of homology that are shown in Table 1 are hypotheses that are phylogenetically congruent with the scenario shown in the cladogram of Fig. 1, i.e. they are 'secondary homology' hypotheses *sensu* De Pinna (1991).

Results and discussion

The results of our observations and comparisons are summarized in Table 1, and are also partially shown in Figs 2–9. In the sections that follow we comment on the information presented in Table 1, paying special attention to some topics that remain particularly controversial among comparative morphologists.

The origin and plesiomorphic condition of the primate facial muscles

As explained in the recent review of Diogo et al. (2008), the mammalian facial muscles derive from the ventral hyoid muscle interhyoideus, and probably also from at least some dorso-medial hyoid muscles (e.g. cervico-mandibularis) of other tetrapods. Monotremes such as the platypus (*Ornithorhynchus*; Fig. 1) have only 10 distinct facial muscles (not including the extrinsic muscles of the ear), i.e. a platysma cervicale, platysma myoides, interhyoideus profundus, sphincter colli superficialis, cervicalis transversus, orbicularis oculi, naso-labialis, buccinatorius, orbicularis oris and mentalis (Diogo et al. 2008; Diogo, 2009; see Table 1 and Fig. 2).

Rodents such as rats (Fig. 1) have up to 20 distinct facial muscles (Diogo et al. 2008; see Table 1). There is still some controversy regarding certain homologies between the facial muscles of monotremes and of other mammals. However, there is strong supporting evidence for the hypothesis that the occipitalis + auricularis posterior, procerus and dilatator nasi + maxillo-naso-labialis + levator anguli oris facialis of rats correspond to part of the platysma cervicale, naso-labialis and orbicularis oris of monotremes, respectively (Diogo et al. 2008; Table 1). The sternofacialis, interscutularis, zygomaticus major, zygomaticus minor and orbito-termporo-auricularis of rats probably derive from the sphincter colli profundus but it is possible that at least some of the former muscles derive from the platysma cervicale and/or platysma myoides (Diogo et al. 2008; Table 1). The therian mandibulo-auricularis is a deep muscle that is probably derived from the platysma cervicale but it is possible that it is derived, in fact, from deep dorsomedial hyoid muscles such as, e.g. the styloideus (which, together with its derivatives stylohyoideus and digastricus posterior and with the stapedius, are among the few mammalian hyoid muscles that are not considered to be facial muscles) (Diogo et al. 2008; Table 1).

As noted above, colugos (Dermoptera or 'flying lemurs') and tree-shrews (Scandentia) are now commonly considered to be the closest living relatives of primates, these three taxa being included in the clade Euarchonta; the clades Glires (lagomorphs + rodents) and Euarchonta make up the clade Euarchontoglires (e.g. Sargis, 2004; Silcox et al. 2007; Fig. 1). Diogo (2009) has recently described the facial muscles of colugos (Fig. 3) and compared them with the

© 2009 The Authors
Journal compilation © 2009 Anatomical Society of Great Britain and Ireland

facial muscles of tree-shrews and of other mammals. The facial musculature of tree-shrews (Table 1) is similar to that of colugos but the latter lack two muscles that are usually present in the former, the sphincter colli superficialis and mandibulo-auricularis. As both of these muscles are found in rodents, as well as in tree-shrews and at least some primates, they were probably present in the LCA of Euarchontans and Primates (Table 1). Some muscles (e.g. frontalis, auriculo-orbitalis, auricularis superior, zygomatico-orbicularis, corrugator supercilii) are normally present as separate elements in tree-shrews, colugos and primates, but not in rodents (Figs 3–9), but there are also muscles (e.g. dilatator nasi, interscutularis, sternofacialis) that are normally present in the latter group but not in euarchontans. The frontalis, auriculo-orbitalis and auricularis superior of euarchontans probably derive from the orbito-temporo-auricularis of other mammals, whereas the zygomatico-orbicularis and corrugator supercilii probably derive from the orbicularis oculi (see Diogo et al. 2008, Diogo, 2009, and Table 1).

A detailed comparison between the facial muscles of primates, tree-shrews, colugos and other mammals suggests that the facial musculature of the LCA of all primates was probably very similar to that seen in the extant tree-shrew *Tupaia* (Table 1). Muscles that have been described in the literature as peculiar to primates, e.g. the zygomaticus major and zygomaticus minor, are now commonly accepted as homologues of muscles of other euarchontans. For instance, in the case of the zygomaticus major and minor, these muscles are respectively homologous to the 'auriculolabialis inferior' and 'auriculolabialis superior' of other mammals (see, e.g. Jouffroy & Saban, 1971; Diogo et al. 2008; Diogo, 2009). The term 'auriculolabialis' was used in descriptions of non-primate taxa such as, e.g. tree-shrews and colugos, because, contrary to the usual condition in anthropoids (Figs 4–9), in these taxa the zygomaticus major and minor usually attach posteriorly onto the cartilage of the external ear (Fig. 3). However, attachment to the external ear also occurs in members of the most basal extant primate clade, the strepsirhines (e.g. Ruge, 1885; Lightoller, 1934; Jouffroy & Saban, 1971; Seiler, 1974b, 1975; Burrows & Smith, 2003; this work). According to our dissections, comparisons and review of the literature, the only muscle that is actually often present as a distinct structure in strepsirhines (e.g. Jouffroy & Saban, 1971; Seiler, 1974b, 1975) but not in tree-shrews or colugos (e.g. Le Gros Clark, 1924, 1926; Lightoller, 1934; Jouffroy & Saban, 1971; Diogo, 2009) is the depressor supercilii (Table 1). This muscle derives from the orbicularis oris matrix, and probably corresponds to part of the corrugator supercilii of non-primate taxa (see Diogo et al. 2008; Table 1). As the depressor supercilii is present in strepsirhine and non-strepsirhine primates, it is likely that this muscle was present in the LCA of primates (Table 1).

According to most authors (e.g. Murie & Mivart, 1872; Ruge, 1885; Huber, 1930b, 1931; Lightoller 1934; Hill, 1953) and our own observations (see, e.g. Burrows & Smith, 2003; this work), extant strepsirhines share a plesiomorphic configuration with most other therian mammals in which the levator labii superioris and levator labii superioris alaeque nasi are not present as distinct muscles (i.e. these primates have an undifferentiated naso-labialis *sensu* the present work; Table 1). However, Seiler (1974b) described both a levator labii superioris and a levator labii superioris alaeque nasi in some strepsirhines, e.g. *Daubentonia madagascarensis*, *Eulemur fulvus* and *Lepilemur ruficaudatus*. Seiler (1974b) also described an 'orbitotemporalis' and an 'auricularis anterior' in these taxa, which would thus correspond to the temporoparietalis and auricularis anterior *sensu* the present work (see Diogo et al. 2008). However, a detailed analysis of his illustrations indicates that the structures that he designates as 'orbitotemporalis' and 'auricularis anterior' actually form a continuous auriculo-orbitalis *sensu* the present work, as is the case in colugos and tree-shrews (e.g. Le Gros Clark, 1924, 1926; Lightoller, 1934; Jouffroy & Saban, 1971; Diogo, 2009) and in the strepsirhine dissections reported by other authors and ourselves (e.g. Murie & Mivart, 1872; Ruge, 1885; Huber, 1930b, 1931; Lightoller, 1934; Hill, 1953; Burrows & Smith, 2003). Another way in which Seiler's reports contradict those of most other researchers concerns the muscles around the mouth. Seiler (1974b, 1975) shows a depressor labii inferioris in the *Eulemur*, *Daubentonia*, *Nycticebus* and *Perodicticus* (but not in the *Lepilemur*) specimens dissected by him. However, according to the descriptions of most authors (e.g. Murie & Mivart, 1872; Ruge, 1885; Lightoller, 1928a; Huber, 1930a, 1931) and our own findings (e.g. Burrows & Smith, 2003; this work), strepsirhines do not have a distinct depressor anguli oris or a distinct depressor labii inferioris, thus sharing the plesiomorphic condition of mammals. Further detailed studies on the facial musculature of the oral region of the strepsirhine taxa described by Seiler, as well as of other non-anthropoid primates, are needed to investigate whether or not at least some of these primates have a distinct depressor anguli oris as usually found in monkeys and hominoids.

In summary, the plesiomorphic condition predicted for the LCA of primates is probably similar to that found in extant strepsirhines such as *Lepilemur* (Table 1). As stressed by Burrows & Smith (2003), the number of facial muscles present in living strepsirhines is higher than that originally reported by authors such as Murie & Mivart (1872) and Huber (1930a, 1931). For instance, Murie & Mivart (1872) reported only seven facial muscles in *Otolemur* (referred to therein as *Galago*), grouping all of the muscles associated with the nasal region into a single 'nasolabial muscle mass'. The supposed lack of complexity seen in strepsirhines was consistent with the anthropocentric, finalistic evolutionary paradigm subscribed to by many anatomists in the last decades of the 19th, and the first decades of the 20th, centuries (e.g. Huber, 1931; see

© 2009 The Authors
Journal compilation © 2009 Anatomical Society of Great Britain and Ireland

Burrows & Smith, 2003). However, it is now accepted that strepsirhines may have more than 20 facial muscles (e.g. 21 in *Lepilemur*, without including the extrinsic muscles of the ear; Table 1). In this respect, the works of authors such as, e.g. Lightoller (1934), Seiler (1974b, 1975; which are unfortunately often neglected by non-German-speaking authors) and Burrows & Smith (2003) were crucial to developing a better understanding of the actual complexity of the strepsirhine facial musculature.

Before moving to the next section, we will provide here a brief account of the general function of the facial muscles that are present in strepsirhines. When we refer in the next section to a certain muscle that is not differentiated in strepsirhines but that is present in anthropoids, we will also briefly describe the general function of that muscle. Unless stated otherwise, the functional descriptions provided in the next section are mainly based on what we know about the muscles of those anthropoids that have been the subject of more frequent and rigorous stimulation and/or movement coding studies, e.g. rhesus monkeys, chimpanzees and particularly modern humans (see, e.g. Andrew, 1963; Preuschoft, 2000; Schmidt & Cohn, 2001; Ekman & Friesen, 2003; Waller & Dunbar, 2005; Parr & Waller, 2006; Parr et al. 2005; Waller et al. 2006, 2008a,b; Vick et al. 2007). In *Lepilemur* (Table 1), a nocturnal, arboreal, territorial, intensive folivore (e.g. Fleagle, 1999), we can reasonably infer muscle function based upon attachments and topology and by comparing these muscles with those of another strepsirhine, the lorisoid *Otolemur*, for which detailed muscle functions have already been proposed (Burrows & Smith, 2003). The platysma myoides probably draws the oral commissure posteroinferiorly, an action that may be used in social interactions as well as feeding, whereas the platysma cervicale probably elevates the skin of the neck. The occipitalis draws the scalp posteriorly toward the nuchal region, whereas the frontalis elevates the skin/brow over the superciliary region. The auriculo-orbitalis may be used to draw the lateral corner of the eyelid posteroinferiorly or the external ear anterosuperiorly. The corrugator supercilii and depressor supercilii are used to draw the medial edge of the superciliary region inferomedially and inferiorly, respectively. The mandibulo-auricularis may be used to approximate the superior and inferior edges of the external ear, as well as the external ear and mandible. The muscles clustered around the upper lip, including the zygomaticus major and zygomaticus minor muscles, may be used to draw the upper lip and posterior region of the mouth posterosuperiorly, functions that may be used in both social interactions and in use of the vomeronasal organ. As their name indicates, the extrinsic muscles of the ear, as well as the auricularis posterior and auricularis superior, are mostly related to movement of the external ear, whereas the orbicularis oculi and orbicularis oris are primarily associated with movement of the eyes and lips, respectively. The buccinatorius mainly pulls the corner of the mouth laterally and presses the cheek against the teeth. The nasolabialis, maxillo-naso-labialis and levator anguli oris facialis are probably used together in drawing the upper lip and posterior region of the mouth superiorly and medially, which is probably used in social interactions and feeding. The mentalis mainly elevates the skin ventral to the lower lip, whereas the sphincter colli profundus probably draws the skin of the neck posterosuperiorly. Although we have proposed these functions based upon muscle attachments and topology and a comparison to closely related species, ethograms of *Lepilemur* and other strepsirhines are clearly needed to test these functional hypotheses.

Homologies and evolution of the facial muscles within anthropoids

There are some notable differences between the plesiomorphic condition described above for non-anthropoid primates such as *Lepilemur* and the condition found in New World and Old World monkeys (Table 1). For example, the mandibulo-auricularis is usually not present as an independent, fleshy muscle in most anthropoids (Table 1; Figs 4–9). It probably corresponds to the stylo-mandibular ligament seen in hominoids such as *Homo sapiens* and monkeys such as *Macaca mulatta* (e.g. Lightoller, 1928a, 1934; Jouffroy & Saban, 1971; Diogo et al. 2008), although in the latter species the origin of this ligament is markedly ventral to the ear, i.e. to the usual posterior attachment of the mandibulo-auricularis (e.g. Geist, 1933; this work). According to Huber (1933), fleshy vestiges of the mandibulo-auricularis are, however, found as a 'rare primitive' variant in some anthropoid taxa (e.g. macaques; see his Fig. 55). The sphincter colli profundus is also normally absent in anthropoids (Table 1; Figs 4–9) but fleshy vestiges of this muscle have also been described in a few macaque specimens (e.g. Lightoller, 1928a; Huber, 1930b, 1931, 1933).

Contrary to other mammals, most anthropoids have a levator labii superioris, levator labii superioris alaeque nasi and procerus (Table 1; Figs 4–9). These muscles are probably derived from the naso-labialis, although the procerus may possibly be derived from the orbicularis oculi (see Diogo et al. 2008; Table 1). Both the levator labii superioris and levator labii superioris alaeque nasi are normally used in elevating the upper lip and flaring the alar region of the nostril, respectively; these movements are seen in social interactions among rhesus macaques, baboons, chimpanzees and other anthropoids (e.g. Goodall, 1986; Partan, 2002). The levator labii superioris muscle is also used for grooming in chimpanzees and for speech in modern humans (e.g. Calvert & Campbell, 2003; Rogers et al. 2009). The procerus muscle is typically described as drawing the medial portion of the superciliary region inferiorly, wrinkling the skin over the glabella (Waller et al. 2008b). Huber (1930b, 1931, 1933) and Lightoller (1928a) sug-

© 2009 The Authors
Journal compilation © 2009 Anatomical Society of Great Britain and Ireland

gested that in *Macaca mulatta* the procerus is not present as a separate muscle, and Lightoller (1928a) stated that the 'labii profundus superior' (i.e. the depressor septi nasi *sensu* the present work) is also not present as a separate muscle in these monkeys. However, Shibata (1959) and Seiler (1970, 1971c) did describe both muscles in *Macaca mulatta*; our dissections corroborate the descriptions of these latter authors (Table 1; see, e.g. Fig. 5). Waller et al. (2008b) did not describe a depressor septi nasi in *Macaca mulatta* but this muscle might well correspond to the small, unlabeled structure that is shown below the nasalis muscle in their Fig. 1. The depressor septi nasi and nasalis of anthropoids are probably derived from the maxillo-nasolabialis (Table 1; Diogo et al. 2008).

Anthropoids often have a depressor anguli oris and depressor labii inferioris (e.g. Schreiber, 1928; Huber, 1930a, 1931, 1933; see Table 1 and Figs 4–9). These muscles are probably derived from the orbicularis oris matrix; some authors suggested that the depressor anguli oris might be the result of a ventral extension of the levator anguli oris (e.g. Ruge, 1887b; Lightoller, 1928a; Huber, 1930a, 1931; Diogo et al. 2008; Table 1). Generally, the depressor anguli oris and depressor labii inferioris function in anthropoids to draw the corner of the mouth posteroinferiorly and to draw the lower lip inferiorly, respectively. These movements are seen in some displays of facial expression and in some feeding contexts (e.g. Goodall, 1986; Dobson, 2009, in press). Huber (1930b, 1931, 1933) and Shibata (1959) state that the depressor labii inferioris is not present as an independent structure in *Macaca mulatta* and *Macaca cyclopis* (note that the muscle named 'depressor labii inferioris' in Fig. 471 of Jouffroy & Saban, 1971, which is based on Fig. 1 of Shibata, 1959, corresponds in fact to the 'incisivus inferioris' and not to the depressor labii inferioris, *sensu* Shibata, 1959). However, the depressor labii inferioris was found in the *Macaca mulatta* specimens dissected by authors such as Waller et al. (2008b) as well as by us (Table 1; see Fig. 4).

With regard to the Hominoidea, the number of facial muscles found in the taxa within this clade is essentially the same as that found in *Macaca mulatta* (Table 1). According to the descriptions available in the literature, the platysma cervicale is usually present in hylobatids (e.g. Sonntag, 1924b; Ruge, 1911; Huber, 1930b, 1931; Loth, 1931; Edgeworth, 1935) and gorillas (e.g. Sullivan & Osgood 1925; Raven, 1950) but is often highly reduced or absent in adult orangutans, panins and modern humans (e.g. Lightoller 1928a; Huber, 1930b, 1931; Loth, 1931; Gasser, 1967). Our dissections corroborate these descriptions (Table 1; see Figs 6–9). The transversus nuchae, found as a variant in the three latter taxa, is often considered to be a vestigial remain/bundle of the platysma cervicale (e.g. Aziz, 1981). Interestingly, Gasser (1967) has shown that the platysma cervicale is present early in the development of modern humans but that it normally disappears as an independent structure in later stages of development. Contrary to the platysma cervicale, the platysma myoides is usually present as a separate structure in adult members of all of the major five extant hominoid taxa (Table 1; Figs 6–9). The occipitalis is also usually present in these five taxa (Table 1; see Fig. 8) but the auricularis posterior is normally not differentiated in the Ponginae (e.g. Sullivan & Osgood, 1925; Lightoller, 1928a; Miller, 1952; Table 1), although it has been described in a few members of this latter subfamily (see, e.g. Winkler, 1989).

There is much confusion in the literature about the presence/absence, in apes, of a separate risorius muscle such as that usually (but not always; see, e.g. Standring, 2004) found in modern humans. In humans, the risorius pulls the lip corners backward, stretching the lips, a function that is, interestingly, usually associated with the display of fear (e.g. Ekman & Friesen, 2003). Lightoller (1928a) stated that there are some structures that are often named 'risorius' in apes but that probably are not homologous to the risorius of humans, and even to each other, because some of these structures apparently derive from the platysma myoides, others from the depressor anguli oris, and still others from muscles such as the zygomaticus major. Huber (1930a, 1931) argued that the 'true' risorius derives from the depressor anguli oris, and that the 'risorius' muscles described in *Pan* are probably not homologous to the 'true' risorius because they derive from the platysma myoides, zyzgomaticus major or both. Loth (1931) agreed with the hypothesis that the 'true' risorius, i.e. the 'risorius Santorini', derives from the depressor anguli oris, proposed that the other 'risorius', the 'platysmarisorius', derives from the platysma myoides, and suggested that a few modern humans might have both a 'true' risorius and a 'platysmarisorius'. In contrast, in his study of modern human development, Gasser (1967) concluded that the 'true' risorius that is usually present in humans derives from the platysma myoides, a view that was supported by Jouffroy & Saban (1971). Based on their own dissections of numerous mammals and a review of the information available in the literature, Diogo et al. (2008) concluded that the muscle risorius that is usually present in humans is probably derived from the platysma myoides, although it cannot be completely discarded that it is partly, or even wholly, derived from the zygomaticus major (Table 1).

Within hylobatids, Seiler (1971d) described a distinct 'risorius' in *Hylobates agilis*, *Hylobates lar* and *Hylobates syndactylus* but it is not clear if the structures that he described in the three species are actually homologous to each other. For instance, in his Figs 591 and 592 the 'risorius' of *Hylobates syndactylus* runs more horizontally than that of *Hylobates agilis* and its fibers have an overall configuration that is somewhat similar to those of the zygomaticus major *sensu* the present work (i.e. a careful analysis of his figures indicates that the 'risorius' of *Hylobates agilis* might be differentiated from the platysma myoides,

© 2009 The Authors
Journal compilation © 2009 Anatomical Society of Great Britain and Ireland

whereas the 'risorius' of *Hylobates syndactylus* might be differentiated from the zygomaticus major). Regarding the Ponginae, according to many assessments (e.g. Sonntag, 1924a; Sullivan & Osgood, 1925; Lightoller, 1928a; Huber, 1930b; Winkler, 1989: Gibbs, 1999; Gibbs et al. 2002), these apes lacks a 'risorius' but Seiler (1971d) reported it to be present. Seiler (1971d), as well as authors such as Chudzinski (1885), Huber (1930b, 1931), Raven (1950), Gibbs (1999) and Gibbs et al. (2002), did also report the presence of a 'risorius' in gorillas. Chudzinski (1885) stated that the 'risorius' of the gorilla that he dissected probably corresponds to the 'true' risorius of humans. Huber (1930b, 1931) argued that the 'risorius' of gorillas, as well as of chimpanzees, is not a 'true' risorius ('of Santorini') because it is derived from the platysma myoides and/or zygomaticus major, and not from the depressor anguli oris (however, as explained above, the human risorius probably does derive from the platysma myoides and/or zygomaticus major). The 'risorius' of the *Gorilla* specimen examined by Raven (1950) is also probably closely related to the platysma myoides. Concerning *Pan*, Gratiolet & Alix (1866), Sonntag (1923, 1924b), Gibbs (1999) and Gibbs et al. (2002) suggest that, although some individuals have a 'risorius', this structure is not completely differentiated from muscles such as the platysma myoides. Sullivan & Osgood (1925) described an 'upper bundle of the platysma' in common chimpanzees, which, according to them, corresponds to the 'true' risorius of humans. In their work on the facial muscles of chimpanzees, Burrows et al. (2006) described a structure that they suggested might be homologous to the risorius found in most humans and explained that this structure was not described by Pellatt (1979b) in other chimpanzees but that it may correspond to part of the 'platysma' *sensu* Sonntag (1923).

Among the hominoids dissected for the present study, only modern humans had a well-defined, separate, risorius. In some non-human specimens (e.g. in the chimpanzees PFA 1016 and PFA 1009 but not in PFA 1051 or HUC 104) a few muscular fibers passed posteriorly and superficially (relative to the platysma myoides) to the angle of the mouth but these fibers did not form a distinct, well-defined muscle risorius such as that found in most humans (Table 1).

All of the other facial muscles that are present in macaques (i.e. zygomaticus major, zygomaticus minor, frontalis, auricularis superior, orbicularis oculi, depressor supercilii, corrugator supercilii, levator labii superioris, levator labii superioris alaeque nasi, procerus, buccinatorius, nasalis, depressor septi nasi, levator anguli oris facialis, orbicularis oris, depressor labii inferioris, depressor anguli oris and mentalis) are normally present in extant hylobatids, orangutans, gorillas, panins and humans (Table 1; see Figs 6–9). However, contrary to monkeys and other hominoids, humans, and possibly also gorillas, usually have an auricularis anterior and temporoparietalis (Table 1). Both of these muscles are derived from the auriculo-orbitalis, which, in other hominoids such as chimpanzees, has often been given the name 'auricularis anterior', although it actually corresponds to the auricularis anterior plus the temporoparietalis of humans and gorillas (Table 1; Diogo et al. 2008). When present, the temporoparietalis stabilizes the galeal aponeurosis, whereas the auricularis anterior draws the external ear superoanteriorly, closer to the orbit.

General remarks and proposal of a unifying nomenclature for the facial muscles of the Mammalia

The names of the facial muscles that we propose are shown in Table 1; Table 1 also provides a list of more than 300 synonyms that have been used by other authors to designate these muscles. To our knowledge, this is the first time that such a detailed list of synonyms of the facial muscles, not only of primates but also of other mammals, has been compiled in a single study. The fact that more than 300 synonyms have been, and continue to be, used in the literature to describe the facial muscles listed in Table 1 stresses the problem that researchers face when trying to compare the structures of the taxa that they are studying with those described by other authors in other taxa, or even in the same taxa. This is particularly problematic for researchers, such as psychologists or neurobiologists interested in the evolution of facial expressions, who work in fields other than comparative anatomy (e.g. Sherwood et al. 2003; Parr & Waller, 2006; Waller et al. 2006, 2008a,b). One of the main goals of this study was to provide researchers with tools to compare the facial muscles in their study animal with muscles previously described in the literature. Our suggested nomenclature expands on the proposals made in Diogo et al. (2008). A main advantage and strength of our nomenclature is that it combines, and thus creates a bridge between, the names used by human anatomists and by researchers working with non-human primates and non-primate mammals. For example, the terms platysma myoides, platysma cervicale, sphincter colli superficialis, sphincter colli profundus, cervicalis transversus, naso-labialis, sternofacialis, interscutularis, orbito-temporo-auricularis, auriculo-orbitalis and maxillo-naso-labialis are often used to designate the muscles of non-primate mammals (e.g. Jouffroy & Saban, 1971). As some of the muscles that are present in these mammals are directly homologous with muscles that are seen in primates and particularly in strepsirhines (e.g. platysma cervicale, platysma myoides, sphincter colli profundus, auriculo-orbitalis, naso-labialis and maxillo-naso-labialis), it is reasonable to use these names in the descriptions of these primates (and not to use, as is often done in the literature, different names to designate these muscles in primates, e.g. 'notoplatysma', 'tracheoplatysma', 'sphincter colli', 'auricularis anterior', 'levator labii inferioris' and 'nasalis', respectively; see

© 2009 The Authors
Journal compilation © 2009 Anatomical Society of Great Britain and Ireland

Table 1). At the same time, our nomenclature retains most of the names used for the facial muscles of modern humans as set out in, e.g., the Terminologia Anatomica (1998), for it is also important to maintain the stability of a nomenclature that has been consistently used during various decades in thousands of publications dealing with human anatomy, evolution, psychology and medicine. In fact, regarding the human facial muscles, there are only two differences between our nomenclature and that used in Terminologia Anatomica (1998). Instead of 'platysma' we use the name platysma myoides (because the muscle of modern humans corresponds to the platysma myoides and not to the whole 'platysma', i.e. platysma myoides + platysma cervicale, of other mammals) and in place of 'levator anguli oris' we use the name levator anguli oris facialis [in order to distinguish this facial muscle from the reptilian mandibular muscle that is also designated as 'levator anguli oris', Diogo et al. (2008) proposed naming the mammalian facial muscle as levator anguli oris facialis and the reptilian mandibular muscle as levator anguli oris mandibularis] (Table 1).

A consequence of using this unifying nomenclature is that it clearly stresses that the facial muscles present in strepsirhines are in reality essentially the same muscles that are present in non-primate mammals such as tree-shrews (Table 1). The main difference between these taxa is that strepsirhines usually have a muscle, the depressor supercilii, that is usually not differentiated in tree-shrews, and that strepsirhines lack two muscles that are often present in tree-shrews, the sphincter colli superficialis and the peculiar, small zygomatico-orbicularis (Table 1). It is interesting to note that each of the three non-primate taxa listed in Table 1 has at least one derived, peculiar muscle that is not differentiated in any other taxa listed in Table 1. So, for instance, *Ornithorhynchus* has a cervicalis transversus, *Rattus* has a sternofacialis and interscutularis and *Tupaia* has a zygomatico-orbicularis. This supports the idea that evolution is not directed 'towards' a goal, and surely not 'towards' primates and modern humans; each taxon has its own particular mix of primitive and derived anatomical structures, which is the result of its unique evolutionary history (Diogo et al. 2008, 2009). That is why we use the term correspond, because muscles such as the zygomatico-orbicularis are not 'ancestral' to the muscles of primates. The zygomatico-orbicularis simply corresponds to a part of the orbicularis oculi that, in taxa such as *Tupaia*, became sufficiently differentiated to deserve being recognized as a separate muscle (Table 1; see also Diogo et al. 2008; Diogo, 2009).

Regarding the evolution of the facial muscles within the primates, the muscles present in macaques are essentially the same muscles that are seen in hominoids, with a few exceptions (Table 1). These monkeys do not have distinct risorius, auricularis anterior and temporoparietalis muscles such as those found in hominoids such as humans but have muscles that are usually not differentiated in some hominoid taxa, e.g. the platysma cervicale (usually not differentiated in orangutans, panins and hominins) and the auricularis posterior (usually not differentiated in orangutans). Overall, monkeys and hominoids have more facial muscles than strepsirhines and, among the taxa listed in Table 1, modern humans, together with gorillas, have the greatest number of facial muscles; this is consistent with the important role played by facial expression in anthropoids in general and in modern humans in particular (e.g. Burrows, 2008). However, the evidence presented in this study, as well as in Burrows & Smith (2003) and Burrows et al. (2006), shows that the difference between the number of facial muscles present in modern humans and hominoids such as hylobatids, chimpanzees and orangutans, and between the number of muscles seen in these latter hominoids and strepsirhines, is not as marked as previously thought (see, e.g. Huber 1930b, 1931). In fact, it is important to stress that the display of complex facial expressions in a certain taxon is not only related to the number of facial muscles. It is also related to the subdivisions, arrangements of the fibers, topology, biochemistry and microanatomical mechanical proprieties of these muscles, as well as to the peculiar osteological and external features, and the specific social group characteristics and ecological setting of the members of that taxon (see, e.g. Andrew, 1963; Preuschoft, 2000; Schmidt & Cohn, 2001; Burrows et al. 2006; Burrows, 2008; Waller et al. 2008a,b; Dobson, 2009, in press; Rogers et al. 2009; Burrows & Cohn, in press). A main goal of the present study was precisely to stimulate and help anatomists, functional morphologists and other researchers such as psychologists, neurobiologists and developmental biologists to undertake future works that will hopefully lead to a more comprehensive, multidisciplinary understanding of the evolution of the facial muscles and facial expressions in primates, and in mammals in general.

Acknowledgements

We thank M. Carleton, D. Schmidt and L. Gordon (National Museum of Natural History), S. Ktretschmar, M. Cánepa, J. C. Stazonelli and G. Scrocchi (Fundación Miguel Lillo), R. Walsh and F. Slaby (Department of Anatomy, George Washington University), B. Richmond (Department of Anthropology, George Washington University), the Duke Lemur Center, Lisa Parr (Yerkes National Primate Research Center), Christopher J. Bonar (Cleveland Metroparks Zoo), and J. Fritz and J. Murphy (Primate Foundation of Arizona) for kindly providing a large part of the specimens analysed for this study. We especially thank J. Clarke and two anonymous reviewers for providing helpful suggestions. R.D. was supported by a George Washington University Presidential Merit Fellowship, B.A.W. by a George Washington University Professorship in Human Origins, the GWU VPAA and GW Academic Excellence Program, M.A.A. by a grant from the Anatomy Department of the Howard University College of Medicine, and A.B. by the Office of the Dean of the Duquesne University.

© 2009 The Authors
Journal compilation © 2009 Anatomical Society of Great Britain and Ireland

References

Agnarsson I, Coddington JA (2007) Quantitative tests of primary homology. *Cladistics* **23**, 1–11.

Andrew RJ (1963) Evolution of facial expression. *Science* **142**, 1034–1041.

Aziz MA (1981) Possible 'atavistic' structures in human aneuploids. *Am J Phys Anthropol* **54**, 347–353.

Bischoff TLW (1870) Beitrage zur Anatomie des *Hylobates leuciscus* and zueiner vergleichenden Anatomie der Muskeln der Affen und des Menschen. *Abh Bayer Akad Wiss München Math Phys Kl* **10**, 197–297.

Bischoff TLW (1880) Beitrage zur Anatomie des *Gorilla*. *Abh Bayer Akad Wiss München Math Phys Kl* **13**, 1–48.

Broca P (1869) L'ordre des primates – parallele anatomique de l'homme et des singes. *Bull Soc Anthropol Paris* **4**, 228–401.

Bryant MD (1945) Phylogeny of Nearctic Sciuridae. *Am Midland Nat* **33**, 257–390.

Burrows AM (2008) The facial expression musculature in primates and its evolutionary significance. *Bioessays*, **30**, 212–225.

Burrows AM, Cohn JF (in press) Anatomy of the face. In *Encyclopedia of Biometrics* (ed. Li SZ). New York: Elsevier.

Burrows AM, Smith TD (2003) Muscles of facial expression in *Otolemur* with a comparison to Lemuroidea. *Anat Rec* **274**, 827–836.

Burrows AM, Waller BM, Parr LA (in review) Facial musculature in the rhesus macaque (*Macaca mulatta*): evolutionary and functional contexts with comparisons to chimpanzees and strepsirrhines. *Anat Rec.*

Burrows AM, Waller BM, Parr LA, Bonar CJ (2006) Muscles of facial expression in the chimpanzee (*Pan troglodytes*): descriptive, comparative and phylogenetic contexts. *J Anat* **208**, 153–167.

Calvert GA, Campbell R (2003) Reading speech from still and moving faces: the neural substrates of visible speech. *J Cogn Neurosci* **15**, 57–70.

Champneys F (1872) The muscles and nerves of a Chimpanzee (*Troglodytes Niger*) and a *Cynocephalus Anubis*. *J Anat Physiol* **6**, 176–211.

Chudzinski T (1885) Sur les muscles peaussiers du crane et de la face observes sur un jeune gorilla. *Bull Soc Anthropol Paris* **8**, 583–586.

Dawkins R (2004) *The Ancestor's Tale – A Pilgrimage to the Dawn of Life*. Boston: Houghton Mifflin.

De Pinna MCC (1991) Concepts and tests of homology in the cladistic paradigm. *Cladistics* **7**, 367-394.

Deniker J (1885) Recherches anatomiques et embryologiques sur les singes anthropoides, foetus de gorille et de gibbon. *Arch Zool Exp Gén* **3**, 1–265.

Diogo R (2007) *On the Origin and Evolution of Higher-Clades: Osteology, Myology, Phylogeny and Macroevolution of Bony Fishes and the Rise of Tetrapods*. Enfield: Science Publishers.

Diogo R (2008) Comparative anatomy, homologies and evolution of the mandibular, hyoid and hypobranchial muscles of bony fish and tetrapods: a new insight. *Anim Biol* **58**, 123–172.

Diogo R (2009) The head musculature of the Philippine colugo (Dermoptera: *Cynocephalus volans*), with a comparison to tree-shrews, primates and other mammals. *J Morphol* **270**, 14–51.

Diogo R, Abdala V, Aziz MA, Lonergan N, Wood BA (2009) From fish to modern humans – comparative anatomy, homologies and evolution of the pectoral and forelimb musculature. *J Anat*, **214**, 694–716.

Diogo R, Abdala V, Lonergan N, Wood BA (2008) From fish to moderm humans – comparative anatomy, homologies and evolution of the head and neck musculature. *J Anat* **213**, 391–424.

Diogo R, Wood BA (2008) Comparative anatomy, phylogeny and evolution of the head and neck musculature of hominids: a new insight. *Am J Phys Anthropol Suppl* **46**, 90.

Dobson SD (2009) Allometry of facial mobility in anthropoid primates: implications for the evolution of facial expression. *Am J Phys Anthropol* **138**, 70–81.

Dobson SD (in press) Socioecological correlates of facial mobility in nonhuman anthropoids. *Am J Phys Anthropol*.

Duvernoy M (1855–1856) Des caracteres anatomiques de grands singes pseudoanthropomorphes anthropomorphes. *Arch Mus Nat Hist Nat Paris* **8**, 1–248.

Edgeworth FH (1935) *The Cranial Muscles of Vertebrates*. Cambridge: University Press.

Ekman P, Friesen WV (2003) *Unmasking the Face – A Guide to Recognizing Emotions from Facial Expressions*. Cambridge: Malor Books.

Fleagle JG (1999) *Primate Adaptation and Evolution*, 2nd edn. San Diego: Academic Press.

Gasser RF (1967) The development of the facial muscles in man. *Am J Anat* **120**, 357–376.

Geist FD (1933) Nasal cavity, larynx, mouth and pharynx. In *The Anatomy of the Rhesus Monkey* (eds Hartman CG, Straus WL), pp. 189–209. Baltimore: Williams & Wilkins.

Gibbs S (1999) *Comparative Soft Tissue Morphology of the Extant Hominoidea, including Man*. Unpublished PhD Thesis, The University of Liverpool.

Gibbs S, Collard M, Wood BA (2002) Soft-tissue anatomy of the extant hominoids: a review and phylogenetic analysis. *J Anat* **200**, 3–49.

Goodall J (1986) *The Chimpanzees of Gombe: Patterns of Behavior*. Cambridge: Harvard University Press.

Gratiolet LP, Alix PHE (1866) Recherches sur l'anatomie du *Troglodytes aubryi*. *Nouv Arch Mus Hist Nat Paris* **2**, 1–264.

Greene EC (1935) *Anatomy of the Rat*. New York: Hafner Publishing.

Gunnell GF, Simmons NB (2005) Fossil evidence and the origin of bats. *J Mammal Evol* **12**, 209–246.

Hill WCO (1953) *Primates – Comparative Anatomy and Taxonomy, I, Strepsirhini*. Edinburgh: University Press.

Hill WCO (1955) *Primates – Comparative Anatomy and Taxonomy, II, Haplorhini: Tarsioidea*. Edinburgh: University Press.

Hill WCO (1957) *Primates – Comparative Anatomy and Taxonomy, III, Pithecoidea, Platyrrhini (Families Hapalidae and Callimiconidae)*. Edinburgh: University Press.

Hill WCO (1959) The anatomy of *Callimico goeldii* (Thomas): a primitive American primate. *Trans Am Phil Soc New Ser* **49**, 1–116.

Hill WCO (1960a) *Primates – Comparative Anatomy and Taxonomy, IV, Cebidae, Part A*. Edinburgh: University Press.

Hill WCO (1960b) *Primates – Comparative Anatomy and Taxonomy, VI, Catarrhini: Cercopithecoidea, Cercopithecinae*. New York: Interscience Publishers.

Hill WCO (1970) *Primates – Comparative Anatomy and Taxonomy, VIII, Cynopithecinae: Papio, Mandrillus, Theropithecus*. Edinburgh: University Press.

Hill WCO (1974) *Primates – Comparative Anatomy and Taxonomy, VII, Cynopithecinae: Cercocebus, Macaca, Cynopithecus*. Edinburgh: University Press.

Huber E (1930a) Evolution of facial musculature and cutaneous field of trigeminus – Part I. *Q Rev Biol* **5**, 133–188.

Huber E (1930b) Evolution of facial musculature and cutaneous field of trigeminus – Part II. *Q Rev Biol* **5**, 389–437.

Huber E (1931) *Evolution of Facial Musculature and Expression*. Baltimore: The Johns Hopkins University Press.

© 2009 The Authors
Journal compilation © 2009 Anatomical Society of Great Britain and Ireland

Huber E (1933) The facial musculature and its innervation. In *The Anatomy of the Rhesus Monkey* (eds Hartman CG, Straus WL), pp. 176–188. Baltimore: Williams & Wilkins.

Janeka JE, Miller W, Pringle TH, et al. (2007) Molecular and genomic data identify the closest living relative of Primates. *Science* **318**, 792–794.

Jouffroy FK, Saban R (1971) Musculature peaucière. In *Traité de Zoologie, XVI: 3 (Mammifères)* (ed. Grassé PP), pp. 477–611. Paris: Masson et Cie.

Kardong KV (2002) *Vertebrates: Comparative Anatomy, Function, Evolution* (3rd ed.). New York: McGraw-Hill.

Kemp TS (2005) *The Origin and Evolution of Mammals*. New York: Oxford University Press.

Larrabee WF Jr, Makielski KH (1993) *Surgical Anatomy of the Face*. New York: Raven Press.

Le Double F (1897) *Traité des variations du système musculaire de l'homme et de leur signification au point de vue de l'anthropologie zoologique, I et II*. Paris: Librairie C. Reinwald.

Le Gros Clark WE (1924) The myology of the tree-shrew (*Tupaia minor*). *Proc Zool Soc Lond* **1924**, 461–497.

Le Gros Clark WE (1926) On the anatomy of the pen-tailed tree-shrew (*Ptilocercus lowii*). *Proc Zool Soc Lond* **1926**, 1178–1309.

Lightoller GHS (1925) Facial muscles – the modiolus and muscles surrounding the rima oris with some remarks about the panniculus adiposus. *J Anat Physiol* **60**, 1–85.

Lightoller GS (1928a) The action of the m. mentalis in the expression of the emotion of distress. *J Anat* **62**, 319–332.

Lightoller GS (1928b) The facial muscles of three orang utans and two cercopithecidae. *J Anat* **63**, 19–81.

Lightoller GS (1934) The facial musculature of some lesser primates and a *Tupaia*. *Proc Zool Soc Lond* **1934**, 259–309.

Lightoller GS (1939) Probable homologues. A study of the comparative anatomy of the mandibular and hyoid arches and their musculature – Part I – comparative myology. *Trans Zool Soc Lond* **24**, 349–382.

Lightoller GS (1940a) The comparative morphology of the platysma: a comparative study of the sphincter colli profundus and the trachelo-platysma. *J Anat* **74**, 390–396.

Lightoller GS (1940b) The comparative morphology of the m. caninus. *J Anat* **74**, 397–402.

Lightoller GS (1942) Matrices of the facialis musculature: homologization of the musculature in monotremes with that of marsupials and placentals. *J Anat* **76**, 258–269.

Loth E (1931) *Anthropologie des parties molles (muscles, intestins, vaisseaux, nerfs peripheriques)*. Paris: Mianowski-Masson et Cie.

MacAlister A (1871) On some points in the myology of the chimpanzee and others of the primates. *Ann Mag Nat Hist* **7**, 341–351.

Marivaux L, Bocat L, Chaimanee Y, et al. (2006) Cynocephalid dermopterans from the Palaeogene of South Asia (Thailand, Myanmar and Pakistan): systematic, evolutionary and palaeobiogeographic implications. *Zool Scripta* **35**, 395–420.

Miller RA (1952) The musculature of *Pan paniscus*. *Am J Anat* **91**, 182–232.

Murie J, Mivart St G (1872) On the anatomy of the Lemuroidea. *Trans Zool Soc Lond* **7**, 1–113.

Netter FH (2006) *Atlas of Human Anatomy*, 4th ed. Philadelphia: Saunders.

Owen R (1830–1831) On the anatomy of the orangutan (*Simia satyrus*, L.). *Proc Zool Soc Lond* 1, 4–5, 9–10, 28–29, 66–72.

Parr LA, Waller BM, Fugate J (2005) Emotional communication in primates: implications for neurobiology. *Curr Opin Neurobiol* **15**, 716–720.

Parr LA, Waller BM (2006) Understanding chimpanzee facial expression: insights into the evolution of communication. *Soc Cogn Affect Neurosci* **1**, 221–228.

Partan SR (2002) Single and multichannel signal composition: facial expressions and vocalizations of rhesus macaques (*Macaca mulatta*). *Behaviour* **139**, 993–1027.

Patterson C (1988) Homology in classical and molecular biology. *Mol Biol Evol* **5**, 603–625.

Pellatt A (1979a) The facial muscles of *Papio ursinus*. *S Afr J Sci* **75**, 30–37.

Pellatt A (1979b) The facial muscles of three African primates contrasted with those of *Papio ursinus*. *S Afr J Sci* **75**, 436–440.

Peng Y, Ye Z, Liu R (1982) The facial musculature of *Rhinopithecus*. *Zool Res* **3**, 245–262.

Polak C (1908) Die Anatomie des genus *Colobus*. *Verhandl Akad Wet Amst* **14**, 1–247.

Pough FH, Heiser JB, McFarland WN (1996) *Vertebrate Life* (4th ed.). New Jersey: Prentice-Hall.

Preuschoft S (2000) Primate faces and facial expressions. *Soc Res* **67**, 245–271.

Raven HC (1950) Regional anatomy of the *Gorilla*. In *The Anatomy of the Gorilla* (ed. Gregory WK), pp. 15–188. New York: Columbia University.

Rogers CR, Mooney MP, Smith TD, et al. (2009) Comparative microanatomy of the orbicularis oris muscle between chimpanzees and humans: evolutionary divergence of lip function. *J Anat* **214**, 36–44.

Ruge G (1885) Über die Gesichtsmuskulatur der Halbaffen. *Morphol Jahrb* **11**, 243–315.

Ruge G (1887a) *Untersuchungen uber die Gesichtsmuskeln der Primaten*. Leipzig: W. Engelmann.

Ruge G (1887b) Die vom Facialis innervirten Muskeln des Halses, Nackens und des Schädels einen jungen *Gorilla*. *Gegen Morphol Jahrb* **12**, 459–529.

Ruge G (1890) Anatomisches über den Rumpf der Hylobatiden – ein Beitrag zur Bestimmung der Stellung dieses genus im System. *Max Weber's Zool Ergebn Reise Niederl Ostindien* **2**, 366–460.

Ruge G (1897) *Über das peripherische Gebiet des nervus facialis boi Wirbelthieren*. Leipzig: Festschrf Gegenbaur.

Ruge G (1910) Verbindungen des Platysma mit der tiefen Muskulatur des Halses beim Menschen. *Morphol Jahrb* **41**, 708–724.

Ruge G (1911) Gesichtsmuskulatur und Nervus facialis der Gattung *Hylobates*. *Morphol Jahrb* **44**, 129–177.

Ryan JM (1986) Comparative morphology and evolution of cheek pouches in rodents. *J Morphol* **190**, 27–42.

Ryan JM (1989) Evolution of cheek pouches in African pouched rats (Rodentia: Cricetomyinae). *J Mammal* **70**, 267–274.

Saban R (1968) Musculature de la tête. In *Traité de Zoologie*, XVI, 3 (Mammifères) (ed. Grassé PP), pp. 229–472. Paris: Masson et Cie.

Saban R (1971) Particularités musculaires des Monotrémes – musculature de la tête. In *Traité de Zoologie*, **XVI**, 3 (Mammifères) (ed. Grassé PP), pp. 681–732. Paris: Masson et Cie.

Sargis EJ (2002a) The postcranial morphology of *Ptilocercus lowii* (Scandentia, Tupaiidae): an analysis of primatomorphan and volitantian characters. *J Mammal Evol* **9**, 137–160.

Sargis EJ (2002b) Functional morphology of the forelimb of tupaiids (Mammalia, Scandentia) and its phylogenetic implications. *J Mammal* **253**, 10–42.

Sargis EJ (2004) New views on tree shrews: the role of tupaiids in primate supraordinal relationships. *Evol Anthropol* **13**, 56–66.

Schmidt KL, Cohn JF (2001) Human facial expressions as adaptations: evolutionary questions in facial expression research. *Yearb Phys Anthropol* **44**, 3–24.

© 2009 The Authors
Journal compilation © 2009 Anatomical Society of Great Britain and Ireland

Schön MA (1968) *The Muscular System of the Red Howling Monkey*. Washington DC: Smithsonian Institution Press.

Schreiber H (1928) Die Gesichtsmuskulatur der Platyrrhinen. *Morphol Jahrb* **60**, 179–295.

Seiler R (1970) Differences in the facial musculature of the nasal and upper-lip region in catarrhine primates and man. *Z Morphol Anthropol* **62**, 267–275.

Seiler R (1971a) A comparison between the facial muscles of Catarrhini with long and short muzzles. *Proc 3rd Int Congr Primat Zürich 1970* **I**, 157–162. Basel: Karger.

Seiler R (1971b) Facial musculature and its influence on the facial bones of catarrhinous Primates. I. *Morphol Jahrb* **116**, 122–142.

Seiler R (1971c) Facial musculature and its influence on the facial bones of catarrhine Primates. II. *Morphol Jahrb* **116**, 147–185.

Seiler R (1971d) Facial musculature and its influence on the facial bones of catarrhine Primates. III. *Morphol Jahrb* **116**, 347–376.

Seiler R (1971e) Facial musculature and its influence on the facial bones of catarrhine Primates. IV. *Morphol Jahrb* **116**, 456–481.

Seiler R (1973) On the function of facial muscles in different behavioral situations – a study based on muscle morphology and electromyography. *Am J Phys Anthropol* **38**, 567–571.

Seiler R (1974a) Muscles of the external ear and their function in man, chimpanzees and *Macaca*. *Morphol Jahrb* **120**, 78–122.

Seiler R (1974b) Particularities in facial muscles of *Daubentonia madagascariensis* (Gmelin 1788). *Folia Primatol* **22**, 81–96.

Seiler R (1975) On the facial muscles in *Perodicticus potto* and *Nycticebus coucang*. *Folia Primatol* **23**, 275–289.

Seiler R (1977) Morphological and functional differentiation of muscles – studies on the m. frontalis, auricularis superior and auricularis anterior of primates including man. *Verh Anat Ges* **71**, 1385–1388.

Seiler R (1979a) Criteria of the homology and phylogeny of facial muscles in primates including man. I. Prosimia and Platyrrhina. *Morphol Jahrb* **125**, 191–217.

Seiler R (1979b) Criteria of the homology and phylogeny of facial muscles in primates including man, II. Catarrhina. *Morphol Jahrb* **125**, 298–323.

Seiler R (1980) Ontogenesis of facial muscles in primates. *Morphol Jahrb* **126**, 841–864.

Sherwood CC, Holloway RL, Gannon PJ, et al. (2003) Neuroanatomical basis of facial expression in monkeys, apes, and humans. *Ann NY Acad Sci* **1000**, 99–103.

Shibata S (1959) On the facial musculature of *Macacus cyclopsis*. *OFAJ* **34**, 159–176.

Shoshani J, Groves CP, Simons EL, Gunnell GF (1996) Primate phylogeny: morphological vs molecular results. *Mol Phylogenet Evol* **5**, 102–154.

Silcox MT, Sargis EJ, Bloch JI, Boyer DM (2007) Primate origins and supraordinal relationships: morphological evidence. In *Handbook of Palaeoanthropology, Vol. 2: Primate Evolution and Human Origins* (eds Henke W, Tattersall I), pp. 831–859. Heidelberg: Springer Verlag.

Sirena S (1876) Ricerche della miologia del *Mycetes fuscus*. *Giorn Sci Nat Econ* **7**, 1–84.

Sommer A (1907) Das Muskelsystem des *Gorilla*. *Jena Z Naturwiss* **42**, 181–308.

Sonntag CF (1923) On the anatomy, physiology, and pathology of the chimpanzee. *Proc Zool Soc Lond* **23**, 323–429.

Sonntag CF (1924a) On the anatomy, physiology, and pathology of the orang-outan. *Proc Zool Soc Lond* **24**, 349–450.

Sonntag CF (1924b) *The Morphology and Evolution of the Apes and Man*. London: John Bale Sons and Danielsson Ltd.

Sperino G (1897) *Anatomia del cimpanzè (*Anthropopithecus Troglodytes*)*. Torino: Unione Tipografica.

Standring S (2004) *Gray's Anatomy*, 39th edn. London: Churchill Livingstone.

Sullivan WE, Osgood CW (1925) The facialis musculature of the orang, *Simia satyrus*. *Anat Rec* **29**, 195–343.

Sutton JB (1883) On some points in the anatomy of the chimpanzee (*Anthropopithecus troglodytes*). *J Anat Physiol* **18**, 66–85.

Swindler DR, Wood CD (1973) *An Atlas of Primate Gross Anatomy: Baboon, Chimpanzee and Men*. Seattle: University of Washington Press.

Terminologia Anatomica (1998) *Federative Committee on Anatomical Terminology*. Stuttgard: Georg Thieme.

Vick SJ, Waller BM, Parr LA, Smith Pasqualini MC, Bard KA (2007) A cross-species comparison of facial morphology and movement in humans and chimpanzees using the facial action coding system (FACS). *J Nonverb Behav* **31**, 1–20.

Virchow H (1915) Gesichtsmuskeln des Schimpansen. *Abh Preuss Akad Wiss* **1**, l-81.

Waller BM, Dunbar RIM (2005) Differential behavioural effects of silent bared teeth display and relaxed open mouth display in chimpanzees (*Pan troglodytes*). *Ethology* **111**, 129–142.

Waller BM, Vick SJ, Parr LA, et al. (2006) Intramuscular electrical stimulation of facial muscles in humans and chimpanzees: Duchenne revisited and extended. *Emotion* **6**, 367–382.

Waller BM, Burrows AM, Cray JJ (2008a) Selection for universal facial emotion. *Emotion* **8**, 435–439.

Waller BM, Parr LA, Gothard KM, Burrows AM, Fuglevand AJ (2008b) Mapping the contribution of single muscles to facial movements in the rhesus macaque. *Physiol & Behav* **95**, 93–100.

Wilder B (1862) Contributions to the comparative myology of the chimpanzee. *Boston J Nat Hist* **6**, 352–384.

Winkler LA (1989) Morphology and relationships of the orangutan fatty cheek pads. *Am J Primatol* **17**, 305–320.

Wood J (1866) Variations in human myology observed during the Winter Session of 1865–6 at King's College, London. *Proc R Soc Lond* **15**, 229–244.

Woollard HH (1925) The anatomy of *Tarsius spectrum*. *Proc Zool Soc Lond* **70**, 1071–1184.

Zuckerlkandl E (1900) Zur Anatomie von *Chiromys madagascarensis*. *Denkschr Akad Wiss Wien Math-Nat* **68**, 89–200.

Appendix 1 List of mammalian specimens dissected

Cynocephalus volans: USNM, 144941, 1 (alc); USNM, uncatalogued, 1 (alc). *Didelphis albiventris*: CML 5971, 1 (alc). *Homo sapiens*: GWU-ANA, 1–16, 16 (for). *Hylobates lar*: HU-ANA, H01, 1 (for). *Lepilemur ruficaudatus*: HU-ANA, L01, 1 (for). *Lutreolina crassicaudata*: CML 4114, 1 (alc). *Macaca mulatta*: HU-ANA, M01, 1 (for); YNPRC, M1–9, 9 (for). *Monodelphis dimidiata*: CML 4118, 1 (alc). *Otolemur garnettii*: DLC, OG1–10, 10 (for). *Otolemur crassicaudatus*: DLC, OC1–12, 12 (for). *Ornithorhynchus anatinus*: USNM, 13678, 1 (alc); USNM, uncatalogued, 1 (alc). *Pan troglodytes*: PFA, 1016, 1 (fre); PFA, 1009, 1 (fre); PFA, 1051, 1 (alc); HU-ANA, C104, 1 (for); GWU-ANT, 01, 1 (for); GWU-ANT, 02, 1 (for); YNPRC, C1–2, 2 (for); CMZ, C1–2, 2 (for). *Pongo pygmaeus*: HU-ANA, O01, 1 (for); GWU-ANT, 01, 1 (for). *Rattus norvegicus*: USNM, uncatalogued, 2 (alc). *Thylamys venustus*: CML 5586, 1 (alc). *Tupaia sp.*: USNM, 87244, 1 (alc), USNM, uncatalogued, 1 (alc).

© 2009 The Authors
Journal compilation © 2009 Anatomical Society of Great Britain and Ireland