True Hermaphroditism

W. LESTER HENRY, M.D., R. FRANK JONES, M.D., GEORGE C. CYPRESS, M.D.
and MERTON B. ANDERSON, M.D.
Howard University College of Medicine and Freedmen's Hospital
Washington, D. C.

AT THE present time 60 well documented cases of true hermaphroditism have been recorded in the world literature.[1] The case now reported is of interest because of the use of new diagnostic aids and the complete surgical conversion of the patient to a single sex.

On September 5, 1955, a baby was born to patient No. 134-003, Freedmen's Hospital, Washington, D. C. On superficial examination, this baby appeared to be a male with bifid scrotom and cryptorchidism. More careful inspection revealed that the phallus was not truly penile inasmuch as there was no urethral opening in the glans. The urethra was found to empty into a small urogenital sinus at the base of the phallus. The apparent bifid scrotum resembled labia majora (Figs. 1, 2, 3).

The following studies were made: 1) analysis of the 24 hour urine for 17 ketosteroids; 2) skin biopsy for determination of genetic sex; and 3) urologic studies including urography of the urogenital communication. The 17 ketosteroid excretion was reported to be 8.5 mg. per 24 hours. The skin biopsy was interpreted by us and by Doctor Barr of the University of Western Ontario as presenting a female pattern. Urologic studies demonstrated beautifully a urogenital sinus, uterus, and tube (Fig. 4).

These data supported a diagnosis of female pseudohermaphroditism. Therefore, it was decided to treat the baby with cortisone as suggested in similar cases by Wilkins.[2] Following control of 17 ketosteroid excretion the phallus was to be amputated and the child sent home. Additional surgery was to be done in the near future.

Cortisone therapy was begun. It soon became apparent that any dose of cortisone used controlled the 17 ketosteroid excretion. This raised a grave doubt about the validity of the initial 17 ketosteroid determination. Recalculation of the data revealed this initial value to have been in error and to have been 0.85 mg. instead of 8.5 mg.

Under these circumstances it seemed most likely that the child was a true hermaphrodiate instead of a female pseudohermaphrodite. Hence, abdominal exploration was performed on the 89th hospital day. Laparotomy revealed a uterus, two tubes, and four gonadal structures, (Fig. 5). On the left was an additional structure which was removed and each of the gonadal structures was biopsied.

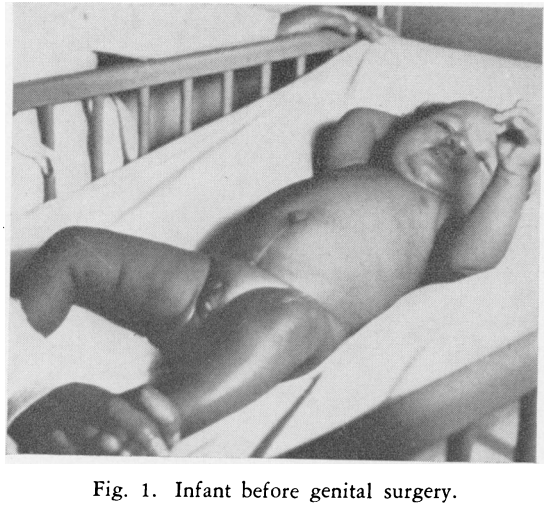

Fig. 1. Infant before genital surgery.

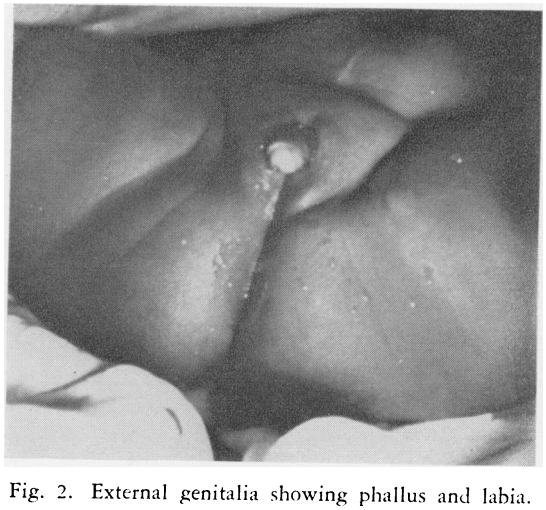

Fig. 2. External genitalia showing phallus and labia.

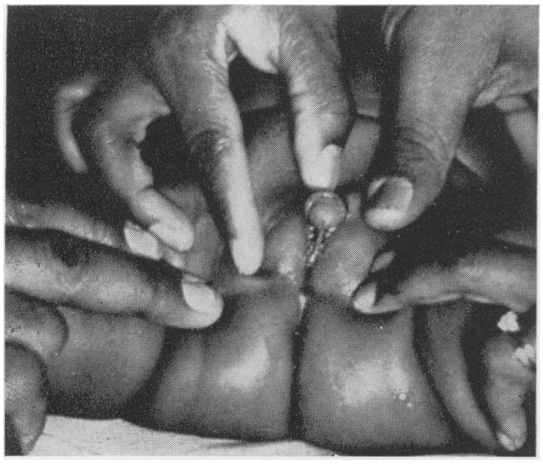

Fig. 3. Same as Fig. 2, with labia separated.

The pathologist's report identified two of the structures as ovotestes and two as ovaries. These tissues are described in detail as follows, together with microscopic sections. (Figs. 6, 7). The report follows:

SPECIMEN I

Gross: Lateral left mass, the most lateral and caudal to the broad ligament". This specimen consists of a small, smooth, light gray, soft and irregularly shaped bit of tissue, measuring approximately 4x3x1 mm. in maximum dimensions. Hemorrhage is noted on one surface.

Microscopic: Examination reveals a section of slightly hemorrhagic, somewhat loose and edematous, collagenous fibrous tissue. The edge of the section suggests a serosal surface except at one site. This surface believed to be serosa is formed by a hyaline membrane and this is covered by erythrocytes in regions. In one small area of the section are two tubular structures, lined by tall columnar epithelium. These are separated from each other by a small amount of very cellular fibrous tissue. These could represent tubular structures or ducts from either sex.

SPECIMEN II

Gross: Lateral mass of the left side (superior to broad ligament)". This is a small fragment of reddish brown, soft tissue measuring approximately 2.5x2x1 mm. in maximum dimensions.

Microscopic: Examination reveals a section of hemorrhagic and rather cellular fibrous tissue, most of which is bordered by a serosa. Some of this serosa is formed by the same type of tissue described in #1. Scattered throughout are numerous primordial follicles and cords or nests of deeply stained, small irregularly shaped cells with little cytoplasm, which resemble the primitive cells from the germinal epithelium.

Fig. 4. Roentgenogram showing Diodrast filling bladder, vagina, uterus and tube.

SPECIMEN III

Gross: Medial mass of the left side (superior to broad ligament)". This is a small, soft, irregularly shaped mass of reddish brown tissue, measuring approximately 5x3x1 mm. in maximum dimensions.

Miscroscopic: Examination reveals a bilobulated piece of fibrous tissue with a smooth serosa which is formed in part by a hyaline membrane, as seen in Specimen 1, and in part by dense collagenous connective tissue. Scattered in one lobule are many primordial follicles with only an occasional seminiferous tubule while in the other lobule are many seminiferous tubules with some primordial follicles located predominantly about the periphery of this lobule. Hemorrhage is evident particularly in the lobule containing the major portion of the primordial follicles. A few vascular channels are present.

SPECIMEN IV

Gross: "Lateral right mass", is similar to Specimen III measuring approximately 3x2x1 mm.

Microscopic: Examination reveals hemorrhagic fibrous tissue, partially covered by a somewhat thick layer of collagenous fibrous tissue, surmounted by a serosa. Scattered within this tissue are many irregularly shaped seminiferous tubules as well as several groups or cords of cells like those seen in Specimen II. In one microscopic field several (10-12) primordial follicles are seen.

SPECIMEN V

Gross: "Right medial mass", also resembles Specimen III, measuring approximately 3x2x1 mm.

Microscopic: Examination shows a microscopic picture similar to Section II with the additional feature of an atretic follicle.

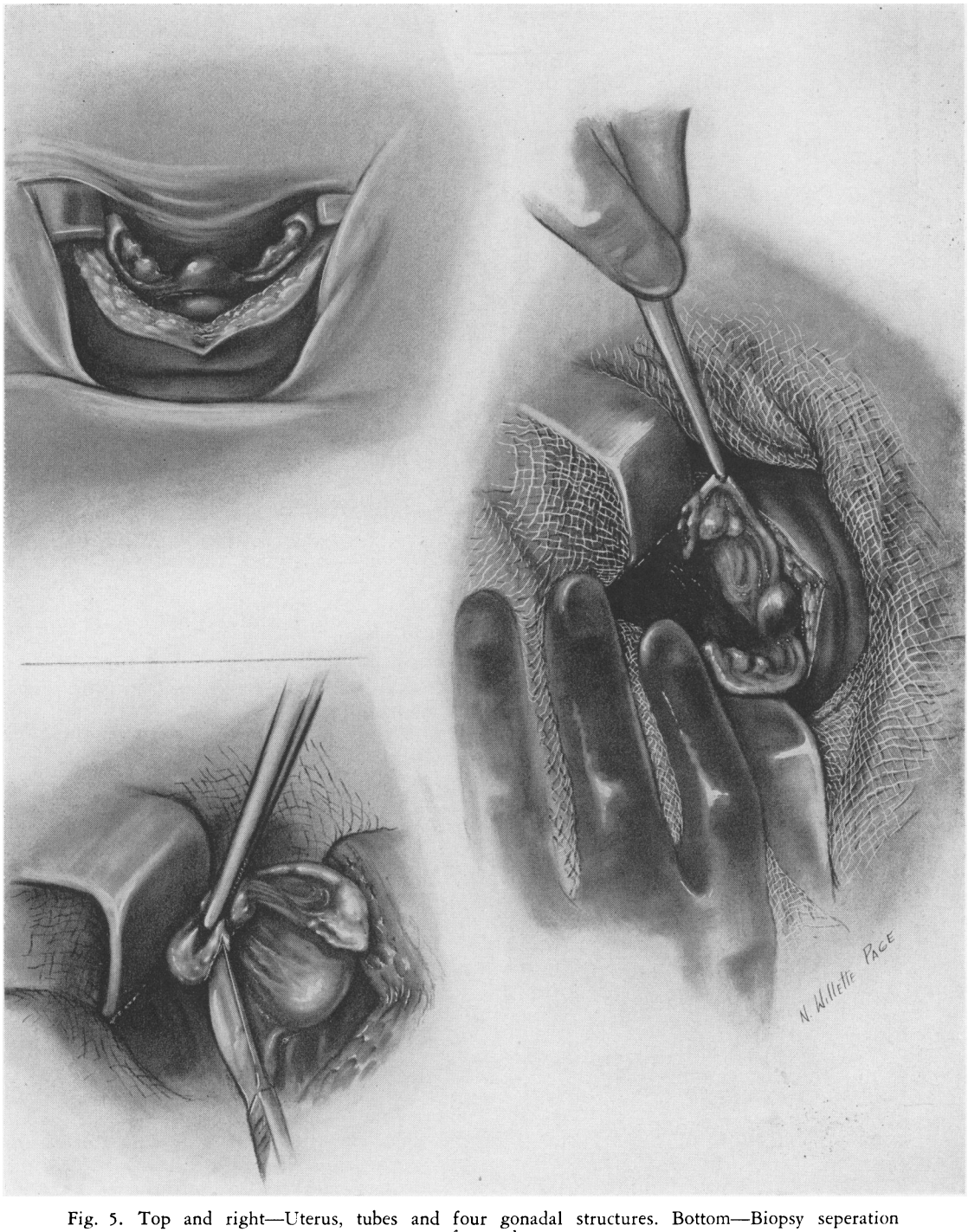

Fig. 5. Top and right—Uterus, tubes and four gonadal structures. Bottom—Biopsy seperation of gonad.

Impressions:

Specimen I—Undetermined Structure
" II—Ovary
" III—Ovo-testis
" IV—Ovo-testis
" V—Ovary

Convalescence from the initial operation was complicated by diarrhea. However on the 135th hospital day the child was again evaluated by the services concerned and the following decisions were made. The gonads identified as ovotestes were to be removed, to avoid activation by the pituitary at puberty and to eliminate the

Fig. 6. Ovotestis showing ovarian follicles on left and seminiferous tubules on right.

risk of neoplasia in abdominal testicular tissue. The phallus was to be removed and separation of urethra and vagina together with repair of the perineum were to be effected at a time in the future.

The ovotestes were removed on the 148th hospital day. On the 171st hospital day the phallus was amputated (Figs. 8, 9). As the vaginal and urethral structures could be separated and repaired simply at this time a complete plastic repair of the external genitalia was performed. Convalescence was speedy and the child was discharged on the 206th hospital day.

The child is well and healthy at present (Fig. 10).

DISCUSSION

Hermaphroditism is a term indicating the presence of male and female physical sexual characteristics in one individual. When both testicular

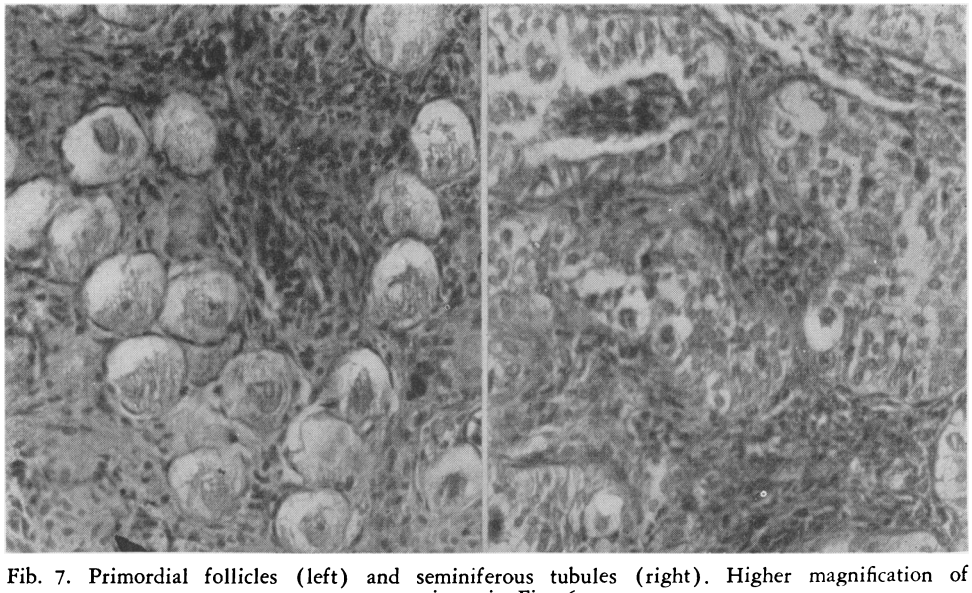

Fib. 7. Primordial follicles (left) and seminiferous tubules (right). Higher magnification of specimen in Fig. 6.

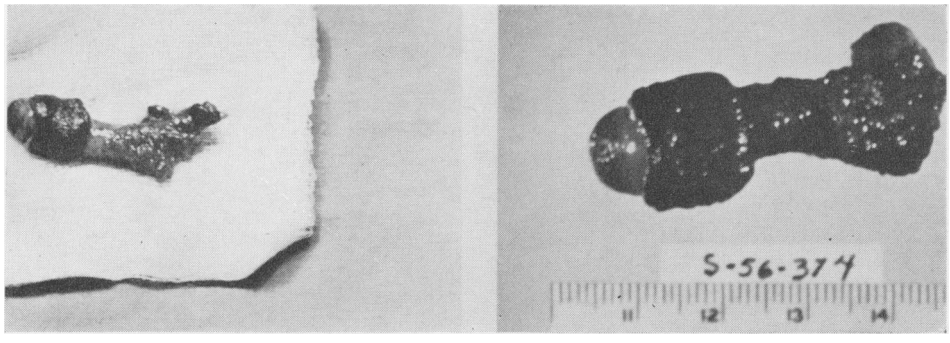

Fig. 8. Amputated phallus. Two views.

and ovarian tissue are present in such an individual the condition is defined as true hermaphroditism. When testicular or ovarian tissue alone is present the condition is defined as false or pseudo-hermaphroditism. This may be of male or female type depending on the nature of the gonad present (Fig. 11).

Female Pseudohermaphroditism

Only the female pseudohermaphrodite is hormonally determined. In this type, possessing only ovarian tissue, the individual is partially masculinized during fetal life because of the secretion of a strong androgen by the fetal adrenal cortex.

This group has been well studied, particularly by Wilkins.[2] The adrenal dysfunction is congenital and represents a biochemical error in the manufacture of steroid hormones. A strong androgen is produced in very large amounts, the C-11 oxysteroids are produced in reduced amounts. Thus gonadotropic activity of the pituitary is inhibited by the androgen while adrenocorticotropic secretion of the pituitary is increased in an effort to improve the production of C-11 oxysteroids. This inhibition of gonadotropin secretion prevents the normal activation of the ovary at puberty or any period of life. The increased secretion of adrenocorticotropic hormone leads to hypertrophy and hyperplasia of the adrenals, (Fig. 12). This hormonal imbalance can be corrected by administration of cortisone or related C-11 oxysteroids. These suppress adrenocorticotropic secretion and thereby stop adrenocortical activity. There follows disappearance of the abnormal androgen and release of pituitary gonadotropins. This therapy must be continued throughout life, inasmuch as the adrenal defect is permanent.

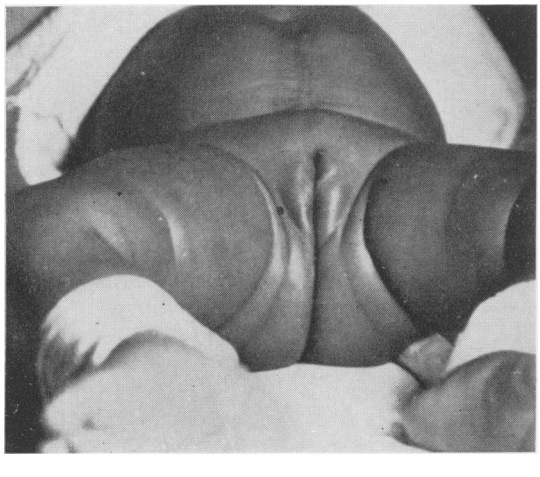

Fig. 10. Photograph of external genitalia after repair.

Fig. 11

	Chromosomal Sex	*17 K.S*
Male Pseudohermaphrodite	Male	Normal
Female Pseudohermaphrodite	Female	Elevated
True Hermaphrodite	Either	Normal

Male Pseudohermaphroditism

Studies on the rat, rabbit, and man indicate that destruction of the gonad in embryonic life before differentiation of the reproductive tract leads to the development of a female reproductive tract, irrespective whether the gonad was ovary or testis.[3] For the male reproductive tract to develop, a gonad must be present which secretes an active androgen, similar to but not identical with testosterone.

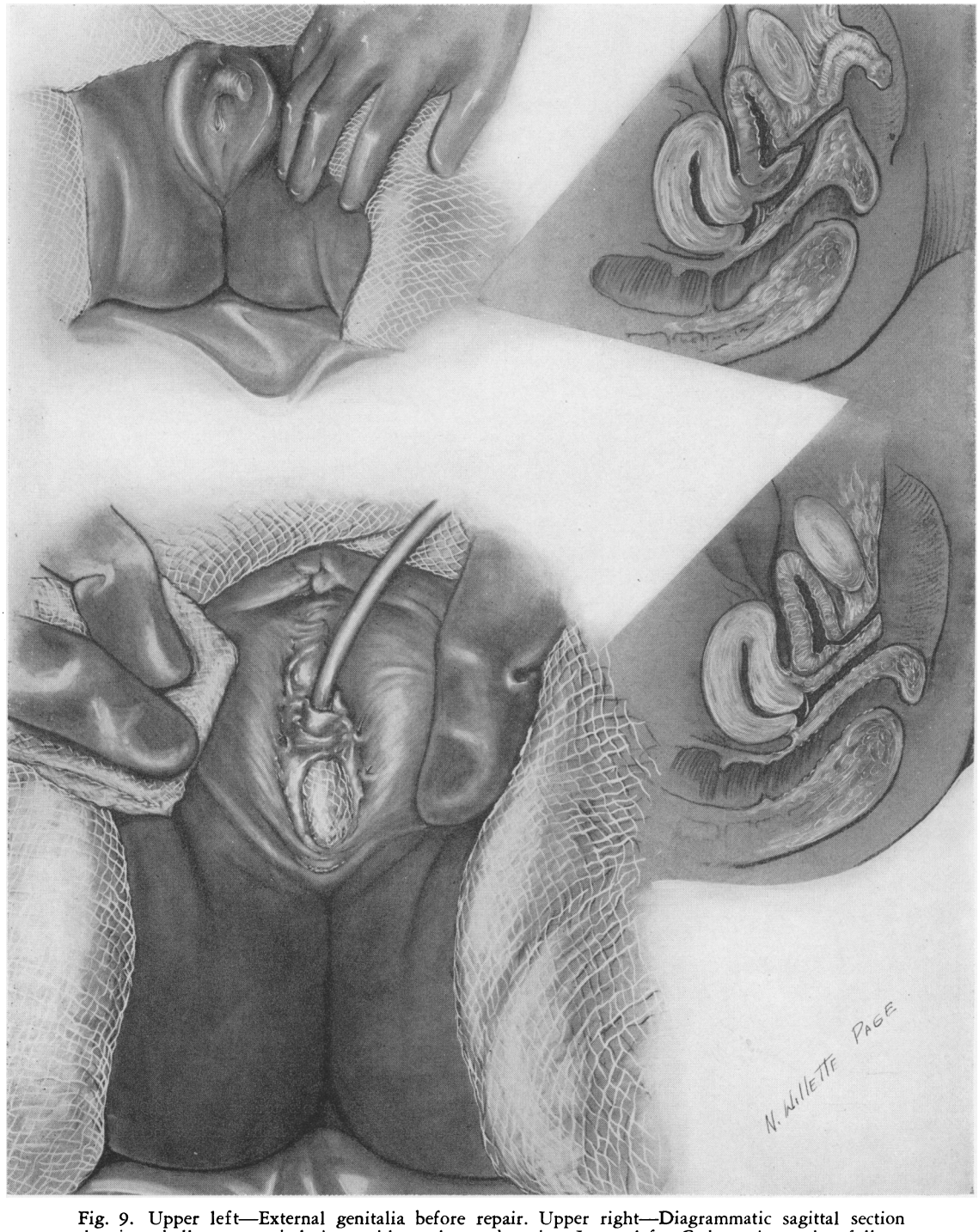

Fig. 9. Upper left—External genitalia before repair. Upper right—Diagrammatic sagittal section showing phallus, urogenital sinus with urethra and vagina. Lower left—Catheter in urethra following amputation of phallus and separation of urethra and vagina. Lower right—Diagram showing vestibule with separate urethral and vaginal openings.

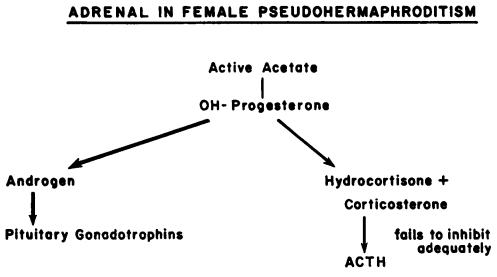

Fig. 12.

The male pseudohermaphrodite represents an individual who suffered damage to his testis during the critical 3rd to 5th months of fetal life. Such a testis would not elaborate male hormone in sufficient quantity resulting in a mixture of male and female characteristics in the reproductive tract.

True Hermaphroditism

In true hermaphroditism both ovaries and testes are present. The two gonads may be present bilaterally or unilaterally or an ovary may occur on one side and a testis on the other. The gonad on either or both sides may be an ovotestis. The resulting reproductive tract on each side will be determined by the nature of the gonad on the side in question. This has been an invariable rule in all reported cases.

Refinement in the diagnosis of hermaphroditic states followed the application of Barr's chromosomal analysis of skin cells to determine genetic sex.[4] The presence of marked peripheral clumping of chromatin occurs only in the female and enables one to separate individuals into genetic or chromosomal males and females (Fig. 13).

Psychologic sex is determined shortly after the age of two years.[5] Therefore, if one hopes to achieve uniformity of gonadal, chromosomal, and psychologic sex one must diagnose these cases early and accomplish the necessary steps as expeditiously as possible.

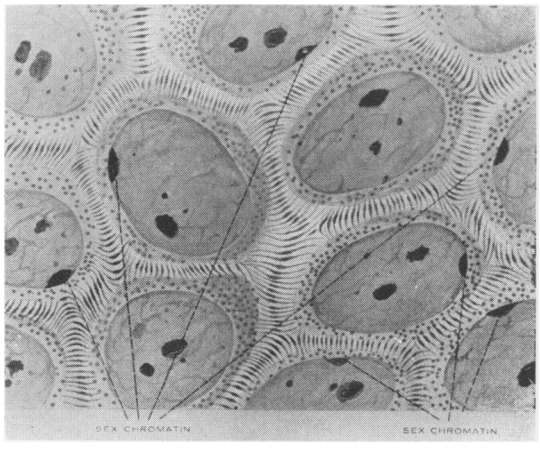

Fig. 13. Chromatin clumping in skill cells of female (after Barr).

SUMMARY

We have presented a case of true hermaphroditism and the methods utilized to diagnose and treat such cases. We believe this to be the earliest completely restored true hermaphrodite on record.

LITERATURE CITED

1. BROMWICH, A. J. British Med. J. 1, 395, 1955.
2. WILKINS, L. and R. A. LEWIS, and R. KLEIN, and L. I. GARDINER, and J. T. GRIGLER, and E. ROSENBERG and C. J. MIGEON. J. Clin. Endocrinol. 1:1. 1951.
3. JOST, A. Recent Progress in Hormone Research, VIII. 379, 1953.
4. BARR, M. L. Anat. Rec., 121, 387, 1955.
5. HAMPSON, J. G. and J. MONEY, and J. L. HAMPSON. J. Clin. Endocrin. 16:4, 547, 1956.

NEW GRANTS FOR MEDICAL RESEARCH FACILITIES

The Public Health Service announced on March 30 approval of 35 grants totaling $3,974,943 to help 27 research institutions in 18 states build additional facilities for research in cancer, heart disease, mental illness and other major illnesses.

The grants were approved by Surgeon General Leroy E. Burney upon recommendation of the National Advisory Council on Health Research Facilities.

The Council, which met at the Public Health Service's National Institutes of Health on March 18-20, reviewed 165 applications amounting to about $66,384,500. Applications for grants will again be considered by the Council on May 27-29.

Congress last year authorized $30,000,000 a year for three years in grants to research institutions on an equal matching basis for the construction and extension of research facilities. The law also established the Health Research Facilities Council, which now has approved 109 grants totaling approximately $30,000,000.