S. J. CREWS: POSTERIOR SUBCAPSULAR LENS OPACITIES

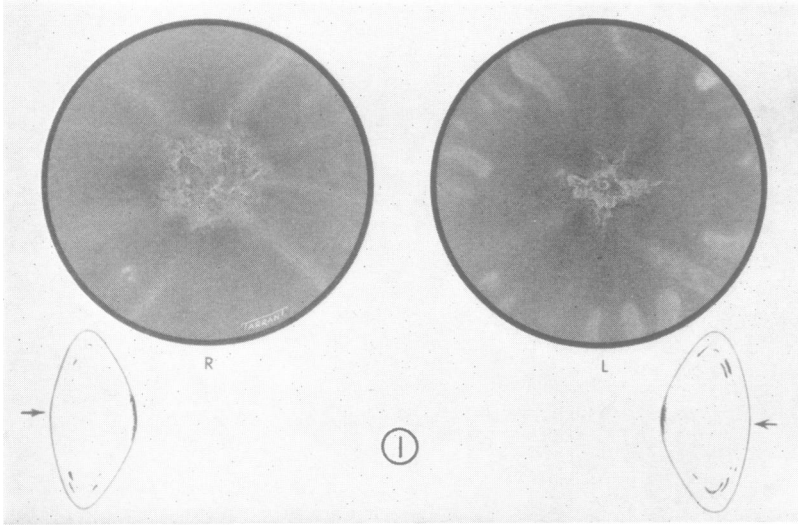

FIG. 1.—Early bilateral cataract; drawings of both eyes. Diagrams show site of opacities.

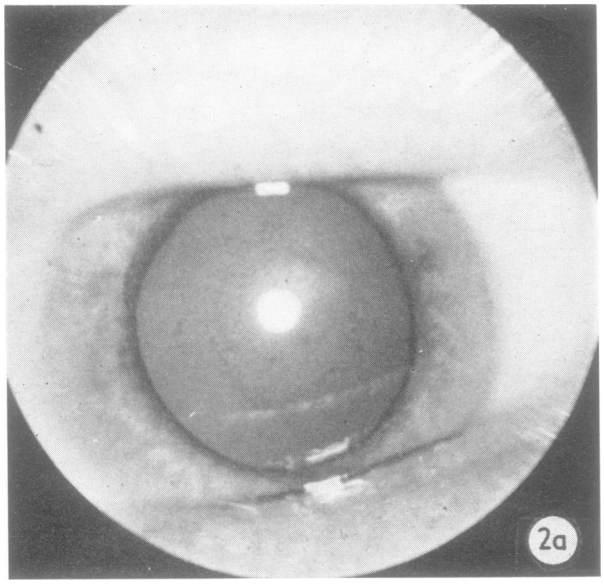

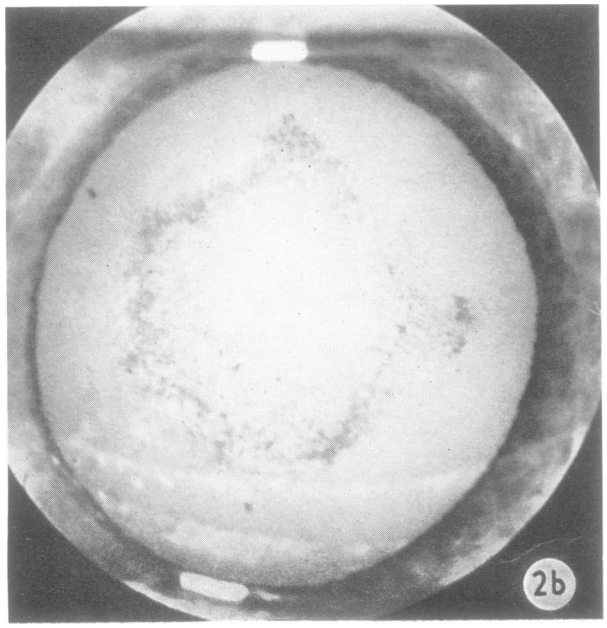

FIG. 2.—Patient with advanced cataract in both eyes. Photographs of right eye: (*a*) low power; (*b*) high power (histology of this right lens is reported in text).

S. ORAM *ET AL.*: RENAL CORTICAL CALCIFICATION AFTER SNAKE-BITE

FIG. 1.—Kidneys are contracted. Dense marginal calcified bands, approximately 2 mm. wide, are seen in the cortex. Irregular strands of calcification extend inwards towards the renal pelves and enclose irregular translucent zones, which are presumably deformed renal pyramids.

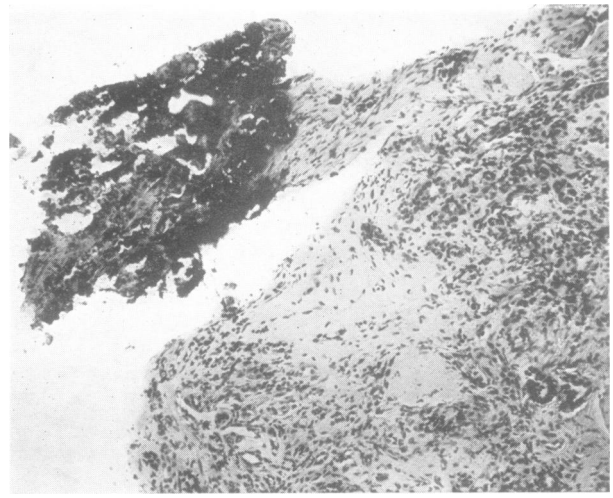

FIG. 2.—Photomicrograph of renal biopsy material (×150). The darkly stained area is necrotic calcified tissue. Two shrunken hyalinized glomeruli are seen, and between them is a dense infiltrate of mononuclear cells.

Harris, J. E., and Gruber, L. (1962). *Exp. Eye Res.*, **1**, 372.
Kirby, D. B. (1927). *Trans. Amer. Acad. Ophthal. Otolaryng.*, 203.
Ogelsby, R. B., Black, R. L., von Sallmann, L., and Bunim, J. J. (1961a). *Arch. Ophthal.*, **66**, 519.
—— —— —— —— (1961b). Ibid., **66**, 625.
Pfahl, S. B., Makley, T. A., McCoy, F. W., and Rothermich, N. O. (1961). *Amer. J. Ophthal.*, **51**, 710.
von Sallmann, L., Caravaggio, L. L., Collins, E. M., and Weaver, K. (1960). Ibid., **50**, 1147.
Toogood, J. H., Dyson, C., Thompson, C. A., and Mularchyk, E. J. (1962). *Canad. med. Ass. J.*, **86**, 52.

RENAL CORTICAL CALCIFICATION AFTER SNAKE-BITE

BY

SAMUEL ORAM, M.D., F.R.C.P. GORDON ROSS, M.B., B.S., M.R.C.P.
LIONEL PELL, M.B., B.S., M.R.C.P., D.M.R.D. JOHN WINTELER, M.D., M.R.C.P.

From King's College Hospital, London

[WITH SPECIAL PLATE]

Bilateral renal cortical necrosis is uncommon and even nowadays survival is rare. The clinical syndrome consists of the abrupt onset of oliguria which proceeds to anuria and uraemia, often with bilateral lumbar pain and sometimes with haematuria, but the blood-pressure remains normal or is only slightly raised as a rule. It is due to bilateral symmetrical patchy or diffuse ischaemic coagulative cortical necrosis with sparing of the medulla. A thin rim of cortical tissue 1–2 mm. wide immediately below the kidney capsule (cortex corticis) is also spared. Associated lesions which may be present include necrosis of the anterior pituitary gland and, more rarely, the adrenal (Sheldon and Hertig, 1942). According to Lauler and Schreiner (1958) the condition was first described by Juhel-Renoy in 1886.

The incidence of cortical necrosis is difficult to ascertain, since a definite diagnosis can be made in life only by renal biopsy. Fewer than 200 examples have been reported, though undoubtedly many more unpublished cases have occurred. Although the causes are numerous, as revealed in the excellent reviews of Duff and More (1941), Wahle and Muirhead (1953), and Lauler and Schreiner (1958), in fact they can be divided into three main groups. In women cortical necrosis is usually associated with accidental haemorrhage (abruptio placentae) or toxaemia in the last trimester—this group is the largest, accounting for more than half of the total cases; in men it is usually due to overwhelming infections or poisons causing bacterial shock; and in children vomiting and diarrhoea leading to dehydration is the commonest cause. Among other causes recorded are incompatible blood transfusions (Wahle and Muirhead, 1953), multiple fractures and internal haemorrhages (McFarlane, 1941), severe burns (Brown and Crane, 1943), peritonitis (McQueeney and Speed, 1952), streptococcal infection (DeGraeff and DeBaan, 1959), and phosphorus poisoning (Perry, 1953). Subsequent calcification of the renal cortices is extremely rare, and, so far as we can ascertain, it has been described during life in only five patients (Gormsen *et al.*, 1955; Moëll, 1957; DeGraeff and DeBaan, 1959; McAlister and Nedelman, 1961; Lloyd-Thomas *et al.*, 1962). The last-mentioned workers noted a double line or "tramline" pattern in the renal cortex radiologically.

In our patient severe bilateral renal cortical necrosis developed after snake-bite. She was treated by haemodialysis and made a partial recovery, but seven months later extensive bilateral radiological calcification of the kidneys was demonstrated. Survey of the literature has failed to reveal any other example of calcified renal cortical necrosis arising from this cause.

Clinical Features

A married woman of 50 was bitten on the right ankle by a snake at 10.30 p.m. on September 9, 1961, while she was in the vicinity of Lake Rudolph, Kenya. The snake was not positively identified, but was thought by the local experts to have been a saw-scaled sand viper (*Echis carinatus*). The patient immediately cut into the bite with a scalpel until the wound bled freely, and then rubbed in a mixture of potassium permanganate and iodine. After a few hours the right foot and ankle became painful and oedematous. During the next day she vomited blood several times and became anuric. Three days later she was flown to Kitale, by which time a haemorrhagic state had developed with epistaxis, haematemesis, melaena, and haemorrhages into both orbits. Four days later she was flown to Nairobi, where examination revealed fang marks and a large blister on the right ankle. Ecchymoses were present on the right arm, the left side of the neck, and the right groin. No clinical abnormality was detected in the respiratory, cardiovascular, or central nervous systems. The blood-pressure was 135/80 and the retinae were normal. At no time did clinical jaundice appear.

Investigations yielded the following results: blood urea 440 mg./100 ml.; serum electrolytes (mEq/l.)—sodium 136, potassium 7.5, chloride 85, alkali reserve 14, calcium 4.9, magnesium 3.0; *p*H (arterial blood) 7.3; haemoglobin 5.1 g./100 ml., W.B.C. 40,000/c.mm; P.C.V. 20%.

On September 19, under the direction of Dr. W. E. Lawes, dialysis was performed, using a Kolff double-coil machine, and by the next day the serum potassium had fallen to 5 mEq/l. and the blood urea to 330 mg./100 ml. Three weeks after being bitten the patient began to pass urine—at first in small amounts with much albumin, and later in increasing quantities. During her recovery the area of the wound sloughed and a skin graft was necessary. Her general condition slowly improved and she was able to leave hospital on December 9. The blood urea was then 117 mg./100 ml. and the haemoglobin 9 g./100 ml. Her weight, which was 47.5 kg. before being bitten, had fallen to 38 kg.

In April, 1962, she came to London. During the intervening months she had experienced malaise, anorexia, and occasional vomiting. She tired easily, was breathless on exertion, and her ankles tended to swell. On examination she looked sallow and unwell and was obviously anaemic. Apart from a trace of oedema at the ankles, however, there were no other abnormal physical signs; blood-pressure 140/70, retinae normal.

Investigations.—Blood count: haemoglobin 8.2 g./100 ml., red cells normochromic, heavy granulation of neutrophils, ample platelets. Urine: specific gravity 1005–1011; slight proteinuria, no casts, sterile, volume of night urine almost equal to volume of day urine. Plasma proteins: 7.2 g./100 ml., electrophoresis normal. Serum electrolytes (mEq/l.)—sodium 135, potassium 4.5, chloride 103, alkali reserve 20; blood urea 138 mg./100 ml. Liver-function tests normal. Chest *x*-ray picture normal. Electrocardiogram normal. *X*-ray examination of the abdomen (Special Plate, Fig. 1): plain films revealed contracted calcified kidneys with crenated wavy margins; the right kidney measured 10.4 by 4.8 cm. and the left 10.9 by 4.8 cm. (normal for women: right 12.4 ± 0.66 by 5.9 ± 0.37 cm., left 12.8 ± 0.77 by 6.1 ± 0.38 cm., Moëll, 1956). The calcification appeared to be distributed in a streaky fashion throughout the kidneys.

Tomograms, however, revealed dense marginal wavy calcified bands of approximately 2 mm. width. Irregular strands of calcification extended inwards from these towards the renal pelves. These strands enclosed a number of irregular translucent areas. It is presumed that the calcified areas represented the remaining contracted renal cortex and that the enclosed translucent zones were deformed renal pyramids. Percutaneous renal biopsy (kindly performed by Dr. C. Comty): The specimen consisted mainly of calcific material, but a small fragment of scarred renal cortex was included. In some of the serial sections shrunken glomeruli with a thickened capsule surrounded by a dense infiltrate of mononuclear cells were seen (Special Plate, Fig. 2).

The patient was discharged from hospital on August 8 on a low-protein diet, norethandrolone ("nilevar") 10 mg. t.d.s., and instructions to drink at least 5 pints (2.8 litres) of fluid daily. She continued to experience malaise, anorexia, and lassitude, but on September 9 the blood urea had fallen slightly to 104 mg./100 ml. When last seen in February, 1963, she had regained her normal weight of 7½ stone (47.6 kg.) and was well apart from occasional vomiting. The blood-pressure was 140/90, and the urine, specific gravity 1012, showed a trace of albumin. The blood urea had fallen to 80 mg./100 ml. and she had a normocytic anaemia (haemoglobin 10.8 g./100 ml.) with a minor degree of undersaturation of the red cells. The period of survival from the onset of bilateral renal cortical necrosis has exceeded one year.

Discussion

Lloyd-Thomas *et al.* (1962) could find only three examples of cortical necrosis, proved by needle biopsy, which recovered, and only one of these, the patient of Gormsen *et al.* (1955), had renal calcification. We have found records of a second patient with cortical calcification who recovered (McAlister and Nedelman, 1961), and our own case reported here brings the total to three.

To our knowledge only one other example has been reported of acute renal failure due to snake-bite and treated by dialysis (Danzig and Abels, 1961). The patient, an 11-year-old boy, survived, but there was no mention of the radiological appearance of the kidneys.

In Kenya snake-bites are not of common occurrence in Europeans, and Hall (1962) reported that only 18 requests for serum had been received during the course of a year.

The clinical findings make it almost certain that our patient was bitten by one of the family of Viperidae, probably the saw-scaled sand viper *Echis carinatus*, which is common in the district concerned. The venom of these snakes consists of a mixture of toxic proteins and enzymes with haemotoxic and necrotizing actions. Circulatory collapse, a haemorrhagic state, haemolysis, and local tissue loss have all been described, and each of these could have contributed to the development of renal cortical necrosis.

Previously Reported Examples of Renal Cortical Calcification

Only five cases have been recorded in which renal cortical calcification was demonstrated radiologically during life, and only two patients survived. All were females and either severely oliguric or anuric (see Table).

Calcification may develop in any necrotic tissue, and Gomori (1943) demonstrated that when necrosis occurred in tubercles in the lung of a rabbit phosphatase appeared in the centre of the necrotic area. It is possible that a similar accumulation occurs in necrotic renal tissue and acts on the phosphate esters to raise the product $(Ca^{++})^3 \times (PO_4^{111})^2$ to values needed for the precipitation of calcium phosphate. It is of interest that the kidney is rich in phosphatase (Kay, 1932).

McAlister and Nedelman (1961) consider that a period of survival of one and a half to two months is necessary for the development of radiologically visible calcification following renal cortical necrosis.

Two of the five patients with renal calcification were alive 9 and 19 months after the onset of their illness. The survival of such patients is presumably due to the patchy distribution of the necrotic areas leaving enough viable cortical tissue to maintain life. Nevertheless, if the extensive renal calcification of our own patient is a reliable index of the amount of renal cortical necrosis, her continuing survival for 18 months is remarkable.

Summary

An example of severe renal cortical calcification following snake-bite is described. In acute cortical necrosis haemodialysis now enables life to be sufficiently prolonged for radiological calcification to appear, but only two other such examples of survival have been recorded.

References

Brown, C. E., and Crane, G. L. (1943). *J. Amer. med. Ass.*, **122**, 871.
Danzig, L. E., and Abels, G. H. (1961). Ibid., **175**, 136.
DeGraeff, J., and DeBaan, P. (1959). *Acta med. scand.*, **163**, 341.
Duff, G. L., and More, R. H. (1941). *Amer. J. med. Sci.*, **201**, 428.
Gomori, G. (1943). *Amer. J. Path.*, **19**, 197.
Gormsen, H., Iversen, P., and Raaschou, F. (1955). *Amer. J. Med.*, **19**, 209.
Hall, L. (1962). *E. Afr. med. J.*, **39**, 66.
Juhel-Renoy, E. (1886). *Arch. gén. Méd.*, **17**, 385.
Kay, H. D. (1932). *Physiol. Rev.*, **12**, 384.
Lauler, D. P., and Schreiner, G. E. (1958). *Amer. J. Med.*, **24**, 519.
Lloyd-Thomas, H. G., Balme, R. H., and Key, J. J. (1962). *Brit. med. J.*, **1**, 909.
McAlister, W. H., and Nedelman, S. H. (1961). *Amer. J. Roentgenol.*, **86**, 129.
McFarlane, D. (1941). *J. Path. Bact.*, **52**, 406.
McQueeney, A. J., and Speed, H. K. (1952). *Rocky Mtn med. J.*, **49**, 513.
Moëll, H. (1956). *Acta radiol. (Stockh.)*, **46**, 640.
—— (1957). Ibid., **48**, 355.
Perry, J. W. (1953). *Aust. Ann. Med.*, **2**, 94.
Sheldon, W. H., and Hertig, A. T. (1942). *Arch. Path.*, **34**, 866.
Wahle, G. H., jun., and Muirhead, E. E. (1953). *Texas J. Med.*, **49**, 770.

Previously Reported Examples of Renal Cortical Calcification

Author	Age & Sex	Aetiology	Days Between Onset of Illness and Detection of Calcification	Radiological Findings	Outcome
Gormsen *et al.* (1955)	21 F	Unknown	61	Tomograms showed diffuse calcification in peripheral parts of both cortices	Haemodialysis with recovery. Blood urea 59 mg./100 ml. nine months after onset
Moëll (1957)	27 F	Severe haemorrhage from vaginal caesarean section	49	Scattered cortical calcification. Shrunken kidneys	Haemodialysis. Death after 116 days
DeGraeff and DeBaan (1959)	14 F	Streptococcal infection of throat	57	Extensive calcinosis of both kidneys on plain *x*-ray film. (Renal biopsy on 20th day revealed calcium in cortex)	Peritoneal lavage. Death after 87 days.
McAlister and Nedelman (1961)	24 F	Haemorrhage from placenta praevia	57	Moderate cortical calcification; 19 months later further calcification had occurred	Haemodialysis with recovery. Blood urea normal after 19 months. Urea and creatinine clearances low
Lloyd-Thomas *et al.* (1962)	26 F	Severe haemorrhage from abortion at 26th week	31	"Tramline" pattern of calcification in both cortices	Haemodialysis. Death after 55 days